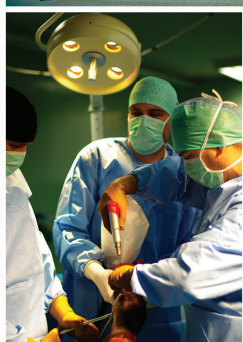




ISSN 2706 - 1795
ISBN 978-953-8006-24-1

OCTOBER 10TH - 12TH 2019 • ZAGREB • CROATIA



8TH INTERNATIONAL CONGRESS "VETERINARY SCIENCE AND PROFESSION"

BOOK OF ABSTRACTS



1919-2019

VETERINARSKI FAKULTET
SVEUČILIŠTA U ZAGREBU



8TH

**INTERNATIONAL
CONGRESS**

“VETERINARY SCIENCE AND PROFESSION”

/// OCTOBER 10TH - 12TH 2019 ///

//// ORGANISER

University of Zagreb
Faculty of Veterinary Medicine

ORGANISING COMMITTEE

President:

Zoran Vrbanac

Vice-presidents:

Nika Brkljača Bottegaro
Nevijo Zdolec

Local Organising Committee:

Iva Benven, Diana Brozić, Ivan Forgač, Anđelko Gašpar, Jelena Gotić, Alen Hraštnik, Maja Lukač, Tatjana Karačić, Luka Krstulović, Nino Maćešić, Maja Maurić, Nikica Prvanović Babić, Marko Pećin, Lada Radin, Luka Radmanić, Zrinka Štritof, Ana Shek-Vugrovečki, Iva Šmit, Vesna Špac, Daniel Špoljarić, Jelena Šuran, Marin Torti, Hrvoje Valpotić, Ivan Vlahek, Lana Vranković, Ivona Žura Žaja

International Organising Committee:

Sanja Aleksić-Kovačević, Tibor Bartha, Otto Doblhoff-Dier, Nihad Fejzić, Andrej Kirbiš, Danijela Kirovski, Atila Kos, Vanja Krstić, Jana Mojžišova, Lazo Pendovski, Vladimir Petkov, Muhamed Smajlović, Peter Sotonyi, Breda Jakovac Strajn, Martin Tomko, Igor Ulčar, Gorazd Vengušt, Petra Winter, Petra Zrimšek

Scientific Committee:

President: Dean Konjević

Jasna Aladrović, Goran Bačić, Ljubo Barbić, Željko Cvetnić, Tomislav Dobranić, Petar Džaja, Martina Đuras, Anamaria Ekert Kabalin, Željko Grabarević, Juraj Grizelj, Andrea Gudan-Kurilj, Boris Habrun, Danijela Horvatek Tomić, Josip Madić, Dean Konjević, Alemka Markotić, Dražen Matičić, Vesna Matijatko, Zoran Milas, Marko Samardžija, Andrea Prevendar Crnić, Alen Slavica, Krešimir Severin, Nenad Turk, Romana Turk, Ivana Tlak Gajger, Tatjana Vilibić-Čavlek, Ksenija Vlahović

ISSN 2706 - 1795

ISBN 978-953-8006-24-1

All abstracts published in this Book of Abstracts have been reviewed by an international scientific committee.

//// IMPRESSUM

Editors in-Chief

Nika Brkljača Bottegaro, Nevijo Zdolec, Zoran Vrbanc

Editorial Board

Diana Brozić, Dean Konjević, Lana Radin, Nenad Turk

Reviewers

Jasna Aladrović, Sanja Aleksić Kovačević, Goran Bačić, Ljubo Barbić, Tibor Bartha, Maja Belić, Nina Bilandžić, Sanja Bosnić, Nika Brkljača Bottegaro, Mirna Brkljačić, Diana Brozić, Darko Capak, Martina Crnogaj, Željko Cvetnić, Tomislav Dobranić, Petar Džaja, Martina Đuras, Anamaria Ekert Kabalin, Tomislav Gomerčić, Jelena Gotić, Željko Gottstein, Željko Grabarević, Juraj Grizelj, Andrea Gudan Kurilj, Josipa Habuš, Suzana Hađina, Danijela Horvatek Tomić, Doroteja Huber, Danijela Kirovski, Ivana Kiš, Dean Konjević, Vanja Krstić, Snježana Kužir, Nikša Lemo, Maja Lukač, Nino Maćešić, Josip Madić, Tomislav Mašek, Dražen Matičić, Vesna Matijatko, Maja Maurić, Hrvoje Mazija, Sven Menčik, Željko Mikulec, Jana Mojžišova, Vladimir Mrljak, Marko Pećin, Boris Pirkić, Nikica Prvanović Babić, Lada Radin, Berislav Radišić, Marko Samardžija, Krešimir Severin, Ana Shek-Vugrovečki, Magda Sindičić, Alen Slavica, Muhamed Smajlović, Vilim Starešina, Iva Šmit, Ivan Conrado Šoštarić Zuckermann, Daniel Špoljarić, Zrinka Štritof, Jelena Šuran, Ivana Tlak Gajger, Martin Tomko, Marin Torti, Nenad Turk, Romana Turk, Hrvoje Valpotić, Gorazd Vengušt, Silvijo Vince, Ksenija Vlahović, Dražen Vnuk, Lana Vranković, Zoran Vrbanc, Nevijo Zdolec, Diana Žele Vengušt, Ivona Žura Žaja

Congress Secretary

Marta Kiš

Language Revision

Ana Sabljak

Graphic design

Ivan Badanjak

Publisher

Faculty of Veterinary Medicine, University of Zagreb
10000 Zagreb, Heinzlova 55

Dear Colleagues,

It is with great pleasure that I welcome you to the 8th International Congress "Veterinary Science and Profession" on behalf of the Organising Committee.

In the year when the University of Zagreb is celebrating 350 years and the Faculty of Veterinary Medicine 100 years of existence, the Congress is one of the events marking the celebration.

This year we are offering a three-day programme divided into six sessions – Veterinary Public Health, Farm Animals, Horses, Exotic and Wild Animals, Small Animals and Free Communications.

We are pleased to present a panel of distinguished invited speakers from multiple countries as well as an impressive number of oral and poster presentations in a wide variety of topics. There are also fourteen workshops dedicated to a hands-on learning environment in order to advance clinical, laboratory and analytical skills of participants.

The PhD Day of the Faculty of Veterinary Medicine will again take place during the Congress. This is a valuable opportunity for young scientists to present their research and contribute to the advancement of veterinary medical science.

The concept of One Health is a vital part in the future of human welfare, and the final day of the Congress will explore the role of veterinarians in the global One Health initiative.

We hope you enjoy your time in Zagreb and discover new ideas and techniques during the Congress. We would like to thank all of the participants, sponsors, invited speakers and workshop leaders who have made the Congress possible.



Assist. Prof. **Zoran Vrbanc**, DVM, PhD, DECVSMR, DACVSMR
President of the Organizing Committee

Acknowledgements

The Congress and the production of these proceedings were supported by the following organisations:

Under the auspices of

The President of the Republic of Croatia Kolinda Grabar Kitarović

The City of Zagreb

Supported by

The Foundation of the Croatian Academy of Sciences and Arts

Ministry of Science and Education

Silver sponsor

MEDICAL INTERTRADE

Bronze Sponsor

DECHRA

Sponsors

AGROPROTEINKA

BIG BLUE

DDL

ELDAN

NOACK

KUŠIĆ PROMET

LABOKLIN

MEDICINSKA NAKLADA

RAUCH

ZAGREB ZOO

Additional support received from

THE FACULTY OF VETERINARY MEDICINE, UNIVERSITY OF ZAGREB

PROGRAM

///// • THURSDAY OCTOBER 10TH 2019 - MAIN LECTURE HALL /////

07.30 - 09.00 REGISTRATION

09.00 - 09.30 OPENING CEREMONY

09.30 - 10.10 KEYNOTE LECTURE

Prof. **Renate Weller**, DVM, PhD, MScVetEd, FHEA, NTF, ECVSMR, ACVSMR, MRCVS, RCVS
Specialist in Diagnostic Imaging

Director of Veterinary Education, CVS (UK) Ltd, London, United Kingdom

**• THE VETERINARY GRADUATE OF TODAY: FIT FOR PURPOSE?
NEW TRENDS IN VETERINARY EDUCATION**

VETERINARY PUBLIC HEALTH - MAIN LECTURE HALL

Chairs: Nevijo Zdolec, Zrinka Štritof

• INVITED LECTURE

10.20 - 11.00

Assoc. Prof. **Bojan Blagojević**, DVM, MSc, PhD, Dipl. ECVPH

Department of Veterinary Medicine, Faculty of Agriculture, University of Novi Sad, Serbia

• THE EVOLUTION OF MEAT SAFETY ASSURANCE SYSTEM IN EUROPE

• ORAL PRESENTATIONS

11.00 - 11.15

Dea Kralj, Nevijo Zdolec:

**• ANTIBACTERIAL EFFECT OF NATURAL BIOPROTECTIVE AGENT ENTEROCIN
EF-101 IN MEAT**

11.15 - 11.30

Brigita Hengl, Dražen Knežević, Vedran Gradvol, Darija Vukić Lušić, Ana Gavrilović,
Jura Jug-Dujaković, Snježana Kazazić, Kristina Pikelj, Irena Vardić Smrzlić, Lorena Perić,
Jakov Žunić, Anamarija Kolda, Damir Kapetanović:

**• DIVERSITY OF *VIBRIO* SPP. IN FARMED AND WILD FISH OF BAY OF MALI STON,
PELJEŠAC (CROATIA)**

11.30 - 12.00 Coffee break

• INVITED LECTURE

12.00 - 12.40

Assoc. Prof. **Lorena Jemeršić**, DVM, PhD

Department for Virology, Croatian Veterinary Institute, Zagreb, Croatia

• THE PRESENCE OF HEPATITIS E VIRUS IN ANIMALS IN CROATIA

- ORAL PRESENTATIONS

12.40 - 12.55

Marin Bajek, Nataša Bauk, Mirela Josipović, Vesna Šeperić, Vanja Slavić Vrzić, Maja Bogdanić, Tatjana Vilbić-Čavlek, Irena Tabain:

- **NOROVIRUS OUTBREAKS IN 2019: RESULTS OF CROATIAN INSTITUTE OF PUBLIC HEALTH**

12.55 - 13.10

Maja Bogdanić, Vladimir Savić, Irena Tabain, Blaženka Hunjak, Ljiljana Milašinčić, Ljiljana Antolašić, Snježana Artl, Ljubo Barbić, Lorena Jemeršić, Jelena Prpić, Ana Klobučar, Andreja Jungić, Vladimir Stevanović, Stjepan Krčmar, Marko Vucelja, Marko Boljfetić, Krunoslav Capak, Tatjana Vilbić-Čavlek:

- **PREVALENCE OF TICK-BORNE ENCEPHALITIS, LYME-BORRELIOSIS AND HUMAN GRANULOCYTIC ANAPLASMOSIS IN PATIENTS WITH A HISTORY OF A TICK BITE, CROATIA (2017-2018)**

13.10 - 13.25

Dario Sabadi, Ljiljana Perić, Vladimir Savić, Mario Duvnjak, Danijel Šimašek, Irena Tabain, Dubravka Lišnjić, Ilija Rubil, Ljubo Barbić, Barbara Grubišić, Veronika Kralik, Vladimir Stevanović, Vedrana Radočaj, Tatjana Vilbić-Čavlek:

- **PREVALENCE AND MOLECULAR EPIDEMIOLOGY OF WEST NILE INFECTIONS IN OSIJEK-BARANJA COUNTY, 2012-2018**

13.25 - 13.40

Mirta Šalamun, Branko Kolarić, Irena Tabain, Ljiljana Antolašić, Ljiljana Milašinčić, Snježana Artl, Vladimir Savić, Ljubo Barbić, Vladimir Stevanović, Tatjana Vilbić-Čavlek:

- **SEROEPIDEMIOLOGY OF PHLEBOVIRUS INFECTIONS IN CROATIA, 2017-2018**

13.40 - 14.30 Lunch break and poster presentation I (Student's hall)

14.30 - 14.45

Alen Kovačević, Nina Krešić, Ivana Šimić, Ines Škoko, Dragan Brnić:

- **MOLECULAR CHARACTERISATION OF ROTAVIRUS A CIRCULATING AMONG DOMESTIC ANIMALS IN CROATIA**

14.45 - 15.00

Nina Krešić, Alen Kovačević, Ivana Šimić, Miljenko Bujanić, Dean Konjević, Dragan Brnić:

- **GENETIC DIVERSITY OF ROTAVIRUS A IN WILDLIFE IN CROATIA**

18.30 - 20.00 WELCOME RECEPTION

///// • THURSDAY OCTOBER 10TH 2019 - CLINICS DEPARTMENT LECTURE HALL /////

FARM ANIMALS - CLINICS DEPARTMENT LECTURE HALL

Chairs: Nino Maćešić, Nikica Prvanović Babić, Željko Gottstein

• INVITED LECTURES

10.20 - 10.55

Prof. Urban Besenfelder, DVM, PhD, Dipl. ECAR

Reproduction Centre Wieselburg, University of Veterinary Medicine, Vienna, Austria

• **THE OVIDUCT – A NEGLECTED ORGAN DUE TO RESTRICTED ACCESS**

10.55 - 11.30

Prof. Urban Besenfelder, DVM, PhD, Dipl. ECAR

Reproduction Centre Wieselburg, University of Veterinary Medicine, Vienna, Austria

• **COW FERTILITY: COMPARATIVE STUDIES ON EARLY EMBRYO DEVELOPMENT**

11.30 - 12.00 Coffee break

• ORAL PRESENTATIONS

12.00 - 12.15

Aneta Piplica, Ivan Vlahek, Ivana Sabolek, Marija Špehar, Sven Menčik:

• **INFLUENCE OF SEASON AND HERD SIZE ON AGE AT FIRST CALVING IN
BUSHA CATTLE BREED**

12.15 - 12.30

Bojan Toholj, Aleksandar Potkonjak, Vesna Miličević, Branislav Kureljušić,

Ozren Smolec, Srđan Krnjić:

• **ULCERATIVE MAMMARY DERMATITIS IN DAIRY COWS – OLD CAUSE
ON DIFFERENT LOCATION?**

12.30 - 12.45

Željko Gottstein, Liča Lozica, Maja Lukač, Estella Prukner-Radovčić,

Danijela Horvatek Tomić:

• **AUTOGENOUS BACTERIAL VACCINES IN POULTRY PRODUCTION
– FRIEND OR FOE**

12.45 - 13.00

Ana Marquiza M. Quilicot, Danijela Horvatek Tomić, Željko Gottstein, Maja Lukač,

Estella Prukner-Radovčić:

• **CHLAMYDIA GALLINACEA IN FREE-RANGE CHICKEN FLOCKS IN CROATIA**

13.00 - 13.15

Liča Lozica, Željko Gottstein:

- **INFLUENCE OF BIOSECURITY MEASURES AND MANAGEMENT PRACTICE ON GENETIC DIVERSITY OF *GALLIBACTERIUM ANATIS* ISOLATED ON POULTRY FARMS**

13.15 - 13.30

Liča Lozica, Danijela Horvatek Tomić, Jelena Repar, Željko Gottstein:

- **EFFECT OF AUTOGENOUS VACCINE ON PHYLOGENETIC RELATIONSHIP AND VIRULENCE PROFILES OF AVIAN PATHOGENIC *E. COLI* ISOLATED FROM BROILER BREEDER FLOCKS**

13.30 - 14.30 Lunch break and poster presentation I (Student's hall)

14.30 - 14.45

Ivan Vlahek, Anamaria Ekert Kabalin, Sven Menčik, Maja Maurić, Aneta Piplica, Velimir Sušić:

- **ANALYSIS OF *IGF1* GENE POLYMORPHISM AND DIFFERENCES IN LITTER SIZE AFTER FIRST PARITY IN ROMANOV SHEEP: PRELIMINARY RESULTS**

14.45 - 15.00

Ivona Žura Žaja, Petra Jurković, Suzana Milinković Tur, Ana Shek Vugrovečki, Mirela Pavić, Mario Ostović, Sven Menčik, Nina Poljičak Milas, Nino Mačešić, Igor DelVechio, Nikolino Žura, Marta Radin, Marinko Vilić:

- **EFFECTS OF GENDER AND GONADECTOMY ON SOME BIOCHEMICAL SERUM PARAMETERS IN SWEDISH LANDRACE PIGS**

18.30 - 20.00 WELCOME RECEPTION

///// • THURSDAY OCTOBER 10TH 2019 - PHYSICS DEPARTMENT LECTURE HALL /////

EXOTIC AND WILD ANIMALS - PHYSICS DEPARTMENT LECTURE HALL

Chairs: Maja Lukač, Ana Shek Vugrovečki, Maja Belić

• INVITED LECTURES

10.20 - 11.00

Dr. **Marja Kik**, DVM, PhD, Dipl. Vet Path RNVA, Dipl. ECZM (Herpetology)

*Department of Pathobiology, Division of Pathology, Faculty of Veterinary Medicine,
Utrecht University, the Netherlands*

• **THE USE OF CYTOLOGY IN AMPHIBIANS, BIRDS, MAMMALS AND
REPTILES AS A TOOL IN DIAGNOSTICS**

• ORAL PRESENTATIONS

11.00 - 11.15

Fran Barac, Danijela Horvatek Tomic, Ivan Cizelj, Maja Belić, Željko Gottstein, Maja Lukač:

• **ORAL AND CLOACAL BACTERIAL FLORA OF MARGINATED TORTOISES
(TESTUDO MARGINATA)**

11.15 - 11.30

Magdalena Kolenc, Kim Korpes, Maja Lukač, Lada Radin, Tomislav Gomerčić, Martina
Đuras:

• **FIRST AID PROTOCOLS FOR DOLPHINS AND SEA TURTLES IN ADRIATIC
SEA DESIGNED WITHIN BLUE PROJECT**

11.30 - 12.00 Coffee break

• INVITED LECTURE

12.00 - 12.40

Prof. Emer. **Đuro Huber**, DVM, MSc, PhD

Department of Biology, Faculty of Veterinary Medicine, University of Zagreb, Croatia

• **LARGE CARNIVORES IN CROATIA: 38 YEARS OF PROJECTS**

• ORAL PRESENTATIONS

12.40 - 12.55

Silvia Blašković, Lucija Hucika, Magda Sindičić, Ira Topličanec, Ivana Selanec,
Ivan Budinski, Vedran Slijepčević, Josip Tomić, Tomislav Rukavina, Franjo Špalj,
Tomislav Gomerčić:

• **HOW MANY LYNXES LIVE ON VELEBIT?**

12.55 - 13.10

Haidi Arbanasić, Duško Ćirović, Ida Svetličić, Veronika Lončar, Kate Šešelja, Željka Celinščak, Tihomir Florijančić, Ivica Bošković, Ana Galov:

- **DIVERSITY OF MAJOR HISTOCOMPATIBILITY COMPLEX CLASS II GENE IN GOLDEN JACKAL (*CANIS AUREUS*) FROM SERBIA**

13.10 - 13.25

Dean Konjević, Miljenko Bujanić, Marta Kiš, Nevijo Zdolec:

- **WILDLIFE AS A DISEASE RESERVOIR – OBSERVATIONS OF A WILDLIFE VETERINARIAN**

13.25 - 13.40

Kim Korpas, Hrvoje Capak, Damir Skok, Jadranko Boras, Ingeborg Bata, Tajana Trbojević Vukičević, Martina Đuras:

- **JUBA – EXTRAORDINARY CHIMPANZEE FROM ZAGREB ZOO: CRANIOMETRICAL AND RADIOLOGICAL CHARACTERISTICS**

13.30 - 14.30 Lunch break and poster presentation I (Student's hall)

///// • THURSDAY OCTOBER 10TH 2019 - PHYSICS DEPARTMENT LECTURE HALL /////

FREE COMMUNICATIONS - PHYSICS DEPARTMENT LECTURE HALL

Chairs: Hrvoje Valpotić, Lada Radin

• ORAL PRESENTATIONS

14.30 - 14.45

Petra Roškarić, Tomislav Mašek, Maja Maurić, Josip Barišić, Krešimir Severin,
Kristina Starčević:

• **LIPOGENESIS AND HEPATIC CD36 EXPRESSION IN RESPONSE TO
CAFETERIA AND HIGH-FRUCTOSE DIET**

14.45 - 15.00

Tihana Josipović, Lucija Ciglar, Maša Efendić, Hrvoje Capak:

• **MICROCHIP MIGRATION IN DOGS – IS THERE BREED PREDISPOSITION?**

15.00 - 15.15

Željana Klječanin Franić, Kristian Lewis, Juliette Alexandra Magoga, Dean Konjević:

• **FALSE FRIENDS IN VETERINARY TERMINOLOGY: IS INFECTION
ALWAYS INFECTION?**

15.15 - 15.30

Lada Radin, Evelyn Steinberg, Ingrid Preusche, Rudolf Dömötör, Jelka Zabavnik Piano,
Mira Mandoki, Christin Kleinsorgen:

• **OVERVIEW AND PRELIMINARY RESULTS OF SOFTVETS PROJECT**

18.30 - 20.00 WELCOME RECEPTION

///// • FRIDAY OCTOBER 11TH 2019 - MAIN LECTURE HALL /////

SMALL ANIMALS - MAIN LECTURE HALL

Chairs: Iva Šmit, Mirna Brkljačić, Marko Pećin

• INVITED LECTURE

09.00 - 09.40

Dr. Marko Pipan, DVM, Dipl. ACVECC

Animal Hospital Postojna, Postojna, Slovenia

• HEAD TRAUMA AND TRAUMATIC BRAIN INJURY

• ORAL PRESENTATIONS

09.40 - 09.55

Katarina Marjanović, Iva Bacan, Tugomir Karadjole, Nino Maćešić, Ivan Folnožić, Juraj Šavorić, Ivan Butković:

• ANAESTHESIA PROTOCOL FOR LAPAROSCOPIC OVARIECTOMY IN A BITCH DIAGNOSED WITH IMMUNE-MEDIATED MENINGOENCEPHALITIS

09.55 - 10.10

Ivana Filipčić, Ines Jović, Jelena Gotić, Iva Šmit, Filip Kajin, Vesna Matijatko, Ivana Kiš, Mirna Brkljačić, Marin Torti:

• RETROSPECTIVE STUDY OF PULMONARY HYPERTENSION IN DOGS EXAMINED AT THE CLINIC FOR INTERNAL DISEASES, FACULTY OF VETERINARY MEDICINE, ZAGREB (2016–2019)

10.10 - 10.25

Valerija Benko, Asier Galan Cousillas, Jurica Tršan, Vladimir Mrljak, Marin Torti:

• PROTEOMIC ANALYSIS OF PLEURAL EFFUSION AND ITS POTENTIAL IN CLINICAL DIAGNOSTICS OF CANINE PULMONARY ADENOCARCINOMA

10.25 - 10.40

Davorin Lukman:

• MANAGEMENT U LABORATORIJSKOJ DIJAGNOSTICI – *Laboklin*

10.40 - 11.00 Coffee break

• INVITED LECTURE

11.00 - 11.40

Assist. Prof. Ana Nemec, DVM, PhD, Dipl. AVDC, Dipl. EVDC,
Spec. in canine and feline medicine

Small Animal Clinic, Veterinary Faculty, University of Ljubljana, Slovenia

• **WAIT AND SEE APPROACH IN CASE OF DENTAL TRAUMA?**

• ORAL PRESENTATIONS

11.40 - 11.55

Filip Kajin, Marin Torti, Iva Šmit, Ines Jović, Martina Crnogaj, Jelena Gotić, Mirna Brkljačić, Vesna Matijatko, Ivana Kiš, Jurica Tršan, Ivana Filipčić, Zrinka Štritof:

• **BACTERIAL PATHOGENS AND ANTIMICROBIAL SUSCEPTIBILITY PATTERNS IN URINARY TRACT INFECTIONS IN DOGS**

11.55 - 12.10

Marina Prišlin, Fran Šimac, Blanka Beer Ljubić, Ivana Kiš, Jasna Aladrović:

• **EVALUATION OF URINALYSIS TEST STRIPS IN DETECTION OF PRESENCE OF BLOOD CELLS IN CANINE URINE**

12.10 - 12.25

Lea Lovrić, Snježana Lučinger, Vesna Matijatko, Ivana Kiš, Tatjana Živičnjak:

• **PREVALENCE OF DIROFILARIA SPP. IN RANDOMLY CHOSEN DOGS**

12.25 - 12.40

Daria Jurković, Vlatka-Antonija Csik, Branimir Rebselj, Ana Petak, Marija Stublić, Relja Beck:

• **FIRST REPORT OF *BABESIA GIBSONI* AND *BABESIA VULPES* IN SYMPTOMATIC DOGS FROM CROATIA: FROM CLINICS TO THERAPY**

12.40 - 12.55

Valentina Kunić, Vesna Mojčec Perko, Zrinka Štritof, Suzana Hađina, Josipa Habuš, Vladimir Stevanović, Krešimir Martinković, Luka Radmanić, Iva Zečević, Matko Perharić:

• **MOLECULAR DIAGNOSTICS AND PHYLOGENETIC ANALYSIS OF FELINE IMMUNODEFICIENCY VIRUS ENV GENE IN NATURALLY INFECTED CATS IN CROATIA**

13.00 - 14.00 Lunch break and poster presentation II (Student's hall)

• INVITED LECTURE

14.00 -14.40

Prof. Breda Jakovac Strajn, DVM, PhD

Institute of Food Safety, Feed and Environment, Veterinary Faculty, University of Ljubljana, Slovenia

• **BARF – SUPERFOOD AND/OR A ONE HEALTH CONCERN?**

- ORAL PRESENTATIONS

14.40 - 14.55

Diana Brozić, Tatjana Živičnjak, Lea Lovrić, Josipa Habuš, Suzana Hađina, Snježana Lučinger, Hrvoje Valpotić, Matko Perharić, Zrinka Štritof:

- **USE OF RAW MEAT-BASED DIETARY REGIMES (BARF) IN DOGS IN CROATIA**

14.55 - 15.10

Iva Zečević, Zrinka Štritof, Suzana Hađina, Vladimir Stevanović, Krešimir Martinković, Matko Perharić, Luka Radmanić, Josipa Habuš:

- **TRAPPED NEUTROPHIL SYNDROME – A CASE REPORT**

15.10 - 15.25

Iva Benvin, Ljiljana Pinter, Zrinka Štritof, Josipa Habuš, Vesna Mojčec Perko, Vladimir Stevanović, Matko Perharić, Ljubo Barbić, Vilim Starešina, Nenad Turk, Zoran Milas, Suzana Hađina:

- **OPTIMISATION OF INOCULUM SIZE OF *MALASSEZIA PACHYDERMATIS* AND ITS USE IN DISK DIFFUSION METHOD FOR ANTIFUNGAL SUSCEPTIBILITY TESTING**

15.25 - 15.40

Ena Oster, Sonja Vukelić, Mirna Abaffy Kirin, Mario Kreszinger, Marko Pećin:

- **ARTHRODESIS, IS IT A WAY TO GO? – A CASE SERIES**

15.40 - 15.55

Iva Raič, Nino Maćešić, Tugomir Karadjole, Goran Bačić, Nikica Prvanović Babić, Ivan Butković, Maša Efendić, Martina Lojkić:

- **FIRST INDUCED HETEROSPERMATIC LITTER IN CROATIA – A CASE REPORT**

15.55 - 16.10

Tena Propadalo, Martina Lojkić, Nikica Prvanović Babić, Jelena Jelen Orlić, Silvijo Vince, Ivan Folnožić, Ivan Butković, Iva Getz:

- **BREEDING SOUNDNESS EXAMINATION OF YOUNG MILITARY WORKING DOGS**

16.30 CLOSING CEREMONY AND STUDENTS AWARDS

///// • FRIDAY OCTOBER 11TH 2019 - CLINICS DEPARTMENT LECTURE HALL /////

HORSES - CLINICS DEPARTMENT LECTURE HALL

Chairs: Nika Brkljača Bottegaro, Jelena Gotić, Nikica Prvanović Babić

• INVITED LECTURES

09.00 - 09.40

Prof. **Renate Weller**, DVM, PhD, MScVetEd, FHEA, NTF, ECVSMR, ACVSMR, MRCVS, RCVS
Specialist in Diagnostic Imaging

Director of Veterinary Education, CVS (UK) Ltd, London, United Kingdom

• **THE HORSE: A MIRACLE OF BIOENGINEERING OR A REALLY STUPID DESIGN?**

09.40 - 10.20

Prof. **Renate Weller**, DVM, PhD, MScVetEd, FHEA, NTF, ECVSMR, ACVSMR, MRCVS, RCVS
Specialist in Diagnostic Imaging

Director of Veterinary Education, CVS (UK) Ltd, London, United Kingdom

• **HOW BIOMECHANICS AFFECTS PERFORMANCE AND RISK OF INJURY IN THE HORSE**

10.20 - 11.00 Coffee break

• ORAL PRESENTATIONS

11.00 - 11.15

Nina Čebulj-Kadunc, Robert Frangež, Jaka Žgajnar, Peter Kruljc:

• **PHYSIOLOGICAL RESPONSES OF LIPIZZAN HORSES TO GRADED EXERCISE TESTS OF VARIOUS INTENSITY**

11.15 - 11.30

Antea Rački, Ivan Vlahek, Nikica Prvanović Babić:

• **INFLUENCE OF REPRODUCTIVE STATUS, AGE AND PERSONALITY OF HORSES ON PLACEMENT AND RESULTS IN SHOWJUMPING COMPETITIONS**

11.30 - 11.45

Petra Špehar, Mato Čačić, Damir Jakšić, Siniša Horvat, Iva Getz, Goran Bačić, Tugomir Karadjole, Nino Maćešić, Martina Lojkić, Nikica Prvanović Babić:

• **INCIDENCE OF RETAINED FOETAL MEMBRANES IN LIPIZZAN BROODMARES AT LIPIK STATE STUD FARM FROM 2015 TO 2019**

11.45 - 12.00

Sara Lolić, Rok Planovšek:

**• EQUINE ODONTOCLASTIC TOOTH RESORPTION AND HYPERCEMENTOSIS
IN A 15-YEAR-OLD ICELANDIC HORSE – A CASE REPORT**

12.00 - 12.15

Jelena Gotić, Darko Grden, Klara Arifović, Valentina Plichta, Nika Brkljača Bottegaro:

**• MECHANICAL FRAGMENTATION URETHROLITH CALCULI REMOVAL IN
A MARE**

12.15 - 13.00

Mustad Workshop Grant Moon:

• READING THE HOOF CAPSULE

13.00 - 14.00 Lunch break and poster presentation II (Student's hall)

14.00 - 15.00

Mustad Workshop Thilo Phau:

• FUNDAMENTALS OF QUANTITATIVE LAMENESS ASSESSMENT IN THE HORSE

15.00 - 16.00

Mustad Workshop Grant Moon:

• SHOEING THE SPORT HORSE

16.00 - 16.30

Mustad Workshop QUESTIONS & ANSWERS

(Weller, Moon, Phau)

16.30 CLOSING CEREMONY AND STUDENTS AWARDS

///// • **FRIDAY OCTOBER 11TH 2019 - PHYSICS DEPARTMENT LECTURE HALL** /////

PHD DAY OF THE FACULTY OF VETERINARY MEDICINE - PHYSICS DEPARTMENT LECTURE HALL

PhD program: Veterinary Science

09.00 - 09.10

Assoc. Prof. Dean Konjević, Dipl. ECZM

• **INTRODUCTION TO A PHD DAY**

• INVITED LECTURE

09.10 - 09.50

Prof. **Peter David Eckersall** BSc, PhD, MBA FSB

University of Glasgow and University of Zagreb

• **MANNA THE MARIE-CURIE EUROPEAN JOINT DOCTORATE IN MOLECULAR ANIMAL NUTRITION, A TRANS EUROPE COLLABORATION BETWEEN UNIVERSITIES AND THE COMMERCIAL SECTOR**

• ORAL PRESENTATIONS

09.50 - 10.05

Doroteja Huber:

• **POSTMORTAL AND MOLECULAR RESEARCH OF BACTERIAL AND PROTOZOAL VECTOR-BORNE DISEASES OF CATS AND DOGS**

10.05 - 10.30 Coffee break

10.30 -10.45

Mirela Pavić:

• **INFLUENCE OF GENDER AND CASTRATION ON THE EXPRESSION AND DISTRIBUTION OF TRANSPORTERS INVOLVED IN TRANSEPITHELIAL GLUCOSE TRANSPORT IN PORCINE SMALL INTESTINE**

10.45 - 11.00

Matko Perharić:

- **MOLECULAR EPIZOOTIOLOGY AND VALIDATION OF FELINE IMMUNODEFICIENCY VIRUS DIAGNOSTICAL PROCEDURES IN CROATIA**

11.00 - 11.15

Miljenko Bujanić:

- **VARIABILITY OF THE GENES OF MAJOR HISTOCOMPATIBILITY COMPLEX IN RED DEER (CERVUS ELAPHUS) IN RELATION TO FASCILOIDES MAGNA INFECTION**

11.15 - 11.30

Nikola Rošić:

- **THE EFFECT OF HEAT STRESS ON ANTIOXIDATIVE STATUS AND MACROMINERAL METABOLISM IN DAIRY COWS DURING THE TRANSITION PERIOD**

11.30 - 11.45

Ivana Pipal:

- **CORRELATION BETWEEN ENERGY METABOLISM OF COWS IN THE EARLY PUERPERIUM AND CALVES IN THE NEONATAL PERIOD**

11.45 - 12.00 DISCUSSION

12.00 - 13.00 Lunch

///// • SATURDAY OCTOBER 12TH 2019 - MAIN LECTURE HALL /////

ONE HEALTH - MAIN LECTURE HALL

Moderators: Jelena Šuran, Lada Radin

10.00 - 10.30

Assoc. Prof. **Andrea Gudan Kurilj**, DVM, PhD, Dipl. ECVP

Department of Veterinary Pathology, Faculty of Veterinary Medicine, University of Zagreb, Croatia

• **"ONE HEALTH" APPROACH IN TUMOUR RESEARCH**

10.30 - 11.00

Assist. Prof. **Vladimir Savić**, DVM, PhD

Poultry Centre, Croatian Veterinary Institute, Zagreb, Croatia

• **INFLUENZA A VIRUSES: FROM BIRDS TO HUMANS**

11.00 - 11.30

Assoc. Prof. **Nevijo Zdolec**, DVM, PhD

*Department of Hygiene, Technology and Food Safety, Faculty of Veterinary Medicine,
University of Zagreb, Croatia*

• **THE ROLE OF VETERINARIANS IN FOOD SAFETY**

///// • THURSDAY OCTOBER 10TH 2019 - STUDENT'S HALL /////

POSTER PRESENTATION I - STUDENT'S HALL

Chairs: Ivona Žura Žaja, Lana Vranković

1. Lejla Velić, Toni Eterović, Benjamin Čengić, Dženo Hadžović, Sabina Šerić Haračić, Amina Hrković Porobija: **CHARACTERISTICS OF BRUCELLOSIS IN THE CANTON OF SARAJEVO**
2. Marta Kiš, Valerij Pažin, Snježana Kazazić, Emilija Cmrečak, Ivan Vičić, Nevijo Zdolec: **ANTIMICROBIAL RESISTANCE OF *YERSINIA ENTEROCOLITICA* ISOLATED FROM TONSILS OF PIGS PRODUCED ON FAMILY FARMS**
3. Andreja Prevendar Crnić, Emil Srebočan: **MERCURY IN PHEASANT (*PHASIANUS COLCHICUS*) ORGANS COLLECTED IN THE VICINITY OF THE NATURAL GAS TREATMENT PLANT IN NORTHERN CROATIA DURING THE LAST TEN YEAR**
4. Dražen Knežević, Brigita Hengl, Darija Vukić Lušić, Ana Gavrilović, Jura Jug-Dujaković, Snježana Kazazić, Kristina Pikelj, Irena Vardić Smrzlić, Lorena Perić, Jakov Žunić, Anamarija Kolda, Damir Kapetanović: **BACTERIAL CONTAMINATION OF BROWN TROUT (*SALMO TRUTTA*) AND COMMON CARP (*CYPRINUS CARPIO*) IN CROATIA**
5. Slavomír Marcinčák, Martin Bartkovský, Dana Marcinčáková, Boris Semjon, Beáta Koreneková, Peter Popelka, Ondrej Slaný, Tatiana Klempová: **EFFECT OF FEEDING *MORTIERELLA ALPINA* PREFERMENTED WHEAT BRAN ENRICHED WITH FATTY ACIDS ON QUALITY OF CHICKEN BREAST MEAT**
6. Boris Semjon, Dana Marcinčáková, Martin Bartkovský, Slavomír Marcinčák: **EFFECT OF FERMENTED FEED SUPPLEMENTATION ON EGG YOLK COLOUR IN LAYING HENS**
7. Tome Nestorovski, Zehra Hajrulai Musliu, Ana Angelovska, Risto Uzunov, Stefan Jovanov: **QUALITY CONTROL OF HONEY PRESENT ON THE MACEDONIAN MARKET**
8. Robert Dumančić, Ivan Vlahek, Katja Močibob, Bojan Toholj, Marija Lipar, Marko Pećin, Ozren Smolec: **PREVALENCE OF LAMENESS IN DAIRY COWS IN CROATIA**
9. Benjamin Čengić, Amel Ćutuk, Lejla Velić, Tarik Mutevelić, Nazif Varatanović, Toni Eterović: **CHALLENGES OF MANAGEMENT IN IMPROVEMENT OF REPRODUCTIVE PERFORMANCE IN DAIRY COWS**
10. Aleksandar Janevski, Iskra Cvetkovikj, Sanja Kiprijanovska, Sasho Dimovski, Dine Mitrov: **SUBCLINICAL MASTITIS IN SMALL DAIRY FARMS IN REPUBLIC OF NORTH MACEDONIA**
11. Darko Grden, Jayne Orr, Ines Prata, Angie Rupp: **HEART MURMUR IN A HEIFER – A CASE REPORT**
12. Lea Lovrić, Zrinka Štritof, Hrvoje Tomšić, Luka Radmanić, Suzana Hađina, Vesna Mojčec Perko, Matko Perharić, Zoran Milas, Josipa Habuš: ***MORAXELLA BOVOCULI* ISOLATED FROM CATTLE WITH INFECTIOUS BOVINE KERATOCONJUNCTIVITIS**
13. Ingo Ralph Albin Lobpreis, Ivona Žura Žaja, Branimira Špoljarić, Silvijo Vince, Ana Shek

Vugrovečki, Daniel Špoljarić, Nina Poljičak Milas, Suzana Milinković Tur, Luka Pajurin, Dina Jelenčić, Tomislav Mikuš, Maja Popović: **MORPHOMETRIC SIZE AND SHAPE PARAMETERS OF ERYTHROCYTES IN LIKA PRAMENKA SHEEP**

14. Sonja Vukelić, Mirta Vučković, Andrija Musulin, Darko Capak, Petar Kostešić, Valentina Plichta, Dražen Matičić, Dražen Vnuk: **COMPARISON OF TWO DIFFERENT SUTURING (CLOSING) TECHNIQUES AFTER PARTIAL LUNG LOBECTOMY ON OVINE MODEL – EX VIVO STUDY**
15. Ana Shek Vugrovečki, Ivona Žura Žaja, Jadranka Pejaković Hlede, Josip Miljković, Krešimir Malarić, Selim Pašić, Nada Dolenčić, Metka Vlahek, Željko Gottstein, Marinko Vilić: **BLOOD CELL COUNT IN BROILER BREEDERS AFTER EXPOSURE TO RADIOFREQUENCY ELECTROMAGNETIC RADIATION**
16. Dana Marcinčáková, Dagmar Mudroňová, Jana Koščová, Martin Bartkovský, Boris Semjon, Slavomír Marcinčák: **EFFECT OF DIETARY HUMIC SUBSTANCES ON BIOCHEMICAL BLOOD PARAMETERS, IMMUNE SYSTEM AND GUT MICROBIOTA OF CHICKEN**
17. Ivana Sabolek, Mario Ostović, Ivan Vlahek, Aneta Piplica, Kristina Matković, Željko Pavičić, Srebrenka Nejedli: **EFFECT OF LITTER DEPTH ON BREAST BLISTER OCCURRENCE AND MORPHOLOGICAL CHARACTERISTICS OF *M. PECTORALIS* MAJOR IN BROILERS**
18. Ozren Šiftar, Loredana Pincan, Marina Prišlin, Lana Vranković, Ivančica Delaš, Miljenko Bujanić, Dean Konjević, Zvonko Stojević, Jasna Aladrović: **COMPOSITION OF FATTY ACIDS IN LIVER, KIDNEY AND SUBCUTANEOUS ADIPOSE TISSUE IN EDIBLE DORMOUSE (*GLIS GLIS*)**
19. Miljenko Bujanić, Magda Sindičić, Franjo Martinković, Andrea Cafiero, Ivana Busch, Majda Požega, Ivan Pervan, Tena Radočaj, Dean Konjević: **FIRST MOLECULAR CHARACTERIZATION OF PARASITES *PARAHELIGMONINA GRACILIS* AND *HYMENOLEPIS SULCATA* IN FAT DORMOUSE (*GLIS GLIS*)**
20. Antea Klobučar, Dora Jović, Josip Kusak, Maja Belić: **HEMATOLOGICAL PARAMETERS OF LARGE CARNIVORES OBTAINED BY BLOOD SMEAR EXAMINATION**
21. Ira Topličanec, Tomislav Gomerčić, Josip Tomaić, Tomislav Rukavina, Ivana Selanec, Vedran Slijepčević, Franjo Špalj, Magda Sindičić: **MONITORING OF LARGE MAMMALS USING CAMERA TRAPS ON MOUNT VELEBIT**
22. Ana Ban, Tomislav Gomerčić, Ira Topličanec, Josip Tomaić, Ivana Selanec, Vedran Slijepčević, Magda Sindičić: **HOW MANY PHOTOS ARE OPTIMAL FOR MONITORING OF WILD LARGE MAMMALS WITH CAMERA TRAPS?**
23. Miljenko Bujanić, Nikolina Škvorc, Borjan Rokoš, Luka Manojlović, Zdravko Janicki, Dean Konjević: **ECONOMIC LOSSES CAUSED BY DISPOSAL OF SKIN AND EDIBLE INTERNAL ORGANS OF THE RED DEER - PRELIMINARY RESULTS**
24. Siniša Faraguna, Maja Belić, Blanka Beer Ljubić, Sandra Kunštek, Romana Turk: **SERUM BIOCHEMICAL AND HEMATOLOGICAL VALUES IN GRIFFON VULTURES (*GYPS FULVUS*) BEFORE AND AFTER REHABILITATION AT BELI VISITOR AND RESCUE CENTRE, ISLAND OF CRES, CROATIA**

25. Marina Tišljar, Krešimir Severin, Stjepan Brzica, Hrvoje Capak, Adela Krivohlavek, Lana Bakulić, Borka Šimpraga, Fani Krstulović, Lucija Šerić Jelaska, Marko Modrić, Vladimir Savić, Relja Beck, Petar Džaja, Vedran Lucić: **SOME INTERESTING FINDINGS IN WILDLIFE BIRDS IMPORTANT IN FORENSIC VETERINARY PATHOLOGY**
26. Petar Kostešić, Mirta Vučković, Ana Smajlović, Tara Kostanjšek, Filip Kajin, Jadranko Boras, Ingeborg Bata, Hrvoje Capak, Boris Pirkić: **MINIMALLY INVASIVE FRACTURE REPAIR OF COMMINUTED TIBIAL FRACTURE IN RING-TAILED LEMUR**
27. Mirta Vučković, Petar Kostešić, Sonja Vukelić, Niko Ivkić, Iva Šmit, Jadranko Boras, Ingeborg Bata, Hrvoje Capak, Dražen Matičić: **DENTAL TREATMENT IN THREE RED-NECKED WALLABIES (*MACROPUS RUFOGRISEUS*), A CASE SERIES**
28. Branka Artuković, Ivana Mihoković, Lidija Medven Zagradišnik, Marko Hohšteter, Ivan-Conrado Šoštarić-Zuckermann, Doroteja Huber, Željko Grabarević, Andrea Gudan Kurilj: **GRANULAR CELL TUMOUR IN THE CENTRAL NERVOUS SYSTEM OF FERRET (*MUSTELA PUTORIUS FURO*)**
29. Valentina Plichta, Marija Mamić, Zoran Vrbanac, Tajna Kovač, Hrvoje Capak, Nika Brkljača Bottegare, Dražen Vnuk, Boris Pirkić: **OSSEOUS METAPLASIA IN CILIARY BODY OF GUINEA PIG – A CASE REPORT**
30. Doroteja Huber, Andrea Gudan Kurilj, Ivan-Conrado Šoštarić-Zuckermann: **FIRST REPORTED CASE OF LEPORINE DYSAUTONOMIA IN CROATIA**
31. Morana Orban, Zvonko Stojević, Lana Vranković, Jasna Aladrović: **INFLUENCE OF FASTING AND REFEEDING ON GLUCOSE-6-PHOSPHATE DEHYDROGENASE, GLUTATHIONE AND LIPID PEROXIDE CONCENTRATION IN CHICKEN BLOOD**
32. Marta Šurbek, Ana Zupčić, Mateo Makšan, Mirna Čoklo, Vedran Micek, Ivan-Conrado Šoštarić-Zuckermann, Ivana Mihoković, Lea Lovrić, Marina Sinković, Anja Samardžić, Krešimir Pavelić, Marko Hohšteter: **EFFECTS OF ZEOLITES ON FORMATION OF PATHOLOGICAL RECTAL LESIONS IN RATS**
33. Ana Zupčić, Marta Šurbek, Mateo Makšan, Mirna Čoklo, Vedran Micek, Ivan-Conrado Šoštarić-Zuckermann, Ivana Mihoković, Lea Lovrić, Marina Sinković, Anja Samardžić, Krešimir Pavelić, Marko Hohšteter: **INFLUENCE OF ZEOLITE AND AZOXYMETHANE ON DEVELOPMENT OF PATHOLOGICAL LESIONS IN CAECUM OF RATS**
34. Petra Šoštarić, Josipa Vlaineć, Zlatko Tomljanović, Ivana Tlak Gajger: **IMMUNOMODULATION ROLE OF EM® PROBIOTIC IN NOSEMA SPP. SPORES NUMBER AND CONCENTRATIONS OF VITELLOGENIN IN HAEMOLYMPH OF HONEYBEE (*APIS MELLIFERA*)**
35. Luka Pajurin, Željka Cvrtila, Tomislav Mikuš, Lidija Kozačinski, Ksenija Vlahović, Daniel Špoljarić, Goran Kiš, Maja Jelena Čop, Ivana Bačić, Vedran Šegota, Maja Popović: **ANALYSIS OF TERPENES IN MATRICARIA PERFORATA AND THYMUS PULEGIOIDES ON GEA-COM LTD. PASTURES USING GC-MS**
36. Lucija Bastiančić, Snježana Kužir, Krešimir Drašner, Krešimir Matanović, Ivan Vlahek, Emil Gjurčević: **EARLY DETECTION OF *THELOHANELLUS NIKOLSKII* INFECTION BY ALCIAN BLUE-ALIZARIN RED S DOUBLE STAINING TECHNIQUE**

///// • FRIDAY OCTOBER 11TH 2019 - STUDENT'S HALL /////

POSTER PRESENTATION II - STUDENT'S HALL

Chairs: Ivona Žura Žaja, Lana Vranković

37. Tonka Ristevski, Ivan-Conrado Šoštarić-Zuckermann, Maja Maurić, Andrea Gudan Kurilj, Marko Hohšteter, Lidija Medven Zagradišnik, Ana Beck, Doroteja Huber: **FELINE PATHOLOGIC CHANGES DIAGNOSED USING CYTOLOGY**
38. Marija Lipar, Marko Hohšteter, Berislav Radišić, Ozren Smolec, Branka Artuković, Ivan-Conrado Šoštarić-Zuckermann, Gordana Gregurić Gračner, Jadranka Bubić-Špoljar, Andrija Musulin, Marko Pećin: **CLINICAL AND CYTOLOGICAL CHARACTERISTICS OF LINGUAL SQUAMOUS CELL CARCINOMA IN FIVE CATS**
39. Magdalena Kolenc, Dragan Petrović, Ljiljana Pinter, Zrinka Štritof, Josipa Habuš, Vladimir Stevanović, Matko Perharić, Suzana Hadina: **EVIDENCE OF OTITIS EXTERNA IN FREE-ROAMING CATS BASED ON OTOSCOPIC EXAMINATION AND CYTOLOGICAL EVALUATION**
40. Biserka Zidar, Nadica Maltar-Strmečki, Lana Vranković, Ljiljana Bedrica, Jasna Aladrović: **HEART RATE VARIABILITY DURING 'KITTY MAGIC' ANAESTHESIA**
41. Valerija Benko, Dora Ivšić Škoda, Gabrijela Jurkić, Nada Kučer, Ana Petak, Filip Kajin, Marin Torti: **REVIEW OF CLINICAL CASES OF BODY CAVITY EFFUSIONS (2015–2019) – OVERVIEW OF CLINICAL CYTOLOGY FINDINGS AND ASSOCIATED ETIOLOGIC FACTORS**
42. Dora Ivšić Škoda, Valerija Benko, Ljiljana Dukarić: **COMPARISON OF STANDARD CLOTTING TESTS IN DOGS BETWEEN QUICKVET AND ACL 7000 ANALYSERS**
43. Irena Artuković, Ljiljana Bedrica, Josipa Kuleš, Jelena Gotić, Renata Barić Rafaj: **HEAT SHOCK PROTEINS IN BABESIOSIS IN DOGS**
44. Karlo Tanhofer, Nika Brkljača Bottegaro, Andrija Musulin, Dražen Vnuk: **IMPACT OF ORCHIECTOMY ON CONTRALATERAL SIDE OCCURRENCE OF PERINEAL HERNIA IN DOGS – A RETROSPECTIVE STUDY**
45. Marija Mamić, Ozren Smolec, Valentina Plichta, Ana Smajlović, Sonja Vukelić, Dražen Vnuk: **SURGICAL MANAGEMENT OF PARAPHIMOSIS IN A DOG – A CASE REPORT**
46. Dunja Vlahović, Kristina Guliš, Hrvoje Capak, Ivana Mihoković, Lidija Medven Zagradišnik, Marko Hohšteter, Branka Artuković, Andrea Gudan Kurilj, Ivan-Conrado Šoštarić-Zuckermann, Doroteja Huber, Željko Grabarević: **SMALL INTESTINE HAEMANGIOSARCOMA IN A DOG – A CASE REPORT**
47. Sonja Vukelić, Mirta Vučković, Dražen Matičić, Hrvoje Capak, Nika Brkljača Bottegaro, Dražen Vnuk: **SURGICAL TREATMENT OF PERIODONTITIS IN DOGS – A RETROSPECTIVE STUDY**
48. Maša Efendić, Dražen Vnuk, Mirna Abaffy Kirin, Lidija Medven Zagradišnik, Marko Hohšteter, Hrvoje Capak, Nino Maćešić, Marija Lipar: **SHORT RECURRENCE TIME IN A DOG WITH ACANTHOMATOUS AMELOBLASTOMA – A CASE REPORT**

49. Lidija Medven Zagradišnik, Dunja Vlahović, Branka Artuković, Doroteja Huber, Andrea Gudan Kurilj, Ivan-Conrado Šoštarić-Zuckermann, Željko Grabarević, Ivana Mihoković, Iva Jelenić, Marko Hohšteter: **RETROSPECTIVE ANALYSIS OF PULMONARY HAEMORRHAGE IN NECROPSIED DOGS**
50. Doroteja Huber, Ivana Mihoković, Filip Kajin, Željko Grabarević, Branka Artuković, Andrea Gudan Kurilj, Ivan-Conrado Šoštarić-Zuckermann, Lidija Medven Zagradišnik, Marko Hohšteter: **INTERNAL HYDROCEPHALUS IN BULLDOG BREEDS**
51. Diana Brozić, Tomislav Bureš, Nika Brkljača Bottegaro, Iva Šmit, Jelena Šuran, Božo Radić, Zoran Vrbanc: **EFFECT OF TWO DIFFERENT FEEDING REGIMES (BARF VS. KIBBLE DIET) ON HAEMATOLOGICAL PARAMETERS IN SEARCH AND RESCUE DOGS DURING FIELDWORK**
52. Anita Kraljević, Tomislav Bureš, Matej Krištić, Branimir Škrln, Dino Stanin, Jana Gams, Deana Basar, Dinko Kolarić, Zoran Vrbanc: **ILIOPSOAS MUSCLE STRAIN IN AN AGILITY BORDER COLLIE – A CASE REPORT**
53. Zoran Vrbanc, Anita Kraljević, Tomislav Bureš, Nika Brkljača Bottegaro, Branimir Škrln, Dino Stanin, Ivana Kiš, Filip Kajin: **REHABILITATION OF ACUTE CANINE POLYRADICULONEURITIS IN TWO DOGS – A CASE REPORT**
54. Ivana Mihoković, Doroteja Huber, Željko Grabarević, Branka Artuković, Andrea Gudan Kurilj, Ivan-Conrado Šoštarić-Zuckermann, Lidija Medven Zagradišnik, Marko Hohšteter: **PRIMARY CANINE OVARIAN TUMORS IN CROATIA**
55. Maša Efendić, Nino Maćešić, Marko Samardžija, Tugomir Karadjole, Martina Lojkić, Valerija Benko, Zrinka Štritof, Vladimir Stevanović, Iva Raič, Hrvoje Capak: **CANINE FOETAL MUMMIFICATION AS A CONSEQUENCE OF PROLONGED GESTATION**
56. Dimitar Bozhinovski, Nikola Adamov, Martin Nikolovski, Dine Mitrov, Aleksandar Janevski, Vlatko Ilieski, Lazo Pendovski: **ANALYSIS OF CANINE PORTAL VEIN RAMIFICATION BASED ON CORRIOSION-SILICONE CASTS AND X-RAY SCANS**
57. Luka Špelić, Zoran Vrbanc, Jelena Gotić, Nika Brkljača Bottegaro: **CONCONI TEST APPLICABILITY IN ASSESSMENT OF HORSE FITNESS – A CASE REPORT**
58. Lazar Marković, Vladimir Gajdov, Tijana Lužajić Božinovski, Ivan Milošević, Milica Kovačević Filipović: **FETLOCK JOINT CARTILAGE LESIONS IN WORKING HORSES – A PILOT STUDY**
59. Tomislav Bureš, Zoran Vrbanc, Jelena Gotić, Hrvoje Capak, Branimir Škrln, Zrinka Štritof, Goran Csik, Nika Brkljača Bottegaro: **SEPTIC SYNOVITIS OF UNKNOWN ORIGIN IN AN ADULT HORSE – A CASE REPORT**
60. Robert Dumančić, Darko Grden, Hrvoje Capak, Branimir Škrln, Andrea Gudan Kurilj, Doroteja Huber, Dražen Vnuk, Ana Smajlović, Nika Brkljača Bottegaro: **PARANASAL SINUS CYST AND ETHMOID HAEMATOMA IN A HORSE – A CASE REPORT**
61. Klara Arifović, Dražen Vnuk, Darko Grden, Jelena Gotić, Ana Smajlović, Marko Hohšteter, Nika Brkljača Bottegaro: **EPIDERMAL INCLUSION CYST IN A MARE – A CASE REPORT**

62. Ana Smajlović, Jelena Gotić, Zrinka Štritof, Andrea Gudan Kurilj, Mirta Vučković, Nika Brkljača Bottegaro: **CLOSTRIDIAL MYOSITIS IN A MARE FOLLOWING EQUINE INFLUENZA AND TETANUS VACCINATION – A CASE REPORT**
63. Valentina Percan, Nika Brkljača Bottegaro, Ivan-Conrado Šoštarić-Zuckermann, Jelena Gotić: **PERITONITIS SUBSEQUENT TO SMALL INTESTINAL ULCERATION IN A HORSE – A CASE REPORT**
64. Ema Listeš, Eddy Listeš, Ljubo Barbić, Maja Maurić: **EXTERIOR MEASUREMENTS OF DALMATIAN BUŠAK HORSE TYPE POPULATION**

/// / KEYNOTE LECTURE / / / /

THE VETERINARY GRADUATE OF TODAY: FIT FOR PURPOSE? NEW TRENDS IN VETERINARY EDUCATION

Renate Weller

Director of Veterinary Education, CVS (UK) Ltd, London, United Kingdom

The clinician as a curator of knowledge

The way information is accessed has fundamentally changed with the invention of the World Wide Web. In terms of making information available to the sheer number of people, this has even superseded the revolutionary effect of the invention of the printed press by Gutenberg in medieval times.

In parallel, the role of the clinician has fundamentally changed. Clinicians are not the privileged keepers of information any more since the information is available to anybody with online access. Most clinicians will have experienced the "Dr Google" effect, where animal owners have already googled their animal's clinical symptoms and have already formed a (right or wrong) opinion. This shifts the role of the clinician to being the person with the skill to apply knowledge to a case, thus turning into a "curator" of knowledge. Sound application of knowledge on the basis of scientific evidence requires critical evaluation of information and this is a skill clinicians need to be given the opportunity to develop during their studies. They need to be able to systematically search and evaluate the vast and rapidly increasing volume of information available in a timely manner and in effect filter the available information and make a sound judgement on the validity of the information.

Shift from a teacher-centred to a learner-centred approach

The role of the teacher needs to shift accordingly, moving away from the teacher being the "fountain of all knowledge" imparting their knowledge in a one-way direction to adopting a "learner-centred" approach that allows the student to develop critical, analytical thinking. This requires the student to work independently, which can be achieved by a directed learning approach, where the student is given a problem and asked to find a solution working alone or in peer teams.

Blended learning

The rapid development of information technology has not only brought about a change in the availability of knowledge, but it also has changed people's attitudes and mindsets. Much has been published about the Millennials, Generation X, Z or iGen. One characteristic they share is that communication channels are digital and the length of communication pieces has decreased; this is, for example, demonstrated by the generation shift from e-mail to Facebook to WhatsApp.

The methods used for information access and communication in everyday life have to be reflected in the channels used for learning. Veterinary medicine includes knowledge, skills and attributes, and a blended learning approach employing both face-to-face teaching as well as mobile learning through digital channels is recommended. For example, "framing" a face-to-

face session by asking students to go through online learning material (e.g. adopting a “flipped classroom approach”) to prepare before a session and then testing how the learning outcomes have been achieved online after the sessions has shown to be an effective approach.

“Soft skills”

The veterinary profession in many countries faces challenges with recruitment and retention for a variety of reasons. Amongst others, these include a lack of ability to cope with the demands of the job and many veterinary schools now include opportunities for their students to develop “soft skills”, such as resilience, leadership of self, stress management, time management and also communication skills as a key factor contributing to a clinician’s success. For practical and ethical reasons, many of those generic skills cannot be practiced on actual clinical cases and many universities “artificially” create learning opportunities for students, e.g. by employing actors. Some universities also consider these attributes and skills during their student selection process.

Challenges to universities

While some aspects of the role of a veterinarian have been unchanged and are unlikely to change (e.g. the ability to palpate), many aspects change constantly, requiring continuous adjustment of the learning opportunities students are offered. This requires the identification – or ideally the prediction – of changes and hence constant liaison with the “market” in the first place and then the consequent adaptations of teaching. University structure combined with the mindset of many university employees is often not conducive to a timely change and proves challenging to the more progressive members of the profession.

Many curricula would benefit from “decluttering”; for any new piece of teaching, one should be taken out. This is often challenging for subject experts and they should be encouraged to focus on concepts rather than detail.

Teachers are looked upon by students as role models and there is a debate whether university-based topic specialists provide the right role model and right level of teaching since the majority of veterinary graduates will work as general practitioners. Many vet schools now address this problem by including primary care practitioners in their teaching staff.

No end in sight: fundamental change in role of the clinician ahead?

It has been suggested in human medicine that with the further development of information technology many of the tasks currently integral to the clinician’s role will be taken over by computers. For example, artificial intelligence (AI) systems have already surpassed the human mind in certain diagnostic processes and many medical curricula now include modules on digital medicine. What AI systems cannot provide is the empathy and the human interaction offered by the human doctor though.

It has been suggested by eminent medical educators that the role of the medic as we know it today will be fundamentally changed in the near future with a part of the role taken over by the computer scientist and the other part by the empathic nurse.

/// // INVITED LECTURES // //

THE EVOLUTION OF MEAT SAFETY ASSURANCE SYSTEM IN EUROPE

Bojan Blagojević

Department of Veterinary Medicine, Faculty of Agriculture, University of Novi Sad, Serbia

The significance of the harvest phase of the meat chain is mirrored in the fact that both the load of meat safety hazards and, consequentially, control potential are high at abattoirs. Therefore, the term "meat safety assurance" has traditionally been related to dressed carcasses and it was given the attention as early as mid-nineteenth century. Zoonotic diseases such as tuberculosis and cysticercosis were relatively prevalent in Europe at that time, while meat inspection system, now being called traditional, was developed to tackle them. Although it provided a valuable contribution to improvements in public and animal health at the time, the performance of the traditional meat inspection system has now become limited. This is mainly due to the traditional system's inability to deal with biological and chemical hazards such as *Salmonella*, *Campylobacter*, *Yersinia enterocolitica*, verocytotoxigenic *Escherichia coli*, *Toxoplasma gondii*, antimicrobial resistance gene-carrying bacteria, residues of veterinary drugs, mycotoxins and dioxins that emerged during the twentieth century and today pose the highest meat-borne risk for consumers. To control the group of hazards that are invisible to meat inspection, measures evolved and became end-product laboratory analyses-based. However, laboratory testing also suffers from many drawbacks, including delayed results, relatedness only to the hazard examined for, expensiveness and limited tests' sensitivities and specificities, the main being its reactive nature. The second half of the 20th century introduced prerequisite programmes (Good Manufacturing Practice and Good Hygienic Practice) and Hazard Analysis and Critical Control Points to act proactively in safe food production. These procedures are nowadays the cornerstones of carcass meat safety through abattoir process hygiene mainly aiming at preventing/reducing meat contamination with the faecal material as the major source of important meat safety hazards.

To overcome the known deficiencies of the existing carcass meat safety systems, the possibility of combining meat inspection with abattoir process hygiene-based controls into a coherent whole has been elaborated for decades. The idea of Longitudinally Integrated Safety Assurance (LISA) originates from the 1930s, when it was concluded that taking preventive measures makes more sense than just examining samples of the final product. Over the last decades, the attention to the LISA concept has been brought again. In 2002, the European Union General Food Law introduced an integrative farm-to-fork approach to food safety and application of the principles of risk analysis. Since then, significant actions have been initiated in the European Union to review and modernise the traditional meat inspection, moving it towards a more risk-based direction. Around 2010, the European Commission asked the European Food Safety Authority (EFSA) for a scientific input to support risk and food chain approach to meat inspection. As a result, EFSA prioritised biological and chemical public health hazards and recommended the new system of "fit for purpose" meat inspection within the whole meat safety assurance. EFSA's scientific opinions published in the period 2011-2013 pose a sound basis of a modern, flexible and dynamic risk-based meat safety system. The proposed system is tailored primarily in respect of prioritised hazards and aims at combining a range of preventive and control measures applied both at farms and abattoirs, longitudinally integrated. The elements and control strategies of the

new carcass meat safety assurance system include risk categorisation of farms and abattoirs, meat inspection *per se*, food safety management systems assuring abattoir process hygiene, traceability of animals and meat, and analysis of the food chain information.

The implementation of the European meat safety assurance system into practice has recently started as a direct result of the changes of relevant legislation. Many challenges are already experienced and it is expected that further implementation will be stepwise and followed by a thorough development, *ad hoc* adjustments and fine-tuning, as well as by continuous practical feasibility tests. Due to the system's complexity and multitasking, defining different roles and responsibilities is the next important step. Future changes of the legislation are expected and several practical challenges are already anticipated. Also, numerous knowledge gaps are identified and further research needs to address them. Finally, strengthening the links between science, policy makers and the meat industry is a precondition for a full implementation of the new meat safety assurance system.

THE PRESENCE OF HEPATITIS E VIRUS IN ANIMALS IN CROATIA

Lorena Jemeršić¹, Jelena Prpić¹, Tomislav Keros¹

¹Department for Virology, Croatian Veterinary Institute, Zagreb, Croatia

Hepatitis E is an enterically transmitted, mostly self-limiting and waterborne viral infection in humans. The significance of the disease as a public health problem is rising since extra-hepatic manifestations and cases of chronic infections in immunocompromised patients have been reported.

Hepatitis E virus (HEV) is classified in the *Hepeviridae* family consisting of two genera, *Orthohepevirus* (*A*, *B*, *C* and *D*) and *Piscihepevirus*. Certain members of *Orthohepevirus A* species, namely HEV-1 and HEV-2 genotypes, are human-specific; whereas HEV-3 and HEV-4 show a zoonotic potential. Even though novel genotypes of HEV and their hosts are consecutively reported, only swine are still considered as the true reservoirs of the virus.

Since 2009, the presence of HEV RNA has been investigated in domestic and wild animals in Croatia. However, positive findings were recorded only in swine and wild boars, showing a viral prevalence of 15.2% and 11.5%, and a high overall seroprevalence of 32.9% and 31.1%, respectively. Some serologically positive wild boars were found to be HEV RNA positive, indicating a chronic infection and possible prolonged virus spread into the environment.

According to the sequence analysis, all strains derived from swine and wild boars have shown to be genetically highly related members of *Orthohepevirus A*, HEV-3 genotype. The genotyping results confirm a grouping of sequences into two general subgroups (3abchij and 3efg) that consist of three smaller subgroups. Two of the subgroups were detected in both animal species throughout the entire investigated period (2009–2017), showing to be endemic, whereas members of the third subgroup appear sporadically. The strains are genetically related to strains found in humans from Croatia and Europe and/or swine from other European countries, indicating that members of the *Suidae* family in Croatia can potentially be considered as risk factors and that trade of live animals or wild boar movement increases the risk of HEV spread.

THE OVIDUCT – A NEGLECTED ORGAN DUE TO RESTRICTED ACCESS

Urban Besenfelder

Reproduction Centre Wieselburg, University of Veterinary Medicine, Vienna, Austria

It is well accepted that semen collection, semen processing and AI currently is the most efficient applied reproductive technique in the bovine species. Following sporadic reports, in the 1970s multiple ovulation and embryo transfer (MOET) was established and practiced in the cattle industry. A couple of years later it was shown that the oviduct can be bypassed and embryos can be produced in the laboratory using an in vitro production system consisting of ovum pick-up, in vitro maturation, fertilisation and in vitro culture. Embryo collection for embryo transfer is routinely accomplished in the late morula stage or blastocyst stage. However, the application of MOET does not necessarily end up in the desired number of embryos. A high proportion of donor animals does not adequately respond to the synchronisation protocol and hormone application. Consequently, the in vitro route promises extra numbers of embryos available for science and breeding purposes. In this context, the year 2017 has been a milestone since it was the first time that the International Embryo Technology Society (IETS) has recorded more embryos produced in vitro than in vivo (Viana J. 2018. 2017 Statistics of embryo production and transfer in domestic farm animals. Embryo Technology Newsletter of the International Embryo Technology Society. 36, 8–25). However, despite increasing available numbers of in vitro embryos, the quality of these embryos lags behind their in vivo counterparts. This conflict, a high embryo yield but a low embryo quality, inevitably directs scientific focus towards the oviduct on both embryo activities and oviduct performance and dynamics.

In order to access the oviduct, we first started our work with rabbits. We replaced the surgical flank incision by midventral laparoscopy. The animals were anaesthetised and fixed in the head-down position. This position allowed the introduction of the laparoscope about 1 cm caudal the umbilical region and the adspsection of uterine horns, oviducts and ovaries. Additionally, a vein catheter was used for the insertion of a transfer system (1 mL syringe – glass capillary) close to the oviduct. The in situ position of the oviduct allowed the introduction of the glass capillary via the infundibulum into the ampulla without the help of forceps. The embryos were transferred in 1–2 μ L medium. In the following steps, laparoscopy in small ruminants and in pigs has been done under general anaesthesia. These animals were fixed in the dorsal recumbent position. The instrumental equipment consisted of the laparoscope, forceps and a metal cannula, through which the transfer system could be inserted.

Despite a well-defined instrumental laparoscopic protocol for embryo transfer, the best results have been obtained after routine application, i.e. over a couple of years we could demonstrate the beneficial impact of this technique for animal breeding as well as for scientific purposes. In rabbits and pigs there was a significant increase in pregnancy rates and the number of implantations according to the number of transferred embryos increased. Moreover, we also use this technique for embryo collection after having superovulated these animals.

For the establishment of the endoscopic access to the bovine oviduct, the first extensive efforts have been directed towards rectal palpation of female cows vs. simultaneous studying of the reproductive tract of slaughtered cows. Being aware of anatomical features of the bovine reproductive tract, the main attention was paid to all structures finally representing the in situ situation, such as

excavations, ligaments, blood vessels, kidney, urinary bladder, rumen etc. Once performing rectal manipulation either using the left or the right hand, it soon becomes clear that managing reproductive organs in front of the endoscope including a 3-dimensional presentation can be challenging, e.g. manipulations lead to visual impairment and/or rotation of the organs may prove difficult. The endoscopic equipment consisted of an outer tube and a bi-tubular inlay that covers the endoscope plus either the transfer or flushing system. A curved fire-polished glass capillary connected to a perfusor tube and a 1-mL syringe served as a transfer system.

Meanwhile, these techniques were applied for many scientific, biomedical and breeding purposes. Besides the increasing demands of delivering and transferring embryos from and to animals of different species for these purposes, changing from laparotomy to laparoscopy/endoscopy had a significant beneficial effect on the reduction of stress for the animals as well.

COW FERTILITY: COMPARATIVE STUDIES ON EARLY EMBRYO DEVELOPMENT

Urban Besenfelder

Reproduction Centre Wieselburg, University of Veterinary Medicine, Vienna, Austria

Although the history of the oviduct dates back a long time, its contribution to early embryo development is still a secret event. Andreas Vesalius (1514–1564) suggested the oviduct as a pendant for the male ductus deferens. Gabriëlis Fallopius (1523–1562) delivered the first and a more accurate description of the oviduct structure. And Reinier De Graaf (1641–1673), whose name has been associated with the founder of modern reproductive biology, provided the first coherent understanding of the reproductive tract, including the oviduct (reviewed by Ankum WM, Houtzager HL, Bleker OP, Human Reproduction Update 1996, 2(4) 365–369). To date, there is much information available regarding the anatomical and histological structure of the oviduct. Moreover, many scientific teams have revealed the global composition of the oviduct fluid, such as protein variety, phospholipid profiles, carbohydrates, ions, pH, viscosity, cytokines, growth factors etc. through the oestrous cycle. However, not much is known on an embryo stage dependent manner, i.e. there is a lack of knowledge regarding tubal key factors necessary for guaranteeing embryo development for both in vivo and in vitro development.

Based upon these demands, it has become obvious that there is a great impact of directly accessing the bovine oviduct. Since abdominal surgery is an invasive and time-consuming intervention, all the expertise gained through working with rabbits, small ruminants and pigs has been focused on the utilisation of the bovine Fallopian tube.

The first experiments were done in heifers to transfer in vitro-derived bovine embryos. Denuded and cleaved embryos were filled into the tip of the glass capillary just before preparing the recipient animals. The outer tube including a blunt trocar was positioned middorsally, close to the fornix of the vagina. The blunt trocar was exchanged with a sharp trocar, which served for the introduction of the tube through the vaginal wall into the abdominal cavity. Finally, the trocar was replaced by the bi-tubular inlay bearing the endoscope and the transfer system. Both ovaries were checked for the presence of a synchronous corpus luteum (CL). The transfers were done ipsilaterally to the CL. Pregnancies and the birth of calves confirmed a successful first endoscopic access to the oviduct. In a further step, embryos of different stages were flushed from superovulated donor animals. After having shown that flushing of the oviduct also ended up in a successful recovery of embryos at all tubal stages, we combined these two steps and performed in vivo culture of in vitro-derived bovine embryos. For this purpose, slaughterhouse ovaries were punctured and cumulus-oocyte complexes collected, in vitro-matured and -fertilised. Presumptive zygotes and cleaved stages were transferred into the oviduct and re-collected on day 7 by flushing oviducts and uterine horns. This first action impressively showed that in vivo culture of in vitro-derived bovine embryos exerts a beneficial impact on embryo quality, such as cryopreservability, lipid metabolism and gene expression profiles. In a large-scale study comparing in vivo vs. in vitro, in vitro-derived embryos at different stages were transferred to the oviduct and flushed at the blastocyst stage and, *vice versa*, following superovulation embryos at different stages were flushed and cultured in vitro up to the

blastocyst stage. In a holistic gene expression analysis of blastocysts, the most sensitive in vitro phases could be revealed. The number of differentially expressed genes provided evidence that fertilisation, embryo genome activation in the 8-cell stage and compaction during the morula stage are the most sensitive in vitro transitional phases.

Moreover, a study was performed in which donor animals had been superovulated embryos were either flushed on day 7 or on day 2 transferred to single ovulated temporary recipients and re-collected on day 7. Surprisingly, embryos cultured in single-ovulated recipients showed a higher ratio of blastocysts/morulae compared to embryos entirely kept in superovulated animals until day 7. The expression analysis depicted that embryos developed in vivo but under abnormal endocrine environment showed elevated expression activities of genes, such as oxidative phosphorylation pathway, some metabolic, translational and transcriptional processes, including genes involved in response to stress. In addition, in vivo culture of embryos in heifers, dairy milking cows and dried-off cows clearly illustrated the effects of blood progesterone concentration including metabolic disorders of high-milk-yielding cows on early embryogenesis. It seems to be obvious that dairy milking cows are not capable of supporting early embryo development. Many consecutive experiments confirmed negative effects of environmental deviations on embryo development, providing important indications for fertility problems.

In order to bridge in vivo embryo development and in vitro production methods, recent studies have shown that prior to ovulation it is possible to transfer a minimal amount of semen into the ampulla for a successful fertilisation. In another study, oviducts were flushed either with 0.5 mL medium or beads having C4 alkyl groups were transferred, kept for 1 hour and re-collected. It is believed that new methods will allow obtaining more detailed information in connection with high-throughput technologies on the molecular, metabolic and proteome level, and creating new designs could make a substantial contribution to our understanding of fertility and to solving fertility problems.

THE USE OF CYTOLOGY IN AMPHIBIANS, BIRDS, MAMMALS AND REPTILES AS A TOOL IN DIAGNOSTICS

Marja JL Kik

*Department of Pathobiology, Division of Pathology, Faculty of Veterinary Medicine,
Utrecht University, the Netherlands*

Cytology, conducted either on wet smears or stained samples of different organs, is a fast and inexpensive tool in diagnostics in both clinical practice and pathology. It is easily performed; however, one needs practice in the interpretation of the results. Very often an aetiological agent can be detected. Moreover, some aetiological agents are readily detected in cytology, whereas histological detection is much more difficult. Yet, it is an additional technique and does not replace histological examination.

The sampling technique is crucial for success. The sample should be representative and of a good, thin quality. We want to study the organ cells, and not the erythrocytes. The smear must be correctly evaluated.

In this lecture the preparation of slides, choosing the right samples, staining methods and microscopic evaluation will be discussed. Examples of normal and abnormal tissues with aetiological agents will be shown. Other topics include: bacterial chlamydial infections in birds; mycotic infections in birds and amphibians; protozoa in wet smears and organ cytology in reptiles, mammals and birds; parasitic infections in birds, fish, amphibians and reptiles. Furthermore, some examples of tumour diagnostics will be shown.

LARGE CARNIVORES IN CROATIA: 38 YEARS OF PROJECTS

Đuro Huber

Department of Biology, Faculty of Veterinary Medicine, University of Zagreb, Croatia

It was on 1 November 1981 that the first bear in Croatia got a radio-collar in the Plitvice Lakes National Park within the project logistically supported by the Park and financially by the state project of "Samoupravna interesna zajednica za znanost (SIŽ-IV)" (subsequently the Ministry of Science). Our first international project was funded by the National Geographic Society from 1986 to 1989.

The Croatian Large Carnivore Team, located at the Biology Department of the Faculty of Veterinary Medicine in Zagreb, was established in 1981 and has been active since.

The break-through method in our study of large carnivores was the use of radio-telemetry, which was first used in the USA in the 1970s, and in Europe before us only in Italy in 1979. The method required live-capturing and chemical immobilisation of studied animals. Having living animals on hand opened access to numerous additional data sources on their morphology, physiology and pathology. Telemetry tracking itself made it possible to follow the movement of marked individuals, learn about their home ranges, activity rhythm, feeding habits, reproduction, growth, mortality, habitat requirements and about their ecology altogether. Recently, genetic studies have become increasingly important. Since 1998 the team has also intensively worked on the securing and monitoring of the permeability of highways. Additionally, we carefully analysed each animal that died in hunting, traffic accidents or from other causes. So far, we radio-tracked 62 different brown bears, 36 wolves and 16 lynx. The scientific results were published in 187 journal papers and books.

Funding of all the work was secured through obtaining numerous projects. Over the past 38 years, there were 25 different projects (some lasting for up to ten years); 17 of those were international, received from the National Geographic Society, U.S.–Croatian science and technology program; International Association for Bear Research and Management; ALIS; LIFE, LIFE III, LIFE+, Euronatur, Bernd Thies Foundation, BIBI MATRA, INTERREG IIIA, INTERREG SLO–HR, FP7, SERA–ERA–NET, NINA Norway and POLONEZ.

All the work brought about numerous results on various aspects of large carnivore population ecology status and conservation needs. Prior to this work there were no scientifically based data available on large carnivores in Croatia. The knowledge based on this research made it possible to identify the current and future threats for large carnivores in Croatia, and to prepare and implement the management plans for each of the three species. On the international level, Croatia became a good example of solid knowledge of large carnivores and an adequate care for these species.

WAIT-AND-SEE APPROACH IN CASE OF DENTAL TRAUMA?**Ana Nemec***Small Animal Clinic, Veterinary Faculty, University of Ljubljana, Slovenia***Portals of root canal infection**

Microorganisms can reach dental pulp via several routes – in animals, dental trauma is the most common and usually presents as complicated crown fracture of the strategic teeth. When the pulp is exposed as a result of a trauma, bacterial penetration is inevitable (primary endodontic infection). Although a defensive reaction occurs in the body (in the dental pulp and later in the periapical tissues), this cannot eliminate microbes that are well-entrenched in the root canal as protected biofilms. Endodontic disease seems to progress similarly in dogs and cats. Initially, pulpitis (inflammation of the dental pulp) develops, which is limited to the coronal portion of the tooth (below the fracture) in the first week post dental pulp exposure in cats with immature permanent teeth. The infection subsequently spreads to involve the whole dental pulp, with pulp necrosis occurring in 54.5% of the cats within 90 days post dental pulp exposure, while in dogs it is usually observed within 65 days following dental pulp exposure. The inflammation also involves periapical tissues, resulting in apical periodontitis. This can be observed in cats within 30 days and in dogs 20 days post dental pulp exposure. Internal inflammatory resorption can be seen in canine teeth with open apices of cats within 30 days post dental pulp exposure.

In dogs, discoloured teeth with intact crowns were found to be non-vital in the majority of cases, although not always showing radiographic signs of endodontic disease. In humans, microbes have also been isolated from teeth with necrotic dental pulp and intact crowns – endodontic infections in such teeth are believed to be preceded by dental pulp necrosis, and bacteria can originate from infected periodontal pockets (controversial), microcracks in dental hard tissues, or exposed dentinal tubules. Dentinal tubules are 1–4 micrometres in diameter, while most bacteria are smaller than 1 micrometre. Bacteria can enter the dental pulp via blood or lymph (anachoresis), although this is believed not to contribute to the disease significantly in humans, and there are no reports for cats and dogs.

Composition of microbiota in primary endodontic infections

Given the abundance of oral microbiota, which can infect the dental pulp when the integrity of dental hard tissues is lost, it is remarkable that the primary endodontic infections consist of a small number of species that are consistently isolated from such root canals. The endodontic environment provides a selective habitat for the establishment of mixed, predominantly anaerobic, mixed Gram+ and Gram- microbiota that form a biofilm. Although sampling (especially strict anaerobic) bacteria from infected root canals is extremely difficult, new technologies have made this simpler. Molecular methods are much more sensitive, but data must be interpreted carefully, since dead bacteria as well as remnants of early colonising bacteria can be detected. The number of cultured microorganisms yielded from fractured teeth (experimentally or naturally) in dogs and cheetahs ranges from 0 to 12 isolates per infected root

canal, and the number of total isolates is around 60. The species of root canal microbiota are similar to those in humans (Proteobacteria, Bacteroidetes and Actinobacteria, among others) with no specific endodontic pathogen identified. Individual species in the root canal are usually of low virulence, but collectively they are pathogenic/virulent due to a combination of factors – synergistical interactions with two other microorganisms, release of endotoxins and exotoxins, synthesis of enzymes that damage host tissues, the ability to interfere with host response and the ability to evoke damage to host cells by stimulating the immune system. In humans, there are also significant differences in the predominant bacterial composition between asymptomatic and symptomatic cases of endodontic infections, but this has not yet been established for animals. Furthermore, in humans, endodontic microbiota composition has been linked to the distinct forms of endodontic disease (e.g. absence/presence of a draining tract, chronicity of apical periodontitis, radiographic periapical changes). A geographic influence in the composition of the root canal microbiota is also suspected in humans. None of these has yet been proven for animals. In general, primary endodontic infections are considered polymicrobial, involving selected opportunistic pathogens.

Diagnosis and treatment of endodontic disease

Although dental fractures and endodontic disease are considered painful, oral/dental pain of animals is rarely noted. Most of the cases are usually diagnosed accidentally, or when overt clinical signs develop. A detailed oral examination and dental radiographs are needed to evaluate the nature of the fracture (e.g. complicated vs. uncomplicated; crown vs. crown-root vs. root fracture) and the extent and severity of endodontic disease in order to plan treatment accordingly. CBCT and CT have proven superior in diagnosing endodontic disease and should be considered, especially in cases where endodontic disease is high on the differential diagnoses list, but dental radiographs fail to reveal any. A fractured and/or endodontically compromised tooth (as confirmed clinically and/or radiographically) requires treatment to remove the infection and alleviate pain. It is unacceptable to monitor teeth with clear signs of endodontic disease. Endodontic disease can be treated either by removal of the tooth (extraction) or by removal of the microbial ecosystem associated with the disease process (endodontic therapy). The description of the procedures is beyond the scope of this Proceedings. Apical periodontitis resolves once the cause of it (infection within the root canal) is removed. However, radiographic monitoring in cases of endodontic therapy is required to ensure healing. In humans, persistent apical periodontitis (occurring after a root canal treatment) presents a more complex aetiological and therapeutic situation than primary apical periodontitis, and in humans it occurs in most cases as a monoinfection. Failure of a periradicular lesion to heal after an endodontic treatment is often related to microbes remaining in the root canal system that have access to periradicular tissues. In most cases, this is due to an inadequate aseptic control of the root canal system during and after the treatment. In addition, factors located beyond the root canal system, within the inflamed periapical tissue, can interfere with post-treatment healing (e.g. extraradicular infection, foreign bodies in the periapex, development of cysts or systemic underlying conditions that prevent healing). The conservative approach with regular radiographic re-checks may be considered in cases of dental trauma without pulp exposure and no radiographic signs of endodontic disease. However, due to the need of anaesthesia for radiographic re-checks, limitations of dental radiography and our inability to properly assess dental pain in animals, it is debatable if the conservative approach is always beneficial to the animals.

HEAD TRAUMA AND TRAUMATIC BRAIN INJURY

Marko Pipan

Animal Hospital Postojna, Postojna, Slovenia

Trauma patients are commonly seen in veterinary medicine, with vehicular trauma, vicious animal interactions, falls from heights, gunshot wounds and malicious human activity being the most common causes. Considering a wide range of potential injuries, all trauma patients require a systematic evaluation with individualised diagnostic and treatment procedures. A head trauma with a traumatic brain injury (TBI) is associated with increased morbidity and mortality; these patients represent a vulnerable group of trauma patients who are at an increased risk of worse outcome and death and who will require greater short- and long-term medical resources. Therefore, every trauma patient with signs of a head injury, abnormal mentation or inappropriate ambulation must be evaluated for TBI. Namely, injury to the brain can rapidly progress to unconsciousness, irreversible brain damage and death, and should therefore be treated as a priority along with cardiovascular and respiratory emergencies.

Any type of a primary brain injury (i.e. injury from the initial insult) can trigger secondary biochemical, molecular and cellular changes in the brain with variable extent and duration. Imbalances in neurotransmitters release, generation of free radicals, calcium-mediated damage, detrimental effect of inflammatory mediators, ischemia and hypoxia, break-down of the blood-brain barrier, mitochondrial dysfunction and metabolic crisis are all well-known secondary processes that may take place in the brain parenchyma after a primary brain injury. These mechanisms, combined with the negative effects of systemic insults seen in polytrauma patients (i.e. hypoxemia, hypotension, hyperthermia, metabolic acidosis, hyperglycaemia, hypo- or hypercapnia), lead to additional brain damage, brain oedema and delayed neuronal death, thereby determining the final extent of a secondary brain injury. Intracranial bleeding and brain oedema are two major causes of increased intracranial pressure (ICP) in TBI, which, if not controlled, can lead to a deadly brain herniation.

The diagnosis of TBI is based on medical history, clinical presentation, neurological examination and diagnostic imaging. The initial neurological examination of a head trauma patient includes an assessment of mentation (i.e. alert and responsive, obtunded, stuporous or comatose) and gait (i.e. ambulatory, paresis or plegia; lateralisation of the neurologic deficit, involvement of front and/or hind legs). In a multitrauma patient, other injuries must be considered (i.e. spinal injuries, fractures of extremities and pelvis) and neurological examination tailored to the individual patient. Furthermore, the impact of extracranial factors on mentation and gait (i.e. hypovolemic shock, hypoxemia, pain) must be taken into account. Further assessment of a brain injury includes the size, symmetry and responsiveness of pupils, presence of abnormal breathing patterns and abnormal posturing of the body (i.e. decerebrate or decerebellate rigidity). Bradycardia with arterial hypertension is seen with severe intracranial hypertension (ICH) and cerebral ischemia. In veterinary medicine, the modified Glasgow Coma Scale scoring system is being used in patients with TBI; this system enables grading of the initial brain injury severity and serial monitoring of the neurological function, and it also facilitates the assessment

of short-term survival. Computed tomography (CT) is considered to be the preferred imaging modality for an acute head trauma patient (with or without TBI) once the initial stabilisation is achieved. With current CT scanners, intracranial bleeding, diffuse brain swelling, fractures of the skull bones and other bones of the head, and sometimes even brain herniation can be diagnosed in a short time. Besides, in polytraumatised patients, CT imaging of the whole body offers the most sensitive and accurate non-invasive diagnostic tool for identifying major injuries of different body systems and organs. Recognition and monitoring of an elevated ICP presents a huge challenge for practicing veterinarians, with invasive ICP monitoring still being a matter of research and not widely available. Papilloedema and an increased optic nerve sheath diameter are two bedside techniques that may help with the diagnosis of ICH.

The treatment of TBI in veterinary medicine is largely supportive. Hypovolaemia, hypotension and respiratory emergencies must be addressed appropriately to prevent arterial hypotension, hypoxemia and hyper- or hypocapnia. Acid-base and electrolyte abnormalities must be corrected. A proper positioning of the patient with head elevation by 15–30 degrees will promote venous drainage from the head and lower ICP. Hyperosmotic agents (i.e. mannitol, hypertonic saline) are used to decrease ICP and increase cerebral perfusion pressure and cerebral blood flow. Corticosteroids in TBI are now known to be harmful and are currently not recommended. Seizures must be aggressively treated with anticonvulsants. Insulin treatment may be justified in severe hyperglycaemia. Interventions that decrease cerebral metabolic rate (i.e. barbiturate coma, therapeutic hypothermia) may be considered in patients with severe ICH that is refractory to medical and surgical therapy, even though the proof of efficacy of these methods in clinical veterinary medicine is missing. Surgical intervention may be indicated in depressed or open skull fractures, ongoing intracranial haemorrhage, haematomas or foreign bodies, or inadequate response to medical therapy.

Despite our better understanding of patho-physiological processes in TBI, advanced multimodality neuromonitoring that would enable an adequate assessment of the brain function after TBI (i.e. monitoring of intracranial pressure, cerebral perfusion pressure and blood flow; assessment of cerebral oxygenation and metabolism; electroencephalography) is rarely available in veterinary medicine. Likewise, effective treatment strategies for severe TBI are lacking, with only few treatment options addressing destructive intracranial processes being available to us. Considering that evolution and progression of a secondary brain injury is a dynamic and unpredictable process, regularly repeated neurological assessments that enable prompt detection of neuro-worsening and appropriate treatment interventions are of paramount importance.

BARF - SUPERFOOD AND/OR A "ONE HEALTH" CONCERN?Breda Jakovac-Strajn¹, Tatjana Pirman², Majda Golob³¹*Institute of Food Safety, Feed and Environment, Veterinary Faculty, University of Ljubljana, Slovenia*²*Department of Animal Science, Biotechnical Faculty, University of Ljubljana, Slovenia*³*Institute of Microbiology and Parasitology, Veterinary Faculty, University of Ljubljana, Slovenia*

The popularity of feeding raw food diets to dogs and cats has increased amongst pet owners worldwide. Many owners have abandoned conventional, dry and canned commercial diets in search of more "natural" and "homemade" choices. This happened more or less as a consequence of what had happened in the human food marketplace of natural and organic products (Schlesinger and Joffe, 2011). Therefore, many pet owners look for products or ingredients with claims of human-grade, organic, holistic, ancestral or instinctual, and at the same time avoid ingredients perceived as not that good, such as fillers or by-products (Shmalberg, 2013). However, pet owners still trust veterinarians for nutritional information. Because of that, the veterinary profession has the responsibility to disseminate accurate and up-to-date information about potential benefits and health risks in regard to the increasingly popular, unconventional feeding of raw, meat-based diets (Kukanich, 2011).

Raw food possesses a substantial risk of infectious disease to pets, their environment and related humans. An important emerging issue is the risk of introducing antimicrobial-resistant bacteria. Raw pet food commonly exceeds hygiene criteria for counts of *Enterobacteriaceae*. These bacteria often encode resistance to critically important antimicrobials such as extended-spectrum cephalosporins, and raw-fed pets develop an elevated risk of shedding such resistant bacteria. Other infectious organisms that may be of concern include *Listeria*, shiga toxinigenic *Escherichia coli*, parasites such as *Toxoplasma gondii* and uncommon agents such as the zoonotic livestock pathogen *Brucella suis*, recently identified in raw pet meat imported from Argentina to the European Union (Davies et al., 2019).

The aim of our study was therefore a microbiological analysis of seven different raw meat diets from Slovene pet shops. The presence of *Listeria monocytogenes*, *Salmonella*, *Enterobacteriaceae*, MRSA (methicillin-resistant *Staphylococcus aureus*) and *E. coli* ESBL (extended spectrum beta-lactamase) was determined in samples (Table 1).

All specimens were cultivated in different selective and non-selective media according to the standard protocols. The suspicious colonies were identified by the matrix-assisted laser desorption/ionisation time-of-flight (MALDI-TOF) mass spectrometry (Microflex LT system, Bruker Daltonics, Germany) according to the manufacturer's instructions.

The isolation of at least one species of pathogenic or resistant bacteria from almost all samples is a fact that requires particular attention. *L. monocytogenes* is one of the most important foodborne bacteria with high mortality among infected individuals. On the other hand, resistant bacteria, such as MRSA and *E. coli* ESBL, do not pose such a serious direct risk of infection, but they are carriers of genes for resistance to different groups of antimicrobials.

Table 1: Microbiological analysis of raw diet samples

Samples	<i>Listeria monocytogenes</i>	<i>Salmonella</i>	<i>Enterobacteriaceae</i> (cfu)	MRSA	<i>E. coli</i> ESBL
1	not detected	not detected	450	detected	not detected
2	detected	not detected	940	not detected	not detected
3	not detected	not detected	1410	not detected	detected
4	detected	not detected	1200	not detected	detected
5	not detected	not detected	910	not detected	detected
6	not detected	not detected	1480	not detected	detected
7	not detected	not detected	1130	not detected	not detected

When a meal is made up of poultry meat, there is a greater risk of being contaminated with *E. coli* ESBL or salmonellas, and in the case of raw pork ingredients it may contain MRSA. All of these bacteria can be destroyed during the heat treatment process, but in raw food they can even multiply. The latter is particularly true for *L. monocytogenes*, which is capable of effectively multiplying even in the refrigerator.

On a precautionary basis, the advice against raw feeding issued by various professional bodies appears justified, especially in the case of the many households that include individuals particularly vulnerable to infectious diseases. In addition, aspects of raw feeding that may have been underappreciated until recently include an increased frequency and number of antimicrobial drug-resistant bacteria in raw foods and the risk of exotic pet, livestock and zoonotic diseases associated with imported raw meats (Davies et al., 2019).

Currently, data on nutritional, medical and public health risks of raw food diets are fragmentary, but they are increasingly forming a compelling body of formal scientific evidence. It appears important that veterinary and public health practitioners and organisations continue to exercise responsibility to communicate this to both consumers and producers of raw food for pets. The mitigation measures focused on human medicine, such as emphasising a safer handling of food at home, may have the most significant impact on currently well-established raw feeding in the short-to-medium term.

THE HORSE: A MIRACLE OF BIOENGINEERING OR A REALLY STUPID DESIGN? HOW BIOMECHANICS AFFECTS PERFORMANCE AND RISK OF INJURY IN THE HORSE...

Renate Weller

Director of Veterinary Education, CVS (UK) Ltd, London, United Kingdom

The most common clinical problem in horses is lameness, and, like human athletes, equine athletes walk a fine line between being top performers and risking an injury. When you train more, you get better, but at the same time your risk of musculoskeletal injury goes up.

Horses have an amazing anatomy

Horses show an amazing ability to perform a whole range of sporting activities. Evolutionarily, they have developed as what is termed "cursorial animals". These animals share the ability to run very fast if they need to (in the past that would have been necessary to escape predators), but also cover large distances at slow speeds while grazing for nourishment, which was essential for survival on the sparse vegetation of the prairie-type land the horse originated from. To be able to do this, the horse has developed special anatomical and physiological features that are all aimed at reducing the energy cost of locomotion. The horse has made its limbs lighter by reducing the number of bones to one weight-bearing column and by not carrying any muscle below the carpus; this allows the horse to move its leg forward more easily. At the same time, the horse has elongated its limbs by essentially walking on tip toes, which allows the horse to have a very long stride and makes room for the very long tendons on the back of its leg. These tendons originate way up at the elbow, pass all the way down the leg, wrapping around the fetlock joint before finishing on the pastern and coffin bones. The fetlock joint is in permanent hyperextension: even in the standing horse it is "angled backwards" and during movement it may even touch the ground at high speeds (Fig. 1). While it may look weird at first glance to have such an "unstable" joint, this allows the horse to use its body weight to save energy while moving. Every time the leg hits the ground, the fetlock joint acts as a pivot around which the flexor tendons on the back of the leg get stretched. These tendons are like rubber bands: when they get stretched, they store energy, which is then released as the leg leaves the ground. These tendons return more than 90% of their energy, thus making horse locomotion extremely energy efficient.

Nothing in life is free

All these modifications come at a cost: if you want to have light legs, you need to make your bones and tendons as gracile as possible. If you do that, they become more fragile. Horse legs get put under tremendous loads, which increase the faster they go. Even a horse in walk puts half of its body weight on its front leg, going up to 2.5x its body weight during gallop. In a 500 kg horse this would result in 1.5 tons coming down on each front leg. And this happens not only once, but again and again during training. A galloping horse will impose about 220 loading cycles per mile and it is indeed the cyclical overloading that leads to injuries in equine as well

as human athletes.

In engineering, the load a structure can take above and beyond what it is supposed to take during normal usage is described as the "safety factor". Man-made structures like elevators usually have a safety factor of 8 to 10: if it says in an elevator that you can have 10 people in it, you should be able to load 80 before it breaks! Horse legs, however, have a safety factor of 2, with the superficial digital flexor tendon in some horses going as low as 1.5. Previous injury results in an even lower safety factor, since scar tissue is not as strong as the original tendon tissue. Hence, it is no wonder that 50% of racehorses in training may suffer from a tendon injury during a racing season.

Bones and tendons in horses have been estimated to have a "working life" of as little as 10,000 cycles before they wear out. It is, therefore, no surprise that horses are prone to musculoskeletal injuries and it is actually almost more surprising that some of them manage to stay sound.

The load experienced by the leg is determined by the body weight and how fast the horse is going. If you want to win races, you cannot reduce speed during a race, but you can modify training speeds. As in humans, body weight in horses needs to be optimal, with a minimum of fat, but enough muscle to power the horse forward.

How the load is distributed matters

Conformation and farriery influence how the load is distributed between different structures (bones, joint, tendons) in the leg. The conformation of the leg determines how much force each structure experiences and we can use farriery techniques to influence this. Changing the foot through trimming or by applying a shoe changes the moment arm of the ground reaction force around the joints and thus changes the moment arms of the flexor tendon (Fig. 1). Every little counts! In an average Thoroughbred racehorse, a centimetre at the toe equates to roughly 50 kg on top when it comes to loads in the flexor tendon – so maybe the handicappers should start paying attention to toe length?

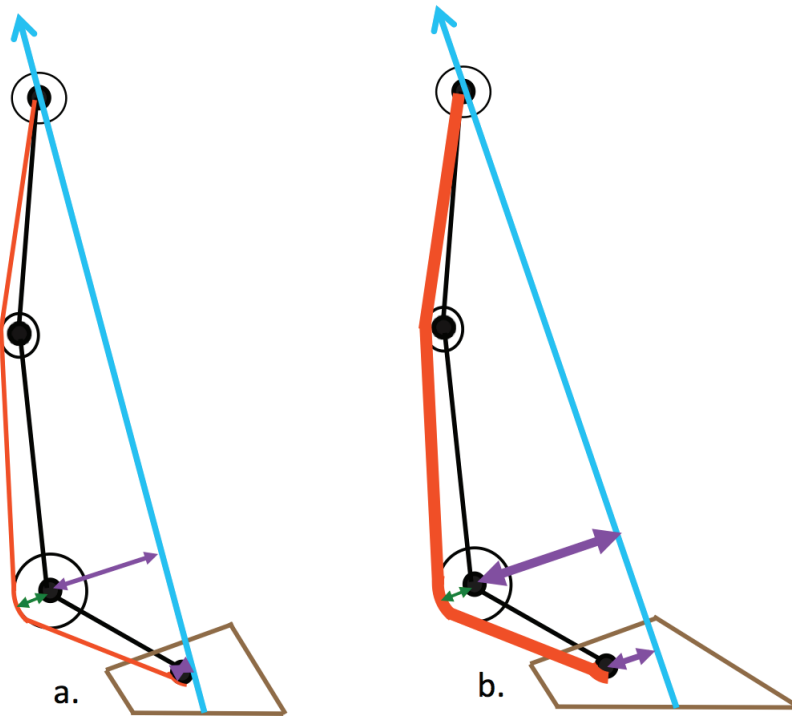


Figure 1

Schematic drawing of the equine forelimb a. under load with a short toe b. under the same load, but with a long toe. Circles = joints, black lines = bones; Blue lines = ground reaction force (GRF), Red lines = flexor tendons, green arrow = flexor moment arm, purple arrow = extensor moment arm. Increased forces are represented by thicker arrows and lines

To prevent the fetlock from collapsing, the rotation force acting on joints on the front of the leg (extensor moment) must equal the force acting on the back of the leg (flexor moment). The extensor moment is the product of the force acting on the whole leg (GRF) and its lever arm around each joint (extensor moment arm). The flexor moment is the product of the force going through the flexor tendons and their lever arms around each joint (flexor moment arm).

If the GRF increases, the extensor moment increases, so the flexor moment must also increase to prevent the fetlock collapsing. Since the moment arm of the flexor tendons around the coffin and fetlock joints are fixed by the size of the sesamoid bones, this is achieved by increasing the force in the flexor tendons.

If a horse has a long toe, the GRF enters the foot closer to the toe. This increases the extensor moment arm and, therefore, the extensor moment overall, so again the flexor moment must also increase by increasing the force in the flexor tendons.

"ONE HEALTH" APPROACH IN TUMOUR RESEARCH

Andrea Gudan Kurilj

Department of Veterinary Pathology, Faculty of Veterinary Medicine, University of Zagreb, Croatia

Today cancer is one of the most prevalent diseases, and not just in humans. In the USA, it is estimated that approximately 500 new cases of cancer are diagnosed per 100,000 of the population each year, whereas in dogs the estimate is 5,300 cancer diagnoses per 100,000 population.

Comparative oncology is a quickly expanding field that examines both cancer risk and tumour development across species. Characterised by interdisciplinary collaboration, its goal is advancement of both human and animal health. Research in this area is mostly focused on finding an ideal animal model to study human cancer. This model should possess comparable histopathological features, biological behaviour and molecular and genetic characteristics.

Considering the failures in cancer drug development and the complexity of cancer biology, the laboratory models of cancer suffer from some serious limitations. Experimental therapies tested in murine models have, all too often, elicited responses that only poorly predict the outcomes of those therapies being translated to the human setting. Murine bone marrow is generally less sensitive to the toxicity induced by chemotherapy than human bone marrow, suggesting that mice are not suitable for use in the evaluation of the adverse effects of novel chemotherapies. Also, genetically modified mice, transplantation and xenograft models obtained from the patient have shown that they do not mimic exactly the specificity of human cancer, thereby limiting their reliability to translational applications. In addition, one of the main disadvantages is the limited life-span of mice, which does not allow several fundamental features of the nature of human cancers to be reproduced: growth over long periods of time, genomic instability and tumour heterogeneity. Finally, there are discrepancies between the immune systems of mice and humans, which raises the question of using mouse models for a rigorous assessment of immunotherapy strategies.

Tumour-bearing dogs capture the "essence" of the problem of cancer in a way that is not achievable with other animal models. In 2005, the canine genome was completely sequenced and a high degree of sequence similarity compared to human genome was identified. Canine cancers also share evolutionarily conserved genomic changes that are found in their human counterparts. Tumour initiation and progression processes in both humans and dogs are influenced by the same factors, including age, nutrition, sex and environment. They drink the water that we drink, sometimes eat the same food that we eat, they are exposed to the same air as we are and could, therefore, be considered epidemiological or aetiological sentinels of the disease. Pet tumours grow slowly in an intact immune system, allowing immune and cancer cells to interact for a long period of time, shaping each other, as well as showing the intra-tumour heterogeneity and genetic instability that is typical of human lesions. The histological and clinical presentation of numerous canine cancers closely parallels that of the corresponding cancers in humans. Yet, humans are not the only ones that benefit from the research of canine

cancer. Biological similarities between canine and human cancers have also provided significant rationale for the study of novel therapeutic approaches in dogs. Furthermore, studying naturally occurring tumours in dogs has an ethical benefit, reducing the number of laboratory animals in which cancer is induced.

In recent years, several groups of researchers have performed veterinary studies in order to test innovative strategies in a highly translational setting. These studies included a wide range of comparative tumours, such as lymphomas, melanomas, osteosarcomas, mammary gland tumours and brain tumours. The most active areas of research are the assessment of changes to genome architecture aimed at identifying regions of genome aberration shared between canine and human cancers (suggestive of a conserved mechanism of pathogenesis), comparative aspects of microRNA expression in canine and human cancers and the investigation of innovative therapeutic approaches with a high translational power for human and canine patients.

Most recently, our faithful companions are used in the research of human tumours in a different manner, not only as a model. They are used in the context of tumour diagnostics, where a few studies have shown that human tumour diagnosis harnessing the superior canine olfactory ability is a promising alternative for the diagnostics of certain types of cancer.

Besides dogs, there are other animals (both prone and resistant to cancer development) that offer their own unique opportunity to better understand the processes involved in tumourigenesis. Among them are marine mammals, bats, naked mole-rats, bowhead whales and elephants. As we can notice, the comparative oncology truly embraces all cancer risks with the goal to broaden our knowledge about tumours and translate this towards improving the health of humans and animals.

INFLUENZA A VIRUSES: FROM BIRDS TO HUMANS

Vladimir Savić

Poultry Centre, Croatian Veterinary Institute, Zagreb, Croatia

Influenza has threatened humankind through history. Humans can be infected with influenza viruses of types A, B and C, the first two being associated with significant morbidity and mortality. Nevertheless, type A is the most threatening, particularly zoonotic and pandemic strains due to little or no pre-existing specific or cross-protective immunity. Human influenza pandemics during the past and the current century have been attributable to viruses with an avian ancestry that entered the human population directly, or indirectly through intermediate hosts. Type A influenza viruses can infect a wide variety of birds and mammals, but the natural hosts and the main reservoir of these viruses are aquatic birds from the orders Anseriformes (ducks, geese and swans) and Charadriiformes (gulls, waders and terns). The vast majority of influenza A viruses is completely adapted to these birds, in which the infection does not cause virtually any signs of illness. Such viruses in aquatic birds are in the evolutionary stasis. In contrast, a very intense evolution in unnatural hosts, such as terrestrial birds and mammals, is attributed to the selection pressure due to the adaptation of these viruses to a new host.

The evolution and diversity of influenza A viruses are driven by two mechanisms. The RNA genome of the virus is comprised of eight segments that encode transcripts for ten essential viral proteins, of which two are surface glycoproteins, haemagglutinin and neuraminidase. The latter two glycoproteins exist in numerous antigenic subtypes and play the most important role in infection and immunity. The accumulation of point mutations in either of the genome segments leading to amino acid changes in the corresponding protein is referred to as antigenic drift, while the reassortment (exchange) of virus genome segments from different influenza A viruses during co-infection is referred to as antigenic shift. The point mutation rate is higher in terrestrial poultry and mammals due to the selection pressure, while the gene segment reassortment is more common in aquatic birds due to the abundance of different influenza A viruses.

Among unnatural hosts, humans are probably the least prone to infection with avian influenza viruses. Nevertheless, certain avian influenza viruses are capable of cross-species transmission, including human infections. Although sustained person-to-person transmission of such viruses has not been documented so far, each human infection with avian influenza viruses provides chances for the virus adaptation towards efficient transmission within human population. On the other hand, the swine plays an important role in epidemiology of influenza A viruses because this species is prone to infection with viruses originating from birds and those originating from mammalian hosts, including humans. Such universal host can serve as a mixing vessel for the reassortment of avian and human viruses, which can result in the emergence of influenza A viruses of a new subtype or new antigenic variant capable for human infection. This scenario has been postulated for the emergence of the recent pandemic influenza A viruses.

THE ROLE OF VETERINARIANS IN FOOD SAFETY

Nevijo Zdolec

*Department of Hygiene, Technology and Food Safety, Faculty of Veterinary Medicine,
University of Zagreb, Croatia*

The veterinary profession is considered to be a profession dealing with the treatment of animals. Candidate students of veterinary medicine express "love for animals" to be the most important reason for enrolment into this study. However, few people will perceive the veterinarian as an expert who protects human health, including veterinarians themselves. In case of farm animals, vets are in the service of human health by implementing national surveillance and diagnostic programmes aimed at detecting the presence of zoonoses (such as salmonellosis, tuberculosis, brucellosis) or by controlling the production of food of animal origin in the food industry (e.g. protecting people from "mad cow disease", trichinellosis, cysticercosis etc.). There are many other examples where public health is in the focus of veterinarians' work, which is often ignored and forgotten. When veterinary medicine is mentioned in the media, it is mostly in the context of "expensive veterinary services", certain scandals with food/animal traceability or unfit meat placed on the market.

It may be stated that most meat-borne zoonoses (like TBC, cysticercosis, TSE) have been almost completely eradicated thanks to the systematic work of the veterinary inspection, as well as the veterinary profession in general. Nowadays, meat hygiene faces other hazards and risks: the veterinary profession takes on even more importance in the context of an integrated meat safety assurance system and risk-based approach in official controls. Namely, doctors of veterinary medicine are the most competent in identifying, analysing and bringing together all the factors that may threaten meat safety (and other food of animal origin) through the whole agri-food chain. In this sense, in order to detect health risks, the comprehensive approach in the meat production and inspection must include veterinary knowledge of primary production and meat hygiene, along with all the available information from the entire production system. During the assessment of meat safety in the slaughterhouse, it is important to analyse Food Chain Information (FCI), epidemiological indicators, herd health, animal welfare and hygiene practice of a slaughterhouse/farm. In that context, the importance of a veterinary practitioner at farm level is obvious, as well as the flow of food chain information from farm to slaughterhouse and vice versa.

The role of a veterinarian is therefore extensive and includes the protection and control of animal health and welfare, zoonoses and assurance of safe animal products for human consumption, promotion of animal reproduction and veterinary protection of the environment. With regard to the veterinary public health work, veterinary activities related to human health protection are carried out by applying animal health and food and feed hygiene regulations.

Doctors of veterinary medicine who work in the public health area are closely related to other professions. Thus, a few years ago, the concept called "One Health" was set up, representing the worldwide initiative and strategy of spreading interdisciplinary cooperation and

communication within the framework of common health protection of humans and animals, as well as the environment. In the area of food production and control, the above mentioned concept is called "One Agri-Food Health", which includes chain-based activities and measures of animal health and welfare protection, human and plant health protection, animal by-products control, environment protection, control of food and feed hygiene and safety, as well as transport controls of goods (import and export). The role of authorised veterinarians and veterinary inspectors in such farm-to-table control system will be presented in this lecture.

/// ORAL PRESENTATIONS ///

ANTIBACTERIAL EFFECT OF NATURAL BIOPROTECTIVE AGENT ENTEROCIN EF-101 IN MEATDea Kralj¹, Nevijo Zdolec²¹Faculty of Veterinary Medicine, University of Zagreb, Croatia, student²Department of Hygiene, Technology and Food Safety, Faculty of Veterinary Medicine, University of Zagreb, Croatia

Bacteriocins are bacterial ribosomal peptides that exhibit antimicrobial activity. Their use in food can affect bacterial foodborne pathogens and spoilage bacteria. In this work, the antibacterial effect of enterocin EF-101 was investigated in minced meat packed in aerobic conditions and cold-stored during the shelf life.

Enterocin was semi-purified from the neutralised supernatant (pH = 7; 10 N NaOH) of *Enterococcus faecalis* EF-101 culture by ammonium sulphate precipitation (484.54 g/L). The activity of enterocin (AU/mL) was tested against *Listeria monocytogenes* NCTC 10527 and the appropriate solution of enterocin in phosphate buffer (pH = 7) was added to minced meat (2560 AU/kg). Minced meat with and without enterocin was microbiologically analysed on days 0, 1, 2, 3 and 4 in triplicate for the aerobic mesophilic bacteria count, enterobacteria, psychrophiles, staphylococci, coliforms, *Escherichia coli*, lactic acid bacteria, *L. monocytogenes* and pH values.

The number of aerobic mesophilic bacteria, enterobacteria, psychrophiles, staphylococci, coliforms and lactic acid bacteria was expected to increase during storage period in both groups of samples, while pH was not significantly changed. However, the antimicrobial effect of enterocin may be the reason for 0.5 and 1.2 logs lower population of lactic acid bacteria and enterobacteria at the end of storage period, respectively. Still, the strongest antimicrobial effect was noted on day 0 or immediately after the addition of enterocin to the population of psychrophiles, coliforms, staphylococci and aerobic mesophilic bacteria.

The obtained results indicate the activity of enterocin in the meat substrate, but with a limited antimicrobial effect probably due to its rapid degradation by tissue enzymes. It is necessary to further evaluate the stability and activity of enterocin EF-101 in combination with other antimicrobial technologies.

DIVERSITY OF *VIBRIO* SPP. IN FARMED AND WILD FISH OF BAY OF MALI STON, PELJEŠAC (CROATIA)

Brigita Hengl¹, Dražen Knežević¹, Vedran Gradvol¹, Darija Vukić Lušić^{2,3}, Ana Gavrilović⁵, Jura Jug-Dujaković⁶, Snježana Kazazić⁴, Kristina Pikelj⁷, Irena Vardić Smrzlić⁴, Lorena Perić⁴, Jakov Žunić⁴, Anamarija Kolda⁴, Damir Kapetanović⁴

¹Croatian Agency for Agriculture and Food, Croatia

²Faculty of Medicine, University of Rijeka, Croatia

³Teaching Institute of Public Health of Primorje–Gorski Kotar County, Croatia

⁴Ruder Bošković Institute, Croatia

⁵Faculty of Agriculture, University of Zagreb, Croatia

⁶Sustainable Aquaculture Systems Inc., USA

⁷Faculty of Science, University of Zagreb, Croatia

The genus *Vibrio* consists of more than 100 species, a number of which could be pathogenic for humans. Besides in molluscs, *Vibrio* spp. can also be found in fish, which can represent a risk to human health. In this paper, we present the diversity of *Vibrio* spp. in farmed and wild fish from the Adriatic Sea in the Bay of Mali Ston.

A total of 51 European sea bass (*Dicentrarchus labrax*) from a fish farm and 37 wild fish caught around cages were sampled for microbiological assessment of *Vibrio* spp. Gill and skin swabs (below the dorsal fin) were taken using sterile swab sticks, swabbing an area of 1 cm². After swab sampling, wild fish were returned alive to the sea. Samples were inoculated on the Marine agar and TCBS agar. Plates were incubated at 22 °C and 35 °C and the number was estimated as CFU for 1 cm² of gills and skin.

Nine different *Vibrio* species were found in farmed European sea bass samples. The most frequent were *V. alginolyticus*, *V. anguillarum* and *V. parathaeumolyticus*. Six other species were present in less than 5 samples (*V. chagasii*, *V. fortis*, *V. harveyi*, *V. mytili*, *V. scopthalmi* and *V. tasmaniensis*). In the wild sea bass, 6 different *Vibrio* species were found, but only *V. harveyi* was found in more than 1 sample and it was present in the highest number in other wild fish species, followed by *V. ichthyenteri*. Other *Vibrio* spp. present in wild fish were *V. alginolyticus*, *V. chagasii*, *V. furnissii*, *V. gigantis*, *V. neptunius*, *V. orientalis*, *V. parathaeumolyticus*, *V. pomeroyi*, *V. rotiferianus* and *V. tasmaniensis*.

The highest *Vibrio* spp. diversity was present in farmed fish, but we also found a high diversity in different wild fish species, although fewer in number. Besides the proven pathogen *V. parathaeumolyticus*, we found other *Vibrio* species that may cause harm to human health. These findings indicate the necessity to follow good hygiene practice in cases when fish are intended for human consumption and to monitor *Vibrio* spp. regularly.

NOROVIRUS OUTBREAKS IN 2019: RESULTS OF CROATIAN INSTITUTE OF PUBLIC HEALTH

Marin Bajek¹, Nataša Bauk², Mirela Josipović², Vesna Šeperić², Vanja Slavić Vrzić³, Maja Bogdanić², Tatjana Vilibić-Čavlek^{3,4}, Irena Tabain²

¹Faculty of Medicine, University of Rijeka, Croatia

²Croatian Institute of Public Health, Zagreb, Croatia

³Zagreb County Institute of Public Health, Zaprešić, Croatia

⁴School of Medicine, University of Zagreb, Croatia

Norovirus is an important cause of non-bacterial gastroenteritis. Norovirus infects hosts of all ages and can cause large outbreaks in closed settings. Person-to-person transmission is essential in endemic cycle. Besides humans, norovirus can infect a range of different animals (e.g. pigs, cattle and mice). Therefore, zoonotic transmission of the infection is possible, indirectly, through contaminated food and water as vehicles, or directly, through animal contact. The aim of this study was to determine the prevalence and distribution of noroviruses in patients with gastroenteritis.

The studied population included 107 patients aged from 4 months to 97 years (median age: 28 years) with clinical symptoms of gastroenteritis. Stool specimens from each patient were tested by using rapid immunochromatographic tests for rotavirus, adenovirus (Rota-AdenoGnost, BioGnost, Zagreb) and norovirus (Norovirus, Biognost, Zagreb), respectively according to the manufacturer's recommendations.

The overall prevalence rates for norovirus, rotavirus and adenovirus were 13.1%, 1.9% and 0.9%, respectively. Out of 14 documented norovirus infections, 2 (14.3%) were sporadic cases and 12 (85.7%) cases were identified as norovirus outbreaks in closed settings: 5 (35.7%) as nosocomial infections and 7 (50%) cases in a child care facility. The first outbreak occurred in March in a hospital setting, and the child care facility outbreak occurred in May. All 5 nosocomial norovirus infection and 1/7 cases in the child care facility occurred in adults.

These findings highlight the importance of an early detection of norovirus cases for preventing the spread of the infection by implementing appropriate hand hygiene, environmental disinfection and isolation of the infected person in high-risk closed settings (e.g. healthcare). Our data also showed that norovirus is an important pathogen in children and, therefore, norovirus detection should be routinely performed in children with gastrointestinal infections.

PREVALENCE OF TICK-BORNE ENCEPHALITIS, LYME-BORRELIOSIS AND HUMAN GRANULOCYTIC ANAPLASMOSIS IN PATIENTS WITH HISTORY OF TICK BITE, CROATIA (2017 - 2018)

Maja Bogdanić¹, Vladimir Savić², Irena Tabain¹, Blaženka Hunjak¹, Ljiljana Milašinić¹, Ljiljana Antolašić¹, Snježana Artl¹, Ljubo Barbić³, Lorena Jemeršić², Jelena Prpić², Ana Klobučar⁴, Andreja Jungić², Vladimir Stevanović³, Stjepan Krčmar⁵, Marko Vucelja⁶, Marko Boljfačić⁶, Krunoslav Capak¹, Tatjana Vilibić-Čavlek^{1,7}

¹Croatian Institute of Public Health, Zagreb, Croatia

²Croatian Veterinary Institute, Zagreb, Croatia

³Faculty of Veterinary Medicine, University of Zagreb, Croatia

⁴Andrija Štampar Teaching Institute of Public Health, Zagreb, Croatia

⁵Josip Juraj Strossmayer University of Osijek, Croatia

⁶Faculty of Forestry, University of Zagreb, Croatia

⁷School of Medicine, University of Zagreb, Croatia

The *Ixodes ricinus* ticks are vectors of a large variety of pathogens, of which tick-borne encephalitis virus (TBEV), *Borrelia burgdorferi* sensu lato complex and *Anaplasma phagocytophilum* are the most important human pathogens. In Croatia, TBE and Lyme-borreliosis are continuously detected, while human granulocytic anaplasmosis is reported sporadically. The aim of this study was to analyse the prevalence of tick-borne zoonoses in patients with a history of a tick bite.

During a two-year period (January 2017–December 2018), serum and cerebrospinal fluid (CSF) samples were collected from 45 patients with neuroinvasive disease and tested for the presence of IgM and IgG antibodies to TBEV, *B. burgdorferi* and *A. phagocytophilum*. Patients were from continental Croatian counties. Serological tests were performed by using a commercial enzyme-linked immunosorbent assay; ELISA (TBEV and *B. burgdorferi*) or an indirect immunofluorescence assay; IFA (*A. phagocytophilum*). TBEV IgM/IgG positive samples were further tested for IgG avidity (ELISA). *B. burgdorferi* IgM/IgG positive samples were confirmed by using an immunoblot test.

TBE was confirmed in 29 patients and neuroborreliosis in 3 patients by the detection of IgM and IgG antibodies in both serum and CSF samples. In 2 patients, TBEV and *B. burgdorferi* co-infection was found. Human granulocytic anaplasmosis was not detected during the testing period; however, IgG antibodies to *A. phagocytophilum* were detected in 12 patients, with antibody titres ranging from 64 to 512. The cases occurred from April to November. The majority of the patients were from the Koprivnica–Križevci, Međimurje, Osijek–Baranja and Varaždin counties.

Our results showed that continental Croatian regions are still endemic for TBEV and Lyme-borreliosis. Further studies on a larger number of patients are needed to confirm the prevalence and clinical significance of human granulocytic anaplasmosis.

PREVALENCE AND MOLECULAR EPIDEMIOLOGY OF WEST NILE INFECTIONS IN OSIJEK - BARANJA COUNTY, 2012 - 2018

Dario Sabadi^{1,2}, Ljiljana Perić^{1,2}, Vladimir Savić³, Mario Duvnjak^{1,2}, Danijel Šimašek^{1,2}, Irena Tabain⁴, Dubravka Lišnjić^{1,2}, Ilija Rubil^{1,2}, Ljubo Barbić⁵, Barbara Grubišić^{1,2}, Veronika Kralik^{1,2}, Vladimir Stevanović⁵, Vedrana Radočaj², Tatjana Vilibić-Čavlek^{4,6}

¹Faculty of Medicine, Josip Juraj Strossmayer University of Osijek, Croatia

²University Hospital Centre Osijek, Osijek, Croatia

³Croatian Veterinary Institute, Zagreb, Croatia

⁴Croatian Institute of Public Health, Zagreb, Croatia

⁵Faculty of Veterinary Medicine, University of Zagreb, Croatia

⁶School of Medicine, University of Zagreb, Croatia

In the Osijek-Baranja County, the first cases of West Nile virus (WNV) infections were confirmed in late August and early September 2012 in 5 patients with neuroinvasive disease. In 2017, there were 2 cases of neuroinvasive disease, while in 2018, 17 patients with neuroinvasive disease were hospitalised.

Among 24 patients, there were 14 (58.3%) women and 10 (41.7%) men. The mean patient's age was 65.5 years (range 6–90 years). The majority of patients were hospitalised in August (14/57.5%) and September (7/29.2%).

Twenty-one patients (87.5%) reported an underlying disease, most commonly hypertension and diabetes. WNV neuroinvasive disease presented as meningoencephalitis in 22 (91.6%) patients, acute cerebellitis in 1 female child (4.2%) and afebrile polyradiculoneuritis in 1 young woman (4.2%). The most common symptoms were fever (22/91.66%), headache (21/87.5%), nausea (15/62.5%), changes in mental status (12/50.0%), neck stiffness (12/50.0%), vomiting (9/37.5%) and photophobia (5/20.8%). Cerebrospinal fluid (CSF) examination showed pleocytosis (leukocytes mean value $103.5 \times 10^6/L$; 30% lymphocytes; 49% neutrophils) and a mildly elevated protein level (mean value 0.756 g/L). A slow diffuse dysrhythmia in EEG was detected in 19 patients (79.2%). CT scans showed generalised brain atrophy in 6 patients (25.0%).

WNV diagnosis was confirmed by the detection of WNV IgM and low avidity IgG antibodies in serum and CSF and/or detection of WNV RNA in CSF and/or urine samples. Five sequenced strains showed the circulation of WNV lineage 2.

The patients were initially treated with acyclovir, ampicillin and ceftriaxone intravenously (until the completion of virology results) with a supportive (antiedematous) therapy. Two patients (8.3%) died and the remaining 22 patients (91.7%) recovered fully.

The presented results indicate that the Osijek-Baranja County is an endemic area for WNV, which was further supported by a high WNV seropositivity rate in poultry and horses.

SEROEPIDEMIOLOGY OF PHLEBOVIRUS INFECTIONS IN CROATIA, 2017–2018

Mirta Šalamun¹, Branko Kolarić^{2,3}, Irena Tabain¹, Ljiljana Antolašić¹,
Ljiljana Milašinčić¹, Snježana Artl¹, Vladimir Savić⁴, Ljubo Barbić⁵,
Vladimir Stevanović⁵, Tatjana Vilibić-Čavlek^{1,2}

¹*School of Medicine, University of Zagreb, Croatia*

²*Andrija Štampar Teaching Institute of Public Health, Zagreb, Croatia*

³*Faculty of Medicine, University of Rijeka, Croatia*

⁴*Croatian Veterinary Institute, Zagreb, Croatia*

⁵*Faculty of Veterinary Medicine, University of Zagreb, Croatia*

Phleboviruses belong to a large group of arboviruses that are transmitted to humans by sandflies. Infections by these viruses in humans manifest as a febrile disease, so-called "three-day fever" ("Pappataci fever"), while Toscana virus (TOSV) may cause neuroinvasive disease. In Croatia, TOSV, sandfly fever Sicilian virus (SFSV) and Naples virus (SFNV) were documented.

The aim of this study was to analyse the seroprevalence of phleboviruses in residents of continental and coastal Croatian areas.

During a two-year period (January 2017–December 2018), a total of 214 participants aged 18–89 years were tested for phlebovirus antibodies. The study group included 113 (52.8%) men and 101 (47.2%) women. Depending on the geographic area, 92 (43.0%) participants were from coastal and 122 (57.0%) from continental Croatian regions. All participants were asymptomatic at the time of testing and did not report recent febrile disease. IgG antibodies to SFSV, SFNV, sandfly fever Cyprus virus (SFCV) and TOSV were determined by using an indirect immunofluorescent assay.

Antibodies to SFSV were found in 5 (2.3%) participants, SFNV in 7 (3.3%), SFCV in 1 (0.5%) and TOSV in 22 (10.3%) participants. There was no significant difference in the phlebovirus seroprevalence according to gender (men 14.2%; women 13.9%) and age of the participants (11.1–19.4%). A statistically significant higher seroprevalence rate ($p < 0.001$) was found among the inhabitants of coastal areas (25.0%) than among the inhabitants of continental regions (5.7%). The results of the logistic regression showed that living in a coastal area is a significant risk factor for flebovirus seropositivity (OR = 5.476; 95%CI = 2.232–13.430).

The results of this study confirmed the presence of phleboviruses in Croatia. Due to a relatively small number of participants, further research is needed to confirm these observations and determine the exact seroprevalence in the studied Croatian regions, both continental and coastal.

MOLECULAR CHARACTERISATION OF ROTAVIRUS A CIRCULATING AMONG DOMESTIC ANIMALS IN CROATIA

Alen Kovačević¹, Nina Krešić¹, Ivana Šimić¹, Ines Škoko², Dragan Brnić¹

¹Department for Virology, Croatian Veterinary Institute, Zagreb, Croatia

²Croatian Veterinary Institute, Regional Department Split, Croatia

Rotavirus A (RVA) is an enteric pathogen affecting human and animal health worldwide. Due to their high prevalence, pathogenicity and zoonotic potential, RVAs are important from both public health and veterinary health perspectives. Thus, as a part of the molecular epidemiology study on RVAs in the Croatian ecosystem, herein we present the genetic diversity of RVAs circulating among domestic animals.

Overall 515 faecal samples or rectal swabs (198 pigs, 161 cattle and 156 dogs) were collected from farms and dog shelters during a period of one year (2018/2019). All isolates were screened for the presence of RVA VP2 gene segment by using real-time RT-PCR. Positive samples were then subjected to further analysis of VP7 and VP4 gene segments by using conventional RT-PCR, by means of different primers combinations due to the RVA high genetic heterogeneity. After the DNA gel electrophoresis, Sanger sequencing was used in order to determine G (VP7) and P (VP4) genotypes.

The molecular detection resulted in 36% of RVA positive samples, from which half were successfully genetically characterised. During one year of sampling, we have determined 8 different porcine, 7 bovine and 2 canine RVA genetic combinations, with predominant G9P[23] and G6P[5] genotypes. Due to the low RVA load in canine samples, only a quarter of positive samples were successfully genetically determined, revealing genotype combinations atypical for dogs. Furthermore, we have detected 1 rare porcine genotype, P[32], previously described in Ireland and Great Britain, as well as the bovine G24P[33], a combination described so far only in cattle in Japan.

The molecular characterisation of RVAs circulating among domestic animals in Croatia showed mostly the typical distribution for porcine and bovine RVA strains, but somewhat unusual for canine genotypes. A continuous monitoring of the RVA molecular epidemiology in domestic animals is warranted to assess its zoonotic potential and impact on public health.

GENETIC DIVERSITY OF ROTAVIRUS A IN WILDLIFE IN CROATIA

Nina Krešić¹, Alen Kovačević¹, Ivana Šimić¹, Miljenko Bujanić²,
Dean Konjević², Dragan Brnić¹

¹Department for Virology, Croatian Veterinary Institute, Zagreb, Croatia

²Department of Veterinary Economics and Epidemiology, Faculty of Veterinary Medicine,
University of Zagreb, Croatia

Rotavirus A (RVA) is a worldwide-distributed enteric pathogen, primarily in humans and domestic animals. Their genetic backbone and molecular epidemiology in wildlife species is rather unknown; hence, their importance might be underestimated. Herein, as a part of the RVA molecular epidemiology project in the Croatian ecosystem, we present the first results on RVA genetic diversity in selected wild species.

During the first year of RVA surveillance (2018–2019), we have collected 498 faecal samples of mostly healthy red deer (n = 121), roe deer (n = 34), red foxes (n = 192), European jackals (n = 3) and wild boar (n = 148). All samples were submitted to RNA extraction and RVA detection by using real-time RT-PCR (RVA VP2 segment). Positive samples were retested by using various conventional RT-PCR protocols in order to amplify VP7 and VP4 RVA segments. Successfully amplified fragments were sent for direct Sanger sequencing in both directions, which allowed for RVA G and P typing.

The results regarding RVA prevalence were in line with the expected values, around 10% in total. In contrast, the genetic diversity was quite remarkable, especially in red foxes, in which we have detected the circulation of 9 G and 5 P RVA genotypes. It is important to note the circulation of 2 potentially novel P and 1 novel G genotype, together with the extremely rare G15 genotype. An interesting finding is the circulation of different RVA genotypes in the red fox, European jackal and wild boar, which are usually present in other mammals. Some of the detected RVA genotypes in wildlife species share a common evolutionary ancestor with human RVA strains; therefore, their zoonotic potential cannot be excluded.

The present work brings an important knowledge on RVA prevalence and genetic diversity in wildlife species which were by now somehow neglected by the scientific community. Consequently, their importance in RVA epidemiology might be underestimated. The future work on elucidating their zoonotic potential is warranted.

INFLUENCE OF SEASON AND HERD SIZE ON AGE AT FIRST CALVING IN BUSHA CATTLE BREED

Aneta Piplica¹, Ivan Vlahek¹, Ivana Sabolek², Marija Špehar³, Sven Menčik¹

¹*Department of Animal Breeding and Livestock Production, Faculty of Veterinary Medicine, University of Zagreb, Croatia*

²*Department of Animal Hygiene, Behaviour and Welfare, Faculty of Veterinary Medicine, University of Zagreb, Croatia*

³*Ministry of Agriculture, Zagreb, Croatia*

The range of the age at the first calving of this late-maturing breed is wide. The estimation of the optimal age at the first calving is of great importance for the growth and development of calves as well as for the later reproductive performance of the autochthonous breed.

The aim of the study was to determine the effect of the calving season (CS) and herd size (HS) on the age at the first calving (AFC) for the Busha cattle. Data set for 1,376 primiparous cows was taken from the central database of the Ministry of Agriculture for the period from January 2003 to February 2019. Primiparous cows were grouped into three classes according to AFC (months) as follows: the first group between 19 and 26, the second group between 27 and 32, and the third group between 33 and 40 months of age. The data within each AFC group were analysed using the least square method and GLM procedure in the SAS software package. The effect of CS as the year-season interaction (four calving seasons were defined according to the year period) and HS with three levels (1–3, 4–10, and more than 10 animals per herd) were included in the model for each AFC group.

The highest number of calvings according to AFC ($n = 825$) was recorded in the first group, with the average AFC of 23.1 months. Both effects were significant ($p < 0.01$) and accounted for 15.7% of AFC variability. In the second calving group ($n = 273$), the average AFC was 29.3 months and only CS ($p < 0.01$) affected AFC and accounted for 31.3% of the variability. The lowest number of calvings ($n = 178$) was recorded in the third group, with the average AFC of 35.8 months. Both effects, CS and HS were significant ($p < 0.01$) and accounted for a certain proportion (27.9%) of AFC variability.

AFC, calving season and herd size could contribute to a high variability in the management of reproduction as a result of difficulties in the planned breeding of native breeds. An assessment of the optimal management procedure with the use of phenotype data can contribute to improving breeding strategies within local cattle breeds.

ULCERATIVE MAMMARY DERMATITIS IN DAIRY COWS – OLD CAUSE ON DIFFERENT LOCATION?

Bojan Toholj¹, Aleksandar Potkonjak¹, Vesna Miličević², Branislav Kureljušić², Ozren Smolec³, Srđan Krnjaić⁴

¹*Department of Veterinary Medicine, Faculty of Agriculture, University of Novi Sad, Serbia*

²*Scientific Veterinary Institute of Serbia, Belgrade, Serbia*

³*Clinic for Surgery, Orthopaedics and Ophthalmology, Faculty of Veterinary Medicine, University of Zagreb, Croatia*

Ulcerative mammary dermatitis (UMD) is also known as udder cleft dermatitis, foul udder, intertrigo, mammary necrotic dermatitis or udder seborrhoea. It affects dairy cattle. Ulcerative mammary dermatitis is commonly located at the anterior junction between the udder and the abdominal wall or between the front quarters. The lesions vary in appearance and size. Thickened skin, ulcerative appearance, crusts, pus and wounds that easily bleed are common findings.

The aetiology of UMD is still unclear. Several risk factors such as udder conformation and udder oedema in high yielding cows, parity and days in milk have been associated with UMD. An association between UMD and mastitis has been suggested, and also as a link between UMD and bovine digital dermatitis (BDD). There may be an association between BDD and UMD, as bacteria from genus *Treponemas* are highly involved in both.

In our research, we investigated a similarity in gross pathology, pathohistology of digital dermatitis (DD) and ulcerative mammary dermatitis in dairy cows. The UMD gross pathology and lesion dynamics are very similar to lesions of DD and include the early ulcerative stage, most commonly followed by proliferative lesions if healing did not occur. Furthermore, we conducted a PCR investigation from tissue obtained from the cows affected by UMD (16 samples) and DD (31 samples). We found 81% of the UMD samples positive for 1 of 3 *Treponema* groups, and at same time 67% of the DD samples were positive for 1 of 3 known *Treponema* groups.

AUTOGENOUS BACTERIAL VACCINES IN POULTRY PRODUCTION – FRIEND OR FOE

Željko Gottstein¹, Liča Lozica¹, Maja Lukač¹, Estella Prukner-Radovčić¹,
Danijela Horvatek Tomić¹

¹Department of Poultry Diseases with Clinic, Faculty of Veterinary Medicine, University of Zagreb, Croatia

Poultry production has become one of the main ways of animal protein production in the world, but poultry suffers from various infectious agents that could seriously devastate it. Viral poultry pathogens are usually successfully controlled by commercial vaccines, while the bacterial ones are generally controlled by good management, biosecurity measures and, if needed, therapy. Since bacterial pathogens have developed antimicrobial resistance, and, in parallel, the evolution of virulence factors has taken place, the problems have become worse. Some of the bacterial species like *Escherichia coli*, *Gallibacterium anatis* etc. have shown a capability to cause significant losses in all production systems. Since universal vaccines for the mentioned pathogens are usually lacking, autogenous vaccines have shown a promising potential.

In the last five years, several farms had significant problems caused by bacterial diseases. Different tissue swabs were taken and a microbiological examination was done. After isolation, the species were additionally identified by using MALDI-TOF and all of the samples were stored for later analyses. Antimicrobial resistance was tested and some isolates, such as *E. coli*, were molecularly typed. The predominant species and strains isolated from target organs in clinical cases were used for the production of an autogenous vaccine for vaccination of the next layer or breeder pullet flocks.

The results showed that the predominant bacterial pathogen in clinical cases was *E. coli*, with a high prevalence of *G. anatis*, *Salmonella Gallinarum* and *Hafnia alvei* on some farms, which were usually resistant to the majority of antimicrobials. After the introduction of an autogenous vaccine and the improvement of management on farms, mortality on a broiler breeder farm was reduced from over 20% to less than 10%. In addition, in some drastic cases of infection with both *E. coli* and *G. anatis* found in 1 layer flock, the vaccine alone reduced the mortality from 31% to 8.8% up to 60 weeks of age. The mentioned results indicate a promising future for autogenous vaccines.

CHLAMYDIA GALLINACEA IN FREE-RANGE CHICKEN FLOCKS IN CROATIA

Ana Marquiza M. Quilicot^{1,2}, Danijela Horvatek Tomić¹, Željko Gottstein¹, Maja Lukač¹, Estella Prukner-Radovčić¹

¹Department of Poultry Diseases with Clinic, Faculty of Veterinary Medicine, University of Zagreb, Croatia

²College of Veterinary Medicine, Visayas State University, ViSCA, Baybay City, Leyte, Philippines

Chlamydia gallinacea has recently been recognised as a new member of the family *Chlamydiaceae* belonging to the avian chlamydia group together with *C. psittaci* and *C. avium*. This study examined the presence of avian chlamydia *C. gallinacea* in free-range chicken flocks raised in Croatia. DNA was extracted from triple swabs (conjunctival, pharyngeal and cloacal), litter-faeces and/or water samples collected from 54 free-range chicken flocks. *Chlamydia gallinacea* was detected by using a qPCR assay by targeting the *enoA* gene. A sample was considered positive when the quantification cycle (Cq) value was ≤ 38 . A flock was considered positive when at least one of the samples was positive for *C. gallinacea*. Twenty-five (46.30%) flocks were found to be positive for *C. gallinacea*. The results of the study confirm the endemicity of *C. gallinacea* in chickens. The presence of *C. gallinacea* in free-range chicken flocks calls for the implementation of effective biosecurity and hygienic measures, as most of the flocks examined were not confined in cages. Moreover, it is therefore highly important to conduct further investigation on the epidemiology, effects on poultry health and production, and zoonotic potential of *C. gallinacea*.

INFLUENCE OF BIOSECURITY MEASURES AND MANAGEMENT PRACTICE ON GENETIC DIVERSITY OF *GALLIBACTERIUM ANATIS* ISOLATED ON POULTRY FARMS

Liča Lozica¹, Željko Gottstein¹

¹Department of Poultry Diseases with Clinic, Faculty of Veterinary Medicine, University of Zagreb, Croatia

Gallibacterium anatis is considered one of the most common bacterial causative agents of various disorders in poultry. Although it is a part of a normal microflora in the upper respiratory and lower reproductive tract, it is an opportunistic pathogen and can cause serious losses in poultry production. Due to its impact on production and high prevalence on poultry farms, we wanted to compare the isolates from two farms with different rearing and management practices. The comparison was done based on the sequences of the gene encoding the β -subunit of the RNA polymerase (*rpoB*), which is highly conserved within the family of *Pasteurellaceae* and has a high discriminatory power.

Bacterial strains from a broiler breeder farm (Farm 1) and a layer farm (Farm 2) were randomly selected. From those samples, DNA was extracted by using Chelex 100 (BioRad, France). The samples were amplified and visualised through polymerase chain reaction and 1% agarose gel electrophoresis, respectively. The purification of the amplicons from gel slices was done by using the ReliaPrep™ DNA Clean-up Concentration System (Promega, USA) and afterwards the isolates were sequenced. The sequences were edited by using the BioEdit Sequence Alignment Editor and afterwards the Basic Local Alignment Search Tool (BLAST) was used to search for identical sequences available at GenBank. A phylogenetic tree was constructed by using the Maximum Likelihood method and Tamura 3-parameter model using the Molecular Evolutionary Genetics Analysis (MEGA X).

The results show a high level of homogeneity of the isolates from the Farm 1, as opposed to heterogeneity of the isolates from the Farm 2. The Farm 1 has its own rearing flocks that are reared in the conditions of higher biosecurity standards, contrary to the Farm 2 that imports pullets from multiple rearing farms and has low biosecurity standards.

The *G. anatis* strains are frequently farm-specific, but these results indicate that low biosecurity measures and a bad management practice could greatly affect their diversity.

EFFECT OF AUTOGENOUS VACCINE ON PHYLOGENETIC RELATIONSHIP AND VIRULENCE PROFILES OF AVIAN PATHOGENIC *E. COLI* ISOLATED FROM BROILER BREEDER FLOCKS

Liča Lozica¹, Danijela Horvatek Tomić¹, Jelena Repar², Željko Gottstein¹

¹Department of Poultry Diseases with Clinic, Faculty of Veterinary Medicine, University of Zagreb, Croatia

²Division of Molecular Biology, Ruder Bošković Institute, Zagreb, Croatia

Avian pathogenic *E. coli* (APEC) is one of the most common microbial causes of decreased production and high mortality rates in poultry farming. Poultry health protection is based on immunoprophylaxis and enables high production rates. We conducted a longitudinal study of two broiler breeder flocks on the same farm that had severe problems with colibacillosis. Since the commercial vaccine was not effective, the use of an autogenous vaccine was initiated. Flock A was vaccinated with the commercial vaccine, while Flock B was vaccinated with the autogenous vaccine. The aim of this study was to investigate the effect of the autogenous vaccine on the phylogenetic relationship and virulence profiles of APEC isolates in these two flocks.

Liver and peritoneum swabs were taken from 10 and 25 hens, respectively, from the Flock A and Flock B. Thirteen APEC isolates from each flock were randomly selected for whole-genome sequencing. DNA was isolated by using the Maxwell RSC Cultured Cells DNA Kit (Promega), followed by paired-end sequencing (MiSeq, Illumina). The CGE tools Assembler, MLST and MyDbFinder were used for *de novo* assembly of the genomes, the detection of housekeeping and virulence genes of our interest, respectively. The concatenations made from housekeeping genes were used for the construction of a phylogenetic tree, which was done by using the Maximum Likelihood method and Kimura 2-parameter model using MEGA X.

The phylogenetic tree showed the isolates clustering into multiple subgroups, mostly showing a clear distinction between the isolates originating from the Flock A and Flock B. The isolates from both flocks clustered in a separate, distant subgroup, which may be linked to a greater severity of symptoms. The virulence profiles showed a diverse frequency of certain virulence genes with a clear distinction between the flocks.

The results indicate that an autogenous vaccine could affect the phylogenetic relation and virulence profiles of APEC isolates. In order to confirm the hypotheses, an extensive study should be conducted with more isolates representing the same flocks, as well as other flocks from the same farm.

ANALYSIS OF *IGF1* GENE POLYMORPHISM AND DIFFERENCES IN LITTER SIZE AFTER FIRST PARITY IN ROMANOV SHEEP: PRELIMINARY RESULTS

Ivan Vlahek¹, Anamaria Ekert Kabalin¹, Sven Menčik¹, Maja Maurić¹, Aneta Piplica¹, Velimir Sušić¹

¹Department of Animal Breeding and Livestock Production, Faculty of Veterinary Medicine, University of Zagreb, Croatia

Insulin-like growth factor 1 gene (*IGF1* gene) controls the synthesis of insulin-like growth factor 1 (*IGF1*), which is involved in many physiological processes including reproduction. The 5' flanking region of the ovine *IGF1* gene is proven to be polymorphic, and the polymorphisms are associated with reproductive traits in some sheep breeds. The aim of this study was to investigate the polymorphism of the *IGF1* gene and the differences in the number of ewes with a specific birth type (litter size) after the first parity regarding the observed *IGF1* gene polymorphic variants.

DNA was extracted from jugular vein blood of 22 Romanov ewes. Amplified PCR products of the 5' flanking region of the ovine *IGF1* gene were digested with the *HaeIII* restriction enzyme, and allele and genotype frequencies were determined. The Fischer-Freeman-Halton's test was used to test the differences in the number of ewes with specific birth type between the observed genotypes. The determined level of significance was $p < 0.05$.

The digestion of PCR products with *HaeIII* revealed 3 genotypes: AA, AB and BB. Allele A had a higher frequency (0.64) than allele B (0.36), and absolute genotype frequencies were as follows: AA (8), AB (12) and BB (2). The median, minimum and maximum for litter size after the first parity for the AA and AB genotyped ewes was 2 (1–3), while within the BB genotype 1 ewe had 1 lamb, and the other one had 2. Multiple births (2 or more lambs per litter) were observed in 87.5%, 75% and 50% of the ewes within the AA, AB and BB genotypes, respectively, and the ewes with the AA genotype had 12.5% and 25% more multiple births than the AB and BB genotyped ewes, respectively. The observed differences were not significant ($p > 0.05$).

This preliminary study confirmed the presence of a polymorphism at the 5' flanking region of the *IGF1* gene in the Romanov sheep. The absence of significant differences in birth type variation between genotypes may be due to the small number of animals involved, so further investigation with a larger number of sheep is recommended.

EFFECTS OF GENDER AND GONADEXCTOMY ON SOME BIOCHEMICAL SERUM PARAMETERS IN SWEDISH LANDRACE PIGS

Ivona Žura Žaja¹, Petra Jurković², Suzana Milinković Tur¹, Ana Shek-Vugrovečki¹, Mirela Pavić³, Mario Ostović⁴, Sven Menčik⁵, Nina Poljičak Milas⁶, Nino Mačešić⁷, Igor DelVecchio⁸, Nikolino Žura⁹, Marta Radin², Marinko Vilić¹

¹Department of Physiology and Radiobiology, Faculty of Veterinary Medicine, University of Zagreb, Croatia

²Faculty of Veterinary Medicine, University of Zagreb, Croatia, student

³Department of Anatomy, Histology and Embryology, Faculty of Veterinary Medicine, University of Zagreb, Croatia

⁴Department of Animal Hygiene, Behaviour and Welfare, Faculty of Veterinary Medicine, University of Zagreb, Croatia

⁵Department of Animal Breeding and Livestock Production, Faculty of Veterinary Medicine, University of Zagreb, Croatia

⁶Department of Pathological Physiology, Faculty of Veterinary Medicine, University of Zagreb, Croatia

⁷Clinic for Obstetrics and Reproduction, Faculty of Veterinary Medicine, University of Zagreb, Croatia

⁸Požega State Penitentiary, Požega, Croatia

⁹Faculty of Veterinary Medicine, University of Zagreb, Croatia, PhD student

Serum biochemical parameters are used to evaluate animal condition and detect diseases. The gender-related differences in physiological processes, pathophysiology, diagnosis and treatment of diseases have an increasing importance in human medicine, and these differences should be investigated and implemented in animal models. Therefore, the aim of this study was to investigate the effects of gender and gonadectomy in pigs on some blood serum biochemical parameters.

The study was conducted on 20 clinically healthy, sexually mature pigs of the Swedish Landrace breed. The pigs were divided into four groups ($n = 5$ each): intact boars (age 271 ± 4 days), intact gilts (age 270 ± 4 days), castrated boars (age 267 ± 5 days) and castrated gilts (age 269 ± 4 days). Blood samples were taken from the jugular vein by using blood test tubes without anticoagulant. After centrifugation, the serum was separated, and the activities of aspartate aminotransferase (AST), alanine aminotransferase (ALT), and γ -glutamyl transferase (GGT) as well as the concentrations of urea and glucose were determined spectrophotometrically. Data analysis was performed by using the Statistica v. 13.4 software. The normality of data distribution was tested by using the Kolmogorov-Smirnov test, and the significance of the differences between the groups by using an analysis of variance and the Tukey HSD test.

The study results showed that the castrated boars had a significantly higher ($p < 0.05$) urea concentration in the blood serum than the intact boars. In addition, the castrated boars had a significantly lower ($p < 0.05$) serum glucose concentration than the intact boars and gilts. The serum activities of AST, ALT and GGT were the highest in the castrated boars, and the lowest in the intact boars, except for the GGT activity, which was the lowest in the castrated gilts.

It can be concluded that for the interpretation of serum biochemical parameters in pigs, i.e. to ensure an accurate clinical diagnosis and prognosis, gender and gonadectomy should be considered. However, further studies including a higher number of animals are required in order to define the effects of gender and gonadectomy on the values of biochemical parameters in blood serum of pigs more precisely.

ORAL AND CLOACAL BACTERIAL FLORA OF MARGINATED TORTOISES (*TESTUDO MARGINATA*)

Fran Barac¹, Danijela Horvatek Tomić², Ivan Cizelj³, Maja Belić⁴, Željko Gottstein²,
Maja Lukač²

¹Faculty of Veterinary Medicine, University of Zagreb, Croatia, student

²Department of Poultry Diseases with Clinic, Faculty of Veterinary Medicine, University of Zagreb, Croatia

³Zagreb Zoo, Zagreb, Croatia

⁴Department of Pathophysiology, Faculty of Veterinary Medicine, University of Zagreb, Croatia

The marginated tortoise (*Testudo marginata*) is the largest European tortoise belonging to the *Testudinidae* family. Adults are recognised most easily by the intense flaring of the rear of their shells, somewhat resembling a skirt.

The natural range of the marginated tortoise is southern Greece, from the Peloponnesus to Mount Olympus. They are also found in isolated zones of the Balkans and Italy, and northeastern Sardinia. The marginated tortoise lives in more mountainous regions than Hermann's tortoise. It can be found in elevations as high as 1,600 m (5,200 ft). The black colour of the carapace is helpful for survival in this environment, as it allows the tortoise to absorb a great deal of heat in a short time, helping it maintain its body temperature.

According to the International Union for Conservation of Nature (IUCN) Red List Category and Criteria, marginated tortoises have been evaluated as not being a focus of species conservation at the moment (*least concern*).

Since the information about the health condition and pathogens afflicting this species is very scarce, we have examined and swabbed a group of animals confiscated at the Croatian–Serbian border and situated at the facility of the Zagreb Zoo.

Oral cavity and cloacal swabs were taken from 20 animals and the samples were plated on different non-selective and selective agars, and incubated under aerobic conditions at 37 °C for 24 h for detection of aerobic bacteria at the Department of Poultry Diseases with Clinic, Faculty of Veterinary Medicine, University of Zagreb, Croatia.

In total, 8 bacterial species were successfully isolated from the oral cavity, with the predominance of *Morganella morganii* and *Enterococcus avium*. Nine bacterial species were isolated from the cloaca, with the predominance of *Escherichia coli* and *Bacillus cereus*.

The results obtained are similar to those previously reported for bacteria in tortoises, although extensive research projects have seldom been performed.

FIRST AID PROTOCOLS FOR DOLPHINS AND SEA TURTLES IN ADRIATIC SEA DESIGNED WITHIN BLUE PROJECT

Magdalena Kolenc¹, Kim Korpes¹, Maja Lukač², Lada Radin³, Tomislav Gomerčić⁴,
Martina Đuras¹

¹*Department of Anatomy, Histology and Embryology, Faculty of Veterinary Medicine,
University of Zagreb, Croatia*

²*Department of Poultry Diseases with Clinic, Faculty of Veterinary Medicine, University of Zagreb, Croatia*

³*EU Funds Office, Faculty of Veterinary Medicine, University of Zagreb, Croatia*

⁴*Department of Veterinary Biology, Faculty of Veterinary Medicine, University of Zagreb, Croatia*

The Adriatic Sea is an important habitat for dolphins and sea turtles. In this region, interaction with humans occurs frequently and it can be lethal for these animals. Most dolphin injuries and deaths are caused by entanglement in fishing nets and other fishing gear. Sea turtles are affected by the same previously mentioned dangers, to which we need to add hypothermia and motorboat collision. The help given by the finder can often save the injured and/or sick animal.

In order to educate and inform the general public, we have designed first aid protocols for dolphins and sea turtles. These protocols were developed within the project dedicated to the development of community-engaged learning at our faculty (short title the Blue Project). They show step-by-step procedures on how to help an injured or sick animal.

In case of an injured, sick or dead dolphin or sea turtle, the finder should call the emergency number 112 and a proper veterinary care will be organised. During very cold winters, the sea turtles found on the sea surface should be taken out of the water and warmed up. In summer, they need to be placed in the shade. Fishing gear or plastic objects should be carefully removed from entangled dolphins. Stranded dolphins should be covered with wet cloth, and in doing so, covering of the nostrils should be avoided. The finder should be aware of protective measures to minimise the risk of acquiring zoonotic diseases as well as of a possibility of being injured by the animal.

The protocols are available at the Blue Project web page (<https://www.argonauta.hr/plavi-projekt/>) and will be distributed to tourist agencies, police stations, coast guards and veterinary clinics along the Croatian coast and islands in order to raise public awareness.

HOW MANY LYNXES LIVE ON VELEBIT?

Silvia Blašković¹, Lucija Hucika¹, Magda Sindičić¹, Ira Topličanec¹, Ivana Selanec², Ivan Budinski², Vedran Slijepčević³, Josip Tomić⁴, Tomislav Rukavina⁴, Franjo Špalj⁵, Tomislav Gomerčić¹

¹Faculty of Veterinary Medicine, University of Zagreb, Croatia

²Association BIOM, Zagreb, Croatia

³Karlovac University of Applied Sciences, Karlovac, Croatia

⁴Velebit Nature Park, Croatia

⁵Paklenica National Park, Croatia

The Eurasian lynx (*Lynx lynx*) is one of the most endangered mammals in Croatia. The autochthonous Dinaric lynx population was exterminated at the end of the 19th century and today's population was established from six individuals reintroduced from Slovakia to Slovenia in 1973. The population remained isolated and today is highly endangered due to inbreeding depression. Until recently, a national monitoring system was not established and scientific data about the distribution and population size were not available. The most efficient method for lynx monitoring is camera traps. Each lynx has a unique pelt colour and pattern, so an individual animal can be identified based on photographs. Therefore, using a network of camera traps, the population distribution can be monitored and the minimal population size can be estimated.

The aim of our research was to determine the minimal number of lynxes in the Velebit Nature Park and Paklenica National Park, since this information is necessary for effective management and protection of the species. In the period from 20 March 2018 to 21 March 2019, a total of 54 camera traps were active in the research area. The camera traps were placed at locations used by lynxes for marking their territory, on forest roads and other locations where lynxes were seen or signs of their presence were noticed.

During 6,141 days, lynxes were recorded in 85 events. The photographs were compared to each other and individual lynxes were identified. We identified 16 individuals, of which for 6 lynxes we had photos of both sides of the body, for 5 individuals only of the left side and for another 5 individuals only photos of the right side.

According to the collected data, the estimated number of lynxes in the monitored area is probably from 13 to 18 individuals. All signs of lynx presence are archived in a database publicly available at <http://vef.lynx.hr>.

DIVERSITY OF MAJOR HISTOCOMPATIBILITY COMPLEX CLASS II GENES IN GOLDEN JACKAL (*CANIS AUREUS*) FROM SERBIA

Haidi Arbanasić¹, Duško Ćirović², Ida Svetličić¹, Veronika Lončar¹, Kate Šešelja³, Željka Celinščak¹, Tihomir Florijančić⁴, Ivica Bošković⁴, Ana Galov¹

¹Faculty of Science, University of Zagreb, Croatia

²Faculty of Biology, University of Belgrade, Serbia

³Ruder Bošković Institute, Zagreb, Croatia

⁴Faculty of Agrobiotechnical Sciences Osijek, Josip Juraj Strossmayer University of Osijek, Croatia

The golden jackal is a canid species currently distributed throughout the southeastern, central and northern Europe. The Serbian population has been growing rapidly since the early 1980s. Previous research was done solely on neutral markers and the results indicated a lower genetic variability of the Serbian population. Given the jackal's recent expansion, it is important to investigate the variability of the adaptive loci in order to explore the population's potential for adaptation. Genes of the major histocompatibility complex (MHC) are one of the most polymorphic coding regions of the vertebrate genome. The role of MHC genes is to encode the receptors responsible for the presentation of antigens to T lymphocytes, which is crucial for specific immune response.

DNA was extracted from 36 individuals that were legally shot in northwestern, eastern and southeastern Serbia. MHC class II loci DLA-DRB1, DQA1 and DQB1 were amplified and sequenced. A newly found allele was confirmed by molecular cloning and three-locus haplotypes were assigned to each individual.

The analysis revealed 4 DQA, 3 DQB and 4 DRB alleles. Allele DQA1*00101 was found for the first time in the golden jackal species, exclusively in 1 individual and, surprisingly, in homozygotic form. The found alleles formed 6 different three-locus haplotypes.

Our results suggest that the Serbian jackal population might have a higher MHC diversity than the Croatian population, as 2 additional alleles were detected on the DQA locus despite the significantly smaller sample size.

WILDLIFE AS DISEASE RESERVOIR – OBSERVATIONS OF WILDLIFE VETERINARIANDean Konjević¹, Miljenko Bujanić¹, Marta Kiš¹, Nevijo Zdolec¹¹Faculty of Veterinary Medicine, University of Zagreb, Croatia

The definition of disease reservoirs still varies from very broad to specific ones. According to the more specific ones, reservoirs are organisms in which an infectious agent lives and multiplies, without causing any harm to it. According to Zaharija, reservoirs have a tendency to maintain certain pathogens permanently, while the source of infection is more of a temporary significance. Anyhow, according to some data, approximately three quarters of pathogens cross from wildlife to domestic animals or humans, resulting in a frequent denotation of wildlife as disease reservoirs. The aim of this paper is to clarify whether certain wild species should be so easily characterised as the reservoirs of disease in various scientific papers.

This paper contains i) a retrospective analysis of literature on certain diseases comparing the previously accepted status of wildlife as reservoirs with present conclusions obtained by the use of new diagnostic tools; and ii) an analysis of wild boar tonsils for the presence of *Yersinia enterocolitica*. In the second part, a total of 37 wild boar tonsils collected at the state open hunting grounds Črnovšćak and Prolom were analysed following the HRN EN ISO 10273 method coupled with chromogenic media CHROMagar *Y. enterocolitica*. From only 12 samples presumptive *Yersinia*-like colonies were selected and subjected to a MALDI-TOF MS identification. Ten isolates were identified as *Serratia marcescens*, and 2 as *Serratia ureilytica* (score value 2.077–2.320).

The data obtained by the review of the literature and our analysis of wild boar tonsils show that the term reservoir should be used more carefully in the case of wildlife. The introduction of new diagnostic tools enables a detailed identification of isolated organisms, which, coupled with epidemiological and especially molecular epidemiology studies sheds a new light on the potential role of wildlife in disease maintenance and transmission.

Acknowledgement: Authors are grateful to Ana Konjević for technical assistance.

JUBA – EXTRAORDINARY CHIMPANZEE FROM ZAGREB ZOO: CRANIOMETRICAL AND RADIOLOGICAL CHARACTERISTICS

**Kim Korpes¹, Hrvoje Capak², Damir Skok³, Jadranko Boras³, Ingeborg Bata³,
Tajana Trbojević Vukičević¹, Martina Đuras¹**

*¹Department of Anatomy, Histology and Embryology,
Faculty of Veterinary Medicine, University of Zagreb, Croatia*

*²Department of Radiology, Ultrasound Diagnostic and Physical Therapy,
Faculty of Veterinary Medicine, University of Zagreb, Croatia*

³Zagreb Zoo, Zagreb, Croatia

A chimpanzee named Juba was born in the Hannover Zoo and moved to the Zagreb Zoo, where she died in July 2017, at the age of 32. Juba was a dominant female in the group. She was always the first to approach food and very interested in enrichment objects newly added to their habitat. Juba developed perceptual-motor abilities well and was unique for her painting skills. During the years spent in the Zoo, she gave birth to Sara in 1999 and Meggy in 2007. Both times she mated with the same male, Boris. Juba suffered from chronic cardiovascular and respiratory diseases and died due to severe haemorrhagic enteritis.

After the necropsy, her skeleton was prepared for an osteological examination and will be displayed for education purposes in the Zagreb Zoo. The skull was measured to determine the basic craniometric values by using callipers. Osteological abnormalities were determined during the macroscopic inspection of the skull. The skull X-ray imaging was performed to confirm these abnormalities.

The maximum length of Juba's skull was 195.0 mm, while the maximum width was 101.7 mm. The right and left orbital indexes were 112.97 and 88.40, respectively. The skull was asymmetric as there was a right shift of the sagittal plane. The asymmetry was followed by a more ventral position of the right temporomandibular joint than of the left one. The right infraorbital margin was more concave in shape than the left one. The vomer deviated to the right. The third left upper molar was retained. All other maxillary and mandibular teeth were fully developed.

We can only presume that all of the mentioned osteological and radiological abnormalities had developed due to the molar retention since other potential causes were not found. As far as we know, this is the first reported craniometrical description of a chimpanzee.

LIPOGENESIS AND HEPATIC CD36 EXPRESSION IN RESPONSE TO CAFETERIA AND HIGH-FRUCTOSE DIET

Petra Roškarić,¹ Tomislav Mašek², Maja Maurić³, Josip Barišić⁴, Krešimir Severin⁵, Kristina Starčević¹

¹Department of Chemistry and Biochemistry, Faculty of Veterinary Medicine, University of Zagreb, Croatia

²Department of Animal Nutrition and Dietetics, Faculty of Veterinary Medicine, University of Zagreb, Croatia

³Department of Animal Breeding and Livestock Production, Faculty of Veterinary Medicine, University of Zagreb, Croatia

⁴Laboratory for Biotechnology in Aquaculture, Division of Materials Chemistry, Ruđer Bošković Institute, Zagreb, Croatia

⁵Department of Forensic and State Veterinary Medicine, Faculty of Veterinary Medicine, University of Zagreb, Croatia

Selecting an adequate experimental model for metabolic syndrome can be challenging due to its multifactorial nature. The most used experimental models have been high-fructose and cafeteria diets. The aim of our investigation was to determine differences between these two models in the hepatic expression of CD36 and the fatty acid profile of total lipids. Additionally, we tested sex as a variable in both models of metabolic syndrome.

Wistar rats (15 male and 15 female, $n = 5$ per group) were divided into control group (CON), high fructose group (HF, 15% of fructose in the drinking water) and cafeteria diet group (CAF, basal diet and cafeteria diet in the 1:1 ratio). The experiment lasted for 16 weeks. The analysis of hepatic fatty acid composition was performed by gas chromatography. Lipid peroxidation was determined by the MDA-TBARS method using high performance liquid chromatography. The liver triglyceride content was measured by a colorimetric quantification kit. The expression of the CD36 gene was assessed by qPCR. The data were compared by the analysis of variance and Tukey post hoc test using the GraphPad Prism 8 software, and the significance was set to $p < 0.05$.

The fatty acid profile of liver fatty acids was significantly different between the CAF and HF diets. The most interesting differences were a decrease in the EPA content and an increase in the content of n6DPA in the CAF diet compared with the HF diet. An increase in the n6DPA content was also higher in the female rats than in the male rats. Lipid peroxidation, expressed as MDA-TBARS, was significantly higher in the CAF group than in the CON and HF groups. Both experimental diets led to the accumulation of triglycerides in the liver. The expression of CD36 was significantly increased in the male and female rats fed with the CAF diet.

The results showed that the experimental models of metabolic syndrome differ significantly in lipid metabolism and lipid peroxidation. Moreover, male and female rats respond differently to experimental diets.

MICROCHIP MIGRATION IN DOGS – IS THERE BREED PREDISPOSITION?

Tihana Josipović¹, Lucija Ciglar¹, Maša Efendić², Hrvoje Capak³

¹Faculty of Veterinary Medicine, University of Zagreb, Croatia, student

²Faculty of Veterinary Medicine, University of Zagreb, Croatia, PhD student and intern

³Department of Radiology, Ultrasound Diagnostic and Physical Therapy,
Faculty of Veterinary Medicine, University of Zagreb, Croatia

Microchipping is recognised as the best identification method in dogs. Nowadays, there is a strict obligation for owners to microchip their own animals. Although chip transducers are well developed and sophisticated, there are some reports about the incidence and potential for microchip migration in different mammal and avian species worldwide.

The aim of this study is to investigate the influence of breed on microchip migration in dogs. The study included a randomised archive search of 1,000 canine neck X-ray images. All of the images were evaluated to find the microchip position. In Croatia, the left side of the neck is the prescribed application region. Any dislocation from this region is classified as microchip migration.

Migrations were found in 177 (17.7%) of the dogs, and other microchipping problems such as multiple or missing transducers were confirmed in 16 (1.6%) of the dogs. In the statistical analysis, the breeds with less than 3 animals were excluded. Mixed-breed dogs were dominant, with the total number of 304 (30.4%). The first three breeds in the number of animals presented were Maltese (75 dogs), Labrador Retrievers (45 dogs) and Shi Tzu (37 dogs). At the same time, these breeds had a low incidence of microchip migration (8.1%; 22.2%; and 8.3%, respectively). The breeds with a high incidence of microchip migration were Belgian Shepherd Malinois (55.5%), German Shepherd (53.3%) and Bernese Mountain Dog (50%). Following these results, we can presume that large breed dogs have a potential for microchip migration. Some of the possible reasons can be a large neck region, an increased physical activity or the body condition in comparison to small and toy dog breeds (especially brachiocephalic ones). Indeed, the majority of mixed-breed dogs with microchip migration in our study were classified into the group from 10 to 25 kg (middle body weight).

Future studies with a larger number of animals are needed to find specific predisposition factors, and finding the causes of microchip migration would also be helpful.

FALSE FRIENDS IN VETERINARY TERMINOLOGY: IS INFECTION ALWAYS INFECTION?

Željana Klječanin Franić¹, Kristian Lewis², Juliette Alexandra Magoga¹, Dean Konjević¹

¹Faculty of Veterinary Medicine, University of Zagreb, Croatia

²Institute of Croatian Language and Linguistics, Zagreb, Croatia

Internationalisms, words originating from the Latin or Greek language, constitute a significant proportion of veterinary terminology. They are very important in professional terminology as their common base enables an easier understanding in different languages, facilitating scientific and professional communication. However, with the development of languages, certain internationalisms have gained different meanings in different languages and professional terminologies. The same or similar words with different meanings are therefore termed "false friends".

In this study we have analysed false friends among the internationalisms that are found in veterinary terminology in Croatian, English and French. The corpus of false friends from scientific and professional veterinary literature, medical dictionaries and term bases was extracted and analysed.

Some of the analysed examples are a part of the fundamental terminology of the profession, and their meaning may differ in all three languages. For example, the term *medicina* in the Croatian language almost exclusively refers to the science of the treatment of diseases, whilst *medicine* in English is primarily a drug, and the word *médecin* in French means a doctor. An animal that harbours parasites is *infected* in the English and French terminology, while in Croatian it is *invaded*. The false friends observed could represent linguistic traps for translators and veterinarians, as verbatim translation can lead to numerous mistakes in translation and, consequently, to misunderstandings. Furthermore, the acceptance of such word pairs may even spread the inappropriate use of professional terms.

Here, on the basis of the examples of false friends in veterinary terminology and the potential mistakes in translation that they can cause, we have pointed out the importance of the use of proper terminology in scientific communication and professional language, which demands accuracy, uniformity and terminological standardisation.

OVERVIEW AND PRELIMINARY RESULTS OF SOFTVETS PROJECT

Lada Radin¹, Evelyn Steinberg², Ingrid Preusche², Rudolf Dömötör³, Jelka Zabavnik Piano⁴, Mira Mandoki⁵, Christin Kleinsorgen⁶

¹Faculty of Veterinary Medicine, University of Zagreb, Croatia

²Office of the Vice-Rectorate for Study Affairs, University of Veterinary Medicine, Vienna, Austria

³Vienna University of Economics and Business, Vienna, Austria

⁴Veterinary Faculty, University of Ljubljana, Slovenia

⁵University of Veterinary Medicine Budapest, Hungary

⁶E-Learning Department, University of Veterinary Medicine Hannover, Foundation, Hannover, Germany

According to research and surveys among veterinarians, there is an increasing demand for the introduction of life skills training in veterinary education. Life skills are essential for an effective performance in everyday situations, but they are also a part of a continuous modernisation of the veterinary profession. New forms of employability, flexibility and security for veterinarians are necessary for thriving of the profession.

The SOFTVETS project aims to create a framework that will equip veterinary students with skills to cope with challenges imposed on them by the ever-changing world and the enormous strain the profession puts on them. The competence model and curriculum are therefore organised in three sections: communication skills, entrepreneurship skills and digital skills.

First, a set of competences was created by the project team in alignment with the IQM-HE-Handbook through an iterative process of literature research, experts' discussions and reviews (Output 1). This is followed by a definition of learning outcomes and development of an ideal curriculum (Output 2). Then, a training concept for the education of teachers involved in skills training will be designed and executed (Output 3). Finally, within three veterinary establishments, a pilot implementation of selected modules is conducted and evaluated (Output 4). The outputs are developed in coordination with a students' association (IVSA) and an accreditation authority for veterinary education establishments within Europe (EAEVE).

The established SOFTVETS competence model now includes ten communication competences, eight digital competences and nine entrepreneurship competences addressing cognitive and practical aspects on four levels (Foundation, Intermediate, Advanced, Expert).

The SOFTVETS project creates a framework for a continuous innovative advancement of veterinary undergraduate curricula in Europe by introducing a life competence training programme.

ANAESTHESIA PROTOCOL FOR LAPAROSCOPIC OVARIECTOMY IN BITCH DIAGNOSED WITH IMMUNE-MEDIATED MENINGOENCEPHALITIS

Katarina Marjanović¹, Iva Bacan¹, Tugomir Karadjole², Nino Maćešić², Ivan Folnožić², Juraj Šavorić², Ivan Butković²

¹Faculty of Veterinary Medicine, University of Zagreb, Croatia, student

²Clinic for Obstetrics and Reproduction, Faculty of Veterinary Medicine, University of Zagreb, Croatia

A Parson Jack Russell Terrier (Fila), a 4-year-old intact female, was referred to the Clinic for a clinical examination prior to laparoscopic ovariectomy. The patient had a history of suspected hormone-induced atopic dermatitis and immune-mediated meningoencephalitis.

The bitch underwent the physical examination, which was unremarkable. Haematology and serum biochemistry profile showed no significant abnormalities. Other diagnostic procedures, X-ray and electrocardiography (ECG) were all normal as well.

Total intravenous anaesthesia (TIVA) has been suggested as the preferred anaesthetic technique in patients with a risk of increased intracranial pressure. Inhalation anaesthetics affect intracranial pressure, which can be increased through a direct vasodilation of cerebral vasculature. Considering the mentioned, a laparoscopic ovariectomy and punch skin biopsy were performed following the propofol-based TIVA protocol.

The bitch was premedicated with midazolam (0.3 mg/kg IM) and methadone (0.5 mg/kg IM). General anaesthesia was induced with propofol (3 mg/kg IV), followed by endotracheal intubation. The patient was connected to the anaesthetic machine with a rebreathing circuit, with the oxygen flow of 2.0 L/min. General anaesthesia was maintained with propofol (0.2 mg/kg/min IV). During the procedure, analgesia was provided by using boluses of fentanyl (5 µg/kg IV). Possible complications during the surgery were hypoventilation, hypoxaemia, respiratory depression, bradycardia and hypotension. Patient monitoring included capnometry, pulse oximetry, oscillometric non-invasive arterial blood pressure measurement and ECG.

The histopathology findings showed epidermal and follicular atrophy and orthokeratotic hyperkeratosis, which is indicative for endocrine-induced dermatopathy.

In conclusion, the propofol-based TIVA protocol for the presented case was shown to be a great choice due to advantages such as maintenance of oxygen delivery to the brain, and to avoid potential increases in intracranial pressure from inhalation agents.

RETROSPECTIVE STUDY OF PULMONARY HYPERTENSION IN DOGS EXAMINED AT CLINIC FOR INTERNAL DISEASES, FACULTY OF VETERINARY MEDICINE, ZAGREB (2016 - 2019)

Ivana Filipčić¹, Ines Jović², Jelena Gotić², Iva Šmit², Filip Kajin², Vesna Matijatko², Ivana Kiš², Mirna Brkljačić², Marin Torti²

¹*Faculty of Veterinary Medicine, University of Zagreb, Croatia, student*

²*Clinic for Internal Diseases, Faculty of Veterinary Medicine, University of Zagreb, Croatia*

In veterinary medicine, pulmonary hypertension (PH) is defined as echocardiographically estimated pulmonary arterial systolic pressure (based on peak systolic tricuspid regurgitation (TR) gradient) greater than 30 mmHg. The severity of PH is classified as mild (≥ 31.4 to < 50 mmHg), moderate (50–75 mmHg) or severe (> 75 mmHg). PH can be further classified as pulmonary arterial hypertension (PAH), resulting from abnormalities on the arterial side of the pulmonary vascular system (e.g. heartworm disease, congenital systemic to pulmonary shunts), or pulmonary venous hypertension (PVH), associated mainly with left-sided heart disease, due to valvular degeneration or cardiomyopathy. The pathophysiology of PAH is multifactorial and results from an imbalance of endogenous and exogenous pulmonary artery vasodilators and vasoconstrictors, whereas the pathophysiology of PVH with left-sided heart disease derives from hypertension caused by increased left atrial pressures, and vasoconstriction-associated hypoxia.

The aim of this retrospective study of dogs with PH referred to the Clinic for Internal Diseases of the Faculty of Veterinary Medicine, Zagreb, was to characterise the population of dogs with PH, determine whether they had PAH or PVH, describe clinical signs, therapy and survival time.

All of the dogs ($n = 38$, 15 females, 23 males) underwent a full physical and echocardiographic examination. Most of the dogs (84%) were less than 10 kg in body weight, were purebred (76%), older than 10 years (81%) and initially presented because of respiratory distress ($n = 18$) or persistent cough ($n = 15$). Only 21% of the dogs had PVH associated with left-sided heart disease and 79% had PAH. Heart murmur was detected in 63% of the dogs. Most of the dogs had moderate PH.

To conclude, pulmonary hypertension is a disease of miniature to small-breed dogs, in which males are more commonly affected. Respiratory distress and cough where a sign of PAH rather than of left-sided heart disease.

PROTEOMIC ANALYSIS OF PLEURAL EFFUSION AND ITS POTENTIAL IN CLINICAL DIAGNOSTICS OF CANINE PULMONARY ADENOCARCINOMA

Valerija Benko¹, Asier Galan Cousillas², Jurica Tršan¹, Vladimir Mrljak¹, Marin Torti¹

¹*Clinic for Internal Diseases, Faculty of Veterinary Medicine, University of Zagreb, Croatia*

²*AZTI Technologia, Marine and food research, Spain*

Patients with pleural, pericardial and peritoneal effusions can be challenging, but the effusion analysis can be an extremely useful tool as the initial step in making a diagnosis of malignancy or a septic condition, in both human and veterinary medicine. There have been very few proteomic studies of effusions in veterinary medicine. Extracellular vesicles such as exosomes have an important role in intracellular communication, and may carry specific sets of proteins, lipids, miRNA, mRNA and DNA.

In this study, we performed a semiquantitative characterisation of exosomal marker proteins flotillin-1, adiponectin, VCAM-1 and CD63 in 2 dogs with pulmonary adenocarcinoma. The samples of both blood serum and pleural effusion in the studied patients and serum from a control animal were analysed. The exosomal proteins were tested by using the Western blot method on the VWR Mini Vertical PAGE System (VWR International Ltd., Northern Ireland) and on the Electroblothing System (Mini Electroblothing System, Biovit, UK). The samples were loaded onto size exclusion chromatography columns (qEV, IZON Oxford) to separate extracellular vesicles from soluble proteins.

Western blot of isolated extracellular vesicles showed significantly increased ($p < 0.05$) serum levels of CD63, flotillin-1 and adiponectin in the dogs with adenocarcinoma compared to the healthy dog. This finding could indicate that the prevalence of these extracellular vesicles is due to the tumour itself, or due to the organism's reaction to the tumour. The presence of these vesicles in pleural effusion could also be documented, but their levels were not indicative of the disease process.

We found evidence that serum and effusions from patients with pulmonary adenocarcinoma contain extracellular vesicles with different protein compositions. Further analysis of size comprehensive proteomic characterisation in a larger population of patients could result in the identification of potential biomarkers for an early detection of adenocarcinoma.

BACTERIAL PATHOGENS AND ANTIMICROBIAL SUSCEPTIBILITY PATTERNS IN URINARY TRACT INFECTIONS IN DOGS

Filip Kajin¹, Marin Torti¹, Iva Šmit¹, Ines Jović¹, Martina Crnogaj¹, Jelena Gotić¹, Mirna Brkljačić¹, Vesna Matijatko¹, Ivana Kiš¹, Jurica Tršan¹, Ivana Filipčić², Zrinka Štritof³

¹Clinic for Internal Diseases, Faculty of Veterinary Medicine, University of Zagreb, Croatia

²Faculty of Veterinary Medicine, University of Zagreb, Croatia, student

³Department of Microbiology and Infectious Diseases with Clinic, Faculty of Veterinary Medicine, University of Zagreb, Croatia

Bacterial urinary tract inflammation (UTI) is a common cause of morbidity in dogs and among the leading reasons for antimicrobial use. An improper therapy leads to treatment failure and favours the development of antimicrobial resistance. The International Society for Companion Animal Infectious Diseases (ISCAID) provides guidelines and recommendations for the diagnosis and treatment of UTI. Multidrug-resistant (MDR) bacteria, non-susceptible to at least one agent in three or more antimicrobial categories, have become a major challenge in both veterinary and human medicine, thus presenting one of the most important public health issues. The surveillance of local pathogen susceptibility patterns is essential for an optimal empirical therapy.

The aim of this retrospective study was to analyse canine urinary tract pathogens and their antimicrobial susceptibility patterns. The study included 275 urine samples obtained from dogs admitted at the Clinic for Internal Diseases of the Faculty of Veterinary Medicine, Zagreb, Croatia, in the period from 1 January 2018 to 1 May 2019.

The culture of 192 (70%) urines was negative, while 83 (30%) yielded a significant bacterial growth. The most commonly identified bacteria were: *Escherichia coli* (41%), *Proteus* spp. (19%) and *Staphylococcus pseudintermedius* (10%), with the incidence of MDR among them being 17%, 41% and 44%, respectively. Resistance to one or more β -lactam antibiotics (most notably amoxicillin) was found in 83% of *E. coli* and 55% of *S. pseudintermedius*, while 47% of *Proteus* spp. were resistant to potentiated sulphonamides. These findings raise concern, since those are the first-choice antimicrobials for the treatment of sporadic and recurrent bacterial cystitis as recommended by the ISCAID.

This study serves as a reminder that clinicians should be aware of local (ideally clinic-level) antimicrobial susceptibility patterns to help guide empirical choices.

EVALUATION OF URINALYSIS TEST STRIPS IN DETECTION OF PRESENCE OF BLOOD CELLS IN CANINE URINE

Marina Prišlin¹, Fran Šimac¹, Blanka Beer Ljubić², Ivana Kiš², Jasna Aladrović³

¹Faculty of Veterinary Medicine, University of Zagreb, Croatia, student

²Clinic for Internal Diseases, Faculty of Veterinary Medicine, University of Zagreb, Croatia

³Department of Physiology and Radiobiology, Faculty of Veterinary Medicine, University of Zagreb, Croatia

In the routine urinalysis, urine test strip (UTS) and sediment evaluation are used to determine the presence of red blood cells (RBC) and white blood cells (WBC) in the urine. Since UTS is an affordable and simple laboratory method that can guide our diagnostic plan, the aim of this study was to evaluate the UTS accuracy in determining the presence of blood cells in the urine of dogs regardless of patients' diagnoses and in particular for patients with a urinary and endocrine problem, since these patients are generally tested.

The analyses of 143 urine samples from patients with problems in different organ systems were performed in the Clinic for Internal Diseases, Faculty of Veterinary Medicine, University of Zagreb. The samples were analysed by using UTS (Siemens Multistix 10SG) and the standard microscopic sediment analysis. All the patients were analysed as a group, regardless of the diagnoses, but patients with the problem localised in the urinary system (PUD; n = 42) and the endocrine system (PED; n = 26) were additionally evaluated as two separate groups.

In all the patients, both PUD and PED, the sensitivity of UTS for RBC was high (> 83%), while the sensitivity for WBC in PED was very low (33%). The specificity for WBC findings in all the groups was above 88%. The lowest specificity for RBC was found in the PUD group (67%). The prevalence of RBC findings was 52% and WBC 24% in all the patients. The highest prevalence of RBC findings was evaluated in PUD (81%). The RBC and WBC findings accuracy for all the patients, both PUD and PED, was almost uniform (> 75%). Positive predictive values for both RBC and WBC findings in all the patients and PUD were above 75%, while in PED positive predictive values for RBC finding were 45%. Negative predictive values for all the patients, both PUD and PED, were above 75%.

In everyday clinic work, we can assume the accuracy of UTS (Siemens Multistix 10SG) for the detection of RBC and WBC findings is above 80%, except for endocrine disease patients, where sediment evaluation is a necessity.

PREVALENCE OF *DIROFILARIA* SPP. IN RANDOMLY CHOSEN DOGSLea Lovrić¹, Snježana Lučinger¹, Vesna Matijatko², Ivana Kiš², Tatjana Živičnjak¹¹Department of Parasitology and Parasitic Diseases with Clinic, Faculty of Veterinary Medicine, University of Zagreb, Croatia²Clinic for Internal Diseases, Faculty of Veterinary Medicine, University of Zagreb, Croatia

Dirofilariosis is an emerging mosquito-borne parasitic zoonosis affecting primarily dogs and it is caused by filarial nematodes *Dirofilaria immitis* and *D. repens*, respectively. Although *D. repens* does not present a serious threat to dogs' health as *D. immitis*, due to its zoonotic potential and more frequent findings in humans in Croatia, it is important to differentiate between these two species. The objective of this study was to assess the prevalence of *Dirofilaria* spp. infection in randomly chosen dogs and to identify *Dirofilaria* species.

During the period from July 2017 to March 2019, our laboratory received a total of 631 canine whole blood (with EDTA) samples that were subjected to a modified Knott's test for detecting and differentiating between *D. immitis* and *D. repens* microfilariae. Additionally, 533 of all the samples were screened for *D. immitis* circulating antigen using the FASTest® HW Antigen (MEGACOR) for recognition of a hidden infection.

Overall, 62/631 (9.82%) blood samples were positive for microfilariae based on a modified Knott's test. A morphometric analysis revealed 61 (98.38%) samples with *D. repens* microfilariae, whereas *D. immitis* microfilariae were recorded in 2 (3.22%) samples. Screening for *D. immitis* circulating antigen resulted in 3 (0.56%) positive samples out of 533 tested.

This study revealed a higher prevalence of *D. repens* than of *D. immitis* in dogs, which is in accordance with former studies carried out in Croatia. Further monitoring could provide a more accurate assessment of the epidemiological situation, thus resulting in raising the awareness of the necessity for dirofilariosis detection, medication and prevention as well as lowering the risk of dogs becoming reservoirs for human infections. Veterinarians and dog owners should be encouraged to practice a regular monthly application of insect repellents and microfilaricides in order to prevent the transmission and spreading of both parasites.

FIRST REPORT OF *BABESIA GIBSONI* AND *BABESIA VULPES* IN SYMPTOMATIC DOGS FROM CROATIA: FROM CLINICS TO THERAPY

Daria Jurković¹, Vlatka-Antonija Csik², Branimir Rebselj³, Ana Petak⁴, Marija Stublić¹, Relja Beck¹

¹Laboratory for Parasitology, Department for Bacteriology and Parasitology, Croatian Veterinary Institute, Zagreb, Croatia

²Ljubimac Veterinary Clinic, Zagreb, Croatia

³Veterina Branimir Veterinary Clinic, Zagreb, Croatia

⁴Clinic for Internal Diseases, Faculty of Veterinary Medicine, University of Zagreb, Croatia

Piroplasmosis is one of the most important tick-borne diseases in dogs. Except the well-known *Babesia canis*, small piroplasms *B. gibsoni* and *B. vulpes* have been detected in asymptomatic dogs in Croatia. In this study, we are reporting the first *B. gibsoni* and *B. vulpes* clinical cases in Croatia, their molecular characterisation and treatment efficiency.

Blood samples of 4 dogs with confirmed small merozoites showing anaemia and thrombocytopenia were analysed using SNAP®4DX® Plus, SNAP® Leishmania and conventional PCR to *Anaplasma/Ehrlichia*, *Babesia/Theileria* and *Mycoplasma spp.* The positive samples were sequenced.

Small merozoites were initially assumed to be *B. gibsoni*. Sequencing revealed *B. gibsoni* in 3 dogs (Dog 1, 2, 3) and *B. vulpes* in 1 dog (Dog 4).

Lethargy, weakness, pale mucous membranes, splenomegaly, anaemia and severe thrombocytopenia were observed in 2 of the *B. gibsoni*-infected dogs (Dog 1, 2). The first one had a history of long-term immunosuppressive therapy due to cataract. Dog 3, co-infected with *M. haemtoparvum* and *B. gibsoni*, had chronic skin problems with scars all over the body. The *B. vulpes*-infected dog showed only anorexia, lethargy and anaemia.

Several drug combinations (imidocarb dipropionate, imidocarb dipropionate and doxycycline in Dog 1 and 2; doxycycline, metronidazole and enrofloxacin in Dog 1) in the *B. gibsoni* cases resulted in an improvement of the health condition, but not in the elimination of pathogens. The final combination of atovaquone and azithromycin resulted in full clinical recovery, parasite clearance and permanent health improvement during the follow-up period (Dog 1 and 3). In the case of *B. vulpes* infection, doxycycline administration suggested an apparent clinical recovery.

The described cases clearly showed that small piroplasms should always be included in the differential diagnosis in cases of anorexia, lethargy, weakness, anaemia and thrombocytopenia. Due to an almost identical morphology of merozoites, the species have to be confirmed by using molecular methods because of a different drug efficiency.

MOLECULAR DIAGNOSTICS AND PHYLOGENETIC ANALYSIS OF FELINE IMMUNODEFICIENCY VIRUS *ENV* GENE IN NATURALLY INFECTED CATS IN CROATIA

Valentina Kunić¹, Vesna Mojčec Perko², Zrinka Štritof², Suzana Hadina², Josipa Habuš², Vladimir Stevanović², Krešimir Martinković², Luka Radmanić², Iva Zečević², Matko Perharić²

¹B. Braun Adria d.o.o., Zagreb, Croatia

²Department of Microbiology and Infectious Diseases with Clinic, Faculty of Veterinary Medicine, University of Zagreb, Croatia

Feline immunodeficiency virus (FIV) is an important viral infection of domestic cats, which occurs worldwide. Like other members of the genus *Lentivirus*, FIV causes a lifelong infection after the integration of provirus into host cell genome. The virus is mainly transmitted by parenteral inoculation of the virus present in saliva and blood through bites and fight wounds. The aim of this study was to determine persistent FIV infection by proving the specific nucleotide sequences of the provirus *env* gene as well as to determine the phylogenetic relationships of FIV sequences identified in Croatia.

The research was conducted on 14 FIV-positive cats. The infection was confirmed by using the commercially available IDEXX SNAP Combo Plus test. The test detected a FIV-specific antibody to viral antigen gp40 in the blood samples. Prior to molecular testing, DNA was extracted from EDTA-treated cat whole blood using the QIAamp DNA Mini Kit. The proviral *env* gene was amplified with primers FIV-7316F (5' - ATA CCA AAA TGT GGA TGG TG - 3') and FIV-7868R (5' - TGC AAG ACC AAT TTC CAG CA - 3'). An agarose gel electrophoresis was performed to visualise PCR product. All 14 positive PCR products were sequenced in both directions by using MacroGen Europe.

A persistent infection was proved in 14 FIV serologically positive cats by using the stated molecular method. Phylogenetic analyses of the multiplied sequence of FIV proviral *env* gene, along with the sequences of the *env* gene from the gene bank, identified the phylogenetic affiliation of all 14 isolates from the territory of the Republic of Croatia to the viral subtype B. In addition to belonging to the viral B subtype, the isolates were phylogenetically shown to correlate with other isolates from the nearest geographic region. The majority of the nucleotide sequences obtained within this research show the highest resemblance with the isolates from Austria. Although phylogenetically all 14 nucleotide sequences of the proviral *env* gene belong to the B subtype, their mutual heterogeneity was also observed.

USE OF RAW MEAT-BASED DIETARY REGIMES (BARF) IN DOGS IN CROATIA

Diana Brozić¹, Tatjana Živičnjak², Lea Lovrić², Josipa Habuš³, Suzana Hađina³,
Snježana Lučinger², Hrvoje Valpotić¹, Matko Perharić³, Zrinka Štritof³

¹Department of Animal Nutrition and Dietetics, Faculty of Veterinary Medicine, University of Zagreb, Croatia

²Department of Parasitology and Parasitic Diseases with Clinic, Faculty of Veterinary Medicine,
University of Zagreb, Croatia

³Department of Microbiology and Infectious Diseases with Clinic, Faculty of Veterinary Medicine,
University of Zagreb, Croatia

Feeding dogs with raw meat-based diets, also known as biologically appropriate raw food (BARF) diets, has been a trend that has gained a significant popularity over the last decade. The aim of this study was to provide information about dietary regimes and the use of BARF diets in dogs in Croatia and, additionally, to identify the owners' motivation to choose the BARF feeding regime.

A questionnaire was designed to assess feeding practices in dogs fed BARF diets. To be included in the analysis, the dogs must have had been fed with a BARF diet retrospectively for a minimum of two months. Data were analysed using the Fisher exact test, and $p < 0.05$ was considered to be significant (GraphPad Software, San Diego, USA).

In total, 95 questionnaires that met the inclusion criteria were collected. The study cohort consisted of female (64%) and male (36%), mostly purebred (68%) dogs with a mean age of 4.5 ± 3.2 years and 19.6 ± 12.5 kilos in weight. The owners changed their respective dog's diet to the BARF feeding regime as a result of a chronic condition (26%), for palatability (27%), for the perceived improved level of energy (21%), and its composition (17%). The majority of the dogs were fed a homemade (HM) BARF diet (58%) and 42% were fed a commercially available (COM) BARF diet. The owners reported a sporadic occurrence of gastrointestinal (GI) symptoms more frequently in the period of the previous two months when the dogs were fed HM BARF diets ($p = 0.0415$). Also, they were more likely to give their dogs raw meat that has not been previously frozen ($p < 0.0001$). There were 37% of the owners using an extruded diet alongside the BARF diet. The owners of the dogs that had a manifestation of allergies or intolerances in the past were more likely to use BARF diets without the addition of extruded diets ($p = 0.038$).

There is a high frequency of using HM BARF diets as the BARF feeding regime of choice. Therefore, it is of high importance to communicate the risk of possible nutritional imbalances as well as a higher incidence of GI symptoms when feeding HM BARF diets.

TRAPPED NEUTROPHIL SYNDROME – A CASE REPORT

Iva Zečević¹, Zrinka Štritof¹, Suzana Hadina¹, Vladimir Stevanović¹, Krešimir Martinković¹, Matko Perharić¹, Luka Radmanić¹, Josipa Habuš¹

¹Faculty of Veterinary Medicine, University of Zagreb, Croatia

Trapped neutrophil syndrome (TNS) in Border Collies is an autosomal recessive inherited condition. This disease is poorly described in the scientific literature, but it is suggested that observed problems are primarily related to recurrent infections due to inherited neutropenic immunodeficiency.

A 3-month-old Border Collie was referred to the Clinic for Infectious Diseases with a history of unilateral ocular discharge, diarrhoea, occasional weakness and *incoordination* of the *hind limbs*. A clinical examination revealed a persistent pupillary membrane, pain in the temporomandibular joint, ataxia and weakness in the hind limbs. Signs of occasional aggression and mood changes were also noted. The initial *complete blood count* (CBC) showed slight anaemia, leukopenia and neutropenia. Biochemistry revealed elevated levels of serum globulins, alanine aminotransferase and *γ-glutamyl transferase*. Hypoglycaemia was present despite an increased appetite.

A partial improvement in the clinical condition was noted after the empirical use of ceftriaxone. The repeated CBCs revealed a normal neutrophil count, but, as all other tests (PCR for distemper, ANA-test, liver function tests, etc.) were negative, a blood sample was submitted for genetic testing. The obtained results revealed that the puppy was a homozygous carrier of a mutation in the VPS13B gene, with both gene copies in the shape of the defective gene responsible for the TNS (mutation).

A significant clinical improvement was *observed after initiation of oral prednisolone* (1 mg/kg BID). During the ensuing three months, the puppy was presented with a relapse of the clinical symptoms on two occasions; when prednisolone dosage reduction was attempted, and then again after six weeks, when the owner missed one day of therapy. On both occasions, despite an obvious clinical deterioration, neutrophil counts were within the reference range.

To the best knowledge of the authors, this is the first described case of TNS without persistent neutropenia. The obtained findings suggest that genetic testing should be considered for all Border Collie puppies presented with cases of unclear aetiology.

OPTIMISATION OF INOCULUM SIZE OF *MALASSEZIA PACHYDERMATIS* AND ITS USE IN DISK DIFFUSION METHOD FOR ANTIFUNGAL SUSCEPTIBILITY TESTING

Iva Benvin¹, Ljiljana Pinter², Zrinka Štritof², Josipa Habuš², Vesna Mojčec Perko², Vladimir Stevanović², Matko Perharić², Ljubo Barbić², Vilim Starešina², Nenad Turk², Zoran Milas², Suzana Hađina²

¹Faculty of Veterinary Medicine, University of Zagreb, Croatia, student

²Department of Microbiology and Infectious Diseases with Clinic, Faculty of Veterinary Medicine, University of Zagreb, Croatia

During the last 15 years, antifungal susceptibility testing of *Malassezia pachydermatis* has been explored using various modified protocols. However, there is no standardised method that would ensure inter-laboratory consistency and results. In susceptibility testing, the turbidity method is the standard for the preparation of the inoculum suspension. A butyrous consistency of *M. pachydermatis* represents a well-known obstacle in the preparation of a homogenous suspension. In this study, we wanted to compare turbidity measurements with the viable plate count, when the inoculum suspension was prepared with lipids. In addition, the reproducibility of the results and the use in the disk diffusion method were evaluated.

A total of thirty isolates of *M. pachydermatis* were subcultured for 72 h at 37 °C on Sabouraud dextrose agar. An inoculum with sterile saline containing 0.04% Tween 80 aiming concentration of 1 to 5x10⁷ CFU/mL was prepared. Different turbidity values and their ten-fold serial dilutions were measured and expressed in McFarland units (McF). For the disk diffusion method, miconazole, clotrimazole and itraconazole tablets (10 µg) and Mueller-Hinton agar with the addition of 2% glucose and 0.5 µg/L methylene blue were used. The plates were incubated at 37 °C and inhibition zones were read after 24, 48, 72, 96 and 120 h.

The inoculum suspensions adjusted to 3.5 McF corresponded to the average of 1.27x10⁷ CFU/mL, providing reproducible results. During the first 48 hr, most of the strains demonstrated a weak growth that became confluent after 72 h, allowing the measuring of diameters of clearly visible inhibition zones. There was a statistically significant difference in the readings of the inhibition zones between 48 and 72 h, while the readings after 96 and 120 h remained consistent.

The use of 3.5 McF corresponded to the recommended range of yeast cell density for antifungal testing, and the optimal reading time at 72 h showed a consistent reproducibility, which represents the first step in the standardisation of the method.

ARTHRODESIS, IS IT A WAY TO GO? – A CASE SERIES

Ena Oster¹, Sonja Vukelić², Mirna Abaffy Kirin², Mario Kreszinger², Marko Pećin²

¹Faculty of Veterinary Medicine, University of Zagreb, Croatia, student

²Clinic for Surgery, Orthopaedics and Ophthalmology, Faculty of Veterinary Medicine, University of Zagreb, Croatia

Arthrodesis is a surgical fusion of two or more joints to form a bony ankylosis. It should be saved as the last resort for when other orthopaedic techniques fail. The indications for arthrodesis are irreparable fractures of joints, chronically unstable joints, chronic severe degenerative joint disease, a neurological injury, etc.

This paper describes a series of cases of arthrodesis performed on clinical patients and different joints with favourable outcomes.

Over the last few years, several animals underwent an arthrodesis procedure at the Clinic for Surgery, Orthopaedics and Ophthalmology, FVMUZ, in order to preserve the limb function. The first one, a 2-year-old mixed-breed female (weighing over 40 kg), had an arthrodesis of the stifle because of a failed patella surgery. The stifle arthrodesis was stabilised with a LC-DCP 4.5 steel plate. The second one, a 7-month-old mixed-breed male, had the same surgery, but the stifle was stabilised with a 3.5 DCP steel plate. The third patient, a 2-year-old French Bulldog, was diagnosed with a Gustilo Anderson type III_B open fracture of the left medial malleolus and luxation of a tarsal joint and the left hip joint. Because of excessive wounds throughout the body, some of them being necrotic, the arthrodesis surgery was scheduled two months after the trauma. A Fixin (Intrauma S.p.A) 1.9–2.5 hybrid plate was placed at the dorsal side of the talocrural joint for a pantarsal arthrodesis. The fourth patient was a 3-year-old French Bulldog who had lateral condyle fracture of a humerus. After the first surgery and implant failure, he underwent an arthrodesis surgery of the elbow with a Fixin 3.0–3.5 plate. The last patient was a 5-year-old German Shepard who underwent a bilateral pancarpal arthrodesis surgery with a DCP stainless steel hybrid plate and a Fixin 3.0–3.5 carpal arthrodesis hybrid plate after a chronic carpal instability.

All of the patients recovered fully after the procedures. Arthrodesis has proved to be a satisfactory method when other methods fail, and should be considered as a better option than limb amputation.

FIRST INDUCED HETEROSPERMATIC LITTER IN CROATIA – A CASE REPORT

Iva Raič¹, Nino Maćešić², Tugomir Karadjole², Goran Bačić², Nikica Prvanović Babić², Ivan Butković², Maša Efendić³, Martina Lojkić²

¹Faculty of Veterinary Medicine, University of Zagreb, Croatia, student

²Clinic for Obstetrics and Reproduction, Faculty of Veterinary Medicine, University of Zagreb, Croatia

³Faculty of Veterinary Medicine, University of Zagreb, Croatia, PhD student and intern

The idea of a dual-sired breeding is to give equal chances to both possible males to fertilise the eggs due to specific oestrus cycle of the bitch. Successful multiple-sired litters allow breeders to maximise offspring possibilities as well as the female's potential by creating more genetic combinations.

Three stud dogs (A, B and C) were presented to the clinic a month before breeding to undergo sperm quality testing in order to choose 2 potential sperm donors. All dogs had a history of prior normal fertility and had a DNA profile. The semen was collected by manual manipulation and only sperm-rich fractions were collected. Immediately after the collection, the semen was evaluated based on the following parameters: colour, volume, pH, progressive motility, concentration, viability and functional integrity of the sperm membrane (HOS test and Bloom staining). After the evaluation, the semen samples were mixed according to the factorial design Stud A and B, Stud A and C and Stud B and C. The mixed samples were evaluated for semen characteristics after 1, 2, 3 and 5 hours. In addition, the mixed samples were subjected to a longevity exam at 4 °C, and the semen quality was assessed on days 3 and 5. The breeding time of the bitch was determined by measuring progesterone (P_4) levels. P_4 concentration at the onset of ovulation was 4.2 ng/mL. The bitch was inseminated 3 times starting on day 2 after ovulation.

Based on semen quality parameters, studs A and B were chosen for insemination. On all 3 days of insemination, the semen of 2 males was collected, evaluated and mixed prior to insemination. Semen volume was adjusted based on quality parameters, to give an equal final concentration for both males. The bitch was inseminated vaginally. The puppies were born 60 days after the first insemination. Blood samples were collected on week 5 via jugular venepuncture into EDTA vacutainer tubes for a genetic analysis. The final results showed 6 puppies from stud A (4 ♂, 2 ♀) and 1 puppy from stud B (♂). No monozygotic twins were born.

BREEDING SOUNDNESS EXAMINATION OF YOUNG MILITARY WORKING DOGS

Tena Propadalo¹, Martina Lojkić², Nikica Prvanović Babić², Jelena Jelen Orlić³,
 Silvijo Vince², Ivan Folnožić², Ivan Butković², Iva Getz²

¹*Faculty of Veterinary Medicine, University of Zagreb, Croatia, student*

²*Clinic for Obstetrics and Reproduction, Faculty of Veterinary Medicine, University of Zagreb, Croatia*

³*Ministry of Defence, Zagreb, Croatia*

The relationship between the main characteristics of native semen and fertility in young military working dogs has been the subject of a very small number of studies. This research provides, for the first time in Croatia, a comprehensive semen evaluation of the military working dogs (MWD) owned by the Ministry of Defence of the Republic of Croatia (MDRC).

Nine virgin MWD (5 German Shepherd dogs and 4 Belgian Shepherd dogs, Malinois), aged 12 to 18 months (1.24 ± 0.19 years) were subjected to a clinical examination, B-mode ultrasonography of the testes, epididymis and prostate, semen evaluation at collection and after storage at 4 °C for 24, 48 and 72 h. The semen was evaluated based on the following parameters: colour, volume, pH, progressive motility, concentration, viability and functional integrity of the sperm membrane (HOS test and Bloom staining). The diluted semen samples were subjected to a longevity exam at 4 °C, and the semen quality was assessed after 24, 48 and 72 hours. The dogs were subjected to the second semen collection and evaluation after two months.

In 7/9 of the virgin dogs, the semen was successfully collected by using digital manipulation at the first collection and in 8/9 of the dogs at the second collection, without the presence of a teaser bitch. All sperm quality parameters were within the optimal range. Sperm progressive motility and motility after 24 and 48 hours of storage was significantly higher in the second collection ($p < 0.05$). The percentage of morphologically normal spermatozoa was also higher in the second-collection specimens, although without a significant difference.

This research has shown that it is necessary to include a variety of clinical and laboratory methods in order to get a complete insight into the breeding potential of dogs and choose those with the highest-quality characteristics for reproduction. Our results of the semen quality evaluation at collection and after storage indicate a high reproductive potential of military breeding and working dogs of the MDRC and offer a possibility of international trade of a high-quality genetic material.

PHYSIOLOGICAL RESPONSES OF LIPIZZAN HORSES TO GRADED EXERCISE TESTS OF VARIOUS INTENSITY

Nina Čebulj Kadunc¹, Robert Frangež¹, Jaka Žgajnar², Peter Kruljc¹

¹*Veterinary Faculty, University of Ljubljana, Slovenia*

²*Department of Animal Science, Biotechnical Faculty, University of Ljubljana, Domžale, Slovenia*

Sport horses are often exposed to adverse conditions threatening their welfare. A common reaction of horses to stressful situations is emotional excitement leading to an elevated heart rate (HR) and cortisol concentrations (CORT), reactions which are also a characteristic of physiological response to an increased physical activity. Measurement of plasma lactate concentrations (LA) is widely used in veterinary and sports medicine, including an evaluation of the reactions to anaerobic exercise. The aim of our study was to determine the reactions of the HR, CORT and LA to a graded exercise load in Lipizzan horses.

The study was performed with six pure-bred Lipizzans, mainly used in equitation courses. The study consisted of two exercise tests, performed by riding in an indoor riding arena for 30 minutes, divided into 10-minute intervals of collected (Test 1) or working (Test 2) walk, trot and gallop. The HRs were recorded telemetrically throughout each exercise test, whilst the plasma CORT and blood LA were measured immediately before and after the workload.

A gradual increase in the HR was recorded in both tests ($p < 0.001$), with higher values reached in Test 2 ($p < 0.001$). CORT measured in Test 1 were higher than in Test 2, with elevated values at the end of the workload ($p < 0.05$). LA measured in Test 1 were lower than in Test 2. A decrease in LA was detected after the end of Test 1 ($p < 0.01$), whilst the opposite situation was present in Test 2 ($p < 0.01$).

The measured physiological values were in the normal ranges reported for horses. Elevated HR, CORT and LA values after the tests reflect physiological reactions to a graded workload. Higher CORT and lower LA in Test 1 than in Test 2 could indicate larger psychological and lower physical burden in collected gates than in working ones.

The results of our study demonstrate the reactions of the HR, CORT and LA of Lipizzan horses to graded exercise and contribute to the knowledge that could be used as a basis for the monitoring of the fitness level, training progress, health status and well-being of this breed and horses in general.

INFLUENCE OF REPRODUCTIVE STATUS, AGE AND PERSONALITY OF HORSES ON PLACEMENT AND RESULTS IN SHOWJUMPING COMPETITIONS

Antea Rački¹, Ivan Vlahek², Nikica Prvanović Babić³

¹Faculty of Veterinary Medicine, University of Zagreb, Croatia, student

²Department of Animal Breeding and Livestock Production, Faculty of Veterinary Medicine, University of Zagreb, Croatia

³Clinic for Obstetrics and Reproduction, Faculty of Veterinary Medicine, University of Zagreb, Croatia

Showjumping is one of five Olympic equestrian disciplines present in Croatia. During these competitions, horses of different age, reproductive status and dominant personality component are all found in the same place and can affect each other's behaviour. The aim of the research was to determine if these characteristics influence placements and results in showjumping competitions.

The research included 41 Warmblood horses: 8 stallions, 18 mares and 15 geldings. The horses were divided by age: young horses, mature horses and older horses, and according to the dominant personality component, obtained by questionnaires: excitability, protection, sociability, inquisitiveness and horses without a dominant personality component. The horses were compared according to the results obtained in showjumping competitions of the Croatian Equestrian Federation in 2017 and 2018. Altogether, data were collected from 80 classes. Forty-four tournaments and 3280 starts were used. The Winter Cup (1.10–1.3) was considered as the time of reproductive quiescence, while the Summer Cup (1.3–1.10) was considered as the full reproductive season.

Based on the statistical analysis of our data, it is obvious that the dominant personality component influences the success of the horse in showjumping (ranking, penalties). Excitable horses had the worst results, especially during the reproductive season ($p < 0.05$). In contrast, protective horses had the best results, regardless of the season. Geldings had the least variations with respect to the season, while mares had significantly better results out of the season ($p < 0.05$).

There is a connection between these factors and the results in showjumping, which is most evident in the fact that excitable horses had the worst results both during and off-season. However, it is important to additionally research all observed parameters on a significantly higher number of showjumpers in order to conclude if our findings could be applied to the complete population of Warmblood horses used in showjumping competitions in Croatia and abroad.

INCIDENCE OF RETAINED FOETAL MEMBRANES IN LIPIZZAN BROODMARES AT LIPIK STATE STUD FARM FROM 2015 TO 2019

Petra Špehar¹, Mato Čačić², Damir Jakšić³, Siniša Horvat⁴, Iva Getz⁵, Goran Bačić⁵, Tugomir Karadjole⁵, Nino Maćešić⁵, Martina Lojkić⁵, Nikica Prvanović Babić⁵

¹*Faculty of Veterinary Medicine, University of Zagreb, Croatia, student*

²*Ministry of Agriculture, Zagreb, Croatia*

³*Lipik State Stud Farm, Lipik, Croatia*

⁴*Veterinarska stanica Pakrac d.o.o. Veterinary Clinic, Pakrac, Croatia*

⁵*Clinic for Obstetrics and Reproduction Faculty of Veterinary Medicine, University of Zagreb, Croatia*

Retained foetal membranes (RFM) in mares are a pathological condition that appears if a mare failed to expel placenta within three hours after delivering a foal. If left untreated, it is a life-threatening condition, with first serious symptoms occurring 10 h postpartum. In general, the incidence of RFM is 2–10% of all post-parturient mares. On the other hand, Friesian mares have the highest incidence (54%) of retained placenta due to a limited population left and inbreeding. Like Friesian horses, the Lipizzan breed also tends to inbreed since the entire world population is around 12,000 horses and the determined level of inbreeding is 11%. The aim of this study was to determine the incidence of RFM in the population of Lipizzan broodmares at the Lipik State Stud Farm.

In five years (2015–2019) and 73 parturitions, there were 21 RFM (28.76%) cases. This is significantly higher than the incidence in the average population. Such a high incidence of RFM could be linked to a limited number of horses in breeding and a small world population of Lipizzan horses. Also, the highest prevalence of RFM (44%) was in 2018 and it correlates with a herpesvirus abortions outbreak. If the inbreeding trend tends to increase in Lipizzan horses, the highest incidence of retained placenta is expected.

However, further research is needed on the entire population of Lipizzan horses in order to gain a better perspective and obtain stronger conclusions about the causes and incidence of RFM in Lipizzan horses.

EQUINE ODONTOCLASTIC TOOTH RESORPTION AND HYPERCEMENTOSIS IN 15-YEAR-OLD ICELANDIC HORSE – A CASE REPORT

Sara Lolić¹, Rok Planovšek²

¹*Veterinarska ambulanta Franco d.o.o. Veterinary Clinic, Vodnjan, Croatia*

²*Veterina Mozirje d.o.o. Veterinary Clinic, Mozirje, Slovenia*

Equine odontoclastic tooth resorption and hypercementosis (EOTRH) is a progressive and painful pathology, predominantly of the incisor and canine teeth. It is characterised by the resorption of the reserve crown, apical region and adjacent alveolar bone, and by the deposition of irregular cementum in resorptive lesions. Clinically, it is observed with severe gingival inflammation, calculus depositions and draining tracts.

A 15-year-old Icelandic gelding was presented for a routine dental exam. Severe gingivitis of all incisors was observed, with an excess amount of calculus deposition and a foul odour. The horse showed the inability to bite through a hard feed with the affected teeth. Otherwise, the horse was in a good body condition, with no reported behavioural changes. After a thorough dental exam, a complete removal of the entire calculus and flushing of the periodontal pockets, therapy consisting of daily rinsing with 5% chlorhexidine solution was started. However, no improvement was noted.

Intraoral dorsoventral and ventrodorsal radiographs showed an irregular surface of all incisors. The extraction of all incisors was performed in one surgery. Although not obvious on the radiographs, hypercementosis was clearly seen on the extracted incisors. The wounds healed completely in two months' time and afterwards the horse was grazing without problems. The only cosmetic difference was the occasional protruding of the tongue.

This gelding showed no signs of discomfort obvious to the owners, despite a very painful chronic disease. Considering that the horse is a prey animal and that it instinctively hides pain, it is paramount to recognise EOTRH in order to prevent silent suffering. Although often resented by the owner, the treatment of choice is extraction, as it increases the quality of life.

MECHANICAL FRAGMENTATION URETHROLITH CALCULI REMOVAL IN MARE

Jelena Gotić¹, Darko Grden¹, Klara Arifović², Valentina Plichta³, Nika Brkljača Bottegaro³

¹*Clinic for Internal Diseases, Faculty of Veterinary Medicine, University of Zagreb, Croatia*

²*Faculty of Veterinary Medicine, University of Zagreb, Croatia, student*

³*Clinic for Surgery, Orthopaedics and Ophthalmology, Faculty of Veterinary Medicine, University of Zagreb, Croatia*

Equine urethral calculi are primarily seen in male horses, although they can occasionally be detected in mares. Urethral calculi of a smaller size can easily cause stranguria occluding a narrow and long urethra of male horses. This case report describes a nonsurgical removal of a big urethral calculi in a mare.

A 23-year-old Warmblood mare was referred to the University clinic for haematuria and a rectally palpable mass in the urethra. Haematuria and stranguria have been noted for the previous three months, but were attributed to prolonged oestrus. The mare was used for showjumping and described as nervous and sensible; therefore she was given magnesium and B1, B6 and B12 vitamin supplements daily for her temper control.

At admission, the mare showed signs of inconsistent stranguria. A firm 10 cm sized mass was palpable rectally in the urethra. Sedation and analgesia were initiated and a sterile lubricant gel for rectal examinations mixed with lidocaine injectable solution was applied abundantly at the urethral orifice surrounding the calculi. A manual extraction was attempted, but without success, due to the large size of the calculi. A long foreign body forceps guided endoscopically was then used to crush and remove the calculi in fragments. An endoscopy examination of the urinary bladder revealed a great amount of smaller uroliths and sediment firmly attached on the ventral aspect of the bladder. A simple irrigation with a saline solution failed as the material was firmly attached to the mucosa. A system of irrigation and suction by using a sterile canine endotracheal tube and suction pump was then applied to remove the foreign material inside the bladder and rinse thoroughly by using the saline solution. The mare was treated with antibiotics and NSAIDs for seven consecutive days and showed immediate relief when urinating, along with temper improvements.

The present case represents a low invasive treatment of urethritis. Bladder and urethral calculi should be considered as a possible cause of pain and behavioural problems in mares.

/// POSTER PRESENTATIONS ///

CHARACTERISTICS OF BRUCELLOSIS IN CANTON OF SARAJEVO

Lejla Velić¹, Toni Eterović¹, Benjamin Čengić², Dženo Hadžović³, Sabina Šerić Haračić⁴, Amina Hrković Porobija⁵

¹*Department of Microbiology with Immunology and Infectious Diseases with Epizootiology, Faculty of Veterinary Medicine, University of Sarajevo, Bosnia and Herzegovina*

²*Department of Obstetrics and Udder Diseases, Faculty of Veterinary Medicine, University of Sarajevo, Bosnia and Herzegovina*

³*Veterinary Office of Bosnia and Herzegovina*

⁴*Department of Epidemiology, Faculty of Veterinary Medicine, University of Sarajevo, Bosnia and Herzegovina*

⁵*Deperment of Morphology, Faculty of Veterinary Medicine, University of Sarajevo, Bosnia and Herzegovina*

Brucellosis is a subacute or chronic infectious disease of animals and humans, disseminated almost worldwide. The Mediterranean area is considered to be the natural habitat of *B. melitensis*, with the dominance of biovar 3. A precise prevalence of Brucellosis in humans around the world is unknown due to a lack of reports from many countries, and the disease is often misdiagnosed and not possible to determine. Also, a very important factor is that Brucellosis shows mild signs or atypical clinical symptoms, which are usually not recognised.

Individual and sporadic cases of Brucellosis in animals in Bosnia and Herzegovina were diagnosed in 2001, although the disease appeared during the 1970s and early 1980s, but was successfully eradicated. New numerous cases of Brucellosis in animals as well as in humans appeared from 2004 to 2006.

The study included people and animals infected in the period from 2013 to 2016 in the area of the Canton of Sarajevo. During our study period, the Institute for Public Health of the Canton of Sarajevo has reported 24 positive cases of human Brucellosis, while in the same period new reports came in for another 343 cases of Brucellosis in domestic animals. Cases of infected people and animals were analysed and categorised according to municipalities of the Canton of Sarajevo, sex and age, while the categorisation of infected animals was conducted according to species in the affected municipality of the Canton of Sarajevo.

ANTIMICROBIAL RESISTANCE OF *YERSINIA ENTEROCOLITICA* ISOLATED FROM TONSILS OF PIGS PRODUCED ON FAMILY FARMS

Marta Kiš¹, Valerij Pažin², Snježana Kazazić³, Emilija Cmrečak⁴, Ivan Vičić⁵, Nevijo Zdolec¹

¹Department of Hygiene, Technology and Food Safety, Faculty of Veterinary Medicine, University of Zagreb, Croatia

²Faculty of Veterinary Medicine, University of Zagreb, Croatia, PhD student; Lidl, Croatia

³Division of Physical Chemistry, Ruđer Bošković Institute, Zagreb, Croatia

⁴Bioinstitut, Čakovec, Croatia

⁵Department of Food Hygiene and Technology, Faculty of Veterinary Medicine, University of Belgrade, Serbia

Yersinia enterocolitica is one of the most important biological hazards in public health closely related to pigs and pork meat production and consumption. Tonsils represent the most important source of meat contamination with pathogen during the slaughtering process. The aim of this work was to investigate the prevalence of *Y. enterocolitica* in tonsils of pigs produced on family farms and slaughtered in the same approved local slaughterhouse, as well as the antimicrobial resistance of isolated strains.

The tonsils of 48 pigs, which came from 14 family farms, were sampled on the slaughter line. The presence of *Y. enterocolitica* in tonsils was determined by using the HRN EN ISO 10273:2017 method and the identification of the susceptible colonies by means of MALDI-TOF MS. The susceptibility of the isolates was tested against eleven antibiotics: levofloxacin (5 µg), ciprofloxacin (5 µg), ampicillin (10 µg), cephalothin (30 µg), cefotaxime (30 µg), tetracycline (30 µg), nalidixic acid (30 µg), ceftazidime (30 µg), trimethoprim/sulfamethoxazole (25 µg), chloramphenicol (30 µg) and streptomycin (10 µg) by using the disc diffusion method. The interpretation of the results based on the size of inhibition zones was carried out according to the CLSI criteria for enterobacteria.

Morphologically typical colonies on CIN agar (small, bull-eye) were found in 26 tonsils samples (54%; n = 48) from pigs produced on 9 farms (64.28%; n = 14) and all were confirmed as *Yersinia enterocolitica* by MALDI-TOF MS. All isolates showed resistance to the same two antibiotics, ampicillin and cephalothin, while only 1 strain was additionally resistant to streptomycin, trimethoprim/sulfamethoxazole, ceftazidime and nalidixic acid.

The results indicate a low level of *Y. enterocolitica* resistance to clinically relevant antimicrobial agents in pigs from Croatian family farms. However, the wide presence of pathogen in the pig population increases the risk of meat cross-contamination during the slaughter process.

MERCURY IN PHEASANT (*PHASIANUS COLCHICUS*) ORGANS COLLECTED IN VICINITY OF NATURAL GAS TREATMENT PLANT IN NORTHERN CROATIA DURING LAST TEN YEARS

Andreja Prevendar Crnić¹, Emil Srebočan¹

¹Department of Pharmacology and Toxicology, Faculty of Veterinary Medicine, University of Zagreb, Croatia

Considering the risk of entry of mercury into the environment and food chain, a comprehensive environmental monitoring programme was conducted in the Molve gas field. Among other biomarkers, pheasant organs were analysed for total mercury concentration by using the ICP-MS method. The aim of this study was to determine the concentration of mercury in the collected samples from 2008 to 2018, monitor its changes over the last ten-year period and assess its possible adverse impact on human and animal health.

Adult pheasants (n = 5) were collected during the hunting season around natural gas treatment plants Molve 9, 10, 11 and 12. Total mercury concentration is expressed in µg/g wet weight of the sample. Statistics were processed by the Statistica 13.4 software.

During the last ten years, the range of the median mercury concentration values in pheasant organs were 0.0003–0.0015, 0.001–0.003, 0.0021–0.005 and 0.0004–0.0016 µg/g for the muscle, liver, kidney and brain, respectively. Median Hg concentrations in all organs slightly differ from year to year, but generally show a consistent pattern in fluctuations, especially a slight decline in values over the last three years.

Comparing our results with those from the previous investigated period (1995–2008), we concluded that they show mainly consistency and a slight decline in values, and that the investigated area near Molve still belongs to a low mercury-contaminated region. In that context, it can be stated that pheasant tissues as food are completely safe for human health. The results also indicate that the research and production of natural gas contaminated by mercury does not threaten human health and the environment.

BACTERIAL CONTAMINATION OF BROWN TROUT (*SALMO TRUTTA*) AND COMMON CARP (*CYPRINUS CARPIO*) IN CROATIA

Dražen Knežević¹, Brigita Hengl¹, Darija Vukić Lušić^{2,3}, Ana Gavrilović⁵, Jura Jug-Dujaković⁶, Snježana Kazazić⁴, Kristina Pikelj⁷, Irena Vardić Smrzlić⁴, Lorena Perić⁴, Jakov Žunić⁴, Anamarija Kolda⁴, Damir Kapetanović⁴

¹Croatian Agency for Agriculture and Food, Croatia

²Faculty of Medicine, University of Rijeka, Croatia

³Teaching Institute of Public Health of Primorje–Gorski Kotar County, Croatia

⁴Ruder Bošković Institute, Zagreb, Croatia

⁵Faculty of Agriculture, University of Zagreb, Croatia

⁶Sustainable Aquaculture Systems Inc., USA

⁷Faculty of Science, University of Zagreb, Croatia

Brown trout (*Salmo trutta*) and common carp (*Cyprinus carpio*) are the most consumed freshwater fish species among Croatian consumers. Contamination of fish with bacteria from the aquatic environment may pose a risk for human health. This study documents the bacterial contamination associated with farm-raised and wild-caught brown trout and common carp in order to assess bacteriological safety for human consumption.

In the period 2016–2018, a total of 193 samples (88 farmed) of brown trout were collected seasonally (spring, summer, autumn and winter) in the Krka river and a related commercial farm. During 2016, a total of 72 samples (66 farmed) of common carp were collected seasonally (spring, summer, autumn) in the Ilova river and a related commercial farm. Samples for microbiological analysis were taken as swabs from the gills and skin by using sterile cotton sticks. All swab samples were serially diluted, plated and incubated on Tryptic Soy agar (22 °C), CHROMagar™ *Acinetobacter* (37 °C), Slanetz-Bartley (35 °C) and *Pseudomonas* agar F (22 °C) for isolation. Representative colonies were picked for further identification by MALDI-TOF MS.

Predominant bacterial genera in both fish species, farm-raised as well as wild-caught, were comprised mostly of *Pseudomonas*, followed by *Acinetobacter* and *Aeromonas*, with the majority of them known as pathogen or opportunistic pathogen for humans and animals, and spoilage bacteria for fish. The less numerous bacteria were from the *Achromobacter*, *Carnobacterium*, *Hafnia*, *Serratia*, *Shewanella*, *Bacillus*, *Delftia*, *Erwinia*, *Enterococcus*, *Morganella*, *Proteus* and *Stenotrophomonas* genera.

Microorganisms play a pivotal role in the area of food safety. The results obtained from this study provide new insights in bacterial contamination of investigated fish species and enable a better assessment of various microbiological safety and quality parameters of the most consumed freshwater fish in Croatia, which may help to optimise product safety and quality as well as resource utilisation.

EFFECT OF FEEDING *MORTIERELLA ALPINA* PREFERMENTED WHEAT BRAN ENRICHED WITH FATTY ACIDS ON QUALITY OF CHICKEN BREAST MEAT

Slavomír Marcinčák¹, Martin Bartkovský¹, Dana Marcinčáková², Boris Semjon¹, Beáta Koreneková¹, Peter Popelka¹, Ondrej Slaný³, Tatiana Klempová³

¹Department of Food Hygiene and Technology,
University of Veterinary Medicine and Pharmacy in Košice, Slovakia

²Department of Pharmacology and Toxicology,
University of Veterinary Medicine and Pharmacy in Košice, Slovakia

³Institute of Biotechnology, Faculty of Chemical and Food Technology,
Slovak University of Technology, Bratislava, Slovakia

Microbial oils rich in different types of biologically active polyunsaturated fatty acids (PUFA) offer an easily accessible alternative, especially for fish oils. The production of PUFA by solid-state fermentation (SSF) of lower filamentous fungi is based on the use of waste products from agricultural and food production. Except for the production of PUFA such as the gamma-linolenic acid (GLA), dihomogamma-linolenic, arachidonic acid (ARA) and eicosapentaenoic acid (EPA), the lower filamentous fungi (*Cunninghamella*, *Mortierella*) eliminate antinutritional substances.

The aim of this work was to evaluate the effect of 10% (w/w) addition of fermented wheat bran (FWB) into commercial broiler feed on fatty acid profile, lipid oxidative stability and sensory quality of chicken breast meat. The fermented product was prepared by SSF of wheat bran using filamentous fungi *Mortierella alpina* CCF 2861. Alpha-linolenic acid (ALA), GLA, ARA and EPA were produced during this process.

In the experiment, 80 day-old chickens COBB 500 divided into two groups – control and experimental (40 per group) – were fed with commercial diet. From day 10 to day 39 of the experiment, 10% of the feed for the experimental group of broilers was replaced by FWB. After slaughtering (day 39), breast meat samples (16 from each group) were collected and evaluated for lipid oxidative stability and sensory analyses. Fatty acid content was determined as their methyl esters by using gas chromatography (ChemStation B0103, Agilent Technologies).

The addition of FWB into the commercial feed mixture significantly affected the profile of fatty acids in breast meat. The amounts of GLA, ALA and DPA in the fat of breast muscles were higher than in the control group. The contents of ARA and EPA were not affected by the application of FWB. Lipid oxidative stability and sensory evaluation of meat were not affected by FWB.

Acknowledgments: This work was supported by the Slovak Research and Development Agency under the contracts: APVV-18-0039 and APVV-14-039.

EFFECT OF FERMENTED FEED SUPPLEMENTATION ON EGG YOLK COLOUR IN LAYING HENS

Boris Semjon¹, Dana Marcinčáková², Martin Bartkovský¹, Slavomír Marcinčák¹

¹Department of Food Hygiene and Technology,

University of Veterinary Medicine and Pharmacy in Košice, Slovakia

²Department of Pharmacology and Toxicology,

University of Veterinary Medicine and Pharmacy in Košice, Slovakia

The aim of this work was to analyse the effect of 10% and 15% (w/w) fermented product addition into commercial feed on egg quality in laying hens at 25 weeks of age. The fermented product was prepared by solid state fermentation of wheat bran by filamentous fungi *Mortierella alpina* CCF2861 with production of arachidonic and eicosapentaenoic acids. The experiment was conducted on 30 pieces of Lohmann Brown classic layers at 17 weeks of age, which were divided into three groups (10 hens in each): the control group (C), fed only with a commercial layer diet, and two experimental groups, F10 and F15, fed with a diet supplemented with 10% and 15% of prefermented feed, respectively. Fermented feed was added to the laying hens feed after the beginning of egg laying (at 21 weeks of age). The animals had access to water and feed *ad libitum* during the experiment. Egg samples were stored for 28 days at the temperature of 4 ± 2 °C in dark conditions.

The colour of egg yolk samples was measured by using a Chroma meter CR-410. The results are expressed as average values of six individual measurements of each egg yolk sample. Statistical evaluation was conducted by two-way analysis of variance using the R-statistics software.

The highest difference in egg yolk colour (ΔE_{ab}) was observed between groups C and F15 that has changed from value $\Delta E_{ab} = 5.41$ to $\Delta E_{ab} = 10.45$ during storage. The effect of fermented feed supplementation was observed in all colorimetric values ($p < 0.05$) that were increased by an average of 5% during the storage period.

The colorimetric values of egg yolks were significantly influenced after feeding with a commercial diet supplemented with 10 and 15% of fermented feed.

Acknowledgements: This work was supported by the Slovak Research and Development Agency under the contracts No. APVV-14-0397 and APVV-18-0039.

QUALITY CONTROL OF HONEY PRESENT ON MACEDONIAN MARKET

Tome Nestorovski¹, Zehra Hajrulai Musliu¹, Ana Angelovska¹, Risto Uzunov¹, Stefan Jovanov¹

¹*Food Institute, Faculty of Veterinary Medicine, Ss. Cyril and Methodius University in Skopje, Skopje, North Macedonia*

Honey is an important foodstuff whose popularity increases continually, and due to this it is a potential subject of adulteration. In order to protect consumers from such fraudulent honey, the Macedonian government has implemented a Directive compliant with the European Directive 2001/110/EC. The aim of this study was to analyse the honey present on the Macedonian market, to see if it meets the criteria set by the Government and do a side-by-side comparison of two methods for sugar content determination: gravimetric and HPLC.

For this study, 50 honey samples were analysed for their electrical conductivity, free acid, reducing sugar and sucrose content, moisture, water insoluble and hydroxymethylfurfural (HMF) content by using standard methods, previously validated and accredited.

The results showed that all the honey samples were compliant with the Directive for their moisture, water insoluble and free acid content, and electrical conductivity. As for the reducing sugars, values ranged from 38.96 g/100 g to 79.60 g/100 g, of which 3 honey samples and 1 product labelled as flower nectar had values lower than the minimum values of 60 g/100 g. The HMF content in the samples varied from 0.10 mg/kg to 77.72 mg/kg, with 1 sample exceeding, with 327.98 mg/kg. Of the analysed samples, 2 exceeded the 40 mg/kg limit for non-tropical climate honeys with values of 79.60 g/100 g and 327.98 mg/kg.

In conclusion, from the 50 analysed samples, 5 failed to meet the Directive requirements, 4 of which had reducing sugar content lower than 60 g/100 g and 1 had HMF content higher than 80 mg/kg, which is the maximum level allowed for honey of tropical climate origin. Comparing the two methods (gravimetric and HPLC), the results for the reducing sugar content were on par with each other, with minor variations of ± 2.1 g/100 g. The results varied more significantly when determining the total sugar content by using the gravimetric method, most likely due to the increasing reduction potential after hydrolysis with HCl.

PREVALENCE OF LAMENESS IN DAIRY COWS IN CROATIA

Robert Dumančić¹, Ivan Vlahek², Katja Močibob¹, Bojan Toholj³, Marija Lipar⁴, Marko Pećin⁴, Ozren Smolec⁴

¹Faculty of Veterinary Medicine, University of Zagreb, Croatia, student

²Department of Animal Breeding and Livestock Production, Faculty of Veterinary Medicine, University of Zagreb, Croatia

³Department of Veterinary Medicine, Faculty of Agriculture, University of Novi Sad, Serbia

⁴Clinic for Surgery, Orthopaedics and Ophthalmology, Faculty of Veterinary Medicine, University of Zagreb, Croatia

Lameness is one of the largest issues within the dairy industry. Economic losses from lameness include a decreased milk production, impaired fertility and an increased risk of culling. This study aimed to investigate the prevalence of lameness in dairy cows in Croatia.

A cross-sectional survey was conducted from January 2018 to December 2018 in continental parts of Croatia. Foot lesion data were recorded by hoof trimmers on 6,537 cows, of which 3,662 had some sort of lameness recorded. The history of farm and management as well as previous lameness history was collected.

The overall prevalence of lameness in dairy cows was 56.01%. The prevalence is reported to be 5% in Sweden and up to 48% in the USA. The prevalence among farmers was not significantly different ($p > 0.05$). Cow owners in the studied areas practice foot trimming, but not regularly, two times a year. Most farmers did not seek veterinary care when a cow showed lameness. Dermatitis digitalis was reported in 32%, hoof ulcer was reported in 27%, laminitis in 19%, hoof fissure in 7%, double sole in 7%, limax in 2% and white line separation in 6% of the cows.

The results suggest that the prevalence of lameness among dairy cattle in Croatia is higher than previously thought and foot lesion data recorded by hoof trimmers can provide useful information to develop effective foot health programmes at the herd level. Lameness was more frequently observed in cows housed in tie stalls without exercise than in cows housed in loose-housing systems. In the present study, the prevalence of lameness in individual herds ranged from 14.9 to 71.7%, which suggests that with the application of an adequately frequent and correct claw-trimming protocol, the prevalence of severe hoof lesions and lameness can be decreased. Digital dermatitis has developed to the most relevant and costly foot disease in dairy cattle in Croatia, especially in cows held mostly in barns.

CHALLENGES OF MANAGEMENT IN IMPROVEMENT OF REPRODUCTIVE PERFORMANCE IN DAIRY COWS

Benjamin Čengić¹, Amel Ćutuk², Lejla Velić³, Tarik Mutevelić⁴, Nazif Varatanović¹, Toni Eterović³

¹*Department of Obstetrics and Udder Diseases, Faculty of Veterinary Medicine, University of Sarajevo, Bosnia and Herzegovina*

²*Department of Ambulatory Clinic, Faculty of Veterinary Medicine, University of Sarajevo, Bosnia and Herzegovina*

³*Department of Microbiology with Immunology and Infectious Diseases with Epizootiology, Faculty of Veterinary Medicine, University of Sarajevo, Bosnia and Herzegovina*

⁴*Department of Physiology and Pathology of Reproduction of Domestic Animals, Faculty of Veterinary Medicine, University of Sarajevo, Bosnia and Herzegovina*

Puerperium period is probably the most significant time interval in a lactation year, where cows are much more sensitive and easily affected by risk factors like stress, metabolic disorders, low body condition score (BCS) and many others. This may lead to health disorders with consequences of a decreased production and reproductive performance.

Our goal was to evaluate management and perform health monitoring of dairy cows before and after parturition. Routine ultrasound checkups of uterus and ovaries were made. BCS was assessed using sonography for a more objective insight, using the scale 1–5. The cows were treated with GnRH hormones at 15 days postpartum and the cows with abnormal uterine/vaginal discharge have had uterine flush done with 0.1% of chlorhexidine. The lameness score was assessed using the ZINPRO locomotion score method. Finally, to include a large number of cows in the insemination programme at once, the cows received hormonal protocols for presynchronisation and synchronisation of oestrus and ovulation.

When the changes in the uterine horn diameter and uterine wall thickness stopped being significant, we concluded that this was the end of involutive processes, with values of 36.9 mm for the uterine horn diameter and 7.8 mm for the uterine wall thickness. A total of 227 dominant follicles and 114 corpora lutea as a proof of ovulation were assessed. BCS before parturition has an average value of 2–2.5 in different cows, which is quite unsatisfactory, and during puerperium in many cows it dropped by more than 1 point. Approximately 59% of the cows had the lameness score of the 2nd degree and 36% of the 3rd degree. A more successful conception (34%) was found in the cows that received the Cosynch 72 h hormonal protocol for oestrus and ovulation synchronisation. Frequent lameness of the 2nd and 3rd degrees, an insufficient BCS before parturition and during puerperium as well as a large number of primiparous cows with retained placenta in our study probably had a significant impact on the final success of artificial insemination.

SUBCLINICAL MASTITIS IN SMALL DAIRY FARMS IN REPUBLIC OF NORTH MACEDONIA

Aleksandar Janevski¹, Iskra Cvetkovikj¹, Sanja Kiprijanovska², Sasho Dimovski²,
Dine Mitrov¹

¹Veterinary Institute, Faculty of Veterinary Medicine, Ss. Cyril and Methodius University in Skopje, North Macedonia

²Research Centre for Genetic Engineering and Biotechnology "Georgi D. Efremov", Macedonian Academy of Sciences and Arts, Skopje, North Macedonia

Subclinical mastitis is an asymptomatic udder infection distributed worldwide, with enormous losses in the dairy industry. The aim of this study was to determine the presence of subclinical mastitis in small dairy farms and to identify the most common bacteria associated with it.

Milk samples (n = 1,230) were obtained from 116 dairy cows (410 udder quarters) in three consecutive samplings 24–72 hours apart in seven dairy farms. The samples were cultured on routine bacteriological growth media and incubated for 24–48 hours, and the isolates were identified by the Axima-iD Plus MALDI-TOF MS Platform.

Subclinical mastitis was confirmed in 51 animals (43.9%), i.e. 111 infected quarters (27%). One hundred and eleven bacteria were isolated and 94 were identified to the species level. Seventeen bacteria were not identified by the SARAMIS software. The most frequent identified bacteria were *Streptococcus uberis* with 10.8% (12/111) and *Staphylococcus aureus* with 10.8% (12/111). *Staphylococcus haemolyticus* was identified in 9% (10/111), followed by *Staphylococcus simulans* in 8.1% (9/111), *Staphylococcus chromogenes* in 6.3% (7/111), *Staphylococcus epidermidis* in 4.5% (5/111), *Escherichia coli* in 3.6% (4/111), *Aerococcus viridans* in 3.7% (3/111), *Lactococcus lactis* in 1.8% (2/111), *Bacillus cereus* in 1.8% (2/111), *Enterococcus faecalis* in 1.8% (2/111), *Staphylococcus gallolyticus* in 1.8% (2/111) and *Enterococcus faecium*, *Staphylococcus xylosus*, *Micrococcus luteus*, *Arcanobacterium pyogenes*, *Streptococcus dysgalactiae*, *Staphylococcus hyicus*, *Streptococcus bovis/equines* and *Lactococcus garvieae* in 0.9% (1/111).

Subclinical mastitis is highly present in the selected small dairy farms. The most prevalent bacteria identified in the dairy farms (*Streptococcus uberis*, *Staphylococcus aureus* and coagulase-negative staphylococci) indicate that poor management and udder health practices, inadequate milking procedures and lack of mastitis control strategies greatly contribute to the occurrence and persistence of subclinical mastitis.

HEART MURMUR IN A HEIFER – A CASE REPORT

Darko Grden¹, Jayne Orr², Ines Prata², Angie Rupp³

¹*Clinic for Internal Diseases, Faculty of Veterinary Medicine, University of Zagreb, Croatia*

²*Scottish Centre for Production Animal Health and Food Safety, School of Veterinary Medicine, University of Glasgow, UK*

³*Veterinary Diagnostic Services, School of Veterinary Medicine, College of Medical, Veterinary and Life Sciences, University of Glasgow, UK*

An 18-month-old Holstein Friesian heifer was referred to the Scottish Centre for Production Animal Health and Food Safety at the University of Glasgow School of Veterinary Medicine.

The history. The heifer was housed, fed silage ad lib with a small amount of barley and cake until two months prior to the admission, when she was put out on pasture and grazed. She had had no history of disease until two weeks prior to the admission, when she became slower, had decreased appetite and progressed to lying down, with no energy and anorexia. The heifer was examined by a first-opinion vet. Their findings included pyrexia, mild ataxia and muffled heart sounds. It was presumed that the heifer was suffering from pericarditis.

The examination upon arrival showed BCS 2, stiff gait and reluctance to stand up or walk, with T 39.7 °C, RR of 40, and HR of 100, 5 quiet ruminal contractions in 5 minutes and 7% dehydration. The lungs were normal but auscultation of the heart revealed a regular rhythm with grade 4/6 systolic murmur. The percussion auscultation test for LDA was negative and the withers test was positive. Blood analysis revealed leukocytosis with neutrophilia and increased bilirubin, total proteins, globulins and GLDH. She was treated with Trimethoprim-Sulfadiazine and Meloxicam IV and orally with 30 litres of fluids. The next day she developed recumbency with tachypnoea and was euthanised.

A post-mortem examination found the presence of multifocal abscesses affecting the heart, liver, spleen, lungs, kidneys and serosal surface of the ileum and caecum, splenic and renal infarcts. The hepatic abscess was close to the vena cava.

Hepatic abscesses are common in cattle and may arise by direct implantation of a foreign body from the reticulum or by haematogenous spread from portal vein emboli. At this stage of the investigation, with no signs of a foreign body or reticular changes, no damage of the ruminal mucosa present and no history of dietary acidosis, the origin of the bacterial infection remains unclear.

MORAXELLA BOVOCULI ISOLATED FROM CATTLE WITH INFECTIOUS BOVINE KERATOCONJUNCTIVITIS

Lea Lovrić¹, Zrinka Štritof², Hrvoje Tomšić, Luka Radmanić², Suzana Hadina²,
Vesna Mojčec Perko², Matko Perharić², Zoran Milas², Josipa Habuš²

¹Department of Parasitology and Parasitic Diseases with Clinic, Faculty of Veterinary Medicine,
University of Zagreb, Croatia

²Department of Microbiology and Infectious Diseases with Clinic, Faculty of Veterinary Medicine,
University of Zagreb, Croatia

Infectious bovine keratoconjunctivitis (IBK) is the most common eye disease of cattle that causes significant economic losses. Until now, IBK outbreaks in Croatia were mostly associated with *Moraxella bovis*, although some recent studies described cases caused by *Moraxella bovoculi* and *Moraxella ovis*. The aim of this study was to gain a better insight into the epizootiological situation in our country and to identify *Moraxella* spp. isolated from the herd with the current outbreak of IBK.

The eye swab of an untreated heifer with clinical symptoms of IBK was inoculated on 5% horse blood agar and incubated at 37 °C for 24 h. Bacterial colonies were identified as *Moraxella* spp. based on morphological features and were subcultured for further identification and purification. For differentiating these bacteria, polymerase chain reaction (PCR) coupled with restriction fragment length polymorphism (RFLP) was performed. Genomic DNA was extracted and subjected to PCR using ISR primers (ISRdown: 5'-GTG AAG TCG TAA CAA GGT AGC CGT-3' and ISRup: 5-ACC GAC GCT TAT CGC AGG CTA TCA-3') for amplifying the 16S-23S intergenic spacer region (ISR). The differentiation of *M. bovis* from other species was based on the PCR product size. The obtained band size of ~600 bp was typical of *M. bovoculi* and *M. ovis*. Additionally, amplified DNA was digested with the enzyme *AfaI* in order to distinguish *M. bovoculi* from *M. ovis*. The resulting RFLP pattern was specific for *M. bovoculi* (~150 bp and ~450 bp). Additionally, the PCR product sequencing confirmed the identity of *M. bovoculi*.

The results obtained in this study could explain the occasional failure of immunoprophylactic and/or treatment strategies against IBK described in some of the previous cases. Further research and typing of the obtained isolates would contribute to a better understanding of IBK pathogenesis, improvement of herd management and reduction of economic consequences.

MORPHOMETRIC SIZE AND SHAPE PARAMETERS OF ERYTHROCYTES IN LIKA PRAMENKA SHEEP

Ingo Ralph Albin Lobpreis¹, Ivona Žura Žaja², Branimira Špoljarić³, Silvijo Vince³, Ana Shek-Vugrovečki², Daniel Špoljarić⁴, Nina Poljičak Milas⁵, Suzana Milinković Tur², Luka Pajurin⁴, Dina Jelenčić¹, Tomislav Mikuš⁶, Maja Popović⁴

¹Faculty of Veterinary Medicine, University of Zagreb, Croatia, student

²Department of Physiology and Radiobiology, Faculty of Veterinary Medicine, University of Zagreb, Croatia

³Clinic for Obstetrics and Reproduction, Faculty of Veterinary Medicine, University of Zagreb, Croatia

⁴Department of Veterinary Biology, Faculty of Veterinary Medicine, University of Zagreb, Croatia

⁵Department of Pathological Physiology, Faculty of Veterinary Medicine, University of Zagreb, Croatia

⁶Department of Hygiene, Technology and Food Safety, Faculty of Veterinary Medicine, University of Zagreb, Croatia

In general, data from erythrocytes (RBCs) morphometric parameters in the Pramenka sheep breed have not been investigated. The aims of this study were: to determine the values of haematological and RBCs morphometric size and shape parameters; to form RBCs groups according to the obtained haematological parameters values and to determine the differences of morphometric parameters between the formed RBCs groups.

Thirty-six blood samples were collected from the jugular vein of clinically healthy sheep, between the ages of 2 and 5. Haematological parameters – haemoglobin (Hgb), haematocrit (HCT), mean corpuscular volume (MCV), mean corpuscular haemoglobin (MCH), mean corpuscular haemoglobin concentration (MCHC) and RBCs distribution width (RDW) – were analysed on a haematology analyser. According to the values obtained, RBCs parameters were categorised into two groups: animals with lower values or values below physiological range (groups 1), and those with higher values or values above physiological range (groups 2). Morphometric RBCs size and shape parameters (area, outline, convex, minimal radius, maximal radius, length and breadth, ellipticity, elongation, solidity, roundness, form factor, contour index) were determined in the stained blood smears by using the SFORM computer-assisted program.

Significantly higher values of RBCs area, outline, convex, minimal radius, maximal radius, length, breadth, were established in Hgb 2, HCT 2, MCV 2, MCH 2 and MCHC 2 groups than in Hgb 1, HCT 1, MCV 1, MCH 1 and MCHC 1 groups, respectively. It was found that the average values of RBCs area, outline, convex, minimal radius, maximal radius, length, breadth, solidity and roundness were significantly higher in the RDW 2 group in comparison with the RDW 1 group.

It can be concluded that the values of RBCs morphometric parameters could serve, along with standard haematological analyses, as a basis for the diagnostic interpretation of anaemic syndromes in veterinary medicine, especially concerning normocytic, macrocytic and microcytic anaemia in sheep.

COMPARISON OF TWO DIFFERENT SUTURING (CLOSING) TECHNIQUES AFTER PARTIAL LUNG LOBECTOMY ON OVINE MODEL – EX VIVO STUDY

Sonja Vukelić¹, Mirta Vučković¹, Andrija Musulin¹, Darko Capak¹, Petar Kostešić¹,
Valentina Plichta¹, Dražen Matičić¹, Dražen Vnuk¹

¹*Clinic for Surgery, Orthopaedics and Ophthalmology, Faculty of Veterinary Medicine,
University of Zagreb, Croatia*

Lung lobectomy is used to remove lung tumours, congenital lung anomalies, chronic lung collapse, post-traumatic diffuse parenchymal laceration and bronchial rupture.

A total of 12 lungs, taken from sheep cadavers, were used. The lungs were intubated with a cuffed tube and the tube was connected to an anaesthesia machine. The lungs were left on the same settings for 5 min before the lobectomy. The respiratory rate was 20/min, the inspiratory pressure (IP) was 20 cm H₂O and the air flow was set on 1 L/min. After 5 min, IP was decreased to 10 cm H₂O and the respiratory rate to 10/min. The right cranial lobe was partially removed from all samples. The pulmonary samples were divided into two groups, depending on which lobectomy technique was used. In the first 6 samples, the incision line was closed with overlapping and simple continuous suture in two layers. In the second 6 samples, the incision line was closed by using a blood vessel sealing device.

After the lobectomy, the respiratory rate was raised to 20/min and IP was increased by 2 cm H₂O every 5 breathes. The lungs were submerged in the water for an easier assessment of the incision line failure. IP was increased until it reached the maximum value of 60 cm H₂O. The chi-squared test was used to determine whether there was a significant difference between the numbers of pulmonary samples that exceeded IP of 20 cm H₂O in the two groups.

In the first group, 6/6 reached a value higher than 20 cm H₂O (4/6 reached the value of 60 cm H₂O). In the second group, in which blood vessel sealing was used, bubbles started to appear from the sealed incision site in 2/6, and in 4/6 bubbles started to appear from sites not connected to the lobectomy. The mean value in the second group was 33.5 cm H₂O and 5/6 lungs reached a value higher than 20 cm H₂O. The difference among the two groups related to the number of lungs samples that exceeded IP of 20 cm H₂O was not observed ($p > 0.05$).

In this study, it has been shown that both methods are suitable options for a lobectomy since the optimum value of IP in live animals in anaesthesia should not exceed 20 cm H₂O.

BLOOD CELL COUNT IN BROILER BREEDERS AFTER EXPOSURE TO RADIOFREQUENCY ELECTROMAGNETIC RADIATION

Ana Shek Vugrovečki¹, Ivona Žura Žaja¹, Jadranka Pejaković Hlede¹, Josip Miljković², Krešimir Malarić³, Selim Pašić⁴, Nada Dolenčić⁵, Metka Vlahek⁵, Željko Gottstein⁶, Marinko Vilić¹

¹Department of Physiology and Radiobiology, Faculty of Veterinary Medicine, University of Zagreb, Croatia

²Faculty of Veterinary Medicine, University of Zagreb, Croatia, student

³Faculty of Electrical Engineering and Computing, University of Zagreb, Croatia

⁴Department of Physics, Faculty of Veterinary Medicine, University of Zagreb, Croatia

⁵Galivet d.o.o. Veterinary Clinic, Prelog, Croatia

⁶Department of Poultry Diseases with Clinic, Faculty of Veterinary Medicine, University of Zagreb, Croatia

The results of many studies have shown that the exposure to radiofrequency electromagnetic fields (RF-EMF) at the operating frequency of wireless communication devices or mobile phones can induce various non-thermal biological effects on humans and animals. Previous studies were investigating radiofrequency electromagnetic radiation effects on chicken growth, development, fertility, mutation, and mortality. However, the knowledge of the effect of RF-EMF on haematological parameters in birds is very limited. The objective of this study was to investigate the blood cell count in 55 week-old broiler breeder flocks exposed to RF-EMF.

The flocks were divided into control and experimental groups. The experimental group was exposed to RF-EMF at 2.4 GHz and an average electric field level of 100 mV m⁻¹ for 21 days. The radiofrequency electric field strength and frequency were measured at three locations using the portable spectrum analyser NARDA SRM 3000 (NARDA, USA). There were no other significant sources of electromagnetic radiation.

Blood samples were collected on the heparin anticoagulant from the wing vein before exposure (day 0) and on days 2, 5, 8, 14 and 20 of the experiment. The number of white (WBC) and red blood cells (RBC) from the collected samples was counted in a Neubauer haemocytometer, according to the Natt and Herrick's method.

After the statistical analysis, there was no statistically significant difference between the control and experimental groups with respect to RBC and WBC counts, although the experimental group had lower values of RBC and WBC.

It can be concluded that a short-term exposure (20 days) to RF-EMF at the frequency of 2.4 GHz and field level of 100 mV/m did not induce alteration in the blood cell count in the breeders. Future research should consider the potential effects of RF-EMF on other blood parameters, and research of a longer RF-EMF exposure time should also be made.

EFFECT OF DIETARY HUMIC SUBSTANCES ON BIOCHEMICAL BLOOD PARAMETERS, IMMUNE SYSTEM AND GUT MICROBIOTA OF CHICKEN

Dana Marcincáková¹, Dagmar Mudroňová², Jana Koščová², Martin Bartkovský³, Boris Semjon³, Slavomír Marcincák³

*¹Department of Pharmacology and Toxicology,
University of Veterinary Medicine and Pharmacy in Košice, Slovakia*

*²Department of Microbiology and Immunology,
University of Veterinary Medicine and Pharmacy in Košice, Slovakia*

*³Department of Food Hygiene and Technology,
University of Veterinary Medicine and Pharmacy in Košice, Slovakia*

Humic substances are heterogeneous natural organic molecules with a whole range of positive impacts on growth parameters and animal health. Nowadays, they are considered to be a suitable substitute for antibiotics growth promoters in broiler fattening.

The aim of the work was to evaluate the effect of 0.8% and 1% of humic substances addition to the commercial broiler feed on the biochemical blood parameters, immune system and gut microbiota of chicken.

In the experiment, 150 day-old COBB 500 chickens were randomly divided into three groups (n = 50). All of the chickens were fed with a commercial feed mixture BR1, BR2, BR3 and BR4 (DeHeus, Czech Republic). Two experimental groups were moreover fed with 0.8% and 1% humic substances added to the feed (Humac Natur AFM, HUMAC Ltd., Košice, Slovakia). On the last day of fattening (day 39), 15 chickens were randomly selected from both groups for a subsequent analysis. In the peripheral blood, the selected biochemical parameters and the ratio of the selected lymphocyte subpopulations were analysed. The impact on the gut microbiota composition was also evaluated and compared among all of the groups of chickens.

The reduced concentration of alkaline phosphatase and aspartate aminotransferase was recorded in the broiler blood of both experimental groups. The ratio of CD4+ and CD8+ lymphocytes has shown an increase in immune system stimulation. The positive effect of humic acids on the intestinal microbiota was also manifested by a significant decrease in the number of enterobacteria and a significant increase in the presence of lactic acid bacteria. The ratio of enterobacteria and lactic acid bacteria indicates a positive effect on the gut microbiota.

The positive effect of humic acids on the immune response and the composition of the intestinal microbiota predisposes them for use in protecting and improving animal health.

Acknowledgement: This work was supported by the VEGA 1/0408/17 grant from the Ministry of Education.

EFFECT OF LITTER DEPTH ON BREAST BLISTER OCCURRENCE AND MORPHOLOGICAL CHARACTERISTICS OF *M. PECTORALIS MAJOR* IN BROILERS

Ivana Sabolek¹, Mario Ostović¹, Ivan Vlahek², Aneta Piplica², Kristina Matković¹, Željko Pavičić¹, Srebrenka Nejedli³

¹Department of Animal Hygiene, Behaviour and Welfare, Faculty of Veterinary Medicine, University of Zagreb, Croatia

²Department of Animal Breeding and Livestock Production, Faculty of Veterinary Medicine, University of Zagreb, Croatia

³Department of Anatomy, Histology and Embryology, Faculty of Veterinary Medicine, University of Zagreb, Croatia

Contact dermatitis is a common issue in broiler chickens, which reduces welfare and productivity. It is a condition affecting skin areas in contact with an irritating or unsuitable material. Therefore, litter quality and type are important factors influencing the occurrence of contact dermatitis in broilers, including breast blisters. However, few studies have been focused on the depth of litter being used and different results have been reported.

This study aimed to assess the effect of litter depth on the occurrence of breast blisters, and the number and diameter of muscle fibres of the *m. pectoralis major* in broilers. The study included 120 broilers divided into four equal groups (n = 30 each). Each group was housed on chopped straw at different litter depths (2 cm, 5 cm, 10 cm and 15 cm) during a six-week fattening period. In all of the groups, stocking density was 30 kg/m², the litter was not turned over, nor was new litter added throughout the fattening period. All of the broilers were housed in the same housing and managed in the same way. The occurrence of breast blisters was assessed in a slaughterhouse in all of the chickens by using the Welfare Quality® protocol. Samples of the left *m. pectoralis major* were taken at the slaughter line, as well as from ten randomly selected chickens in each group. The Statistica v. 13.4 software was used for data analysis.

According to the obtained results, there were no differences ($p > 0.05$) in the rate of breast blisters between the groups of broilers. Furthermore, there were no between-group differences ($p > 0.05$) in the mean number of muscle fibres of the *m. pectoralis major*, while the mean diameter of muscle fibres was higher ($p < 0.05$) in broilers housed at 10 cm and 15 cm litter depths than in those at the depths of 2 cm and 5 cm.

It is concluded that litter depth has no impact on the rate of breast blisters and the number of *m. pectoralis major* fibres in broilers, yet it affects the muscle fibre diameter.

COMPOSITION OF FATTY ACIDS IN LIVER, KIDNEY AND SUBCUTANEOUS ADIPOSE TISSUE IN EDIBLE DORMOUSE (*GLIS GLIS*)

Ozren Šiftar¹, Loredana Pincan¹, Marina Prišlin¹, Lana Vranković², Ivančica Delaš³,
Miljenko Bujanić⁴, Dean Konjević⁴, Zvonko Stojević², Jasna Aladrović²

¹Faculty of Veterinary Medicine, University of Zagreb, Croatia, student

²Department of Physiology and Radiobiology, Faculty of Veterinary Medicine, University of Zagreb, Croatia

³Department of Chemistry and Biochemistry, School of Medicine, University of Zagreb, Croatia

⁴Department of Veterinary Economics and Analytical Epidemiology, Faculty of Veterinary Medicine, University of Zagreb, Croatia

The Edible dormouse is Croatian autochthonous game. Hunted dormice can be used in nutrition and dormice oil is traditionally used in wound treatment in some regions of Croatia. So, the objective of this study was to determine the fatty acid (FA) composition of the liver, kidney and subcutaneous adipose tissue (SAT) in Edible dormouse (*Glis glis*) and the influence of gender.

This study was conducted on 17 Edible dormice (10 females and 7 males). Samples of SAT, the liver and the kidneys were collected during the legal hunting season (September–October 2017). The samples of tissues were homogenised, total lipids extracted by using the Folch et al. (1957) method and FA composition was determined by gas chromatography.

The most prevalent FA in the kidneys and SAT of Edible dormice were monounsaturated FA (MUFA). The most prevalent MUFA in both tissues was C18:1cis-9 (53.17 ± 10.53 ; 40.98 ± 9.01 , respectively). The second abundant FA were saturated FA (SFA), with C16:0 (22.29 ± 6.52 ; 19.72 ± 7.94 , respectively) as the most prevalent FA. The least represented were polyunsaturated FA (PUFA), of which the linoleic acid (C18:2n-6) had the highest concentration. The highest number of FA was detected in the liver, and the liver tissue had the highest percentage of PUFA and SFA among the examined tissues. The ratio of n6/n3 in the liver of Edible dormice was 0.85/1.35. The highest percentage of MUFA was detected in SAT. A significantly higher percentage of C18:3n-3 and ratio of n6/n3 was found in the liver and SAT in the male than in the female dormice ($p < 0.05$). We did not find a significant difference in the kidney fatty acid profile between the male and female dormice. In the kidneys, the percentage of the arachidonic acid (AA) was 2.5 times higher than in the liver and SAT.

The fatty acid composition in all three tissues is very similar between males and females, and the n6/n3 ratio is optimal in the liver. The higher percentage of AA in the kidneys could be due to prostaglandins synthesised from AA that influence filtration and reabsorption in the kidneys.

FIRST MOLECULAR CHARACTERISATION OF PARASITES *PARAHELIGMONINA GRACILIS* AND *HYMENOLEPIS SULCATA* IN FAT DORMOUSE (*GLIS GLIS*)

Miljenko Bujanić¹, Magda Sindičić¹, Franjo Martinković¹, Andrea Cafiero², Ivana Busch³, Majda Požega³, Ivan Pervan⁴, Tena Radočaj⁴, Dean Konjević¹

¹Faculty of Veterinary Medicine, University of Zagreb, Croatia

²University of Milan, Italy, student

³Faculty of Veterinary Medicine, University of Zagreb, Croatia, student

⁴Faculty of Agriculture, University of Zagreb, Croatia

The fat dormouse (*Glis glis* L.) is a small arboreal rodent from the family of Gliridae. The species is autochthonous in Croatia and traditionally trapped for meat consumption, use of fat in traditional medicine and for fur. The only previous research of its parasites in Croatia used animals from the alpine Gorski kotar area, and identified nematode *Paraheligmonina gracilis* and cestode *Hymenolepis sulcata*.

The goal of our research was to identify parasites present in the gastrointestinal tract of the fat dormouse from the hunting ground no. XVII/135 Vrgoračko jezero (Dalmatinska zagora – the Mediterranean part of Croatia). The digestive system of 32 fat dormice was examined and the collected parasites were identified using both morphological and molecular methods.

A total of 96.9% of the dormice were infected; *P. gracilis* occurred in 96.9%, and *H. sulcata* in 25.0% of the samples, always in co-infection with *P. gracilis*. The Chi-squared test showed that there was a statistically significant difference in the total infection with *P. gracilis* compared to *H. sulcata*. The odds ratio (OR) showed that the infection with *H. sulcata* is 1.4 times more likely to occur in male than in female dormice. We isolated DNA and sequenced the *P. gracilis* rDNA regions ITS1 and ITS2 and *H. sulcata* ITS2 and the mitochondrial DNA COI region.

DNA sequences of these parasites were not previously published, making this the first molecular description of *P. gracilis* and *H. sulcata*, which will help in resolving their taxonomic positions and phylogeography. These sequences will also be a valuable tool for distinguishing *H. sulcata* from *H. nana* and *H. diminuta*, which cause a globally widespread zoonosis – human hymenolepiasis, a serious concern for public health in many developing and underdeveloped countries.

HAEMATOLOGICAL PARAMETERS OF LARGE CARNIVORES OBTAINED BY BLOOD SMEAR EXAMINATION

Antea Klobučar¹, Dora Jović¹, Josip Kusak², Maja Belić³

¹Faculty of Veterinary Medicine, University of Zagreb, Croatia, student

²Department of Veterinary Biology, Faculty of Veterinary Medicine, University of Zagreb, Croatia

³Department of Pathophysiology, Faculty of Veterinary Medicine, University of Zagreb, Croatia

Large carnivores, the grey wolf (*Canis lupus*), brown bear (*Ursus arctos*) and Eurasian lynx (*Lynx lynx*), are endangered species in Europe, and their populations are an important indicator of quality and environmental preservation. Haematological profile is one of the important indicators of population health. The aim of this study was to assess some haematological parameters from the blood smears and to obtain morphometric features of erythrocytes.

Eighteen blood smears of three different adult carnivores originating from Eastern Turkey were used in this study, 5 from the grey wolf, 9 from the brown bear and 4 from the Eurasian lynx. From the blood smears, the total leukocyte count, differential leukocyte count and reticulocyte percentage were estimated. The diameter, surface area and perimeter of erythrocytes were analysed using the CELL^{AB} special software.

The average leukocyte count in the grey wolf was $12.69 \times 10^3/\mu\text{L}$, the brown bear had $11.93 \times 10^3/\mu\text{L}$ leukocytes and the Eurasian lynx $7.64 \times 10^3/\mu\text{L}$, with segmented neutrophils as the dominant cells in all animals. The reticulocyte percentage in the grey wolf was 4.20%, in the brown bear 1.88% and in the Eurasian lynx 3.75%. In the morphometric analysis, the average diameters in the grey wolf, brown bear and Eurasian lynx erythrocytes were 6.09 μm , 5.51 μm and 5.13 μm , respectively. The erythrocyte surface area in the wolf, bear and lynx was 30.56 μm^2 , 29.51 μm^2 and 24.82 μm^2 , respectively. The erythrocyte perimeter in the wolf, bear and lynx was 23.55 μm , 22.56 μm and 20.62 μm , respectively.

The evaluated total leukocyte count was not significantly altered compared to the literature data for the same species. Since there are no reference values for the reticulocyte percentage as well as for the erythrocytes morphometric features in large carnivores, further studies are required to determine the physiological values in these species. We find our results to be a useful framework for the future research in the field of large carnivores haematology.

MONITORING OF LARGE MAMMALS USING CAMERA TRAPS ON MOUNT VELEBIT

Ira Topličanec¹, Tomislav Gomerčić¹, Josip Tomačić², Tomislav Rukavina², Ivana Selanec³, Vedran Slijepčević⁴, Franjo Špalj⁵, Magda Sindičić¹

¹Faculty of Veterinary Medicine, University of Zagreb, Croatia

²Velebit Nature Park, Croatia

³Association BIOM, Zagreb, Croatia

⁴Karlovac University of Applied Sciences, Karlovac, Croatia

⁵Paklenica National Park, Croatia

Mount Velebit is the largest mountain range in Croatia, around 145 kilometres in length and 30 kilometres in width. Due to various landscapes, it offers different habitats for a large number of species. Using camera traps over an eight-month period, from March to October 2018, we investigated the occurrence of large mammals at different types of microlocations (forest roads, animal forest paths, lynx marking sites, water sources and mineral licks) for two large data sets. In the area of northern Velebit, 21 camera traps recorded 2006 events over 2,517 days, while 14 camera traps in southern Velebit recorded 1,143 events in 2,029 days. In total, we recorded 19 species of wild animals. The most frequent ones were: the roe deer (*Capreolus capreolus*) 16.4%, fox (*Vulpes vulpes*) 10.7% and chamois (*Rupicapra rupicapra*) 9.3%. The jackal (*Canis aureus*), fallow deer (*Dama dama*), hedgehog (*Erinaceus europaeus*) and rock partridge (*Alectoris graeca*) were recorded only in the northern part of Velebit. We found a statistically significant difference ($p < 0.0001$) for a number of events per camera trap daily for the chamois in southern Velebit and for the roe deer, fox (*Vulpes vulpes*), bear (*Ursus arctos*), hare (*Lepus europaeus*), marten (*Martes sp.*) and badger (*Meles meles*) in the northern part. Concerning microlocations, the most common species on the roads were the fox (15.96%), roe deer (12.35%) and red deer (*Cervus elaphus*) (6.33%). The bear (29.55%) and lynx (*Lynx lynx*) (6.82%) were the most frequent at marking sites, while the roe deer was the most common at water sources and in animal forest paths (29.08% and 18.98%). The chamois was the most frequent species visiting salt licks (75.94%). Our study suggests that for future research of the occurrence of large mammals, it is advisable to set camera traps at different types of microlocations. Conversely, when a certain species is targeted, the specific type of microlocation must be chosen in correlation with the activity pattern of the researched species.

HOW MANY PHOTOS ARE OPTIMAL FOR MONITORING OF WILD LARGE MAMMALS WITH CAMERA TRAPS?

Ana Ban¹, Tomislav Gomerčić¹, Ira Topličanec¹, Josip Tomaić², Ivana Selanec³, Vedran Slijepčević⁴, Magda Sindičić¹

¹Faculty of Veterinary Medicine, University of Zagreb

²Velebit Nature Park, Croatia

³Association BIOM, Zagreb, Croatia

⁴Karlovac University of Applied Sciences, Karlovac, Croatia

Over the last two decades, camera traps have become one of the most commonly used non-invasive methods for wildlife research. As there is a wide variety of camera trap models and methodologies, it is challenging to choose the most appropriate ones according to the species being researched, its habitat and research goals. Choosing the appropriate camera settings affects the quality of the data, time needed to analyse them and financial aspects of the research. The aim of this research was to determine which settings of infrared camera traps with active sensors are the most suitable for the monitoring of large mammals on Velebit mountain, Croatia. Velebit is one of the most important diversity hot spots in Croatia, with all three large carnivores (bear, wolf and lynx) present as well as the golden jackal, red fox, roe and red deer, chamois, mouflon and wild boar. A total of 25 camera traps have been placed at 20 locations – forest roads, animal paths in the forest, lynx marking spots, water sources and exhibited salt. We compared the success of the identification of the species and the number of the animals on camera traps with three types of settings – 3 photos, 1 photo + 30-s video, 3 photos + 30-s video. During a total of 2,292 days, 729 events were recorded, and 14 mammal species were identified. The analyses indicated that the camera traps with the setting of 1 photo and 10 seconds of video are the most effective for monitoring large mammals. In 94% of the cases, the species and number of animals were identified in the first out of 3 consecutive photos. In the 30-s videos, the species and number of animals were, on average, successfully identified during the first 5 seconds of the video. A total of 70% of the videos taken after the 3 photos were empty, while 28% of the videos taken after 1 photo were empty, indicating that the videos taken after 3 photos are not useful. The only species with a lower recognition success rate in the first photo was the wild boar, so for the wild boar research we recommend using 2 photos and a 10-second video.

ECONOMIC LOSSES CAUSED BY DISPOSAL OF SKIN AND EDIBLE INTERNAL ORGANS OF THE RED DEER – PRELIMINARY RESULTS

Miljenko Bujanić¹, Nikolina Škvorc², Borjan Rokoš³, Luka Manojlović⁴, Zdravko Janicki¹, Dean Konjević¹

¹Faculty of Veterinary Medicine, University of Zagreb, Croatia

²Faculty of Veterinary Medicine, University of Zagreb, Croatia, student

³Trnsko 24, 10000 Zagreb

⁴Vincenta od Kastva 6, 10000 Zagreb

The red deer is one of the most valued game species. Red deer meat or venison is very similar to bovine meat, while the meat of the hind is more similar to roe deer meat. The fatty acid composition of deer meat has a higher proportion of highly unsaturated fatty acids, making it more suitable for human consumption. During evisceration, a large amount of potentially edible parts are disposed. Besides them, deer skin, once a highly appreciated product, nowadays represents a side product that is sent to the pound as waste. The aim of this paper was to analyse potential economic losses in the hunting ground caused by such practice.

The survey was performed in the state open hunting ground no. VII/15 Zapadna Garjevica (Bjelovar-Bilogora County). A total of 43 red deer carcasses were collected and equally distributed according to sex and age categories. From game meat, only the meat with bones is exploited economically, so there is no available data on the prices of other potentially usable parts. Therefore, we used the prices of the equal parts of cattle carcasses.

The field dressing percentage was 75.7%. Of edible internal organs, the average weight of the red deer heart was 1.18 kg, the kidney 0.39 kg and the liver 2.27 kg, while the average skin mass was 9.82 kg. Without using these organs, the economic loss amounts to an average of HRK 83.95 per animal. According to age categories, the loss per body weight is as follows: 0.75 HRK 0.75 per kg (1 year old), HRK 0.69 per kg (2), HRK 0.67 per kg (3–5) and HRK 0.65 per kg (> 5). With an annual hunting quota of approximately 270 animals, the total loss amounts to HRK 22,666.50.

The financial balance of a hunting ground is usually very fragile. A reduction in any economic losses should be one of the main efforts of each of the hunting ground owners. If we compare the observed loss and the average price of venison for a deer weighing 106 kg on average (a conditional individual – CI), we can notice that with the price of HRK 23 per kg of venison, the total loss is 15 CI (5.6% of the hunting quota).

SERUM BIOCHEMICAL AND HAEMATOLOGICAL VALUES IN GRIFFON VULTURES (*GYPS FULVUS*) BEFORE AND AFTER REHABILITATION AT BELI VISITOR AND RESCUE CENTRE, ISLAND OF CRES, CROATIA

Siniša Faraguna¹, Maja Belić¹, Blanka Beer Ljubić², Sandra Kunštek¹, Romana Turk¹

¹Department of Pathophysiology, Faculty of Veterinary Medicine, University of Zagreb, Croatia

²Laboratory of Clinic for Internal Diseases, Faculty of Veterinary Medicine, University of Zagreb, Croatia

The Griffon vulture (*Gyps fulvus*) is an endangered and the largest bird of prey in Croatia, which is at a considerable risk of extinction. Haematology and blood chemistry values are important diagnostic tools providing useful information on the general health and pathological conditions of individuals. In order to assess the health status and pathological conditions of individual vultures, the knowledge of their normal ranges of blood parameters is essential. The aim of this study was to evaluate blood parameters of Griffon vultures before and after rehabilitation.

Four Griffon vultures (3 immature and 1 adult) admitted to the Beli Visitor and Rescue Centre for Griffon Vultures were included in the study. After a clinical examination, blood samples were collected twice, immediately upon arrival and after rehabilitation. In the collected samples, the complete blood count (CBC) and serum biochemical profiles (GLU, total protein, albumin, globulins, TG, CHOL, BIL, urea, creatinine, Ca, AST, ALT, ALP, CK and LDH) were analysed.

Upon arrival, 2 birds had a lower PCV (23 and 30%, respectively) than after rehabilitation (both birds 48%). Two birds had a lower glucose level upon arrival (13.51 and 13.79 mmol/L) than after rehabilitation (17.4 and 19.89 mmol/L). One bird had a higher urea concentration upon arrival (5.1 mmol/L) than after rehabilitation (0.9 mmol/L). Additionally, there were significant variations in ALT, AST, ALP, CK and LDH enzyme activities in several birds upon arrival than after rehabilitation.

Upon arrival, we found a considerable variation in some parameters, suggesting pathological conditions in some individuals. However, after rehabilitation, the majority of parameters were within the reference range, indicating a proper treatment and care of the animals.

Since data on haematology and blood chemistry baseline values of Griffon vultures are still scarce, our results contribute to a better evaluation of the health status and pathological conditions in this endangered species.

SOME INTERESTING FINDINGS IN WILDLIFE BIRDS IMPORTANT IN FORENSIC VETERINARY PATHOLOGY

Marina Tišljarić¹, Krešimir Severin², Stjepan Brzica³, Hrvoje Capak⁴, Adela Krivohlavek⁵, Lana Bakulić³, Borka Šimpraga¹, Fani Krstulović¹, Lucija Šerić Jelaska⁶, Marko Modrić⁷, Vladimir Savić¹, Relja Beck⁸, Petar Džaja², Vedran Lucić⁹

¹Laboratory for Pathology, Laboratory for Bacteriology and Laboratory for Virology and Serology, Poultry Centre, Croatian Veterinary Institute, Zagreb, Croatia

²Department of Forensic and Judicial Veterinary Medicine, Faculty of Veterinary Medicine, University of Zagreb, Croatia

³Forensic Science Centre Ivan Vučetić, Zagreb, Croatia

⁴Department of Radiology, Ultrasound Diagnostic and Physical Therapy, Faculty of Veterinary Medicine, University of Zagreb, Croatia

⁵Department of Environmental Protection and Health Ecology, Andrija Štampar Teaching Institute of Public Health, Zagreb, Croatia

⁶Department of Biology, Faculty of Science, University of Zagreb, Croatia

⁷Public Institution "Priroda", Rijeka, Croatia

⁸Laboratory for Parasitology, Croatian Veterinary Institute, Zagreb, Croatia

⁹Association BIOM, Zagreb, Croatia

Over the period 2010–2019, a pathomorphological survey of the causes of death of various bird species was done at the Laboratory for Pathology, Croatian Veterinary Institute, Zagreb, Croatia. A total of 5,561 birds were examined. In 325 (5.84 %) wild birds, the primary cause of death was established. Additional examinations (histopathological, radiological, toxicological, bacteriological, mycological, parasitological, virological and entomological) established pathogenesis. The presented cases showed that the greatest threats to health and survival, and the most common causes of acute deaths of wild birds were: (un)intentional poisoning, gunshot wounds, drowning, collision, electrocution, wounds sustained by another animal or man, and disease. Even from the forensic point of view, some points might be interesting:

- 1) According to the authors' experience and literature data, the only possible pathognomonic change in drowning is found in birds (bleeding in the occipital sinus).
- 2) Electrocution should not be assumed from the anamnestic data. Necropsy is necessary for the diagnosis of extremely different gross lesions in various cases.
- 3) Bullets in the bird that has died suddenly do not necessarily have to be the primary cause of death. In birds in which vital organs were spared, but great arteries ruptured, generalised arteriosclerosis was diagnosed.
- 4) Random toxicological analyses of organ samples harvested at necropsy of wildlife birds in 2018 and 2019 (electrocution, drowning etc.) confirmed chronic lead intoxication in several cases. Since chronic intoxication caused by various chemical poisons triggers neurological disturbances before death, routine toxicological analyses at necropsies of wild birds may prove to be vitally important in conserving the entire ecosystem.

MINIMALLY INVASIVE FRACTURE REPAIR OF COMMINUTED TIBIAL FRACTURE IN RING-TAILED LEMUR

Petar Kostešić¹, Mirta Vučković¹, Ana Smajlović¹, Tara Kostanjšek², Filip Kajin³,
Jadranko Boras⁴, Ingeborg Bata⁴, Hrvoje Capak⁵, Boris Pirkić¹

¹Clinic for Surgery, Orthopaedics and Ophthalmology, Faculty of Veterinary Medicine,
University of Zagreb, Croatia

²Faculty of Veterinary Medicine, University of Zagreb, Croatia, student

³Clinic for Internal Diseases, Faculty of Veterinary Medicine, University of Zagreb, Croatia

⁴Zagreb Zoo, Zagreb, Croatia

⁵Department of Radiology, Ultrasound Diagnostic and Physical Therapy,
Faculty of Veterinary Medicine, University of Zagreb, Croatia

The *Lemur catta* is a large arboreal/terrestrial quadruped from the suborder *Strepsirrhini* in the order *Primata*. Despite being the most populous lemur in zoos worldwide, the ring-tailed lemur is listed as endangered by the IUCN Red List due to habitat destruction and hunting. Lemurs are highly social animals, living in large groups with a strict, female-dominant hierarchy.

A 9-year-old, male, intact, healthy ring-tailed lemur from the Zoo was presented with a non-weightbearing hindlimb. It was sedated with an IM injection of 0.035 mg/kg medetomidine, 3.5 mg/kg ketamine and 0.1 mg/kg midazolam. A clinical exam showed evidence of a fracture of the left crus. An X-ray study found a comminuted tibial and fibular fracture. An IV catheter was placed into the cephalic vein, and midazolam (0.25 mg/kg) was applied. General anaesthesia was induced with propofol 2 mg/kg IV. The lemur was intubated and 2% isoflurane was used to maintain anaesthesia. Hydration was maintained with 0.9% NaCl 10 mL/kg/h IV. Epidural analgesia was provided by using 1% lidocaine 0.15 mg/kg. End tidal CO₂, ECG, capnography, pulse oximetry, oesophageal temperature and non-invasive blood pressure were continuously monitored.

A medial, minimally invasive portal approach to the tibia was used, and an intramedullary pin was introduced. A titanium 2.4 mm locking plate was pre-contoured, applied to the tibia and fixed with six screws. The incision sites were reconstructed with a monofilament absorbable suture (Maxon 3-0, Covidien) in three layers. Analgesia was provided with meloxicam (0.1 mg/kg IV), and maintained perorally for the next five days.

The recovery from the surgery was uneventful, and the lemur started weightbearing within a few days. It was kept in contact with the group, but in a secluded den. A control X-ray study after four weeks showed a significant callus formation and the lemur was introduced back into the group after six weeks. To the authors' knowledge, this is a first report of an osteosynthesis in a lemur.

DENTAL TREATMENT IN THREE RED-NECKED WALLABIES (*MACROPUS RUFOGRISEUS*) – A CASE SERIES

Mirta Vučković¹, Petar Kostešić¹, Sonja Vukelić¹, Niko Ivkić², Iva Šmit³, Jadranko Boras⁴, Ingeborg Bata⁴, Hrvoje Capak⁵, Dražen Matičić¹

¹Clinic for Surgery, Orthopaedics and Ophthalmology, Faculty of Veterinary Medicine, University of Zagreb, Croatia

²Faculty of Veterinary Medicine, University of Zagreb, Croatia, student

³Clinic for Internal Diseases, Faculty of Veterinary Medicine, University of Zagreb, Croatia

⁴Zagreb Zoo, Zagreb, Croatia

⁵Department of Radiology, Ultrasound Diagnostic and Physical Therapy, Faculty of Veterinary Medicine, University of Zagreb, Croatia

The red-necked wallaby or Bennett's wallaby (*Macropus rufogriseus*) is a medium-sized macropod marsupial (wallaby), which inhabits the coastal forests of eastern and southeastern Australia and Tasmania. They have been trapped extensively for fur and persecuted by ranchers. However, the population numbers have recovered in recent years and they are now common to abundant throughout most parts of their range.

Three intact, red-necked wallaby females, all aged 6 years, from the local zoo were presented with a history of inappetence, difficulties with food intake, hypersalivation, scratching of the head, hiding and social avoidance. The animals were sedated by IM darting with a cocktail of dexmedetomidine 0.05 mg/kg, ketamine 3.5 mg/kg and butorphanol 0.3 mg/kg. A clinical examination revealed severe oral inflammation, broken, missed and infected teeth, bone expansion and loss of periodontal attachment, diagnosed by periodontal probing. Dental radiography showed severe alveolar bone loss in the area of the maxillary incisors, connective tissue attachment loss and bone resorption.

Under the general anaesthesia, maintained with 2% sevoflurane, dental cleaning was performed by using power scalers. Infraorbital nerve blocks with 0.5% bupivacaine was used for all three surgical procedures. Extraction was the treatment of choice for maxillary incisors, and an open method tooth extraction was performed. Periodontal flaps were used for gingival reconstruction.

Postoperative care included analgesia with meloxicam 0.1 mg/kg administered SC once, and then PO for seven more days, and antibiotic treatment with clindamycin 22 mg/kg PO, given with food, for seven days.

All three animals were returned to their den immediately after recovery from the surgery. Food was not withheld, and they started to eat within a day.

Dental radiography was performed 30 days post-surgery, showing good healing without signs of inflammation or secondary lesions in all three animals.

GRANULAR CELL TUMOUR IN CENTRAL NERVOUS SYSTEM OF FERRET (*MUSTELA PUTORIUS FURO*)

Branka Artuković¹, Ivana Mihoković¹, Lidija Medven Zagradišnik¹, Marko Hohšteter¹,
Ivan Conrado Šoštarić Zuckermann¹, Doroteja Huber¹, Željko Grabarević¹,
Andrea Gudan Kurilj¹

¹*Department of Veterinary Pathology, Faculty of Veterinary Medicine, University of Zagreb, Croatia*

Granular cell tumours (GCTs) encompass a histogenetically heterogeneous group of tumours reflecting still unsolved histogenesis of these tumours. So far, GCT has been reported in ferrets only within the nervous system. To the authors' knowledge, this is the second report of GCT in the ferret family.

A 5-year-old castrated female ferret without clinical signs of disease was temporarily put in care. A routine health check was done beforehand. The level of troponins was slightly elevated. A heart ultrasound, ECG and X-ray were performed, without reaching the final diagnosis. After three weeks, the animal showed lameness (right hind leg), which progressed and it became totally ataxic. The animal developed inappetence and incontinence. It was treated with Sucralfat and Meloxoral. Despite of the therapy, the animal died two days later and was submitted to necropsy.

Grossly, the most significant finding was a 14x15 mm white to grey friable expansive well-demarcated mass in the medial to caudal part of the left frontal lobe that compressed adjacent brain tissue and expanded towards subependymal areas of the left lateral ventricle. Histologically, the mass was composed of sheets and nests of large round to polygonal cells admixed with a few spindle-shaped cells supported by a sparse fibrovascular stroma. Neoplastic cells had abundant granular pale eosinophilic cytoplasm and round nuclei with stippled chromatin and a single central nucleolus. Mitotic figures were rare. Within the mass (centrally), there were necroses and haemorrhage. The tumour cells granules were PAS-positive, and the cells were positive for vimentin and less so for S-100 protein. The described mass was diagnosed as GCT.

In conclusion, intracranial neoplasms are rare in ferrets, but should be considered as a differential diagnosis in animals with neurologic signs.

OSSEOUS METAPLASIA IN CILIARY BODY OF GUINEA PIG – A CASE REPORT

Valentina Plichta¹, Marija Mamić¹, Zoran Vrbanac², Tajna Kovač³, Hrvoje Capak²,
Nika Brkljača Bottegato¹, Dražen Vnuk¹, Boris Pirkić¹

¹*Clinic for Surgery, Orthopaedics and Ophthalmology, Faculty of Veterinary Medicine, University of Zagreb, Croatia*

²*Department of Radiology, Ultrasound Diagnostic and Physical Therapy, Faculty of Veterinary Medicine, University of Zagreb, Croatia*

³*Veterinarska ambulanta Šegota Veterinary Clinic, Zagreb, Croatia*

Osseous metaplasia has been reported within ocular lesions in humans and some animals. Clinically, it is presented as a white irregular mass with variable vascularisation that extends throughout the root of the iris into the anterior part of the anterior chamber. In guinea pigs, this formation is often called heterotopic bone formation or osseous choristoma. Histologically, it consists of bony spicules surrounded by a fibrous envelope, sometimes with haematopoietically active marrow. Guinea pigs are susceptible to ectopic mineralisation due to dietary factors. Affected animals tend to be older, with 15% of them having mineralisation elsewhere.

A male guinea pig, 4 years old, was presented for an ophthalmologic examination due to enlargement of the right eye and blink inability that lasted for three days. White irregular plaques were noted in the iridocorneal angle that extended onto the anterior surface of both irides. The findings were significantly more present in the right eye, with the involvement of the iridocorneal angle throughout the whole circle. Intraocular pressures were measured by applanation tonometry valued 27 mmHg for the right eye and 17 mmHg for the left eye (normal limits range from 13 to 21 mmHg). Fluorescein stain did not reveal any corneal lesions. A radiopaque ring of mineral origin was noted on radiography in both irides. The guinea pig was treated with carbonic anhydrase inhibitors (dorzolamide 2% with timolol 0.5%) two times daily for the right eye. After two weeks of therapy, the blink reflex returned to normal, and the intraocular pressure in the right eye decreased to the normal range and valued 21 mmHg.

Osseous metaplasia of the ciliary body can be a common finding in older guinea pigs and usually has no clinical significance. This case presents a complication of osseous metaplasia by narrowing the iridocorneal angle, causing secondary glaucoma, which can be successfully treated with carbonic anhydrase inhibitors.

FIRST REPORTED CASE OF LEPORINE DYSAUTONOMIA IN CROATIADoroteja Huber¹, Andrea Gudan Kurilj¹, Ivan Conrado Šoštaric Zuckermann¹¹Department of Veterinary Pathology, Faculty of Veterinary Medicine, University of Zagreb, Croatia

Leporine dysautonomia (or dysautonomia of hares) is an idiopathic disorder associated with degeneration of neurons of the peripheral nervous system, with a loss of sympathetic and parasympathetic nerve function. The disease has so far been described in rabbits and hares from Great Britain, and a similar disorder has also been described in horses (grass sickness), dogs and cats (Key-Gaskell syndrome). We are describing the first case of leporine dysautonomia in a rabbit from Croatia.

A female rabbit (*Oryctolagus cuniculus*) of unknown age and breed was submitted for necropsy to the Department of Veterinary Pathology. No history data was provided except the existence of unspecified neurologic signs. The rabbit was subjected to a full necropsy and representative slices of all organs were fixed in 10% neutral, buffered formalin, routinely dehydrated, embedded into paraffin and stained with haematoxylin and eosin.

Gross findings included cachexia, dehydration, dilated intestines and urinary bladder. The small intestine was filled with small amounts of orange mushy content and gas. The large intestine was filled with a moderate amount of mushy, green content and small amounts of gas, without the presence of caecotrophs. The mucosa of the entire intestine was grossly normal. Other organs did not show gross lesions, but were dark red in colour, indicating congestion. Due to the presence of all permanent teeth and thymus, the rabbit was presumed to be juvenile to young adult. Histologic findings included severe vacuolation of neurons of the submucous and myenteric plexus in the intestinal tract. Based on gross and microscopic pathologic findings, leporine dysautonomia was diagnosed.

Dysautonomia is a disorder that rarely affects rabbits. However, based on the results of the current report, the disorder is present in Croatia and it has to be considered as a possible differential diagnosis in animals with neurological symptoms and mild gross findings including cachexia and distension of the intestines and urinary bladder.

INFLUENCE OF FASTING AND REFEEDING ON GLUCOSE-6-PHOSPHATE DEHYDROGENASE, GLUTATHIONE AND LIPID PEROXIDE CONCENTRATION IN CHICKEN BLOOD

Morana Orban¹, Zvonko Stojević², Lana Vranković², Jasna Aladrović²

¹*Faculty of Veterinary Medicine, University of Zagreb, Croatia, student*

²*Department of Physiology and Radiobiology, Faculty of Veterinary Medicine, University of Zagreb, Croatia*

Avian metabolism is more intense than metabolic rate in mammals. Therefore, the consumption of oxygen in avian species is more intensive, which means that birds are exposed to a higher oxidative stress due to an increased level of free radicals. The objective of this study was to determine the influence of fasting and refeeding on the concentrations of glutathione (GSH) and lipid peroxide measured as reactive products of the thiobarbituric acid (TBARS) in blood and the glucose-6-phosphate dehydrogenase (G6PDH) activity in chicken erythrocytes.

At the age of 61 days, Lohman Brown cockerels were exposed to a 48-h fasting and afterwards to a 24-h refeeding. The blood for the analysis was taken from the wing vein before fasting (control values), after the 48-h fasting, and then 24 h after refeeding. The concentrations of GSH and TBARS and the activity of G6PDH were determined and expressed per gram haemoglobin.

In cockerels, the concentration of GSH in blood after refeeding was significantly higher than the control and fasting values. The TBARS concentration did not show significant differences throughout the experiment. The activity of G6PDH after the 24-h refeeding significantly decreased compared to the control level.

Based on the results, we can conclude that the GSH concentration during 48 h was maintained at similar levels as the control values, probably due to the transport from the liver and other organs. After refeeding, GSH was increased considering the absorption from the intestine and synthesis, which compensated the reduced G6PDH activity. Lipid peroxidation decreased as a result of a lower intensity of metabolism during fasting.

EFFECTS OF ZEOLITES ON FORMATION OF PATHOLOGICAL RECTAL LESIONS IN RATS

Marta Šurbek¹, Ana Zupčić¹, Mateo Makšan¹, Mirna Čoklo², Vedran Micek³,
Ivan Conrado Šoštarić Zuckermann⁴, Ivana Mihoković⁴, Lea Lovrić⁵,
Marina Sinković⁶, Anja Samardžić⁷, Krešimir Pavelić⁸, Marko Hohšteter⁴

¹Faculty of Veterinary Medicine, University of Zagreb, Croatia, student

²Teaching Institute of Public Health of Primorje-Gorski Kotar County, Rijeka, Croatia

³Institute for Medical Research and Occupational Health, Zagreb, Croatia

⁴Department of Veterinary Pathology, Faculty of Veterinary Medicine, University of Zagreb, Croatia

⁵Department of Parasitology and Invasive Diseases with Clinic, Faculty of Veterinary Medicine, University of Zagreb, Croatia

⁶Oktal Pharma, Zagreb, Croatia

⁷Pavešić Veterinary Practice, Bakar, Croatia

⁸Department of Natural and Health Studies, Juraj Dobrila University of Pula, Croatia

Colorectal cancer is one of the most common types of cancer in humans. Azoxymethane (AOM) is a chemical mutagen used for tumour induction in rats, which can serve as a model for colorectal tumour research due to similarities with colorectal tumour in humans. Among others, they include the similarities in the response to various preventive substances. Zeolites are a group of volcanic minerals related to many medical effects.

A total of 95 female rats were used for the purpose of the research. The animals were divided into five groups; positive (treated with AOM) and negative control (not treated with AOM and zeolite), plus three test groups (treated with AOM and zeolite). The animals were euthanised and samples from the rectum were submitted for a histopathological analysis. The aim of this study was to evaluate the impact of zeolites on rectal lesions.

The presence of an infiltrate was found in 16% of the samples in the negative control group, 35% in the positive control group, and 31%, 76% and 65% in groups T1, T2 and T3, respectively. The infiltrate was classified by the cell type as lymphoplasmacytic. According to the intensity, the infiltrate was in most cases described as mild. Statistically significant differences were confirmed ($p < 0.01$) in the intensity, distribution, localisation and infiltrate type between a particular test and control groups. Proliferative lesions were found in 7.7% of the samples and were divided into three groups: adenomas, carcinomas and hyperplasias. The proliferative lesions were described in 12% of the positive control samples and were classified as benign hyperplasia. In groups T2 and T3, the lesions were classified as tubulopapillary adenocarcinoma, with the incidence of 6%. In the T1 group, proliferative changes were confirmed in 12% of the samples and all were benign, classified as hyperplasia and adenoma.

In this study, no positive impact of zeolites on rectal lesions was observed. Potentially negative effects of zeolites should be further examined.

INFLUENCE OF ZEOLITE AND AZOXYMETHANE ON DEVELOPMENT OF PATHOLOGICAL LESIONS IN CAECUM OF RATS

Ana Zupčić¹, Marta Šurbek¹, Mateo Makšan¹, Mirna Čoklo², Vedran Micek³, Ivan Conrado Šoštarić Zuckermann⁴, Ivana Mihoković⁴, Lea Lovrić⁵, Marina Sinković⁶, Anja Samardžić⁷, Krešimir Pavelić⁸, Marko Hohšteter⁴

¹Faculty of Veterinary Medicine, University of Zagreb, Croatia, student

²Teaching Institute of Public Health of Primorje-Gorski Kotar County, Rijeka, Croatia

³Institute for Medical Research and Occupational Health, Zagreb, Croatia

⁴Department of Veterinary Pathology, Faculty of Veterinary Medicine, University of Zagreb, Croatia

⁵Department of Parasitology and Invasive Diseases with Clinic, Faculty of Veterinary Medicine, University of Zagreb, Croatia

⁶Oktal Pharma, Zagreb, Croatia

⁷Pavešić Veterinary Practice, Bakar, Croatia

⁸Department of Natural and Health Studies, Juraj Dobrila University of Pula, Croatia

Recently, a large number of research studies have tried to investigate the carcinogenic effect of the environment and food in order to identify pharmacologically active substances that would prevent or delay the onset of cancer. Zeolites are a group of volcanic minerals that can be created naturally or produced industrially. Zeolites have a large number of medical effects, so they are used in both human and veterinary medicine. Azoxymethane is a chemical mutagen and tumour-initiating compound, which is commonly used in rat models of colon cancer.

The aim of this study was to investigate the possible inhibitory effects of zeolite on azoxymethane-induced cancer of the caecum in rats.

For the purpose of the research, a total of 95 female rats were used. The rats were divided into five groups: positive and negative control group and three test groups. The animals were sacrificed 42 weeks after the second injection of azoxymethane to estimate the effect of the treatment in order to ensure enough time for the tumour development, and samples from caecum were submitted for a pathohistological analysis.

The pathohistological analysis of the histological slides identified changes that include: the presence of infiltrates, fibrosis, oedema and lymphoid hyperplasia. Finally, the results indicate that there were no positive impacts of zeolite on caecal lesions and we suggest further research.

IMMUNOMODULATION ROLE OF EM® PROBIOTIC IN NOSEMA SPP. SPORES NUMBER AND CONCENTRATIONS OF VITELLOGENIN IN HAEMOLYMPH OF HONEYBEE (*APIS MELLIFERA*)

Petra Šoštarić¹, Josipa Vlainić², Zlatko Tomljanović³, Ivana Tlak Gajger¹

¹Department of Biology and Pathology of Fish and Bees, Faculty of Veterinary Medicine, University of Zagreb, Croatia

²Division of Molecular Medicine, Ruđer Bošković Institute, Zagreb, Croatia

³Ministry of Agriculture, Zagreb, Croatia

Nosema disease is a parasitic disease of adult honeybees caused by microsporidia from the genus *Nosema*. It has detrimental effects on the strength, productivity and immune suppression of honeybee colonies, so an appropriate control of this disease is advisable. Effective microorganisms are combinations of numerous species of useful microbes, which are widely used in different fields.

As a novel approach in the therapy, we hypothesise that the EM® PROBIOTIC for beekeeping usage could play an important role in the suppression of a *Nosema* spp. invasion and in stimulating the synthesis of vitellogenin, which has an impact on immunological responses and pathogen defence at both individual and honeybee colony level. The aim of this study was to determine the influence of additional feeding of honeybee colonies with the EM® PROBIOTIC for beekeeping usage on the previously mentioned parameters, in controlled and field conditions.

Honeybee colonies fed probiotic were given a sugar solution, with three different dilutions (2.5%; 5%; 10%) of the commercial probiotic called EM® PROBIOTIC FOR BEES. The sampling of workers' haemolymph was performed on the 13th and 22nd day after the initial feeding. The number of *Nosema* spp. spores was determined by counting spores using a Malassez haemocytometer, and the concentrations of vitellogenin in the haemolymph samples were determined by the MyBioSource ELISA kit using a spectrophotometer.

The results showed that the concentrations of vitellogenin increased and were significantly different ($p < 0.05$) in the haemolymph samples of the experimental groups in comparison with the control groups on the 13th day after the initial feeding. Similarly, the experimental colonies showed a significant decrease in the number of *Nosema* spp. spores in comparison with the control group during the field test.

The obtained results have presented valuable insights into the possible immunomodulation in honeybees and into the novel biotechnological approach that may address the current needs of global beekeeping.

ANALYSIS OF TERPENES IN *MATRICARIA PERFORATA* AND *THYMUS PULEGIOIDES* ON GEA-COM LTD. PASTURES USING GC-MS

Luka Pajurin¹, Željka Cvrtila¹, Tomislav Mikuš¹, Lidija Kozačinski¹, Ksenija Vlahović¹, Daniel Špoljarić¹, Goran Kiš², Maja Jelena Čop³, Ivana Bačić³, Vedran Šegota⁴, Maja Popović¹

¹Faculty of Veterinary Medicine, University of Zagreb, Croatia

²Faculty of Agriculture, University of Zagreb, Croatia

³Forensic Science Centre Ivan Vučetić, Zagreb, Croatia

⁴Faculty of Science, University of Zagreb, Croatia

The identification and monitoring of specific plant biomarkers in animal products and tissues can be related to feed and nutrition, whereby lamb meat from lambs fed on pasturage contains more phenols, terpenes, indoles and sulphur compounds. Aromatic herbs, as a part of the hey/pasturage botanical composition, can affect sheep's/lamb's health, quality and aroma profile with their bioactive molecules. Numerous studies have confirmed a better aroma, colour and quality of lamb meat and a more favourable composition of fatty acids. It all points to the possibility of producing functional lamb meat.

During May, June and July 2019 on the pastures of GEA-COM Ltd. (Crkvina), there was a noticeable occurrence of *Matricaria perforata* and *Thymus pulegioides*, both of which were rich in terpenes and terpenoids. Therefore, within the scope of the research, the content of aromatic hydrocarbons and derivatives in *Matricaria perforata* and *Thymus pulegioides* is determined using a gas chromatographic and mass spectrometric analysis (GC-MS).

The chemical composition of *Matricaria perforata* identified by the GC-MS data is listed: naphthalene, phenanthrene, benzophenone, trans-anethole, β-farnesene, aromadendrin, α-bisabolol and matricarin. The constituents found in *Thymus pulegioides* were α-pinene, camphene, β-pinene, myrcene, eucalyptol, carene, β-ocimene, *allo*-ocimene, bornyl acetate, α-copaene, β-bourbonen, caryophyllene, β-cubeben, α-bergamotene, germacrene D, bicyclogermacrene, α-farnesene, δ-cadinene, spathulenol and caryophyllene oxide.

Since the breeding and feeding system of lambs on the GEA-COM Ltd. farm may have a significant influence on lamb meat aroma or on the composition of volatile compounds, it is the project's (HRZZ; IP-2016-06-3685) interest to determine the chemical composition (terpenes) of aromatic herbs from the Crkvina pastures. The results could contribute to a better understanding of the environmental impact (plant flora) on the quality and aroma of the Lika Pramenka lamb meat.

EARLY DETECTION OF *THELOHANELLUS NIKOLSKII* INFECTION BY ALCIAN BLUE-ALIZARIN RED S DOUBLE STAINING TECHNIQUE

Lucija Bastiančić¹, Snježana Kužir¹, Krešimir Drašner², Krešimir Matanović³, Ivan Vlahek⁴, Emil Gjuričević³

¹Department of Anatomy, Histology and Embryology, Faculty of Veterinary Medicine, University of Zagreb, Croatia

²IHOR PARK Fish Farm, Jastrebarsko, Croatia

³Department of Biology and Pathology of Fish and Bees, Faculty of Veterinary Medicine, University of Zagreb, Croatia

⁴Department of Animal Breeding and Livestock Production, Faculty of Veterinary Medicine, University of Zagreb, Croatia

Thelohanellus nikolskii Akhmerov, 1955 is a non-native myxosporean parasite, which was originally described in eastern Russia and Vietnam. The life cycle of *T. nikolskii* has two phases. The aurantiactinospore phase takes place in an annelid host (*Tubifex tubifex*), while the myxospore phase occurs in the common carp (*Cyprinus carpio*). In the common carp, the parasite forms large polysporic plasmodia in the fins and scales. This study describes a case of thelohanellosis caused by *T. nikolskii* in semi-intensively cultured 47-day old common carp fry.

The common carp fry was sampled on a fish farm in Croatia, during the regular monitoring of the health status. A total of 140 fry were sampled from 5 to 47 days post hatching (DPH). The collected fry were killed by an overdose of tricaine methane sulfonate (MS 222) and a complete parasitological examination was conducted. The Dingerkus and Uhler (1977) method was used for the demonstration of the ossification process and development of *Thelohanellus* infection. The stained samples were analysed by an Olympus SZX7 stereoscopic microscope, by using a digital camera (Olympus DP12) and the Cell B software (Soft Imaging System).

T. nikolskii infection was found in only 1 specimen at the age of 47 DPH. By 47 DPH, the whole skeleton of the common carp was almost completely ossified. The infection was characterised by the presence of numerous plasmodia on the entire surface of the fins. In this Alcian Blue-Alizarin Red S stained fry, plasmodia were not difficult to detect and were located on the fin rays, on the surface of the hemisegments. At the site of the infection, *T. nikolskii* produced a weakly blue stained 'cartilaginous capsule'. Within this capsule, small cartilaginous and/or bony islets were observed.

Today, this pathogenic *Thelohanellus* species is widely distributed among Croatian fish farms.

FELINE PATHOLOGIC CHANGES DIAGNOSED USING CYTOLOGY

Tonka Ristevski¹, Ivan-Conrado Šoštarčić-Zuckermann², Maja Maurić³, Andrea Gudan Kurilj², Marko Hohšteter², Lidija Medven Zagradišnik², Ana Beck², Doroteja Huber²

¹Faculty of Veterinary Medicine, University of Zagreb, Croatia, student

²Department of Veterinary Pathology, Faculty of Veterinary Medicine, University of Zagreb, Croatia

³Department of Animal Breeding and Livestock Production, Faculty of Veterinary Medicine, University of Zagreb, Croatia

The microscopic analysis of cytological samples is a simple, fast, cheap and minimally invasive method for diagnosing pathologic changes in cats, used routinely in many veterinary clinics. This research has examined all changes that were diagnosed in cats from cytological samples delivered to the Department of Veterinary Pathology from 2009 to 2018.

The diagnosed changes were classified as one of the following categories: "neoplasia", "inflammation", "other pathologic changes" or "nondiagnostic samples", based on the reported criteria for a cytological examination. For each change, breed, age, gender and anatomic location were analysed by using statistics to determine whether these variables were connected to the diagnosed change.

The total number of examined samples, which originated from an approximately equal number of males (49%) and females (51%), was 306. The most frequent change was neoplasia (44%), while inflammation (20%), other pathologic changes (18%) and nondiagnostic samples (18%) were detected in a similar number of the cats. Round cell neoplasia was the most frequent neoplasia (33%), followed by mesenchymal (31%) and epithelial neoplasia (28%). The most common breed was domestic short-haired, but there was no connection between the breed and the category. Pathologic changes were diagnosed in altogether 10 organ systems, of which the skin was the most frequent. The average age of the examined cats was 8.4 years (y), with a variation between categories: the average age of the cats with neoplasia was 9.2 y, with inflammation 8.0 y, with other pathologic changes 8.6 y and with nondiagnostic samples 7.7 y. The most frequent type of inflammation was purulent, followed by pyogranulomatous inflammation. Other types of inflammation were diagnosed in a low number of the cats. Reactive hyperplasia of lymph nodes was the most frequent among other diagnosed pathologic changes.

In conclusion, the most frequently diagnosed pathologic changes in the cats were neoplasia, which corresponds to literature data. The most frequent neoplasia was round cell neoplasia, which is the most common neoplasia in cats. The skin was the most frequent tissue sampled, probably due to easy accessibility.

CLINICAL AND CYTOLOGICAL CHARACTERISTICS OF LINGUAL SQUAMOUS CELL CARCINOMA IN FIVE CATS

Marija Lipar¹, Marko Hohšteter², Berislav Radišić¹, Ozren Smolec¹, Branka Artuković², Ivan-Conrado Šoštarić-Zuckermann², Gordana Gregurić Gračner⁴, Jadranka Bubić-Špoljar³, Andrija Musulin¹, Marko Pećin¹

¹*Clinic for Surgery, Orthopaedics and Ophthalmology, Faculty of Veterinary Medicine, University of Zagreb, Croatia*

²*Department of Veterinary Pathology, Faculty of Veterinary Medicine, University of Zagreb, Croatia*

³*Department of Biology, School of Medicine, University of Zagreb, Croatia*

⁴*Department of Animal Hygiene, Behaviour and Welfare, Faculty of Veterinary Medicine, University of Zagreb, Croatia*

The oral cavity is the fourth most common site of neoplasia in cats, and the great majority of tumours such as squamous cell carcinoma (SCC) are malignant. There is no sex predisposition to SCC in cats and it appears mostly in older cats. Predisposing factors could be a viral infection, a chronic bacterial infection located in the oral cavity and a mechanical irritation of the tongue.

Feline oral SCCs are highly invasive, but have a low metastatic potential. Therefore, they cause the majority of pathologic changes at the site. The most common clinical signs of lingual tumours are excessive salivation, inability to eat or drink, an enlargement of the tongue, bleeding and anorexia. Differential diagnoses include leukoplakia, papilloma, fibroma and adenoma.

Five female mixed-breed cats, aged from 6 to 16 years, were presented at the Clinic for Surgery, Orthopaedics and Ophthalmology at the Faculty of Veterinary Medicine, Zagreb. Tumours were observed at the ventral or dorsal part of the tongue basis. The X-ray of the thorax was unremarkable in all of the cases. The blood count showed a mild anaemia and leukocytosis. A fine needle aspiration (FNA) of the tumours was performed and cytological specimens were stained by using the Giemsa method. In all of the cases, squamous cell carcinoma was diagnosed. The cytological findings in all of the cases showed the presence of a large number of single, large keratinocytes and irregular groups of cuboid, small, basal cell types. There were also poorly differentiated epithelial, polygonal cells with moderate anisocytosis and anisokaryosis, scant cytoplasm and large nuclei with prominent nucleoli. There was also an inflammatory reaction characterised by the presence of neutrophils and macrophages.

In all 5 cases, the tumours were inoperable due to the size of the tumours as well as their position. Symptomatic and supportive therapy was administered.

EVIDENCE OF OTITIS EXTERNA IN FREE-ROAMING CATS BASED ON OTOSCOPIC EXAMINATION AND CYTOLOGICAL EVALUATION

Magdalena Kolenc¹, Dragan Petrović², Ljiljana Pinter³, Zrinka Štritof³, Josipa Habuš³, Vladimir Stevanović³, Matko Perharić³, Suzana Hadina³

¹Department of Anatomy, Histology and Embryology, Faculty of Veterinary Medicine, University of Zagreb, Croatia

²Nera Small Animal Veterinary Practice, Zagreb, Croatia

³Department of Microbiology and Infectious Diseases with Clinic, Faculty of Veterinary Medicine, University of Zagreb, Croatia

Some studies reported the prevalence of feline otitis externa in the range from 2 to 55.1%, mainly in pet cats. The aim of this study was to determine the presence of otitis externa in free-roaming cats by means of an otoscopic examination and cytological evaluation of the external ear canal.

Ear swabs were collected from 74 cats during the Trap-Neuter-Release project. The ear pinnae were inspected and an otoscopic examination of the external ear canal and tympanum was performed. Microscope slides with swab impressions were stained. Cocci, rods and *Malassezia* were counted under oil-immersion microscopic fields. The diagnosis of otitis was made based on the recommended threshold values of counted cell numbers together with the clinical signs. The mineral oil technique was used to evaluate the collected cerumen for the presence of ear mites at low microscopic magnification.

Clinically, otitis externa was detected in 45.9% of the cats, bilaterally in 97.1% and unilaterally in 2.9% of the cats. Crusty lesions were observed on the pinna of 17.6% of the cats. In 88.2% of the cases, otitis externa was presented by a large amount of cerumen, mainly black in colour (82.4%) and of a crumbly consistency (55.9%). A cytological examination showed the prevalence of otitis externa in 79.4% of the cats with the clinical signs of inflammation. *Malassezia* yeasts together with *Otodectes cynotis* was detected in 55.6%, followed by *Malassezia* spp. alone in 40.7% of the cats with otitis. Coccoid bacteria were associated with otitis in 3.7% of the cats, while rod-shaped bacteria were always observed together with cocci, *Malassezia* spp. or *O. cynotis*.

This study demonstrated a high prevalence of ear inflammation in free-roaming cats, with *O. cynotis* mites and *Malassezia* spp. identified as the most prevalent causes. In addition, there was a good overlap between the clinical signs of otitis externa and the cytological results. These data represent rare and valuable information about otitis in free-roaming cats.

HEART RATE VARIABILITY DURING 'KITTY MAGIC' ANAESTHESIA

Biserka Zidar¹, Nadica Maltar-Strmečki², Lana Vranković³, Ljiljana Bedrica⁴,
Jasna Aladrović³

¹*Horvat Veterinary Practice, Krapinske Toplice, Croatia*

²*Division of Physical Chemistry, Ruđer Bošković Institute, Zagreb, Croatia*

³*Department of Physiology and Radiobiology, Faculty of Veterinary Medicine, University of Zagreb, Croatia*

⁴*Clinic for Internal Diseases, Faculty of Veterinary Medicine, University of Zagreb, Croatia*

The heart rate variability (HRV) analysis is an important tool in cardiology. HRV shows the fluctuating time between normal sinus beats (RR intervals) and indicates modulation of the heart rate by the autonomic nervous system (ANS). The purpose of the study was to determine HRV in anaesthetised cats subjected to elective castration. Therefore, the Poincaré plot analysis, a method to assess the dynamics of HRV, was performed.

The research was performed on 80 domestic cats. For the 'dexKB' group (20 male and 20 female cats), combinations of the anaesthetics dexmedetomidine 40 µg/kg ketamine 5 mg/kg and butorphanol 0.4 mg/kg were administered. For the 'domKB' group (20 male and 20 female cats) an anaesthetic combination of medetomidine 80 µg/kg, ketamine 5 mg/kg and butorphanol 0.4 mg/kg was administered.

A quantitative analysis of HRV was displayed by the Poincaré plot by adjusting it to an ellipse. For the performance analysis, the SD1 (Standard Deviation 1), SD2 (Standard Deviation 2), Poincaré index (PI) and the area of the ellipse were used as evaluation parameters. The female cats had the highest PI 60 min after anaesthetics administration and two times larger area of the ellipse in 'dexKB'. SD1 and SD2 increased linearly up to 60 minutes in the females. In the male 'dexKB' cats, the highest PI was recorded 120 min and in 'domKB' 30 min after the administration of anaesthetics. The area of ellipse differs in time and the highest area was in the male 'dexKB' cats 60 min after anaesthetics administration, while in 'domKB' the highest area was 120 min after the application of anaesthesia. SD1 and SD2 in the male 'domKB' cats increased during anaesthesia and in 'dexKB' they increased up to 30 min after the anaesthetic combination administration.

The analysis provides a qualitatively and quantitatively visual measure of ANS activity, a decrease in sympathetic and increase in parasympathetic activity, and can be used for a better dynamic monitoring during the induction of anaesthesia in the 'dexKB' and 'domKB' cats.

REVIEW OF CLINICAL CASES OF BODY CAVITY EFFUSIONS (2015–2019) – OVERVIEW OF CLINICAL CYTOLOGY FINDINGS AND ASSOCIATED AETIOLOGIC FACTORS

Valerija Benko¹, Dora Ivšić Škoda¹, Gabrijela Jurkić¹, Nada Kučer¹, Ana Petak¹, Filip Kajin¹, Marin Torti¹

¹*Clinic for Internal Diseases, Faculty of Veterinary Medicine, University of Zagreb, Croatia*

Effusion can be defined as a pathological accumulation of free fluid in the peritoneal, pleural or pericardial cavity as a consequence of one or more diseases (e.g. traumas, neoplasia, cardiovascular, metabolic, infectious or inflammatory diseases). Body cavity effusions are traditionally classified according to the total protein concentration and the total nucleated cell count (TNCC) as transudates (total protein < 2.5 g/dL, TNCC < 1,500 cells/μL), modified transudates (total protein 2.5–7.5 g/dL, TNCC 1,000–7,000 cells/μL) and exudates (total protein > 3.0 g/dL, TNCC > 7,000 cells/μL).

The dogs (n = 133) included in the study were admitted at the Clinic for Internal Diseases, Faculty of Veterinary Medicine, University of Zagreb, and had confirmed effusion in one or more body cavities with associated clinical signs. Additionally, the dogs were divided into general groups according to the cause of effusion: (1) neoplastic, (2) non-neoplastic, and the dogs with exudate were subgrouped into those with (3) septic and (4) non-septic exudate.

The majority of the dogs (n = 77) had effusion that was classified as modified transudate; in 69% of the dogs, the cause of effusion was neoplasia and in 31% the cause was classified as non-neoplastic. The second most common type of effusion (n = 46) was exudate. In 61% of the dogs with exudate, the cause was neoplastic, and in 39% the cause was non-neoplastic. Of the neoplastic exudates, 96% were non-septic and 4% were septic exudates. In the group of non-neoplastic exudates, 61% were septic, while 39% were non-septic exudates. Transudates (n = 10) were the least frequent type of effusion, mainly caused by non-neoplastic diseases (70% vs. 30%).

The present study showed that the most common body cavity effusions in dogs admitted at the Clinic for Internal Diseases, Faculty of Veterinary Medicine, University of Zagreb, were modified transudates, with the most frequent cause being a neoplastic disease.

COMPARISON OF STANDARD CLOTTING TESTS IN DOGS BETWEEN QUICKVET AND ACL 7000 ANALYSERS

Dora Ivšić Škoda¹, Valerija Benko¹, Ljiljana Dukarić²

¹*Clinic for Internal Diseases, Faculty of Veterinary Medicine, University of Zagreb, Croatia*

²*Health Centre of the Ministry of the Interior, Zagreb, Croatia*

Standard clotting tests for evaluating the functionality of the blood coagulation cascade are prothrombin time (PT) and activated partial thromboplastin time (aPTT). PT is used to assess the extrinsic and common pathway and aPTT to assess the intrinsic and common pathway.

The aim of this study was to compare the results of standard clotting tests in dogs measured immediately and individually using the QuickVet analyser with those measured in stored samples in one turn using the ACL 7000 analyser.

The QuickVet analyser is a mechanical clot detection system based on one-time-use test cartridges containing micro channels and test-specific reagents. However, the ACL 7000 analyser utilises the photo-optical turbidimetric method to measure standard clotting tests.

The material for comparison was residual blood from 120 dogs with various medical conditions. The dogs included in the study were admitted at the Clinic for Internal Diseases, Faculty of Veterinary Medicine, University of Zagreb. Blood was drawn specifically to assess the health status of the dogs. The first measurement was made using the QuickVet analyser in whole citrated blood. After centrifugation, the plasma was separated and frozen at – 80 °C. The samples were collected for five months until the second measurement on the ACL 7000 analyser in the Special Hospital for Medical Rehabilitation of Stubičke Toplice.

The results were divided into two groups of different sizes and different duration of collection. Agreements between measurements were analysed using the Bland-Altman method and Passing and Bablok regression analysis. The PT showed a significant constant and significant proportional difference in each group. The aPTT showed a significant proportional difference in each group. However, the aPTT showed no significant constant difference between the two methods in each group. In conclusion, these methods cannot be used interchangeably.

Taking into account the analysis of a large number of stored samples at once, we recommend measurement by the QuickVet analyser, despite the high price of the test.

HEAT SHOCK PROTEINS IN BABESIOSIS IN DOGS

Irena Artuković¹, Ljiljana Bedrica², Josipa Kuleš³, Jelena Gotić², Renata Barić Rafaj⁴

¹*Polyclinic for Cardiovascular Disease Prevention and Rehabilitation, Zagreb, Croatia*

²*Clinic for Internal Diseases, Faculty of Veterinary Medicine, University of Zagreb, Croatia*

³*ERA Chair Team (VetMedZg), Clinic for Internal Diseases, Faculty of Veterinary Medicine, University of Zagreb, Croatia*

⁴*Department of Chemistry and Biochemistry, Faculty of Veterinary Medicine, University of Zagreb, Croatia*

Heat shock proteins (HSPs) have the role of cellular chaperones, responsible for a proper conformation, translocation and degradation of other proteins. Recent discoveries suggest that HSPs have a much wider role outside the cells. Changes in the HSPs expression as well as their location (intra/extracellular) are now associated with the pathogenesis of a wide range of diseases in humans and animals.

Serum concentrations of HSP40, HSP60 and TNF α in dogs with babesiosis ($n = 18$) were measured using ELISA tests and compared to the values in healthy dogs ($n = 18$). The Mann-Whitney test and Spearman's correlation were tested, with significance $p < 0.05$.

In babesiosis, HSP60 was increased. A strong correlation shows TNF α and HSP40 ($r = 0.78$), and TNF α and HSP60 ($r = 0.82$). It is known that an increase in HSP60 can be induced by an elevation of temperature, oxidative stress and an acute inflammatory reaction. All of the mentioned factors occur in babesiosis in dogs and their common characteristic is that they disturb the tertiary structure of proteins. Consequently, an increased HSP in babesiosis may have a protective role against protein denaturation.

While parasites express HSPs when they invade their host, host cells express the same proteins as a defensive mechanism. It seems that the parasite hijacks the host HSPs, because host chaperones have been found in association with proteins of parasitic origin at the erythrocyte membrane, which suggests that host HSPs may facilitate trafficking of proteins of parasitic origin to the erythrocyte surface.

Recent studies have shown that HSP60 induces TNF release from macrophages and monocytes. A strong correlation between HSPs and TNF α as inflammatory marker indicates the role of chaperones in acute inflammation in babesiosis.

Molecular chaperones have the potential to deliver clinically relevant diagnostic and therapeutic approaches. The current challenge is to fully understand these networks and establish their clinical potential.

IMPACT OF ORCHIECTOMY ON CONTRALATERAL SIDE OCCURRENCE OF PERINEAL HERNIA IN DOGS – A RETROSPECTIVE STUDY

Karlo Tanhofer¹, Nika Brkljača Bottegaro², Andrija Musulin², Dražen Vnuk²

¹*Faculty of Veterinary Medicine, University of Zagreb, Croatia, student*

²*Clinic for Surgery, Orthopaedics and Ophthalmology, Faculty of Veterinary Medicine, University of Zagreb, Croatia*

Perineal hernia (PH) is a common disorder in dogs that occurs as a result of a weakened perineal diaphragm. Patients present unilateral or bilateral perineal swelling, straining or inability to defecate and urinate. Dogs with PH are mostly intact males older than 5 years. The aim of this study was to analyse the signalment, the operative technique performed and postoperative contralateral occurrence related to perioperative castration.

Data on dogs with surgically treated perineal hernia in the period from 1 January 2008 to 1 April 2019 were analysed. Patients diagnosed with PH made up a total of 0.64% of all the patients admitted to the Clinic for Surgery, Orthopaedics and Ophthalmology. Perineal hernia was diagnosed based on a clinical examination and radiologic findings. The dogs were categorised according to sex, age and body weight (small, medium and large breeds). Data concerning the surgical technique performed and the occurrence of PH on the contralateral side after the surgery were reviewed.

There were 90 dogs surgically treated for PH and all were male. The average age of the dogs undergoing surgery was 9.38 ± 2.42 years. Most of the patients were small-breed dogs (54.65%). Seventy-six (89.41%) dogs had unilateral hernia and 9 (10.59%) dogs had bilateral hernia. There was 12.22% of contralateral occurrence, of which 54.54% occurred in neutered dogs. The castration had no impact on contralateral occurrence ($p > 0.05$). The most commonly performed surgical technique was the transposition of the internal obturator muscle (74.16%). A herniorrhaphy using polypropylene mesh was performed in 24.72% of the operated patients. There was a single case in which both techniques were used.

This study shows that perioperative castration may not have a direct impact on the contralateral occurrence of PH. However, further studies involving a larger number of patients are warranted to confirm this conclusion.

SURGICAL MANAGEMENT OF PARAPHIMOSIS IN DOG – A CASE REPORT

Marija Mamić¹, Ozren Smolec¹, Valentina Plichta¹, Ana Smajlović¹, Sonja Vukelić¹, Dražen Vnuk¹

¹*Clinic for Surgery, Orthopaedics and Ophthalmology, Faculty of Veterinary Medicine, University of Zagreb, Croatia*

Paraphimosis is defined as the inability to retract the penis into the anatomical position within the preputial sheath. Phallopey is one of the most often used techniques in the treatment of paraphimosis.

A 7-year-old neutered male Maltese dog was presented for signs of recurrent paraphimosis despite previous castration that was initially successful, but episodes of paraphimosis recurred after a few weeks. The physical examination findings at the time of the referral consultation showed that the penis was flaccid, but protruded 2 cm cranially to the preputial orifice. Drying and slight inflammation of the tip of the penis were detected. Preputial ostium was of an appropriate size, inverted, exposing the glans penis. However, with lubrication, the prepuce could easily be drawn cranially to cover the penis. A surgical correction was recommended to the owner. One week later, a phallopey was performed under general anaesthesia. A 4 cm long incision was performed at the lateral side of the preputium into the preputial cavity. Strips of penile and preputial mucous membranes were excised and the borders of those defects were reapposed in a simple continuous pattern, using knotless barbed suture composed of glycomer 631 (V-loc90™). The subcutaneous layer and skin were reconstructed routinely. The phallopey resulted in a complete coverage of the glans penis by the prepuce. The dog was discharged from the clinic the following day with a five-day course of meloxicam, fentanyl transdermal patch and postoperative care instructions.

In this case report, phallopey using knotless barbed suture is described as a successful surgical treatment option for recurrent paraphimosis in a dog. The technique is rapid, allows the preservation of the normal penile anatomy and is simple compared to other more radical techniques. In the dog in this study, no recurrence, complications or adverse sequelae were observed. In cases where conservative management has failed, phallopey should be considered as one of the surgical options.

SMALL INTESTINE HAEMANGIOSARCOMA IN DOG – A CASE REPORT

Dunja Vlahović¹, Kristina Guliš³, Hrvoje Capak⁴, Ivana Mihoković², Lidija Medven Zagradišnik², Marko Hohšteter², Branka Artuković², Andrea Gudan Kurilj², Ivan Conrado Šoštarić Zuckermann², Doroteja Huber², Željko Grabarević²

¹*Department for Pathological Morphology, Croatian Veterinary Institute, Zagreb, Croatia*

²*Department of Veterinary Pathology, Faculty of Veterinary Medicine, University of Zagreb, Croatia*

³*Samobor Veterinary Clinic, Samobor, Croatia*

⁴*Department of Radiology, Ultrasound Diagnostic and Physical Therapy, Faculty of Veterinary Medicine, University of Zagreb, Croatia*

Haemangiosarcoma (HSA) is a malignant tumour of endothelial cells, which occurs most frequently in old dogs. HSA may arise at any site of the body, but the most common primary sites in dogs are the spleen, skin/subcutis, right atrium and liver. Although primary colonic HSA in a dog has been described, literature survey, to the authors' best effort, has so far showed no data of small intestine HSA. We are reporting the first case of small intestine HSA in a dog.

An 11-year-old male mixed-breed dog was admitted to the veterinary clinic because of poor a general condition. After an X-ray and ultrasound examination, which showed an abdominal mass approx. 9x5 cm in size, the mass excision and enterectomy were performed. The excised mass was round and dark red-black haemorrhagic in appearance.

Histopathologically, the tumour consisted mostly of atypical neoplastic vascular spaces of various sizes, lined by endothelial cells with cytological atypia located in lamina muscularis externa of the small intestine. In the solid parts of the tumour, anaplastic endothelial cells were plump, spindle to ovoid, with prominent nuclei. Marked anisocytosis and anisokaryosis with many bizarre nuclei were found. Mitoses were rare. Lymphocytic infiltrates were observed multifocally. Immunohistochemical staining confirmed cytoplasmic expression of CD 31 in the endothelial cells.

Since there were no lesions found in the spleen during the surgical procedure and no hepatic or cardiac lesions were observed in the X-ray and ultrasound, our finding suggests primary small intestine HSA in the dog, which is, to the authors' knowledge, reported for the first time.

SURGICAL TREATMENT OF PERIODONTITIS IN DOGS – A RETROSPECTIVE STUDY

Sonja Vukelić¹, Mirta Vučković¹, Dražen Matičić¹, Hrvoje Capak², Nika Brkljača Bottegato¹, Dražen Vnuk¹

¹*Clinic for Surgery, Orthopaedics and Ophthalmology, Faculty of Veterinary Medicine, University of Zagreb, Croatia*

²*Department of Radiology, Ultrasound Diagnostic and Physical Therapy, Faculty of Veterinary Medicine, University of Zagreb, Croatia*

Periodontitis or periodontal disease is one of the most common pathologies in dogs. It is defined as an inflammatory reaction to dental plaque, resulting in progressive gingival withdrawal and destruction of the periodontal ligament and alveolar bone. Early stages are characterised by reversible gingivitis that, if left untreated, progresses to irreversible periodontitis. The aim of the study was to analyse the extent of the surgical treatment required considering the stage of periodontitis.

The study included data on dogs that underwent a surgical treatment of periodontitis from December 2016 to July 2018. The dogs were divided into categories according to: size, age, sex, breed, jaw type and medical history data. All of the dogs underwent a clinical examination under general anaesthesia and oral X-rays were taken. Data were analysed according to the teeth affected by periodontitis, number of furcations, number of extracted teeth, alveolar bone involvement and lack of teeth.

There were 65 dogs admitted for dental treatment in the study period. Most of them were males, 55.4%, and 47/65 were small-breed dogs. The average age of the dogs was 9.2 ± 2.9 years. Sixty-one dogs had more than one tooth extracted. A correlation has been noted between the loss of the alveolar bone and the number of extracted teeth ($p < 0.01$). The animals with a visible horizontal or vertical loss of the alveolar bone required a higher number of tooth extractions. The small-breed dogs had a lower probability of the extraction of only one tooth.

With the progression of the disease, the animals required a more invasive treatment in the form of more extractions. Small-breed dogs are prone to a faster progression of periodontitis. The results of the present study emphasise the importance of an early treatment of periodontitis in order to avoid more invasive surgical procedures. Therefore, the implementation of a regular dental control should be a part of everyday small animal practice.

SHORT RECURRENCE TIME IN DOG WITH ACANTHOMATOUS AMELOBLASTOMA – A CASE REPORT

**Maša Efendić¹, Dražen Vnuk², Mirna Abaffy Kirin², Lidija Medven Zagradišnik³,
Marko Hohšteter³, Hrvoje Capak⁴, Nino Maćešić⁵, Marija Lipar²**

¹*Faculty of Veterinary Medicine, University of Zagreb, Croatia, PhD student and intern*

²*Clinic for Surgery, Orthopaedics and Ophthalmology, Faculty of Veterinary Medicine, University of Zagreb, Croatia*

³*Department of Veterinary Pathology, University of Zagreb, Croatia*

⁴*Department of Radiology, Ultrasound Diagnostic and Physical Therapy, Faculty of Veterinary Medicine, University of Zagreb, Croatia*

⁵*Clinic for Obstetrics and Reproduction, Faculty of Veterinary Medicine, University of Zagreb, Croatia*

Ameloblastomas are benign odontogenic neoplasms that rarely become malignant and occur in the maxilla or mandible. A 7-year-old male mixed-breed dog was admitted to the Clinic due to a swelling on the buccal side of the left mandibular canine area lasting for five days. The swelling was a polyp-like, bean-sized, exophytic mass. The physical examination was unremarkable. The blood results showed only leukopenia. The X-ray findings showed a local gingival swelling without bone lesions. An FNA of neoplasia did not reveal the diagnosis due to a small cell count. The dog underwent an excisional biopsy (EB) under general anaesthesia (GA). Histopathology revealed neoplastic proliferation that was extending from the hyperplastic mucosa and expanding the subepithelial connective tissue. Neoplasia was composed of irregular cords of columnar to polygonal epithelial cells with a moderate amount of eosinophilic cytoplasm, while peripheral cells contained antinuclear nuclei. Anisokaryosis was moderate and the mitotic rate was 10/10 HPF. Multifocally, there were islands of osteoid and bone tissue with bone lysis and ossification. Occasionally within the stroma there were mixed inflammatory infiltrates, diffuse oedema and focal haemorrhage. Histologic findings favoured the diagnosis of acanthomatous ameloblastoma, which is known as a locally aggressive jaw tumour with a high propensity for recurrence. The swelling relapsed three months after the initial excision. The X-ray findings in the left mandibular canine region showed a mild periosteal reaction from the third incisor to the second premolar, with canine root degeneration. The treatment of choice was a partial mandibulectomy under GA. The recovery period was short, without any complications during the healing process. In conclusion, despite the accurate tumour margins assessment following the first excision, acanthomatous ameloblastoma confirmed its aggressive proliferation in a short period of time, resulting in odontogenic degeneration. Hence, an EB should always be performed with wide surgical margins.

RETROSPECTIVE ANALYSIS OF PULMONARY HAEMORRHAGE IN NECROPSIED DOGS

Lidija Medven Zagradišnik¹, Dunja Vlahović², Branka Artuković¹, Doroteja Huber¹, Andrea Gudan Kurilj¹, Ivan Conrado Šoštaric Zuckermann¹, Željko Grabarević¹, Ivana Mihoković¹, Iva Jelenić³, Marko Hohšteter¹

¹Department of Veterinary Pathology, Faculty of Veterinary Medicine, University of Zagreb, Croatia

²Department for Pathological Morphology, Croatian Veterinary Institute, Zagreb, Croatia

³DVM, Zagreb, Croatia

Pulmonary haemorrhage in dogs can be caused by different aetiological factors such as coagulation disorders, which include anticoagulant rodenticide toxicity, thrombocytopenia and disseminated intravascular coagulation. It can also be a result of sepsis, trauma and vasculitis, which are the most common causes in dogs. Gross appearance varies from multifocal petechiae to an extensive intraalveolar distribution. Microscopic findings include red blood cells in the alveolar spaces due to their extravasation from blood vessels and the presence of intraalveolar macrophages containing haemosiderin.

Archived canine necropsy reports and histopathological specimens collected during a three-year period from the Department of Veterinary Pathology, Faculty of Veterinary Medicine, University of Zagreb, were examined for pulmonary haemorrhage to determine the most common causes for this lesion as well as the primary cause of death in these dogs.

Pulmonary haemorrhage was found in 111 dogs. It was most commonly caused by trauma (17.12%, 19/111), toxicity (13.51%, 15/111), sepsis (9.91%, 11/111), heart failure (9.01%, 10/111), infectious (7.21%, 8/111) and parasitic (5.41%, 6/111) diseases. A severe pulmonary haemorrhage directly associated with the cause of death was found as a consequence of trauma, anticoagulant rodenticide toxicity and *Leptospira* spp. infection. The most commonly affected were the mixed-breed dogs (31.53%, 35/111) and the dogs of the breeds from the Fédération Cynologique Internationale Group 2 (FCI 2) (Pinscher and Schnauzer – Molossoid and Swiss Mountain and Cattle dogs) (21.62%, 24/111). The dogs between 3 and 15 years of age were more commonly affected (52.25%, 58/111).

Our results correspond with the present literature data regarding the common causes of pulmonary haemorrhage in dogs. Although haemorrhage can accompany various pathological disorders, it is important to consider leptospirosis as a differential diagnosis in unclear cases of pulmonary haemorrhage due to its zoonotic potential.

INTERNAL HYDROCEPHALUS IN BULLDOG BREEDS

Doroteja Huber¹, Ivana Mihoković¹, Filip Kajin², Željko Grabarević¹, Branka Artuković¹, Andrea Gudan Kurilj¹, Ivan Conrado Šoštarić Zuckermann¹, Lidija Medven Zagradišnik¹, Marko Hohšteter¹

¹*Department of Veterinary Pathology, Faculty of Veterinary Medicine, University of Zagreb, Croatia*

²*Clinic for Internal Diseases, Faculty of Veterinary Medicine, University of Zagreb, Croatia*

Hydrocephalus is a pathologic condition of the central nervous system characterised by an abnormal accumulation of fluid in the cranial cavity. In internal hydrocephalus, the fluid is accumulating in the ventricular system.

The brains of 32 bulldogs were investigated by means of a gross and histologic examination. The English Bulldog population included 10 dogs: 2 puppies (< 1 year) and 8 adults (≥ 1 year). The French Bulldog population included 22 dogs: 7 puppies and 15 adult dogs. All clinical data regarding the neurologic status of the animal were collected. The cause of death was determined based on pathologic findings.

Internal hydrocephalus was present in 5 English Bulldogs (50%; 2 puppies and 3 adults). Neurologic signs were not present in any of the dogs with hydrocephalus. Apart from pathologic changes associated with hydrocephalus, no other lesions were noted in the brain. In all of the dogs, the cause of death was not related to hydrocephalus. In the French Bulldog population, internal hydrocephalus was noted in 4 dogs (18.2%; 1 puppy and 3 adults). Neurologic signs were present in all of the dogs with available clinical data (3 dogs). In 2 of these dogs, the histologic slides of the brain showed pathology associated with hydrocephalus, including dilation of ventricles with thinning of the white matter and subependymal oedema, with the cause of death not related to neurologic pathology. In the other 2 dogs, which were euthanised due to severe and progressive neurologic signs, necrotising leukoencephalitis and necrotising meningoencephalitis were diagnosed, respectively.

Internal hydrocephalus is commonly found in brachycephalic breeds, often as an incidental finding on necropsy, which was also shown in this study. In the English Bulldogs, hydrocephalus was more frequently found as an incidental finding not associated with neurologic symptoms or lethal outcome in these animals. Although in 2 French Bulldogs the neurologic pathology led to euthanasia, hydrocephalus found in these dogs was probably a consequence of a primary disease (necrotising encephalitis).

EFFECT OF TWO DIFFERENT FEEDING REGIMES (BARF VS. KIBBLE DIET) ON HAEMATOLOGICAL PARAMETERS IN SEARCH AND RESCUE DOGS DURING FIELDWORK

Diana Brozić¹, Tomislav Bureš², Nika Brkljača Bottegaro³, Iva Šmit⁴, Jelena Šuran⁵, Božo Radić⁶, Zoran Vrbanc⁷

¹Department of Animal Nutrition and Dietetics, Faculty of Veterinary Medicine, University of Zagreb, Croatia

²Faculty of Veterinary Medicine, University of Zagreb, Croatia, student

³Clinic for Surgery, Orthopaedics and Ophthalmology, Faculty of Veterinary Medicine, University of Zagreb, Croatia

⁴Clinic for Internal Diseases, Faculty of Veterinary Medicine, University of Zagreb, Croatia

⁵Department of Pharmacology and Toxicology, Faculty of Veterinary Medicine, University of Zagreb, Croatia

⁶Hedera d.o.o., Split, Croatia

⁷Department of Radiology, Ultrasound Diagnostic and Physical Therapy, Faculty of Veterinary Medicine, University of Zagreb, Croatia

The effect of the macronutrient ratio in the diet fed to the dogs performing at medium to high intensity during a prolonged period has not been sufficiently researched. The aim of the study was to evaluate the changes in haematological parameters in Croatian Mountain Rescue Service dogs included in two different feeding regimes during a simulated fieldwork.

There were 11 healthy dogs (mean age 3.57 ± 1.81 years) included in the study, divided into two groups: the raw meat-based diet group (BARF) and the kibble diet group (KIB). Both commercially available diets were uniform for each group. Other than the different food processing principle of the diet (raw, frozen vs. pressed), the diets differed in the macronutrient level: on a dry matter basis, the BARF diet consisted of protein, fat and carbohydrate in the following proportions: 45.2:32.2:5.5, and the kibble diet 27.5:18.7:42.8. The feeding protocol lasted for four months. During that period, blood samples were obtained once per month: the baseline sample in the morning before the feeding and the second one immediately after six hours of fieldwork. Data were analysed within the groups before and after the fieldwork using the paired t-test ($p < 0.05$).

Haematological parameters, red blood cell (RBC) ($p < 0.05$), haemoglobin (HGB) ($p < 0.05$) and haematocrit (HCT) levels ($p < 0.01$) were significantly lower post-fieldwork in the KIB group than the baseline values. White blood cell (WBC) and segmented neutrophil counts ($p < 0.01$) were higher post-workout in the KIB group. In the BARF group, mean platelet volume (MPV) ($p < 0.05$) significantly decreased after the workout, while other parameters did not differ significantly.

The physiological response of search and rescue dogs during a prolonged fieldwork is similar to the changes described in endurance activity. Haematological parameters in the BARF group seem to be less affected by the performed workload.

ILIOPSOAS MUSCLE STRAIN IN AGILITY BORDER COLLIE – A CASE REPORT

Anita Kraljević¹, Tomislav Bureš², Matej Krištić², Branimir Škrlin³, Dino Stanin³, Jana Gams⁴, Deana Basar⁵, Dinko Kolarić⁶, Zoran Vrbanc³

¹Faculty of Veterinary Medicine, University of Zagreb, Croatia, postgraduate master's student

²Faculty of Veterinary Medicine, University of Zagreb, Croatia, student

³Department of Radiology, Ultrasound Diagnostic and Physical Therapy, Faculty of Veterinary Medicine, University of Zagreb, Croatia

⁴Dogs4motion, Veterinary Rehabilitation & Hydrotherapy, Ravne na Koroškem, Slovenia

⁵Equus Vitalis, Dugo Selo, Croatia

⁶Special Hospital for Medical Rehabilitation, Daruvarske Toplice, Daruvar, Croatia

The iliopsoas muscle comprises the *psoas major* and *iliacus* muscles. Its function is to flex the hip and lower portion of the spine, lateral rotation of the femur, and to advance the femur cranially. Iliopsoas strain is commonly associated with dog sport activities.

A Border Collie female, 7 years old, was admitted with a history of poor performance following an injury a month before, during agility competition, while knocking down an obstacle. The dog was hesitating to jump, and lameness was present on the hind left limb post activity.

A physical examination showed a shortened stride in the hind left limb, discomfort in the left hip extension and painful hip extension with abduction and with internal rotation. The pain was elicited on palpation of the iliopsoas muscle as well as iliopsoas tendon and point of insertion on the lesser trochanter of the femur. The palpation of thoracolumbar region muscles showed tension. Thermal imaging revealed lower temperature readings in the left thigh/groin muscles, indicating less muscle activity of the affected limb. The X-ray showed signs of lumbar osteoarthritis.

The initial rehabilitation programme included ultrasound, laser and massage therapies, followed by stretching movements of hip extensors with abduction. Electroacupuncture was performed to assist with pain control. Underwater treadmill activity was introduced in the 2nd week. Strengthening exercises included caveletti poles and balance exercises.

Training was introduced in the 5th week, with low-intensity workouts, jumping over lower bars and a more straight-line movement. The instructions for warming up and stretching before and a proper cooling after training were strictly followed.

After 8 weeks of rehabilitation, the dog returned to regular training, and subsequently to competition.

Rehabilitation following iliopsoas muscle strain may last several weeks. In order to help prevent the injury and avoid re-injury, it is necessary to include warming up and active stretching before training or competition.

REHABILITATION OF ACUTE CANINE POLYRADICULONEURITIS IN TWO DOGS – A CASE REPORT

Zoran Vrbanac¹, Anita Kraljević², Tomislav Bureš³, Nika Brkljača Bottegaro⁴, Branimir Škrin¹, Dino Stanin¹, Ivana Kiš⁵, Filip Kaji⁵

¹Department of Radiology, Ultrasound Diagnostic and Physical Therapy, Faculty of Veterinary Medicine, University of Zagreb, Croatia

²Faculty of Veterinary Medicine, University of Zagreb, Croatia, postgraduate master's student

³Faculty of Veterinary Medicine, University of Zagreb, Croatia, student

⁴Clinic for Surgery, Orthopaedics and Ophthalmology, Faculty of Veterinary Medicine, University of Zagreb, Croatia

⁵Clinic for Internal Diseases, Faculty of Veterinary Medicine, University of Zagreb, Croatia

Acute canine polyradiculoneuritis (ACP) or idiopathic polyradiculoneuritis is an acquired peripheral neuropathy, which primarily affects the ventral nerve roots and peripheral nerves, resulting in flaccid tetraparesis/tetraplegia. There is no age, breed or sex predilection associated with the development of ACP. No proven specific treatment exists. Physical therapy and nursing are recommended as supportive treatment. Most affected dogs show signs of spontaneous improvement within 3 to 4 weeks, with complete recovery within 2 to 6 months.

Two dogs, female, mixed-breed, aged 6 and 10 years, were admitted with signs of acute flaccid non-ambulatory tetraparesis and generalised lower motor neuron (LMN) signs. A tentative diagnosis of ACP was made based on the medical history, clinical presentation, examination findings, diagnostic imaging and routine laboratory tests.

Both dogs were presented in the physical therapy unit in lateral recumbency and required complete assistance to move in a sternal position. The dogs were supported in a sitting or standing position with no weight bearing on all limbs. Muscle atrophy was present mostly on the hind limbs. The rehabilitation programme consisted of joint passive range of motion movements (PROM) and core muscle and limb massage during the 1st week. Electrostimulation was performed during the first 2 weeks as well as PROM and stretching techniques. After 2 weeks, the dogs were able to maintain a sternal position without support, and showed voluntary movement of the hind limbs. PROM, massage and balance exercises, such as reaching for treats while in a sternal position, were included in the home programme. Assistive standing and voluntary movements of all limbs were present by the end of the 3rd week in one patient, and the 5th week in the other. At that point, underwater treadmill sessions and active exercises were introduced.

Physical therapy combined with a proper home rehabilitation programme can result in a positive functional outcome over a shorter period of time in dogs with ACP.

PRIMARY CANINE OVARIAN TUMOURS IN CROATIA

Ivana Mihoković¹, Doroteja Huber¹, Željko Grabarević¹, Branka Artuković¹, Andrea Gudan Kurilj¹, Ivan Conrado Šoštaric Zuckermann¹, Lidija Medven Zagradišnik¹, Marko Hohšteter¹

¹*Department of Veterinary Pathology, Faculty of Veterinary Medicine, University of Zagreb, Croatia*

Neoplastic ovarian disease in dogs is uncommon, but may affect health and fertility or even threaten the life of the animal. The classification of these tumours is primarily based upon the histologic appearance of tumour cells and their embryologic origin. Primary ovarian tumours are classified as epithelial, sex cord stromal (which frequently produce reproductive hormones associated with endocrine clinical symptoms like pyometra, non-regenerative anaemia and thrombocytopenia), germ cell, mixed or mesenchymal tumours.

The study investigated the incidence of histological types of 27 canine ovarian tumours analysed at the Department of Veterinary Pathology from 2009 to 2018. The age and breed of all the dogs were retrieved from the Department's database.

The most frequently diagnosed tumours were sex cord stromal tumours (48%), followed by epithelial tumours (33%), germ cell tumours (8%), mixed tumours (7%) and mesenchymal tumours (4%). The most frequently affected breed was the mixed breed (11 bitches, 41%). Other affected breeds were Labrador Retriever (3, 10%), Tornjak, German Shepherd, unknown breed (2, 7% each), and Boxer, Irish Setter, Yorkshire Terrier, Standard Schnauzer, Maltese, American Bulldog, American Staffordshire Terrier (1, 4% each). The average age of the dogs diagnosed with ovarian tumours was 10.7 years.

Ovarian tumours present a rare disease of the ovary in dogs, which was also noted in the current research, as only 27 tumours were diagnosed in a 10-year period. A possible explanation is that many dogs are neutered at an early age; hence a pathology of the ovary cannot develop. Furthermore, after an ovariohysterectomy, reproductive organs are often not submitted for histology due to financial restrictions of owners. The tumours were most frequently diagnosed in the mixed-breed dogs, which is presumably a consequence of the predominance of this breed in Croatia. Although ovarian tumours in dogs are uncommon, they should present a differential diagnosis in bitches with suspected reproductive pathology.

CANINE FOETAL MUMMIFICATION AS CONSEQUENCE OF PROLONGED GESTATION

Maša Efendić¹, Nino Maćešić², Marko Samardžija², Tugomir Karadjole², Martina Lojkić², Valerija Benko³, Zrinka Štrito⁴, Vladimir Stevanović⁴, Iva Raič⁶, Hrvoje Capak⁵

¹Faculty of Veterinary Medicine, University of Zagreb, Croatia, PhD student and intern

²Clinic for Obstetrics and Reproduction, Faculty of Veterinary Medicine, University of Zagreb, Croatia

³Clinic for Internal Diseases, Faculty of Veterinary Medicine, University of Zagreb, Croatia

⁴Department of Microbiology and Infectious Diseases with Clinic, Faculty of Veterinary Medicine, University of Zagreb, Croatia

⁵Department of Radiology, Ultrasound Diagnostic and Physical Therapy, Faculty of Veterinary Medicine, University of Zagreb, Croatia

⁶Faculty of Veterinary Medicine, University of Zagreb, Croatia, student

A 1-year-old Kangal Shepherd bitch was admitted to the Clinic due to ultrasound (US) diagnostic of the first pregnancy 30 days following mating. Canine pregnancy normally ranges from 58 to 70 days. The US finding revealed 4 fetuses with a physiological heartbeat. The gestational sac diameter corresponded to foetal age. A suggestion for the next control examination was at the 45th day of the gestation, but the owners came on the 91st day, since parturition had not started.

The bitch underwent a physical examination, which was unremarkable. The CBC showed mild anaemia, which corresponds to mid gestation. Serum biochemistry results were in the normal ranges, except hypoalbuminemia and a slightly increased CRP. Serum P₄ was 7.88 ng/mL. There were no vaginal signs for parturition initiation.

An abdominal US showed well-developed but avital fetuses without foetal fluid. The endometrium was unchanged without intraluminal free fluid. The X-ray showed 6 completely developed and ossified fetuses without foetal fluid. There were also initial signs of skeleton decalcification. Based on the elevated P₄ and the absence of the free fluid, mummification of the fetuses occurred due to persistence of *corpus luteum* presence.

A radical C-section was performed in general inhalation anaesthesia and all the fetuses with placenta were delivered. The cytology of the smear and endometrium aspirate revealed mild cellular slide with a predominance of segmented neutrophils (86%), lymphocytes (12%) and eosinophils (2%) with haematoidin crystals, connected to non-septic neutrophil inflammation. The bacterial findings of uterine aspirate as well as herpes viral molecular testing of foetal organs were negative. The postpartum X-ray of fetuses showed no signs of congenital malformation.

In conclusion, prolonged gestation can result in foetal death and many further complications. At the final stage of pregnancy, it is important to monitor the decline of serum P₄ as the evidence of luteolysis in order to prevent a prolonged parturition and foetal death.

ANALYSIS OF CANINE PORTAL VEIN RAMIFICATION BASED ON CORRIOSION-SILICONE CASTS AND X-RAY SCANS

Dimitar Bozhinovski, Nikola Adamov, Martin Nikolovski, Dine Mitrov, Aleksandar Janevski, Vlatko Ilieski, Lazo Pendovski

Department of Functional Morphology, Faculty of Veterinary Medicine, Ss. Cyril and Methodius University in Skopje, North Macedonia

Vascular corrosion casts (VCC) are used for a three-dimensional assessment of vascular variations. In order to assess the variations of the canine portal vein ramification, we compared the X-ray contrast scans of fresh canine livers and hepatic VCC. The livers were obtained from healthy male ($n = 5$) and female ($n = 8$) dog cadavers (Macedonian Shepherd, Cane Corso, German Shepherd) ranging from 15 to 35 kg body weight. The livers were extracted by post-mortem dissection. The portal vein of each specimen was washed with a heparin solution, filled with an X-ray contrast (Ultravist-370) and scanned. Silicone polymers were injected into the portal vein and the liver was submerged in a 20% solution of NaOH at 50 °C for 24 hours. The analysis of the VCC and X-ray scans showed that the portal vein branched in the shorter and smaller right portal branch (*ramus dexter*) and the longer and substantial left portal branch (*ramus sinister*). The right portal branch supplied right liver portions. It ramified in 1 or 2 branches directed dorsolaterally towards the caudate process of the caudate lobe and into 1–3 branches directed ventrolaterally into the right lateral lobe. The left branch was directed transversally into the ventral and left liver portions. In proximity of porta hepatis, it ramified in 2–3 branches for the supply of the ventral portion of the right lateral lobe. The second branch was directed ventrally to the right medial lobe, followed by 1–3 dorsally directed papillary process branches. Ventrolaterally, it ramified to 1–3 quadrate lobe branches, 1 left medial lobe branch and 3 left lateral lobe branches. The described ramification pattern was consistent in all the specimens. There was no significant anatomical variation of the portal vascular system observed among different dog breeds, body weight and sex. Silicone-filled and corroded portal vascular casts of dog livers were authentic to their *in situ* anatomical topography.

CONCONI TEST APPLICABILITY IN ASSESSMENT OF HORSE FITNESS – A CASE REPORT

Luka Špelić¹, Zoran Vrbnac², Jelena Gotić³, Nika Brkljača Bottegaro⁴

¹*Faculty of Veterinary Medicine, University of Zagreb, Croatia, student*

²*Department of Radiology, Ultrasound Diagnostic and Physical Therapy, Faculty of Veterinary Medicine, University of Zagreb, Croatia*

³*Clinic for Internal Diseases, Faculty of Veterinary Medicine, University of Zagreb, Croatia*

⁴*Clinic for Surgery, Orthopaedics and Ophthalmology, Faculty of Veterinary Medicine, University of Zagreb, Croatia*

Performance testing in horses is an important part of the preparation for competition. The Conconi test is routinely used in people and involves measurements of the heart rate (HR) and velocity during incremental exercise. Measurements of the HR and velocity are transcribed into charts in which the heart rate deflection point (HRDP) is detected by deflection of linearity during the increase of velocity. The heart rate deflection point defines the highest intensity of exercise in which lactate production can be compensated and aerobic metabolism retained. The aerobic-anaerobic threshold is very important in endurance horses, as it represents the maximum speed at which horse can run for longer distance. A lactate concentration of 4 mmol/L is considered as the aerobic threshold level.

An elite 10-year-old endurance, Arabian cross gelding underwent an incremental exercise test. During the test, the HR, velocity and blood lactate were measured. The progressive test consisted of 13 phases, each of 1,600 m in length, with a starting velocity of 16 km/h and increasing by 2 km/h in each subsequent phase. The average HR and velocity as well as lactate level were recorded after each phase. A single-axis chart of the HR was made to determine the HRDP. However, the obtained chart did not show a linear increase, disabling the straightforward interpretation of the results. The interfering factor of this test was the horse's excitement, which kept the HR unusually high in the first phases. Blood lactate reached the 4 mmol/L level at the velocity of 31.3 km/h, while the maximum recorded lactate level was 11.5 mmol/L at the velocity of 37.2 km/h.

The Conconi test used for the assessment of the horse's fitness needs to be better adapted in conditions that reduce interfering factors. A prolonged warm-up period could be extremely valuable. To the best of our knowledge, the Conconi test was not previously used for the assessment of fitness in horses and, with appropriate modifications, could represent a noteworthy non-invasive tool in performance assessment in different equestrian disciplines.

FETLOCK JOINT CARTILAGE LESIONS IN WORKING HORSES – A PILOT STUDY

Lazar Marković¹, Vladimir Gajdov², Tijana Lužajić Božinovski³, Ivan Milošević³,
Milica Kovačević Filipović⁴

¹Faculty of Veterinary Medicine, University of Belgrade, Serbia, PhD student

²Faculty of Veterinary Medicine, University of Belgrade, Serbia, student

³Department of Histology and Embryology, Faculty of Veterinary Medicine, University of Belgrade, Serbia

⁴Department of Pathophysiology, Faculty of Veterinary Medicine, University of Belgrade, Serbia

The horse is still used as a working animal, harnessed in a sled or wheeled chariots loaded with cargo several times heavier than the horse itself. There are no data on the extent of cartilage lesions in the fetlock joints of front and hind legs of working horses. The aim of the study was to determine the size and position of gross cartilage lesions in front and hind metacarpo-phalangeal (fetlock) joints of working horses.

Front and hind legs were collected from a local abattoir after the working horses were slaughtered for the reasons not related to this study. The study was conducted on eight horses from 5 to 12 years old (mean 8.625 ± 0.91 years), with a body weight of 550 ± 29.46 kg. Thirty-two fetlock joints were examined for external gross anatomy changes. After joint dissection, the cartilage of metacarpal and metatarsal bones was stained with blue ink and photos were taken. The cartilage lesions were stained deep blue, in contrast to light blue surface of the undamaged cartilage. The anatomical position of the lesions was recorded. The ImageJ software was used to measure the total surface of the cartilage and the surface of the cartilage under the lesions. The dimension of the lesions was expressed as a percentage of the total cartilage surface and presented as mean \pm standard error.

Gross anatomy changes like skin lesions, wounds, joint oedema or any type of deformities were not observed. The position of the cartilage lesions was symmetrical and occupied lateral and medial metacarpal and metatarsal condyles next to the sagittal ridge. The lesions on the lateral condyles had the same surface area like those on the medial, $12.3 \pm 1.03\%$ versus $10.7 \pm 0.99\%$, respectively. The cartilage lesions on the front legs ($23.62 \pm 1.68\%$) were broader than those on the hind legs ($22.5 \pm 3.35\%$).

The results of this pilot study indicate no difference between metacarpal and metatarsal cartilage surface lesions. Further studies are indicated to determine the severity of cartilage and putative subchondral bone lesions by histologic evaluation.

SEPTIC SYNOVITIS OF UNKNOWN ORIGIN IN ADULT HORSE – A CASE REPORT

Tomislav Bureš¹, Zoran Vrbanac², Jelena Gotić³, Hrvoje Capak², Branimir Škrlin²,
Zrinka Štritof⁴, Goran Csik⁵, Nika Brkljača Bottegaro⁶

¹Faculty of Veterinary Medicine, University of Zagreb, Croatia, student

²Department of Radiology, Ultrasound Diagnostic and Physical Therapy,
Faculty of Veterinary Medicine, University of Zagreb, Croatia

³Clinic for Internal Diseases, Faculty of Veterinary Medicine, University of Zagreb, Croatia

⁴Department of Microbiology and Infectious Diseases with Clinic,
Faculty of Veterinary Medicine, University of Zagreb, Croatia

⁵BEST FRIENDS Veterinary Clinic, Zagreb, Croatia

⁶Clinic for Surgery, Orthopaedics and Ophthalmology, Faculty of Veterinary Medicine,
University of Zagreb, Croatia

Septic synovitis affects synovial joints, tendon sheaths and bursas. In adult horses, the most frequent causes of synovial sepsis are penetrating trauma and iatrogenic contamination, although reports of septic synovitis of unknown origin are described.

A Warmblood mare, 27 years old, was admitted with a history of lameness and swelling of a hind limb lasting for three weeks. The mare had been treated with antibiotics and NSAIDs with deterioration of clinical signs. Two years earlier, a part of an intravenous catheter remained in her jugular vein, without causing any clinical manifestation. At admission, the mare was apathetic, but responsive. The rectal temperature was 37.6 °C, and the heart rate 60/min. Gluteal muscles atrophy and 5/5 grade lameness in the right hind limb were noted. The right tarsal and metatarsal regions were warm and oedematous, with the swelling most pronounced in the medial plantar region. An ultrasound examination revealed a distention of the tarsal tendon sheath with hypoechoic fluid and a pronounced adhesion formation. By performing synoviocentesis, a yellow-pinkish fluid was obtained. Microbial culture identified *Streptococcus equi* subsp. *zooepidemicus*. An X-ray examination did not reveal any abnormalities. The mare was treated with daily standing multi-needle lavage, intrasynovial and intravenous antimicrobial medication (ceftiofur 2.2 mg/kg IV BID). After 10 days, the mare's attitude improved and the lameness score changed to 4/5. On ultrasound, a regression of the process was evident, but X-ray revealed osteomyelitis of the calcaneal bone. In the following months, the clinical status of the mare remained constant, although there was an obvious radiological progression of the pathological process.

The present case emphasises the need to consider septic synovitis in adult horses even in cases where there is no evident perforation of synovial structures or a possibility of iatrogenic contamination. It remains speculative if the described *corpus alienum* could have been the culprit behind synovial sepsis.

PARANASAL SINUS CYST AND ETHMOID HAEMATOMA IN HORSE – A CASE REPORT

Robert Dumančić¹, Darko Grden², Hrvoje Capak³, Branimir Škrin³, Andrea Gudan Kurilj⁴, Doroteja Huber⁴, Dražen Vnuk⁵, Ana Smajlović⁵, Nika Brkljača Bottegaro⁵

¹Faculty of Veterinary Medicine, University of Zagreb, Croatia, student

²Clinic for Internal Diseases, Faculty of Veterinary Medicine, University of Zagreb, Croatia

³Department of Radiology, Ultrasound Diagnostic and Physical Therapy,
Faculty of Veterinary Medicine, University of Zagreb, Croatia

⁴Department of Veterinary Pathology, Faculty of Veterinary Medicine, University of Zagreb, Croatia

⁵Clinic for Surgery, Orthopaedics and Ophthalmology Clinic,
Faculty of Veterinary Medicine, University of Zagreb, Croatia

Paranasal sinus cysts are the second most common cause of secondary sinusitis in horses. The most common clinical signs are dyspnoea, facial swelling, epiphora and nasal discharge. The diagnosis is made by confirming the presence of a yellow, viscous, translucent and odourless fluid obtained via sinus centesis. Radiography, endoscopy and CT scanning can provide additional data, useful for treatment planning and prognosis.

A 12-year-old Warmblood mare was admitted with a five-month history of epistaxis and facial swelling. At admission, a swollen area of 5x3 cm in size proximal of *crista facialis* was obvious together with epiphora and blepharospasm in the right eye. A strong stertor could be heard during rest. A sinus centesis revealed the presence of a large volume of yellow, viscous fluid. Cytology findings showed a high number of neutrophils with protein precipitation.

Radiography discovered osteolytic processes with complete shading of maxillary and frontal sinuses and a mild deviation of the nasal septum. Endoscopic findings included a constriction of ventral nasal meatus of the affected side. Standing surgery was attempted, but due to her temper, the surgery had to be performed in general anaesthesia. A frontonasal flap was performed and a cyst with a yellow, smooth surface was observed. The cyst was stretching through all ipsilateral sinuses and it was not possible to differentiate between sinus compartments. The majority of the cyst content was removed and a Foley catheter was placed into the sinus cavity. Before recovery, PCV was 27%. The mare died during recovery due to hypovolemic shock. Histopathology of the cyst material revealed the aetiology of a progressive ethmoid haematoma.

Paranasal sinus cyst is a progressive disease that requires surgical intervention. In the present case, an earlier diagnosis and surgical procedure in standing sedation could have had a different outcome. Paranasal sinus cyst is a diagnosis that is not to be overlooked in cases of secondary sinusitis.

EPIDERMAL INCLUSION CYST IN MARE – A CASE REPORT

Klara Arifović¹, Dražen Vnuk², Darko Grden³, Jelena Gotić³, Ana Smajlović², Marko Hohšteter⁴, Nika Brkljača Bottegaro²

¹*Faculty of Veterinary Medicine, University of Zagreb, Croatia, student*

²*Clinic for Surgery, Orthopaedics and Ophthalmology, Faculty of Veterinary Medicine, University of Zagreb, Croatia*

³*Clinic for Internal Diseases, Faculty of Veterinary Medicine, University of Zagreb, Croatia*

⁴*Department of Veterinary Pathology, Faculty of Veterinary Medicine, University of Zagreb, Croatia*

Epidermal inclusion cysts (EIC) are small formations developed out of ectodermal tissue. They are most commonly formed under the surface of the skin inside the nasal diverticulum of horses.

A 2-year-old grey Lipizzaner mare was admitted with a swelling in the region of the right nostril. A rhinoscopic examination revealed an ellipsoid cyst, 4 cm in diameter, of soft elastic consistency in the dorsolateral aspect of the nasal diverticulum. A fine needle aspiration (FNA) was performed and a small amount of yellow-green content was aspirated. Cell structures with square, angular to irregularly polygonal pink cells of about 20–30 micrometres in diameter with rarely visible small hyperchromatic nuclei were noted. The cells were consistent with highly keratinised cells and were surrounded by multiple rod-shaped bacteria and a moderate number of erythrocytes. Cytological findings indicated EIC.

The cyst was surgically extirpated during standing sedation and an infraorbital nerve block. The cyst was approached from the outside, but the skin of external nares was also aseptically prepared. As a common complication, the diverticulum was penetrated during surgery. The skin and subcutis were closed in the standard manner. A histologic examination revealed a cystic structure that expanded the subepithelial tissue and elevated the overlying epidermis. The cyst was lined by a thick wall of squamous epithelium that underwent gradual keratinisation and contained deeply basophilic keratohyalin granules within the stratum granulosum and melanin pigments throughout the basal layer. The cyst lumen was filled with laminations of keratin. On the basis of histological findings, the diagnosis of EIC was confirmed. Two years after the surgical procedure there were no signs of recurrence.

The location of the pathological process in the present case was indicative of EIC; however, due to the grey colour of the mare, it was paramount to rule out melanoma. This case emphasises the diagnostic value of FNA.

CLOSTRIDIAL MYOSITIS IN MARE FOLLOWING EQUINE INFLUENZA AND TETANUS VACCINATION – A CASE REPORT

Ana Smajlović¹, Jelena Gotić², Zrinka Štritof³, Andrea Gudan Kurilj⁴, Mirta Vučković¹, Nika Brkljača Bottegato¹

¹*Clinic for Surgery, Orthopaedics and Ophthalmology, Faculty of Veterinary Medicine, University of Zagreb, Croatia*

²*Clinic for Internal Diseases, Faculty of Veterinary Medicine, University of Zagreb, Croatia*

³*Department of Microbiology and Infectious Diseases with Clinic, Faculty of Veterinary Medicine, University of Zagreb, Croatia*

⁴*Department of Veterinary Pathology, Faculty of Veterinary Medicine, University of Zagreb, Croatia*

Clostridial myositis, also known as malignant oedema, is a severe and potentially fatal disease in horses, causing significant necrotising soft tissue infections. The common types of bacteria found in muscle fibres are *Clostridium perfringens*, *C. septicum*, *C. novy*, and *C. chauvoei*. Cases of clostridium myositis have been described after intramuscular application of flunixin meglumine, phenylbutazone and ivermectin. This report presents a case of a mare with clostridium myositis following influenza and tetanus vaccination.

A 7-year-old mare was admitted with a history of six-day apathy, fever (40 °C), ventral oedema and haematuria. The mare was vaccinated with equine influenza and tetanus vaccine one week prior to the admission. One day after vaccination, swelling and heat of the injection site on the neck were noticed.

At admission, the mare was apathic, unresponsive and ataxic, febrile (38.8 °C), with a heart rate of 92 and a respiratory rate of 48. Mucous membranes were pale and yellowish with a capillary refill time of 3 seconds. Advanced emphysema involved the neck, thorax and the abdominal and inguinal regions on the right side of the body. An ultrasound examination of the swollen regions revealed hyperechoic shadowing between muscle fibres. Blood analysis showed severe anaemia and leucocytosis. As a result of a serious medical condition and poor prognosis, the owner decided to euthanise the animal. A post-mortem examination revealed gangrenous myositis with necrosis and degeneration of skeletal muscles of the right side of the neck, right front leg and right side of the abdomen. From skeletal muscles *Clostridium perfringens* was isolated.

To the best of our knowledge, this is the first case of clostridial myositis following vaccination by a combined influenza and tetanus vaccine. Although rare, this disease represents a life-threatening condition that should be considered as a possible complication after intramuscular applications.

PERITONITIS SUBSEQUENT TO SMALL INTESTINAL ULCERATION IN HORSE – A CASE REPORT

Valentina Percan¹, Nika Brkljača Bottegaro², Ivan Conrado Šoštarić Zuckermann³,
Jelena Gotić⁴

¹Faculty of Veterinary Medicine, University of Zagreb, Croatia, student

²Clinic for Surgery, Orthopaedics and Ophthalmology, Faculty of Veterinary Medicine,
University of Zagreb, Croatia

³Department of Veterinary Pathology, Faculty of Veterinary Medicine, University of Zagreb, Croatia

⁴Clinic for Internal Diseases, Faculty of Veterinary Medicine, University of Zagreb, Croatia

Gastric and colonic ulcerations are a common pathology in horses; however, small intestinal ulceration is a very rare finding. The available research on this subject is scarce, largely due to the difficulty of visualising the small intestinal mucosa in a live horse. Moreover, there are no obvious clinical signs, and a definitive diagnosis can be made at an exploratory laparotomy or necropsy when a perforating lesion is clearly visualised. This report describes a case of a 20-year-old mare with perforated ulcers in the small intestine.

Three weeks prior to the admission, the mare showed signs of colic and hyperthermia. After being treated with NSAID and antibiotic therapy, her clinical signs diminished. Haematology and serum biochemistry analysis indicated an increase of non-segmented neutrophils and mild hypoalbuminemia. Trimethoprim sulfadiazine was then administered at a dosage of 30 mg/kg per os for a week. After a short improvement, clinical signs of colic reoccurred.

At admission, the mare's BCS was 3/9. Thrombophlebitis and thrombosis of the left jugular vein were noted. Ultrasonography of the jugular vein revealed hyperechoic foci consistent with gas accumulation, indicative of an anaerobic infection. A fist-size mass was palpable rectally in the area of the hind mesenteric radix. The peritoneal fluid sample was defined as fibrinopurulent exudate. As the mare deteriorated clinically, an exploratory laparotomy was recommended, but was rejected by the owner and the mare was euthanised.

A necropsy and microscopic examination revealed multifocal perforated ulcers of the jejunum of variable size (1–3 cm) with chronic active peritonitis. Multifocal thromboses of the mesenteric arteries were detected as well as acute, subacute and chronic infarcts of the kidney cortex.

In this case, aetiology of jejunal perforation remained unclear, while previously reported causes described parasite migration, diverticulosis and intestinal muscular hypertrophy, NSAID use and various vascular diseases (i.e. ischaemia).

EXTERIOR MEASUREMENTS OF DALMATIAN BUŠAK HORSE TYPE POPULATION**Ema Listeš¹, Eddy Listeš², Ljubo Barbić³, Maja Maurić⁴**¹*Faculty of Veterinary Medicine, University of Zagreb, Croatia, student*²*Regional Institute Split, Croatian Veterinary Institute, Split, Croatia*³*Department of Microbiology and Infectious Diseases with Clinic, Faculty of Veterinary Medicine, University of Zagreb, Croatia*⁴*Department of Animal Breeding and Livestock Production, Faculty of Veterinary Medicine, University of Zagreb, Croatia*

In today's modern world, a lot of effort is put into the conservation of local autochthonous breeds in order to preserve global biodiversity and a larger genetic pool. One of Croatian autochthonous breeds, classified as extinct or unknown, is the Dalmatian Bušak horse. As in Dalmatia there still is a small population of horses that according to their physical characteristics correspond to those of the Dalmatian Bušak, the object of our study was to take their basic body measurements in order to characterise the population, and compare them with those of other Croatian autochthonous breeds (Croatian Coldblood, Croatian Posavina horse and Međimurje horse). Nine measurements were taken from 15 horses by using a Lydtin stick (height at withers, height at croup and chest depth), ribbon (chest and cannon bone circumference) and calliper (shoulder width, croup width and croup length). The Dalmatian Bušak was lower at both withers (129.73 ± 4.78 cm) and croup (130.69 ± 4.75 cm) than other Croatian autochthonous breeds. It also had a shorter body (132.68 ± 5.38 cm) and croup length (43.73 ± 2 cm), narrower shoulder (28.39 ± 2.41 cm) and croup width (40.69 ± 3.01 cm), shallower chest depth (60.31 ± 3.77 cm) and thinner chest (159 ± 11.25 cm) and cannon bone circumference (17.08 ± 1.12 cm). Measurements are given as arithmetic mean and standard deviation. In conclusion, in this preliminary study we found that horses of the Dalmatian Bušak type are a relatively homogeneous population, as well as that they are smaller and differ quite from other Croatian autochthonous breeds. In addition, the Dalmatian Bušak should also be compared to the to the Bosnian Mountain horse, as they are similar in type and have a neighbouring geographic distribution.

**/// PHD DAY OF THE FACULTY
OF VETERINARY MEDICINE,
UNIVERSITY OF ZAGREB ///**

//// INVITED LECTURE

MANNA THE MARIE-CURIE EUROPEAN JOINT DOCTORATE IN MOLECULAR ANIMAL NUTRITION, A TRANS EUROPE COLLABORATION BETWEEN UNIVERSITIES AND THE COMMERCIAL SECTOR

Peter David Eckersall

University of Glasgow and University of Zagreb

The EU-funded European Joint Doctorate in Molecular Animal Nutrition (MANNA) is a research and training project being carried out across Europe that is designed to train a cohort of 11 early stage researchers (ESR) by undertaking dual PhD degrees in two leading European universities while being trained in advanced technology to be applied in animal science.

The MANNA project links the veterinary and animal science faculties of the Universities of Zagreb, Glasgow, Milan, Bonn, Barcelona and Košice with the ESRs using genomics, proteomics and metabolomics to enhance research in cattle, pig and chicken nutrition. Each of the 11 projects within MANNA examines the interaction between genes, proteins and metabolites. For example for the two ESRs based in Zagreb the response of chicken to diet modified with immune mediating feed is being determined in a collaboration with the University of Glasgow while the effect of enhancing the diet of calves with bioactive lipids on growth and metabolism is being undertaken with the University of Bonn. In addition to the scientific investigations being undertaken by the ESRs a full training programme is underway with a mix of summer schools, internal training and placements with partners from non-academic sectors.

The MANNA project has a committed role to integrate links with industry and research institutes such that the ESRs will develop close links to the animal nutrition, animal health and diagnostic sectors. The MANNA project is a model for the future of programmes to develop dual degrees between the advanced Faculties in Europe for co-tutelle postgraduate education that will provide integrated education for the researchers of the future.

//// ORAL PRESENTATIONS

POSTMORTAL AND MOLECULAR RESEARCH OF BACTERIAL AND PROTOZOAL VECTOR-BORNE DISEASES OF CATS AND DOGS

Doroteja Huber

Department of Veterinary Pathology, Faculty of Veterinary Medicine, University of Zagreb, Croatia

Vector-borne diseases (VBD) present a global health problem of cats and dogs. Pathogenicity of VBD-causing pathogens is usually evaluated in clinical studies, while lesions caused by pathogens are rarely described. This study investigated VBD-causing pathogens in cats and dogs from Croatia, with determination of pathogen involvement in lethal outcome of the host.

Dead anemic, icteric, thrombocytopenic animals and/or animals infested with ticks/fleas were necropsied and samples from parenchymal organs were collected for histologic and molecular investigation. All of the samples were screened by using conventional PCR for the presence of *Anaplasma/Ehrlichia*, *Babesia/Theileria*, *Bartonella*, *Cytauxzoon*, *Hepatozoon*, haemotropic *Mycoplasma* and *Rickettsia* DNA.

In cats, pathogens were detected in 29 of 37 animals (78%): *Candidatus Mycoplasma haematoparvum* (20 cats), *Can. M. haemominutum* (8), *Babesia canis* (5), *Can. M. turicensis* (3), *Mycoplasma haemofelis* (3) and *Bartonella clarridgeiae* (1), with co-infections in 11 cats. Single or multiple haemotropic *Mycoplasma* infection was associated with lethal outcome in 3 of the cats due to circulatory collapse and hypoxia, and with non-lethal anemia in 4 additional cats.

From 64 analysed dogs, 30 (47%) harboured pathogens: *B. canis* (25 dogs), *Hepatozoon canis* (7), *M. fastidiosum* (2) and *Can. M. haematoparvum* (1), with co-infections in 5 dogs. The only pathogen that caused lesions in the infected dogs was *B. canis*, leading to death in 17 dogs due to severe haemolytic crisis with septic shock. None of the other detected pathogens caused death or detectable lesions.

Cats in Croatia are mostly infected by flea-borne pathogens, namely haemotropic *Mycoplasma*, rarely causing lethal disease, even in co-infections. Dogs are mostly infected by tick-borne pathogens. *B. canis* was the only pathogen able to cause multi-systemic, lethal disease, but it was also found in dogs without any lesions, indicating the possibility of a subclinical infection.

INFLUENCE OF GENDER AND CASTRATION ON EXPRESSION AND DISTRIBUTION OF TRANSPORTERS INVOLVED IN TRANSEPITHELIAL GLUCOSE TRANSPORT IN PORCINE SMALL INTESTINE

Mirela Pavić

*Department of Anatomy, Histology and Embriology, Faculty of Veterinary Medicine,
University of Zagreb, Croatia*

The sodium-glucose cotransporter 1 (SGLT1) transports glucose across the brush-border membrane of the small intestine, whereas the basolateral sodium-independent transporter 2 (GLUT2) transfers the glucose out of enterocytes. The sodium-potassium pump (Na/K-ATPase) actively transfers excessive sodium ions. The study was conducted on 20 pigs of the Swedish Landrace breed, divided into four groups: males, females, castrated males and castrated females. Tissue samples of the duodenum, jejunum and ileum were taken and analysed by immunostaining of tissue cryosections, Western blotting and polymerase chain reaction (PCR). The cellular localisations for Na/K-ATPase and GLUT2 on basolateral membranes and for SGLT1 on the brush-border membrane of enterocytes were confirmed. The expression of Na/K-ATPase at the protein level shows gender differences (males < females), while the existence of gender differences at the mRNA level was not detected. The expression of SGLT1 at the protein level does not show gender differences, while the existence of gender differences was observed at the mRNA level (males > females). The expression of GLUT2 at the protein level, similar to Na/K-ATPase, shows gender differences (males < females), whereas the existence of gender differences at the mRNA level was observed only in the ileum. The observed gender differences in the Na/K-ATPase and GLUT2 protein expression are due to the inhibitory effect of male sex hormones at the posttranscriptional level of gene regulation in the small intestine, whereas SGLT1 exhibits different molecular features without gender differences in the expression. The expression of functionally linked Na/K-ATPase and SGLT1 increases from the duodenum to the ileum, while GLUT2 has the highest expression in the jejunum. This distribution pattern of transporters involved in glucose transport indicates that the jejunum and ileum are the main sites of glucose absorption in the small intestine of a pig.

MOLECULAR EPIZOOTIOLOGY AND VALIDATION OF FELINE IMMUNODEFICIENCY VIRUS DIAGNOSTICAL PROCEDURES IN CROATIA

Matko Perharić

Department of Microbiology and Infectious Diseases with Clinic, Faculty of Veterinary Medicine, University of Zagreb, Croatia

Feline immunodeficiency virus (FIV) is a significant pathogen of domestic and non-domestic felids worldwide. After the integration of the provirus into host cell genome, FIV causes a lethal, incurable and lifelong infection. The aim of this study was to analyse and determine the epizootiological features, as well as the prevalent subtype and phylogenetic characteristic of FIV in the domestic cat population of Croatia.

A total of 285 different blood samples of domestic cats were tested using a rapid enzyme-linked immunosorbent assay for the detection of FIV antibodies. To establish the epizootiological features, the cats were divided according to clinical presentation, sex, neutering status and age. Following DNA extraction from 143 blood samples (86 ELISA-positive and 57 negative), the polymerase chain reaction was performed to amplify the FIV proviral gag gene. The positive PCR product samples were sequenced in both directions and gag sequence fragments were compared against previously reported gag sequences in the GenBank in order to determine the phylogenetic characteristic.

The overall seroprevalence of FIV infection among domestic cats in Croatia was 21.4%. A statistically significant clinical feature in FIV-infected cats was inflammatory lesions of the oral cavity. The confirmed risk factors include the male sex, non-castration and age over 6. Based on the sequence diversity, all of the 53 Croatian gag sequences were clustered within the FIV B subtype.

This research shows a high seroprevalence of FIV among domestic cats. To prevent a potential infection, all cats with outdoor access should be neutered, unless used for breeding. All FIV isolates identified in this research belong to the FIV B subtype. The Croatian isolates show a close phylogenetic relationship with the Austrian and Italian ones, confirming the circulation of FIV regional viral strains. The obtained data are a necessary prerequisite for developing more reliable molecular diagnostic tools, as well as for the development and introduction of an effective FIV vaccine against field strains.

VARIABILITY OF GENES OF MAJOR HISTOCOMPATIBILITY COMPLEX IN RED DEER (*CERVUS ELAPHUS*) IN RELATION TO *FASCIOLOIDES MAGNA* INFECTION

Miljenko Bujanić

Faculty of Veterinary Medicine, University of Zagreb, Croatia

Major Histocompatibility Complex (MHC) genes play a pivotal role in the host defence system by enabling the presentation of parasitic antigens to the immune system. Two main hypotheses are that heterozygotes are more resistant to diseases than homozygotes; and that resistance/susceptibility toward certain pathogens is influenced by specific alleles. As non-native disease, fascioloidosis is an ideal model for monitoring the development of host-parasite interactions.

For this research, 117 red deer samples were collected (Gorski kotar (n = 26), Lipovljani (n = 28), Radinje (n = 31), Vrbanja (n = 8), Spačva (n = 11), Tikveš (n = 13)). The locations were chosen according to the presence of *F. magna*. The livers were analysed macroscopically. The sequencing of the DRB MHC class II exon 2 was carried out using the Next Generation Sequencing (NGS).

The prevalence in regions with *F. magna* was 82.4%. Exon 2 of the DRB MHC class II was analysed in 46 selected animals. A total of 44 different alleles were detected, with a maximum number of 4 alleles per animal, suggesting the existence of 2 DRB loci. Four alleles were previously known (DRB_NS36, DRB_NS38, DRB_ref01 and DRB_ref02), while other 40 were detected for the first time. Only 3 alleles are common for the red deer population from the Gorski kotar region and the lowland part of Croatia. The DRB_ref01 and DRB_ref06 alleles were detected only in the lowland populations, and the differences in the infection between animals with the DRB_ref01 and DRB_ref06 alleles were statistically significant.

The fact that only 3 alleles are common in the red deer population from the Gorski kotar region and the lowland part of Croatia supports the hypothesis of the existence of two red deer subspecies – the Dinaric and Pannonian deer. The relationship between the DRB_ref01 and DRB_ref06 alleles suggests a potential evolution of host-parasite interaction.

Acknowledgement: Fully supported by the Croatian Science Foundation grant UIP 3421.

EFFECT OF HEAT STRESS ON ANTIOXIDATIVE STATUS AND MACROMINERAL METABOLISM IN DAIRY COWS DURING TRANSITION PERIOD

Nikola Rošić

Veterinarska stanica Jastrebarsko Veterinary Clinic, Jastrebarsko, Croatia

Heat stress (HS) evokes physiological and metabolic adaptive mechanisms with the consequences of metabolic disorders, oxidative stress and inflammation, causing decreased immunity of cows, especially during the transition period. The aim of this study was to analyse the effects of heat stress on energy metabolism, macromineral concentrations, antioxidative status, acute phase response and hormonal function of adipose tissue of cows during the transition period from 3 weeks before calving until 5 weeks after calving.

A total of 24 Simmental dairy cows were divided into two equal groups according to the time of calving: the summer and autumn periods. In both groups, physiological parameters (rectal temperature, respiratory rate and heart rate) were measured and blood samples were taken seven times: 21 and 7 days before calving and on the 8th, 16th, 24th, 32nd and 40th day after calving.

The physiological parameters and temperature-humidity index values in the summer indicated a mild to moderate HS in cows. Non-esterified fatty acids (NEFA), β -hydroxybutyrate and bilirubin concentrations and gamma-glutamyl transferase activity were lower in the summer than in the autumn, indicating a decrease of the NEFA response during HS.

A lower paraoxonase 1 and superoxide dismutase activity in the summer suggested that the HS cows had a more prolonged negative energy balance and oxidative stress than the cows in a thermoneutral zone. A higher concentration of serum amyloid A in the summer is an indicator of the acute phase response due to the detrimental effect of HS on the transitional cows' innate immune system. A lower leptin concentration in the HS cows suggested the preservation of glucose in order to decrease NEFA oxidation for energy requirements. A higher adiponectin concentration in the HS cows also indicated a reduced lipomobilisation and a higher degree of inflammatory response in HS conditions. The obtained results will contribute to the development of new strategies to alleviate the negative effects of HS on welfare and production in dairy cattle.

CORRELATION BETWEEN ENERGY METABOLISM OF COWS IN EARLY PUERPERIUM AND CALVES IN NEONATAL PERIOD

Ivana Pipal

VETMED d.o.o. Veterinary Clinic, Popovača, Gornje Selo 59, Stručec

Energy metabolism in cows and calves during early puerperium and early neonatal periods was analysed using blood biochemical parameters.

The study included Simmental cows (n = 13) and calves (n = 13). Blood was obtained 6, 12 and 48 hours and 7, 14 and 30 days after birth. The parameters analysed were glucose, total protein, albumin, urea, triacylglycerols, total cholesterol, HDL cholesterol, LDL cholesterol, β hydroxylacetic acid (BHB), non-esterified fatty acids (NEFA), insulin and IGF-1 concentrations.

The glucose concentration in the cows' serum decreased during the study, while it increased in the calves. The concentration of albumin showed a significant decrease in cows, while total protein was constant. In calves, total serum protein significantly increased up to the 7th day, while albumin significantly increased from the 7th to the 30th day. Urea in cows' serum significantly decreased from the 6th to the 48th hour. The concentration of triacylglycerols in cows' serum significantly reduced up to 48 hours. The concentration of total cholesterol in cows significantly increased from the 7th day, and in calves it increased from the 48th hour. HDL in cows significantly fell from the 6th to the 48th hour, increased on the 7th day and remained at that level. In calves, HDL concentration significantly increased from the 48th hour. LDL cholesterol in cows significantly increased from the 7th to the 30th day, while in calves it was constantly increasing from the 12th hour. BHB in cows and calves was low until the 30th day, when it showed a significant increase. The concentration of NEFA in cows significantly decreased from the 6th until the 12th hour, increased from the 48th hour until the 7th day, and decreased until the end of the study. In calves, it was significantly lower until the 14th day and then showed a slight increase.

The obtained results indicate rapid and significant changes in energy metabolism in the first hours after birth. Biochemical parameters in early neonatal period are different compared with the parameters after the 7th and 14th day.

