

# Spine and Spinal Cord War Injuries during the War in Croatia

Stipan Janković, MD PhD\*  
Željko Bušić, MD†

Dragan Primorac, MD PhD‡

**Objective:** The present report summarizes the experience of an evacuation hospital in southern Croatia in treating 96 patients with spine and spinal cord war injuries. **Methods:** A retrospective review was done for 96 wounded persons (86 soldiers, 10 civilians) with spinal cord injuries from August 1991 through December 1995. The ages ranged from 15 to 59 years (mean, 28.3 years for soldiers, 38.5 years for civilians). Diagnostic procedures were plain radiography, computed tomography, and computed tomographic myelography. However, in most cases a more conservative surgical approach was used. **Results:** The highest rates of admittance were recorded in 1992 ( $N = 38$ ) and 1993 ( $N = 47$ ). The lumbar spine was injured in 55% of the patients, the cervical and thoracic spines in 17.7%. All injuries were caused by projectiles from automatic rifles and sniper fire (51%) and from fragments of explosive devices (49%). Blast injury of the spinal cord was found in 10 patients. The most frequent complications caused by the fragments were wound infection, urinary tract infection, decubitus, and pneumonia. Four patients (4.2%) died in the hospital, and 43.0% of patients survived but were severely handicapped. **Conclusion:** Careful clinical examination combined with modern diagnostic imaging and use of broad-spectrum antibiotics reduced the need for surgical intervention in patients with spinal cord injuries.

## Introduction

From a military medicine point of view, the characteristics of the war in Croatia were as follows<sup>1-7</sup>: (1) conflicts of limited intensity with sudden massive attacks, mainly on civilian targets; (2) more than one-third of Croatian territory was occupied, and evacuation after injury was slow and impeded by poor roads and blocked roads; (3) lack of ambulance vehicles adapted for difficult conditions on the ground and complete lack of safe and effective helicopters for evacuation; (4) lack of any professional military medical experience; (5) limited supplies of equipment, making surgical management very complex; (6) poor communication network, limiting exchange of data on casualties; and (7) use of unconventional weapons such as multiple mine pallets and "dumdum" bullets.

Besides these limiting factors, spinal cord injuries constituted a large medical problem. Such injuries have a high mortality rate, with severe consequences for the patient, the patient's family, and society as a whole. However, the management of these injuries remains controversial.<sup>8-12</sup>

The purpose of this study was to review our experience in the management and clinical outcome of 96 patients with war injuries to the spinal cord during the war in Croatia from 1991 to 1995.

\*Department of Radiology, †Department of Neurosurgery, and ‡DNA Forensic Science Laboratory, University Hospital Split, Split, Croatia.

This manuscript was received for review in December 1997. The revised manuscript was accepted for publication in April 1998.

Reprint & Copyright © by Association of Military Surgeons of U.S., 1998.

## Patients and Methods

From August 1991 to December 1995, during the war in southern Croatia, 96 patients with war spine and spinal cord injuries (mostly penetrating) were treated at the Department of Neurosurgery, Clinical Hospital Split. This hospital was the main evacuation hospital for the area of southern Croatia as well as for a great part of neighboring Bosnia and Herzegovina. After triage (these patients formed the group that did not warrant priority for evacuation from the battlefield) at the first level of care (the aid station and its associated ambulance clearing company) and the second level of care (the mobile surgical hospital or field hospital), the patients required transfer by ambulance vehicles or helicopter to the evacuation hospital. Upon arrival, the patients were treated and stabilized in the emergency room.

Antibiotic (penicillin, gentamicin, metronidazole), antitetanic (tetanus toxoid), and antiedematous (corticosteroid bolus) therapies were administered. Foley catheters were inserted and multidisciplinary management was continued.

All patients underwent plain radiography of the involved regions as well as computed tomography, if indicated. Myelography or computed tomographic myelography was performed when there was evidence of cerebrospinal fluid leaking from the wound to locate the site of the dural tear and when progressive neurologic deficit was suspected.

Of the 96 patients, 86 of them (90%) were soldiers and the remaining 10 were civilians (4 women and 6 men). The mean age of the wounded soldiers was 28.3 years (range, 17-61 years), and the mean age of the injured civilians was 38.8 years (range, 15-59 years).

The majority of the patients arrived within 24 hours from the time of injury (range, 1 hour to 15 days). Associated injuries to other organs and systems occurred in 50 patients (52.0%). The patients were separated into two clinical groups according to spinal cord deficit. Deficits were considered "complete" if total loss of function existed and "incomplete" if any function remained below the level of injury.

Our indications (criteria) for surgical intervention were incomplete spinal cord deficit, progressive neurologic deficit, presence of an active cerebrospinal fluid fistula and a grossly contaminated wound, and injuries to the cauda equina.

All other patients were treated conservatively (without laminectomy). Physiotherapy and psychosocial rehabilitation were started as soon as possible for all patients. After completion of the neurosurgical treatment, patients continued their rehabilitation in specialized centers.

## Results

War injuries of the spine and spinal cord according to year are shown in Figure 1. War injuries according to the spinal segments are shown in Figure 2. The mechanisms of injury are shown in Figure 3.

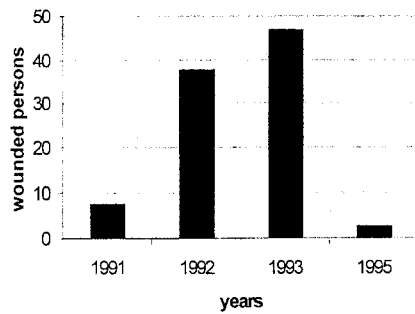


Fig. 1. War injuries of the spine according to years.

Different radiological findings in wounded persons with spine and spinal cord injuries are shown in Table I. Various complications that appeared during hospitalization are shown in Table II.

Of the 96 patients, 27 (28%) were treated surgically, i.e., underwent bilateral laminectomy at the level of the injury. Removal of intraspinal missiles or bone fragments was performed only in cases of compression of the neurologic structures. For 6 patients who were treated surgically because of spinal instability (22.2%), stabilization procedures were performed 2 to 3 months later. All other patients ( $N = 69$ , 72%) were treated conservatively. During hospitalization (average length, 17 days; range, 14–93 days), 4 patients (4.2%) died.

### Discussion

In this study, we present our experiences in the treatment of patients with spine and spinal cord injuries in the region of southern Croatia. Despite the experiences by different authors, the optimal management of missile wounds of the spine remains controversial and unclear. With each patient we were faced with the dilemma of whether to begin surgical treatment or use a conservative approach. However, surgical management was restricted compared with similar series of spinal injuries in civilians.

According to North Atlantic Treaty Organization doctrine (which was accepted by the Croatian Army Medical Service), indications for the surgical treatment of war spinal injuries are progressive neurologic deficit and spinal instability. Injuries that cause complete neurologic deficit below the level of injury do not indicate surgery.<sup>13</sup>

During the Vietnam War, U.S. Army neurosurgical policy dictated obligatory laminectomy for all patients with spinal

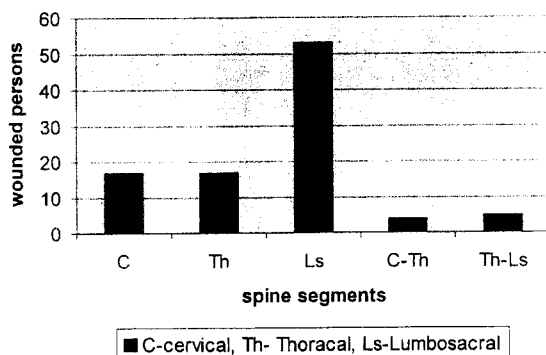


Fig. 2. War injuries of the spine according to segments.

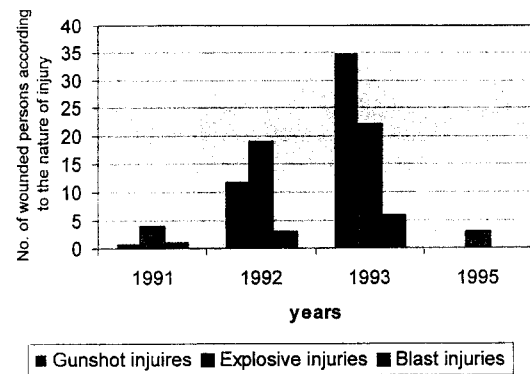


Fig. 3. Penetrating injuries of the spine and spinal cord.

wounds. Furthermore, during the Korean conflict, Wannemaker advocated early laminectomy for all penetrating spinal injuries affecting the cervical cord.<sup>14</sup>

During the war in Croatia in a few hospitals in the capital city of Zagreb, all patients with neurologic deficit underwent surgical decompression and spinal canal revision to relieve the compression of the spinal cord. Those procedures created conditions for preservation and activation of the remaining intact portion of the spinal cord.<sup>15–18</sup> It is noteworthy that these were mainly selected patients already triaged at other hospitals, and not wounded persons direct from the site of injury. We followed the advice of those authors who advocate more conservative treatment of war spinal injuries.<sup>19–22</sup>

Our results are in agreement with those of Yashon et al.,<sup>23</sup> who concluded “that the final outcome in these patients is closely correlated with the initial neurological status rather than with surgery and that the performance of a laminectomy does not seem to influence the outcome.” We agree with Hammoud et al.,<sup>24</sup> who wrote: “Laminectomy for treating penetrating missile cord injuries has no significant advantage in terms of neurological outcome.”

It is interesting that our results are almost identical with those of Rukovanjski,<sup>25</sup> who described the experience of treating war spinal injuries that occurred in eastern Croatia and were treated in Osijek Clinical Hospital (the main evacuation hospital in the war zone of eastern Croatia).

### Conclusion

Our data suggest that a more conservative approach, rather than laminectomy and removal of fragments from the spinal

TABLE I  
RADIOLOGIC DIAGNOSES FOR WAR SPINE AND SPINAL CORD INJURIES

Radiologic Findings	Patients	Percentage
Isolated fracture of the spine (without spinal cord lesion)	12	12.5
Fracture of the spine with lesion of spinal cord	68	70.8
Lesion of spinal cord without lesion of the spine	10	10.4
Fracture of the spine with luxation/subluxation of the spine	6	6.3

TABLE II  
COMPLICATIONS IN PATIENTS WITH SPINAL CORD INJURIES

Complication	Patients	Percentage
Wound infection	24	25.0
Decubitus	10	10.4
Urinary tract infection	8	8.3
Pulmonary embolism	2	2.1
Pneumonia	10	10.4
Venous thrombosis	1	1.0
Septicemia	1	1.0
Intradural abscess	1	1.0
Spondylitis	1	1.0
Total	58	60.2

canal, yields good results. Surgical treatment should be reserved for patients with leaking spinal fluid, progressive neurologic deficit, spinal instability, and root pain. Modern imaging techniques in diagnostic facilities (computed tomography, computed tomographic myelography), appropriate anatomic diagnosis, and treatment with broad-spectrum antibiotics significantly decrease the likelihood of infection; therefore, the metal and bone fragments need not be removed.

### References

- Lacković Z, Markeljević J, Marušić M: Croatian medicine in 1991 war against Croatia: a preliminary report. *Croat Med J* 1992; 33(suppl II): 110-9.
- Luetić V, Šoša T, Tonković I, et al: Military vascular injuries in Croatia. *Cardiovasc Surg* 1993; 1: 3-6.
- Radonić V, Barić D, Petričević A, Andrić D, Radonić S: Military injuries to the popliteal vessels in Croatia. *J Cardiovasc Surg* 1994; 35: 27-32.
- Radonić V, Barić D, Petričević A, et al: War injuries of the crural arteries. *Br J Surg* 1995; 82: 777-83.
- Janković S, Žuljan I, Sapunar D, Buča A, Pleština-Borjan I: Clinical and radiological management of wartime eye and orbit injuries. *Milit Med* 1998; 163: 423-6.
- Janković S, Sapunar D, Jurišić Z, Majić V: Medical support to a nonprofessional brigade during the Croatian Operation Storm. *Milit Med* 1997; 162: 37-40.
- Janković S, Dodig G, Biočić M, et al: Analysis of medical aid to Croatian Army soldiers wounded at the front line. *Milit Med* 1998; 163: 13-6.
- Jacobs GB, Bergs RA: Treatment of acute spinal cord injury in war zones. *J Neurosurg* 1971; 34: 163-70.
- Papa J, Doko Z, Vučković R, et al: The value of CT myelography in the analysis of bullet lesions of the spine. *Reumatizam* 1994; 1(suppl 2): 15-6.
- Janković S, Buča A, Lahman M, Devčić S, Bušić Ž: The role of computed tomography in diagnosis of war injuries of the spine and spinal cord. *Reumatizam* 1994; 1(suppl 2): 1-4.
- Collins KF: Surgery in the acute treatment of spinal cord injury: a review of the past forty years. *J Spinal Cord Med* 1995; 18: 3-8.
- Yoshida GM, Garland D, Waters RL: Gunshot wounds to the spine. *Orthop Clin North Am* 1995; 26: 109-16.
- Bowen TE, Bellamy RF: *Emergency War Surgery. Second US revision of the Emergency War Surgery NATO Handbook.* Washington, DC, US Government Printing Office, 1988.
- Wannamaker GT: Spinal cord injuries: a review of the early treatment of 300 consecutive cases during the Korean conflict. *J Neurosurg* 1954; 11: 517-24.
- Nanković V: Spine war injuries. *Reumatizam* 1994; 1(suppl 2): 7-10.
- Kvesić D, Nanković V, Šegvić P: Cervical spine war injuries. *Reumatizam* 1994; 1(suppl 2): 17-20.
- Kejla Z, Kvesić D, Nanković V, Buljat G, Šegvić P: Thoracic spine war injuries 1991-1993. *Reumatizam* 1994; 1(suppl 2): 21-3.
- Buljat G, Nanković V, Kvesić D, et al: Lumbar spine war injuries. *Reumatizam* 1994; 1(suppl 2): 25-30.
- Demetriades D, Theodoron D, Cornwell E, et al: Transcervical gunshot injuries: mandatory operation is not necessary. *J Trauma* 1996; 40: 758-60.
- Lin SS, Vaccaro AR, Reich SM, et al: Low velocity gunshot wounds to the spine with an associated transperitoneal injury. *J Spinal Disord* 1995; 8: 136-44.
- Kihūr T, Ivatury RR, Simon R, Stahl WM: Management of transperitoneal gunshot wound of the spine. *J Trauma* 1991; 31: 1579-83.
- Robertson DP, Simpson RK: Penetrating injuries restricted to the cauda equina: a retrospective review. *Neurosurgery* 1992; 31: 265-9.
- Yashon D, Jane JA, White RJ: Prognosis and management of spinal cord and cauda equina injuries in 65 civilians. *J Neurosurg* 1970; 32: 163-70.
- Hammoud MA, Haddad FS, Moufarrij NA: Spinal cord missile injuries during the Lebanese civil war. *Surg Neurol* 1995; 43: 432-42.
- Rukovanjski M: Spinal cord injuries caused by missile weapons in the Croatian war. *J Trauma* 1996; 4(suppl): 189-92.