

Axial vs. Angular Dynamization of Anterior Cervical Fusion Implants

Marin Stančić¹, Petra Margetić², Esmat Elabjer³ and Milan Milošević⁴

¹ Department of Neurosurgery, University Hospital »Dubrava«, School of Medicine, University of Zagreb, Zagreb, Croatia

² Department of Radiology, University Hospital of Traumatology, School of Medicine, University of Zagreb, Zagreb, Croatia

³ Sports Department, University Hospital of Traumatology, School of Medicine, University of Zagreb, Zagreb, Croatia

⁴ Outpatient Orthopaedic Office, Zagreb, Croatia

ABSTRACT

Aim of our study was to compare anterior cervical fusion with fusion augmented with dynamic implants and with the first generation H-plate. Methods. Patients with radiculopathy and/or myelopathy were included in a prospective cohort study. Clinical outcome was assessed according to the Nurick, Odom, and SF 36 scales. Rotation and translation of screws, and quality of fusion (Tribus) were assessed at the 6-week and 4-year follow-up examinations. Neurodecompression was performed in 81 patients (one-level N=45, two-level N=26 and multi-level N=10) in the period from January 2001 to September 2003. 50 male and 31 female patients were divided into three groups, depending upon type of fusion: 1. Augmented with dynamic implants (N=33), 2. Augmented with H-plate (N=33), and 3. Non-augmented (N=15), one-level. There were no significant differences in clinical outcomes between the groups. Dynamization was detected in both augmented groups: axial in the dynamic implant group (mean translation \pm SD = 2.67 ± 0.79 mm), and angular in the H-plate group (angle of rotation $7.2^\circ \pm 3.04^\circ$). Six-week fusion was significantly better in the dynamic implants and non-augmented groups, as compared with the H-plate group. Two patients in the H-plate group developed pseudoarthrosis, 7 patients in the dynamic implant group had supradjacent segment heterotopic ossification and two of these additional ankylosis. Three patients in the non-augmented group had dislodgement of the bone graft with transient dysphagia in one of them. Our results suggest that selection of implants is not crucial for clinical outcome. Subsidence is allowed with both fixation systems. Fusion is faster and more effective in the axially dynamized group.

Key words: surgical procedure, anterior, cervical plate, myelopathy, decompression, cervical fusion

Introduction

Cervical spondylotic myelopathy (CSM) is the most common pathological condition affecting the spine of older persons^{1,2}. Untreated CSM has a progressive clinical course that could lead to a spastic paraplegia in the elderly³. The best type of surgical procedure for cervical radiculomyelopathy is not known⁴. Decompression of the cord or the nerve root is the principal aim⁵. Anterior cervical decompression was introduced in the mid-1950s^{6,7}. Despite the fact that following its first publication it was critically compared with »russian tonsilectomy«, this new technique became widely accepted⁸. Anterior cervical decompression is traditionally combined with fusion of the decompressed segment, although existing evidence shows that this may not be necessary or appropriate⁹⁻¹². Osteogenic, osteoconductive and osteoinductive properties of

autologous bone graft theoretically secure the best possible fusion, which has been confirmed in the clinical practice^{13,14}. High incidence of iliac crest donor site pain after graft harvest procedures stimulated introduction of nonautologous interbody fusion materials¹⁵. Some authors reported better fusion without pain in the graft donor site with bone graft substitutes^{16,17}. Donor site pain is quite rare and well tolerated by patients in the results of other studies^{18,19}. Pioneers of anterior decompression and fusion technique had high rates of pseudoarthrosis and kyphosis in multilevel procedures, which led to the development of an anterior internal fixation device in 1964²⁰. From Boehler till now many different plates, divided in three generations, were designed. Unrestrictive backout plates represent the first generation of internal



Fig. 1. Upper: Classification system for anterior cervical plate constructs. Left: First generation unrestricted backout plate. Center: Second generation restricted backout semi-constrained plate. Right: Third generation dynamic plate.

fixation (Figure 1 upper, lower-left). In the second generation, backout of the screws is restricted by locking of the screw head (Figure 1 lower-center) and plates are designed in two variants: constrained and semi-constrained rotational system. The third generation comprises dynamic plate, designed as alignment guide that allows almost 100% of axial graft loading, in order to stimulate natural bone healing (Figure 1. lower-right). Internal fixation became an unavoidable part of every cervical spine fusion, even in one-level decompression²¹. The clinician is faced with a burgeoning and bewildering array of plate designs, each claiming to secure the best clinical outcome. In view of this uncertainties, it is not surprising that there are substantial variations in the proportion of the patients with cervical spondylotic radiculomyelopathy who are referred for surgery. In addition, appearance

of every new and better designed internal fixation system is connected with price increase.

In a prospective cohort study, we investigated whether fusion with the third generation dynamic fixation system is better than fusion with the first generation unrestricted backout plate. The second aim of the study was to answer the question: »Is fusion without any augmentation equally effective as fusion with implants after one level discectomy?«

Patients and Methods

Patients

Between January 2001 and September 2003, a total of 81 patients with spondylogenic radiculopathy and/or myelopathy eligible for the study were referred from neurosurgical outpatient department to our hospital. Their symptoms had not decreased despite the application of conservative therapy. The indication for surgical treatment and inclusion criteria were symptoms and signs of compressive radiculopathy or myelopathy. Multi-level patients with cervical kyphosis or negative Ishihara index (Figure 2 left) were included into the study. The existence of MRI or CT/myelography confirmed cord and/or nerve root compression was required for the inclusion into the study (Figure 2 right). Patient's consent to participate in the independent clinical and radiographic follow-up was also required. Patients whose primary symptoms were either axial pain or those with a history of previous cervical spine surgery, fracture, tumor, intradural pathology or segmental instability (>3 mm) were excluded.

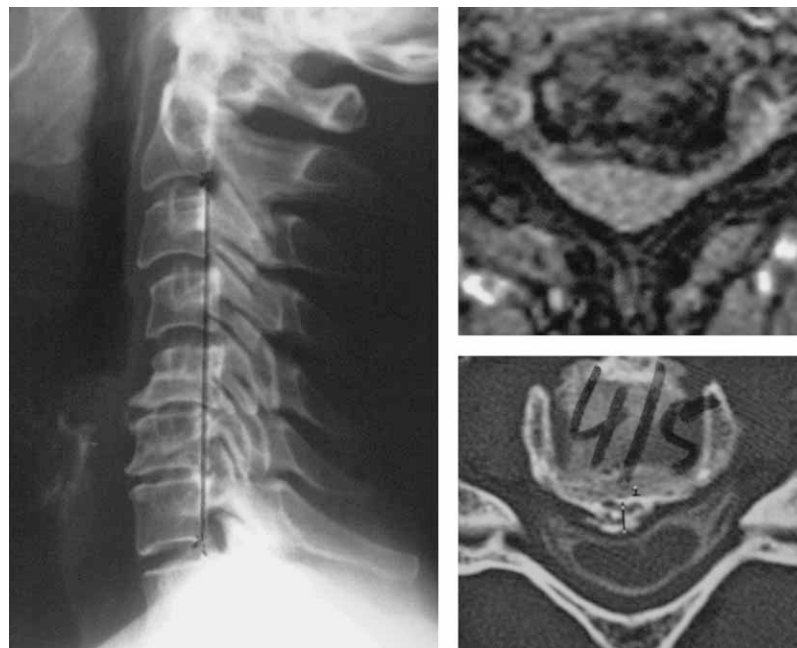

Fig. 2. Left: Kyphotic cervical spine with negative Ishihara index. Right: Spinal cord compression shown by MRI (upper) and CT after myelography (lower).

Ethics Committee approved the clinical trial. Patients were informed about surgical treatment options and offered non-augmented fusion after one-level discectomy without need for plating, decompression with fusion augmented with H-plate as classical surgical technique or augmentation with dynamic internal fixation system that offers theoretical advantages, but that new internal fixation device is still in the clinical research phase. Patients were allowed to choose their type of surgery, and, therefore, were allocated into one of three study groups. According to previous clinical studies results, we planned 33 patients for each augmented group, 15 one-level patients, 13 two-level and 5 multilevel patients^{22,23}. 15 one-level patients were planned for the non-augmented fusion group. Cessation of the study was planned when the proposed number of patients in each subgroup had been operated on. A four-year follow-up was planned.

Surgical Treatment

An anterior approach to the cervical spine was performed from the right side. The patients were placed in the supine position. The head was slightly extended and the shoulders were pulled down with the duck tape fixation. Visualization was obtained through a horizontal incision for one and two level decompression and through incision along the medial border of the sternocleidomastoid muscle for multilevel procedure. A C-arm was used to confirm the level that was going to be operated on. To obtain sufficient medio-lateral exposure the medial aspects of the longus colli muscles were resected from their attachments to the vertebral body. Following incision of the anterior longitudinal ligaments, a Caspar's distractor was placed in the vertebrae above and below the segment planned for decompression. Discectomy and/or corpectomy were performed with a high-speed drill. Using an operative microscope, osteophytes and ossifications of the posterior longitudinal ligament (OPLL) were removed. Iliac crest autologous bone graft was inserted under compression. In the H-plate group, fusion was augmented with the first generation Orozco plate (Instrumentarija, Zagreb, Croatia). In the dynamic group, fusion was augmented with DOC implants (Acromed, Johnson&Johnson, USA). Multilevel decompression was performed with preservation of intermedial vertebra in order to avoid a bridging plate construction. Before wound closure, a lateral X-ray was done to confirm satisfactory graft and implant placement. A cervical orthosis was applied. The paravertebral drain was removed on the next morning after surgery and the patients were allowed to resume normal activities.

Primary endpoints

Clinical outcomes were assessed using the *Odom criteria*: excellent, good, fair, or poor²⁴. Patients with excellent outcomes were those in whom the following was demonstrated: a significant reduction and/ or cessation of pain medication usage, return to full participation in pre-morbid activities, and/ or return to full-time work; additionally a significant improvement was demonstra-

ted with regard to subjective pain. Good outcomes were found in patients with an improvement in subjective pain, an ability to work part time and/ or partially participate in pre-morbid activities, and a diminished requirement for narcotic and/ or analgesic medications compared with preoperative dependence. Patients with fair outcomes were those with mild improvements in subjective pain, no change in analgesic/narcotic use and only minimal participation in pre-morbid activity and/ or work, while poor outcomes were defined as no reported improvement in pain, no participation in pre-morbid activities/ work, and increased or same levels of narcotic/ analgesic use.

Neurological outcome was assessed according to difference between the preoperative and 4-year follow-up Nurick grade. The Nurick grading scale²⁵ is based on the degree of difficulty in walking as follows: Grade 0-signs or symptoms of root involvement without evidence of spinal cord disease; Grade 1-signs of spinal cord disease without difficulty in walking; Grade 2-slight difficulty in walking which does not prevent full-time employment; Grade 3-difficulty in walking which prevents full-time employment or the ability to do all housework, but not so severe to require someone help to work; Grade 4-patients able to walk only with someone else's help or with the aid of a frame; Grade 5-chair-bound or bedridden.

Possible improvement in the postoperative quality of life was calculated as difference between the preoperative and 4-year follow-up patient-based SF-36 grading scale²⁶⁻²⁸. Mean results are reported on a transformed scale of 0 to 100, with higher numbers representing better outcomes on 8 Health Scales: Physical Function (PF), Role-Physical (RP), Bodily Pain (BP), General Health (GH), Vitality (V), Social Function (SF), Role-Emotional (RE) and Mental Health (MH).

Secondary endpoints

Two independent researchers evaluated radiographs taken at the end of the surgery, at 6-week and at 4-year follow-up examinations. Fusion quality was rated according to the Tribus grading scale as follows (29): 1 – trabeculation and space obliteration (Figure 3 upper-left), 2 – endplate partially obliterated, 3 – lucent lines < 1mm, 4 – lucent lines > 1mm and 5 – motion on flexion-extension x-ray views.

To determine dynamization of the implants, translation and rotation of the instrumented screws were radiologically evaluated. Translation was measured in millimeters as the difference of distances between upper and lower screws (Figure 3 upper-center and right). Rotation of the screws was calculated in grades as the difference between screw-plate angles (Figure 3 lower-left and center). Placement of the implants was graded on the basis of the following criteria²⁹: 1 – ideal, with screws positioned in the vertebral body and the plate not overlapping an adjacent disc space; 2 – fair, with the plate overlapping adjacent disc space (Figure 3 lower-right); and 3 – poor, with screws penetrating into the adjacent disc space.

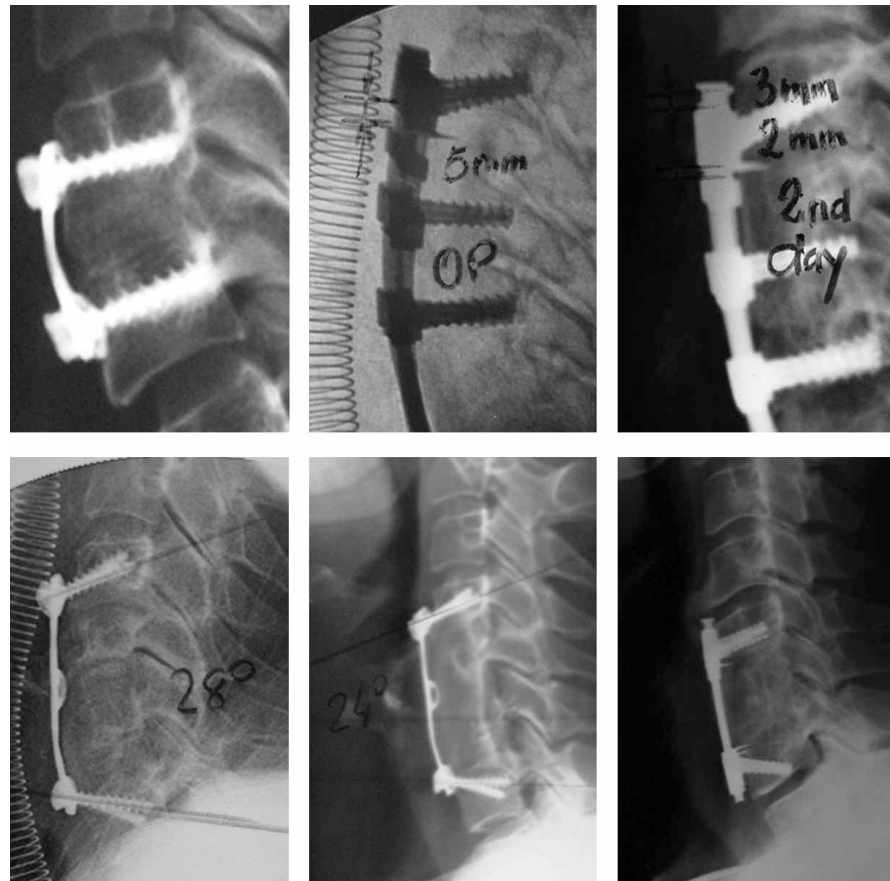


Fig. 3. Upper-left: trabeculation and space obliteration of upper and lower end-plate represent grade 1 according to Tribus classification. Upper-center and right: natural settling under dynamic implants occurred in the first two postoperative days. Lower-left and center: rotation of 4 degrees was noticed on the 6-week follow-up X-ray after two-level corpectomy. Lower-right: vertical rods axial telescoping with overlapping of supradjacent segment induced heterotopic ossification.

Masking and Follow-up

The patients were included into the study by the first author (MS), according to the inclusion and exclusion criteria and their own consent. Selected patients were referred to the second and third independent investigator (PM and EE), who independently examined patients and checked their questionnaires preoperatively and after 4-year follow-up. In addition, they assessed X-rays according to the Tribus criteria. Each patient's medical records were labeled with patient's record number and forwarded to the third and fourth independent investigator (EE and MM) for statistical analysis.

Statistical analysis

The following observed parameters were used in the statistical analysis of differences between the groups: clinical outcomes (SF-36 scale, Nurick criteria, and Odom criteria), and radiological outcomes (Translation and rotation of screws, and Tribus grading scale for grading of fusion and placement of implants). For comparisons between groups the Student t-test was used.

Results

From January 2001 to September 2003, 50 male and 31 female patients fulfilled the inclusion criteria and were allocated into 3 study groups (Table 1). They underwent anterior cervical decompression and fusion. The mean-age was 52 years (52.6 ± 8.42) for the Dynamic system group and 51 years (51.8 ± 8.06) for the H-plate group. Patients with one-level decompression from both groups were compared with 15 patients in whom non-augmented fusion was performed (nine males and six females, mean age 50 years (50.2 ± 7.2)). Two patients in the H-plate group and 1 patient in the DOC group were lost for the 4-year follow-up examination.

Quality of life according to SF-36 significantly improved following surgery in all studied groups (DOC: preoperatively 52.6%, postoperatively 72.7%, $p=0.000001$; H-plate: preoperatively 57.2%, postoperatively 74.6%, $p=0.000001$; NAF: preoperatively 53.5%, postoperatively 75.6%, $p=0.000003$). There were no significant differences between the groups in the postoperative total SF-36 values (DOC fixation vs. »H«-plate $p=0.408537$; »H«-plate vs. NAF $p=0.758439$; DOC vs. NAF $p=0.341247$),

TABLE 1
DEMOGRAPHIC PREOPERATIVE AND FOLLOW-UP DATA OF PATIENTS OPERATED ON USING INSTRUMENTED FUSION WITH DYNAMIC FIXATION (TRIAL) AND FIXATION WITH SEMI-CONSTRAINED CERVICAL PLATE

Parameter	Augmented fusion		Non-augmented fusion (graft)
	Dynamic	»H«-plate	
Gender (M/F)	21/12	20/13	9/6
Age(years) †	52.6±8.42	51.8±8.06	50.2±7.2
One-level decompression	15	15	15
Two-level decompression	13	13	0
Three-level decompression	5	5	0
Average Nurick Grades	0.73±0.70	0.67±0.61	0.67±0.70
p	0.784698 vs H-plate	1.000000 vs NAF	0.824604 vs Dyn

TABLE 2
PRIMARY OUTCOME ACCORDING TO NURICK GRADES AND ODOM'S CRITERIA

Parameter	Augmented fusion		Non-augmented fusion (graft)	
	Dynamic	»H«-plate		
Average Nurick Grades	0.13±0.35 (-0.60)	0.06±0.28 (-0.61)	0.10±0.32 (-0.57)	
P	0.558860 vs H-plate	0.775019 vs NAF	0.811457 vs Dynamic	
p vs preoperative	0.000426	0.000426	0.022204	
Odom's criteria	Excellent	18/32	20/31	9/15
	Good	14/32	11/31	6/15
	Fair	0/32	0/31	0/15
	Poor	0/32	0/31	0/15

TABLE 3
SECONDARY OUTCOME IN AUGMENTED FUSION AND NON-AUGMENTED FUSION GROUP AT 6 WEEKS AND 4 YEARS FOLLOW-UP

Follow-up	Parameter	Augmented fusion		Non-augmented fusion
		Dynamic	H-plate	
6 weeks	Angle (degree) †	0	7.2±3.04	–
	Translation (mm) †	2.67±0.79	0	–
	Fusion grade †	1.53±0.56	2.13±0.62	1.50±0.51
	p	0.000028 vs H-plate	0.000268 vs NAF	0,861215 vs Dyn
4 years	Fusion grades †	1.13±0.34	1.21±0.52	1.1±0.31
	p	0.441864 vs H plate	0.393371 vs NAF	0.731264 vs Dyn
	Complications	HO N=7 Ankylosis N=2	0	Graft dislodgement N=3

although differences were significant in some categories of the test (Table 2). Clinical outcome in all studied patients was graded as excellent or good. One patient had hardware breakage with translucency greater than 1 mm seven months after surgery. CT scan confirmed pseudoarthrosis. Following posterior pedicle screw fixation, the outcome was good. Patients in all studied groups showed significant neurological improvement. Postoperative differences between groups were not significant (Dynamic fixation – »H«-plate $p=0.000426$; »H«-plate – NAF $p=0.000426$; Dynamic fixation – NAF $p=0.022204$).

In the DOC group screw rotation was 0° (Table 3). The mean (range) angle of screw rotation in the »H«-plate group measured 7.2° (4.16° to 10.26°). Angles of rotation in one-level, two level and multilevel decompression in the H-plate fusion subgroups were 4°, 7°, and 8.9° respectively. The mean (range) translation of the screws in the DOC group was 2.67 mm (1.88 to 3.46), while in the H-plate group translation was not detected.

Fusion grade at 6-week follow-up examination was significantly lower in the DOC group (mean ± SD Tribus grade = 1.53±0.56), and in the non-augmented fusion

group (mean \pm SD Tribus grade = 1.50 ± 0.51), whereas in the H-plate group it was higher (mean \pm SD Tribus grade = 2.13 ± 0.62). One patient in the H-plate group had a translucency greater than 1 mm at two-year follow-up examination. Seven patients in the DOC group had heterotopic ossification in the suprajacent segment and two of them also had ankylosis (Figure 4 left). In the last 10 patients of DOC group internal fixation device was placed in the upside-down position to avoid overlapping of adjacent segment with dynamized implants (Figure 4 center and right). We did not notice ossification in the subjacent segment among these 10 patients.

Discussion

Our study showed no differences in the clinical outcome among three different types of fusion following anterior cervical decompression in the treatment of spondylotic radiculomyelopathy. In addition, we showed that the first generation unrestricted backout plates were also dynamic devices permitting angular deformation. Angular dynamization was limited under 10 degrees. Six week follow-up X-rays of the patients with the third generation dynamic implants showed a lower frequency of visible endplate-bone graft interface. One patient in the H-plate group underwent posterior transpedicular fixation due to severe neck pain seven months after surgery, with radiological finding of non-union and hardware breakage (Figure 6) Four-year follow-up X-ray of the second patient from the H-plate group showed translucency greater than 1 mm without clinical signs of non-union.

Our study had at least two weaknesses. First, the group of patients included into the trial was small, because the study was planned for a county hospital where the frequency of surgeries used for the treatment of spondylogenic radiculomyelopathies was relatively low.

Second, allocation of the patients was not random but we allowed the patients to choose the type of surgery. Randomized Controlled Trials is viewed as the gold standard of clinical research when the goal is to compare the efficacy of various treatment options. We believed that for comparison of different types of surgeries, the issues of blinding (for patient, investigators, and treating physicians) and willingness to consent to randomization may limit the scientific validity and practicality of such trials³⁰.

All the surgeries were performed by a single surgeon, which eliminates the influence of different surgical techniques. In addition, according to our best knowledge this is the first study that prospectively compared three common anterior cervical fusion techniques. Epstein, Bose, and Steinmetz reported very promising results obtained by different types of dynamic implants in case series^{31–34}. Epstein compared complications after dynamic plate fixation in multilevel cervical corpectomy and circumferential fusion technique. Introduction of dynamic plates reduced failure rate and need for secondary posterior fusion from 13 to 3.6%³⁵.

Clinical outcome was assessed according to surgeon-based outcome scales (the Nurick grades and Odom criteria) and patient-based outcome scale (SF-36 questionnaire). In the majority of studies dealing with anterior cervical fusion, operative outcomes have been evaluated using surgeon-based criteria^{36–40}. More recently, outcomes have been assessed using patient-based questionnaires, particularly the SF-36. Employing the SF-36 to evaluate outcomes of 28 two-level ACDF, Klein et al.⁴¹ concluded that the SF-36 revealed significant postoperative improvement on 5 Health Scales: Bodily Pain, Vitality, Physical Function, Role-Physical, and Social Function. Epstein combined surgeon-based measures and SF-36 to evaluate results following single-level ACF procedures performed with fixed and/or dynamic plating system^{32,42,43}.

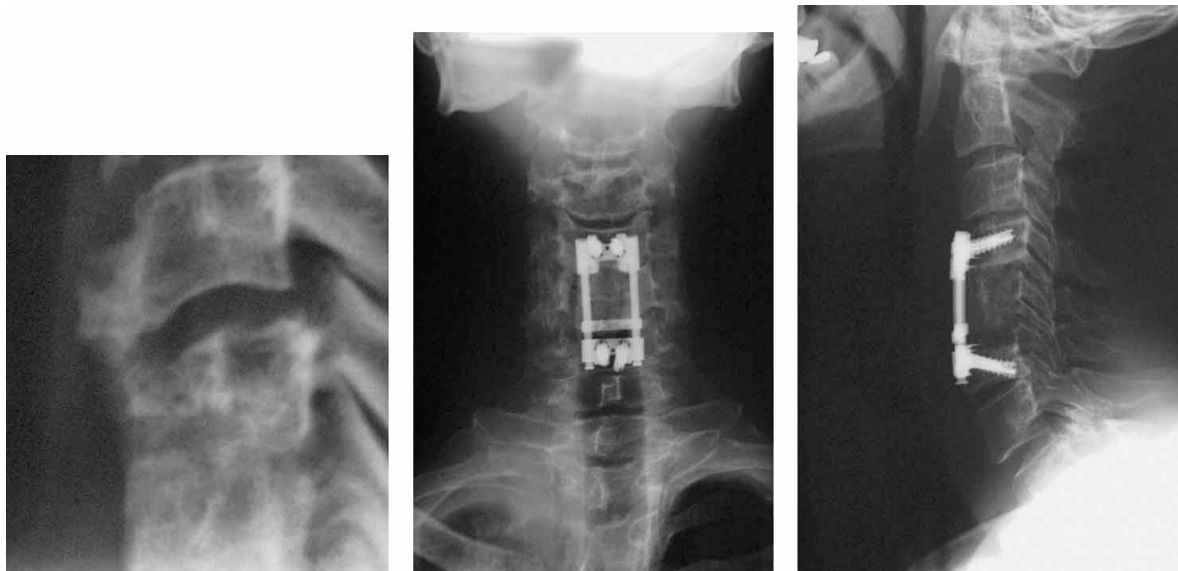


Fig. 4. Left: heterotopic ossification with ankylosis of suprajacent segment. Center and right: dynamic implants were placed in upside-down position aiming to prevent overlapping of adjacent segment with vertical rods following its axial telescoping.

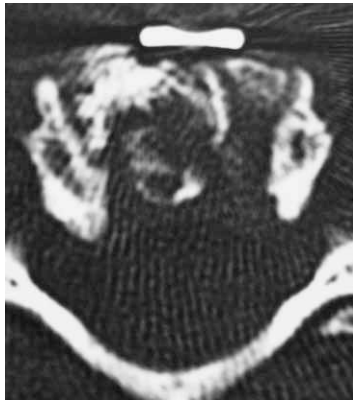

Fig. 5. Poor fit and small bone surface area of contact are surgeon-related factors responsible for non-union under H-plate

Analysis of three outcome measures in our study demonstrated that there was no difference between three studied groups. A huge number of papers about surgical treatment of spondylotic radiculomyelopathy deal with proper selection of implants, in contrary to negligible number of clinical studies about indications for surgery, thoroughness of decompression, or construction design^{5, 44–46}. Our results suggest that selection of implants is not crucial for the clinical outcome.

Wolff's law describes bone response to stress, and suggests that bone heals optimally when exposed to compressive loads. The usefulness of the anterior cervical plate is promotion of fusion by providing stability between the bone graft and donor vertebrae. However, an implant induces reduction of bone healing by enhancing loads under plate, which may result in non-union. Brodke and colleagues showed that in conditions simulating graft subsidence load sharing ratio is more than 4 times better in the dynamic implant group than in the plate group⁴⁷. Tye and colleagues showed that in the immediate weeks following instrument-assisted ACF fusion segment subsides or decreases in the length⁴⁸. In the dynamic group of our study almost all subsidence occurred in the first two days following surgery. Three factors directly affect the incidence and extent of subsidence: 1. the closeness of fit of the bone graft in the vertebral body mortise, 2. the surface area of contact between the bone graft and vertebral body, and 3. the quality of contact surfaces. There is a proverbial »race« between the failure of the implant and the acquisition of bony fusion. The capability of an anterior cervical plate to stabilize the spine after three-level corpectomy was significantly reduced with fatigue loading⁴⁹. Panjabi et al.⁵⁰ showed that there is an excessive screw-vertebra motion caused by fatigue at the lower end of the three-level corpectomy model. In our study, six week follow-up X-rays of patients with the 3rd generation dynamic implants showed a lower frequency of visible endplate-bone graft interface at the end of repair stage of bone healing process. These results suggest that normal settling is faster and early bone healing process better with dynamic implants. Unfortunately, we did not plan our study as a prospective observational co-

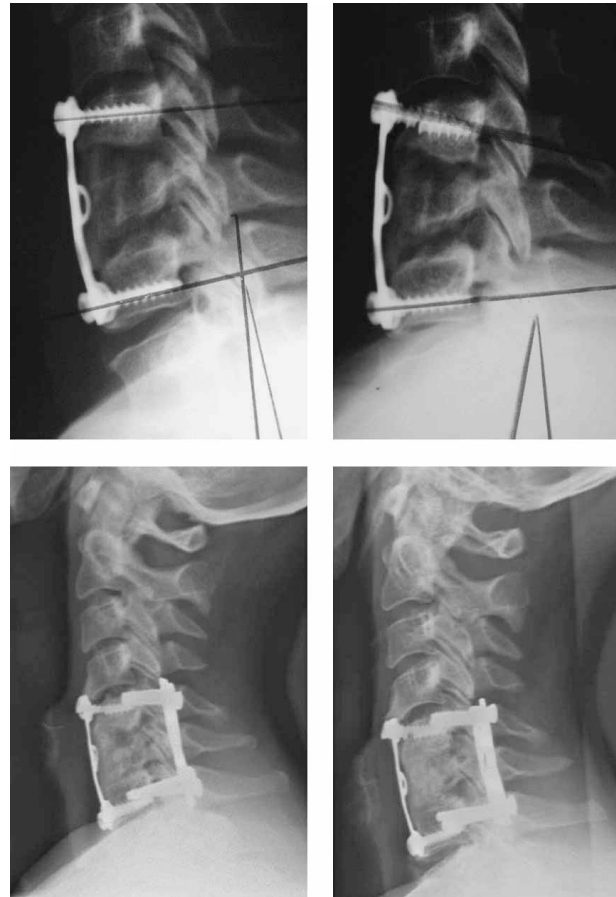


Fig. 6. X ray of the patient with non-union following H plate fixation that underwent additional fixation 7 month after initial surgery. Upper-left: 6-week follow-up. Upper-right: 6-month follow-up showing upper screw breakage. Lower left: 3-months following redo partial fusion was noticed. Lower right: 6-months following redo complete fusion occurred.

hort study, and we can not correlate early radiological findings with the clinical course.

In our study, the patient who needed a posterior redo, surgeon-related factors of a poor fit and small bone graft surface area of contact were probably responsible for non-union (Figure 5 right). Rotational dynamization of the H-plate was insufficient to allow excessive need for settling caused by poor fit and small surface area of contact. After an anterior cervical plate is applied with the graft under compression, the graft force increases in extension and decreases in flexion⁵¹ which is opposite to DOC system that offers essentially no resistance to vertical movement. Resistive strength of the endplate-subhondral bone is estimated to be 200 N. This limit was approached with 5 to 10 degrees of extension. The loads required to cause endplate bone failure are approached rapidly within the degrees of motion occurring in most available cervical orthoses. The application of an anterior cervical plate with suboptimal bone graft creates supraphysiologic loading in extension, which is a possible explanation of failure in our patient.

One third of our patients with supradjacent segment heterotopic ossification had dynamic fixation, which led to ankylosis in two patients. Ankylosis was also recorded in one patient.

Vertical rods axial telescoping is allowed in upper platform and where implant does not overlap supradjacent segment following dynamization. Overlapping of the disk was connected with heterotopic ossification and ankylosis. Delamarter was the single author that reported adjacent level impingement⁵². In the last ten patients of the trial group, dynamic implant was placed in the upside-down position which prevented overlapping of the adjacent segment. (Figure 4 center and right)

Clinical implication of our study is that selection of the internal fixation device must not be the main concern of the surgeon in decision making process. Three patients in the NAF group with dislocated segment of the graft with transitory dysphagia in one of them and the

two pseudarthrosis in the H-plate group, suggest that implant can be recommended in all decompressed patients with selection of dynamic implants for two and more level decompression. The reluctance of surgeons to use a new design of cervical plate can not be excused with explanation of saving money for the health care delivery system.

Our next step should be a study in which possible differences in speed of natural settling and bone healing process will be compared both clinically and radiologically.

Acknowledgement

The Croatian Ministry of Science and Technology (grant No. 0062076 to M. Stančić) financially supported this study. Part of these results will be presented at The Fourth Congress of the Croatian Neurosurgical Society.

REFERENCES

1. YOUNG WF, Am Fam Physican, 62 (2000) 1064. — 2. PALLIS C, JONES AM, SPILLANE JD, Brain, 77 (1954) 274. — 3. CLARK E, ROBINSON PK, Brain, 79 (1956) 483. — 4. FOUYAS IP, STATHAM PFX, SANDERCOCK PAG, Spine, 27 (2002) 736. — 5. FAGER CA, Lahey Clin Found Bull, 18 (1969) 99. — 6. CLOWARD RB, J Neurosurg, 15 (1958) 602. — 7. SMITH GW, ROBINSON RA, J Bone Joint Surg [Am], 40 (1958) 607. — 8. EDWARDS CC 2nd, RIEW KD, ANDERSON PA, HILIBRAND AS, VACCARO AF, Spine J, 3 (2003) 68. — 9. SAVOLAINEN S, RINNE J, HERNESNIEMI J, Neurosurgery, 43 (1998) 51. — 10. DOWD G, WIRTH F, J Neurosurg, 90 (1999) 8. — 11. GEORGE B, GAUTHIER N, LOT G, Neurosurgery, 44 (1999) 81. — 12. BERTAGNOLI R, YUE JJ, PFEIFFER F, FENK-MAYER A, LAWRENCE JP, KERSHAW T, NANIEVA R, J Neurosurg Spine, 2 (2005) 403. — 13. KAUFMAN HH, JONES E, Neurosurgery, 24 (1989) 264. — 14. WIGFIELD CC, NELSON RJ, Spine, 26 (2001) 687. — 15. HEARY RF, SCHLENK RP, SACHTERI TA, BARONE D, BROTEA C, Neurosurgery, 50 (2002) 510. — 16. SAMARTZIS D, SHEN FH, GOLDBERG EJ, An HS, Spine, 30 (2005) 1756. — 17. THALGOTT JS, FRITTS K, GIUFFRE JM, TIMLIN M, Spine, 24 (1999) 1295. — 18. KURZ LT, GARFIN SR, BOOTH RE, Spine, 14 (1989) 1324. — 19. BANWART JC, ASHER MA, HASSANEIN RS, Spine, 20 (1995) 1055. — 20. BOHLER J, Z Orthop Ihre Grenzgeb, [in German] 103 (1967) 512. — 21. BALABHARDA RSV, KIM DH, ZHANG HY, Neurosurgery, 54 (2004) 1405. — 22. JUGOVAC I, BURGIĆ N, MIČOVIĆ V, RADOLOVIĆ-PRENC L, URAVIĆ M, GOLUBOVIĆ V, STANČIĆ M, Croat Med J, 43 (2003) 33. — 23. LJUBIČIĆ BISTROVIĆ I, LJUBIČIĆ Đ, EKL D, PENEZIĆ LJ, MOČENIĆ D, STANČIĆ M, Croat Med J, 43 (2002) 702. — 24. ODOM GL, FINNEY W, WOODHALL B, JAMA, 166 (1958) 23. — 25. NURICK S, Brain, 95 (1972) 87. — 26. JUREŠA V, IVANKOVIĆ D, VULETIĆ G, BABIĆ-BANASZAK A, SRČEK I, MASTILICA M, BUDAK A, Coll Antropol, 24 (2000) 69. — 27. HEE HT, WHITECLOUD TS, MYERS L, GAYNOR J, ROESCH W, RICCIARDI JE, Spine J, 1 (2001) 176. — 28. GREVITT M, KHAZIM R, WEBB J, MULHOLLAND R, SHEPPERD J, J Bone Joint Surg [Br], 79B (1997) 48. — 29. TRIBUS CB, CORTEEN DP, ZDEBLICK TA, Spine, 24 (1999) 860. — 30. KELLER RB, ATLAS SJ, Spine, 30 (2005) 847. — 31. EPSEIN NE, J Spinal Disord, 15 (2002) 221. — 32. EPSEIN NE, Spinal Cord, 41 (2003) 153. — 33. BOSE B, J Neurosurg, 98 (2003). — 34. STEINMETZ MP, WARBEL A, WHITFIELD M, BINGAMAN W, J Neurosurg Spine, 97 (2002) 330. — 35. EPSEIN NE, Spinal Cord, 41 (2003) 379. — 36. VACCARO AR, FALATYN SP, SCUDERI GJ, EISMONT FJ, MCGUIRE RA, SINGH K, GARFIN SR, J Spinal Disord, 11 (1998) 410. — 37. SAUNDERS RL, PIKUS HJ, BALL P, Spine, 23 (1998) 2455. — 38. FESSLER RG, STECK JC, GIOVINI MA, Neurosurgery, 43 (1998) 257. — 39. ELERAKY MA, LLANOS C, SONNTAG VK, J Neurosurg, 90 (1999) 35. — 40. MACDONALD RL, FEHLING MG, TATOR CH, LOZANO A, FLEMING JR, GENTILI F, BERNSTEIN M, WALLACE MC, TASKER RR, J Neurosurg, 86 (1997) 990. — 41. KLEIN GR, VACCARO AR, TODD JR, Spine, 25 (2000) 801. — 42. EPSEIN NE, J Spinal Disord, 13 (2000) 324. — 43. EPSEIN NE, J Spinal Disord Tech, 15 (2002) 221. — 44. TERESI LM, LUFKIN RB, REICHER MA, FOFFIT BJ, VINUELA FV, WILSON GM, BENTSON JR, HANAFEE WN, MRI imaging, Radiology, 164 (1987) 83. — 45. RIEW KD, MCCULLOCH JA, DELAMARTER RB, AN HS, AHN NU, Instr Course Lect, 52 (2003) 497. — 46. SINGH K, VACCARO AR, KIM J, LORENZ EP, LIM TH, AN HS, Spine, 29 (2004) 845. — 47. BRODKE DS, GOLLOGLY S, MOHR A, NGUYEN BK, DAILEY AT, BACHUS KN, Spine, 26 (2001) 1324. — 48. TYE GW, GRAHAM RS, BROADDUS WC, YOUNG HF, J Neurosurg, 97 (2002) 186. — 49. ISOMI T, PANJABI MM, WANG JL, VACCARO AR, GARFIN SR, PATEL T, Spine, 24 (1999) 2219. — 50. PANJABI MM, ISOMI T, WANG JL, Spine, 24 (1999) 2283. — 51. DIANGELO DJ, FOLEY KT, VOSSEL KA, RAMPERSAUND YR, JANSEN TH, Spine, 25 (2000) 783. — 52. DELAMARTER R, BAE H, Eurospine (Porto, Portugal: Poster #20, 2004).

M. Stančić

Department of Neurosurgery, University Hospital »Dubrava«, School of Medicine, University of Zagreb, Avenija Gojka Šuška bb, 10000 Zagreb, Croatia
e-mail: marin.stancic@zg.t-com.hr

USPOREDBA PREDNJE CERVİKALNE FUZIJE SA FUZIJOM POJAČANOM DINAMIČKIM IMPLANTANTOM

SAŽETAK

Cilj ovog istraživanja je usporediti prednju cervikalnu fuziju sa fuzijom pojačanom dinamičkim implantatom te s fuzijom kod koje je korištena tzv. H-ploča prve generacije. Pacijenti sa radikulopatijom i/ili mijelopatijom u kliničkoj slici uključeni su u prospektivnu kohortnu studiju. Klinički rezultati mjereni su prema Nurick, Odom i SF 36 skalama. Rotacija i translacija vijaka kao i kvaliteta fuzije (Tribus) ocjenjivana je na kontrolnim pregledima nakon šest tjedana i četiri godine. Neurodekompresija je učinjena kod 81 pacijenta (jedan nivo 45 pacijenata, dva nivoa dekompresije 26 pacijenata i dekompresija na više nivoa u 10 pacijenata), u razdoblju od siječnja 2001. do rujna 2003. 50 muških i 31 ženski pacijent podijeljeni su u tri grupe, ovisno o tipu provede fuzije. U prvoj skupini pacijenata korišten je dinamički implantat (33), u drugoj skupini fuzija je provedena s H-pločom (33), dok je kod 15 pacijenata provedena fuzija bez augmentacije. Nije bilo značajne razlike u kliničkom ishodu između navedenih grupa. Pomak implantata zabilježen je u obje grupe: aksijalni u grupi s dinamičkim implantatom (srednja translacija \pm SD = $2,67 \pm 0,79$ mm), i angularni u grupi s korištenom H-pločom (kut rotacije $7,2 \pm 3,04^\circ$). Fuzija nakon šest tjedana bila je značajno bolja u skupini s dinamičkim implantatima i skupini bez pojačanja implantatom, u usporedbi sa skupinom pacijenata kod kojih je korištena H-ploča. Dva pacijenta u potonjoj skupini razvila su pseudartrozu, sedam pacijenata u skupini s dinamičkim implantatom razvila su heterotopične osifikacije susjednog segmenta, dok je kod dvojice iz navedene skupine primjećena i dodatna ankiloza. Tri pacijenta u skupini s učinjenom fuzijom bez pojačanja imala su pomak koštanog presadka s prolaznom disfagijom kod jednog od njih. Naši rezultati upućuju na to da izbor implantata nije ključan za ishod kliničkog liječenja. Slijeganje sustava je moguće kod primjene oba fiksacijska sistema. Fuzija je brža i učinkovitija u skupini pacijenata s aksijalnim pomakom implantata.