

# Research Competitions (Oral Presentations)

## (Abstracts 1 to 18)

### 001 Basic Research Competition

Tomographic and immunohistochemical study on Onlay Grafts remodeling: iliac crest vs. calvarial bone

**Presenter:** Salata LA

*University of Sao Paulo, Ribeirao Preto, Brazil*

**Co-authors:** Faria PEP<sup>1</sup>, Pedrosa Jr WF<sup>2</sup>, Okamoto R<sup>1</sup>, Xavier SP<sup>2</sup>, Salata LA<sup>2</sup>

<sup>1</sup>University of State of Sao Paulo, Aracatuba, Brazil, <sup>2</sup>University of Sao Paulo, Ribeirao Preto, Brazil

**Background and aim:** The factors behind volume loss of onlay bone grafts are still controversial. The pattern of volume loss of bone grafts is hypothesized to be a consequence of the origin/microarchitecture of the donor site. The iliac crest and calvarial grafting are commonly used in implant surgery for bone augmentation. The objectives of this study are to correlate the degree of volume/density maintenance of autogenous bone grafts with the biomolecular events occurring in the grafts harvested from iliac crest and skull placed onlay.

**Materials and methods:** Sixty New Zealand White rabbits were used in the study, 30 were subjected to 10 × 10 × 3 mm iliac crest grafting in the mandible while the other 30 rabbits received the same size calvarial grafts. All the recipient beds were perforated. After graft fixation and flap suture all animals were submitted to coronal computed tomography (CT) of the mandible. Twelve animals (six iliac crest and six calvaria) were sacrificed, respectively, at 5, 7, 10, 20 and 60 days after surgery. A second CT was taken just before sacrifice. Histological slides were prepared from each experimental site for both immunohistochemical (osteopontin, osteocalcin, type I collagen, and VEGF antibodies) and histological analyses.

**Results:** The intra-group CT data showed increasing bone density in calvaria grafts from baseline values to 7, 10, 20 and 60 days postoperative ( $P < 0.05$ ) and increased graft volume from the baseline to 20 days ( $P < 0.05$ ). As to the iliac crest group, the volume decreased from the baseline to 20 and 60 days and 10 days for density parameter ( $P < 0.05$ ). When both groups were compared, the calvarial graft was related with higher bone density at 5, 7, 10, 20 and 60 days and increased volume at 10, 20 and 60 days ( $P < 0.05$ ) than iliac crest grafts. The findings on immuno-markers revealed that grafts revascularization was more effective in all periods in the calvarial group, as well as the process of bone deposition (type I collagen and osteopontin).

**Conclusion:** Compared with iliac crest, the calvarial graft demonstrates the ability to preserve bone volume and density via revascularization facilitation and higher rate of bone deposition.

### 002 Basic Research Competition

Histological study on the implant interface following flapless implantation

**Presenter:** Choi BH

*Wonju College of Medicine, Yonsei University, Wonju, Korea*

**Co-authors:** Choi BH, Jeong SM, Xuan F, Kim HR, Mo DY  
*Wonju College of Medicine, Yonsei University, Wonju, Korea*

**Background and aim:** While it has been shown that the exclusion of the mucoperiosteal flap can prevent postoperative bone resorption associated with flap elevation, there have only been a few studies on the peri-implant mucosa following flapless implant surgery. The purpose of this study was to compare the morphogenesis and vascularity of the peri-implant mucosa between flap and flapless implant surgeries by using a canine mandible model.

**Materials and methods:** In six mongrel dogs, bilateral, edentulated, flat alveolar ridges were created in the mandible. After 3 months of healing, two implants were placed in each side by either the flap or flapless procedure. After another healing period of 3 months, biopsies were obtained, prepared for light microscopy, and exposed to morphometric measurements.

**Results:** The height of the mucosa, the length of the junctional epithelium, the gingival index, the bleeding on probing, the probing depth, and the marginal bone loss were all significantly greater in the dogs that had the flap procedure than those that had the flapless procedure ( $P < 0.05$ ). The supracrestal connective tissue lateral to the implant was found to be more richly vascularized in the flapless group than in the flap group.

**Conclusion:** These results indicate that gingival inflammation, the height of junctional epithelium, and bone loss around non-submerged implants can be reduced when implants are placed without flap elevation. In addition, they suggest that the flapless procedure may increase the vascularity of the peri-implant mucosa.

### 003 Basic Research Competition

Effect of magnetic fields produced by neodymium magnet on osteoblast activity

**Presenter:** Leesungbok R

*Kyung Hee University School of Dentistry, Seoul, Korea*

**Co-authors:** Leesungbok R<sup>1</sup>, Cho YW<sup>1</sup>, Lee HS<sup>2</sup>, Ahn S<sup>1</sup>, Lee SW<sup>1</sup>

<sup>1</sup>Kyung Hee University School of Dentistry, Seoul, Korea, <sup>2</sup>Kangnung University, College of Dentistry, Kangnung City, Korea

**Background and aim:** To determine the effects of magnetic fields by comparing interaction between the osteoblast and titanium dental implant with a magnet (inserted in the Mag-Screw abutment.) using cell cultures and pocket cultures.

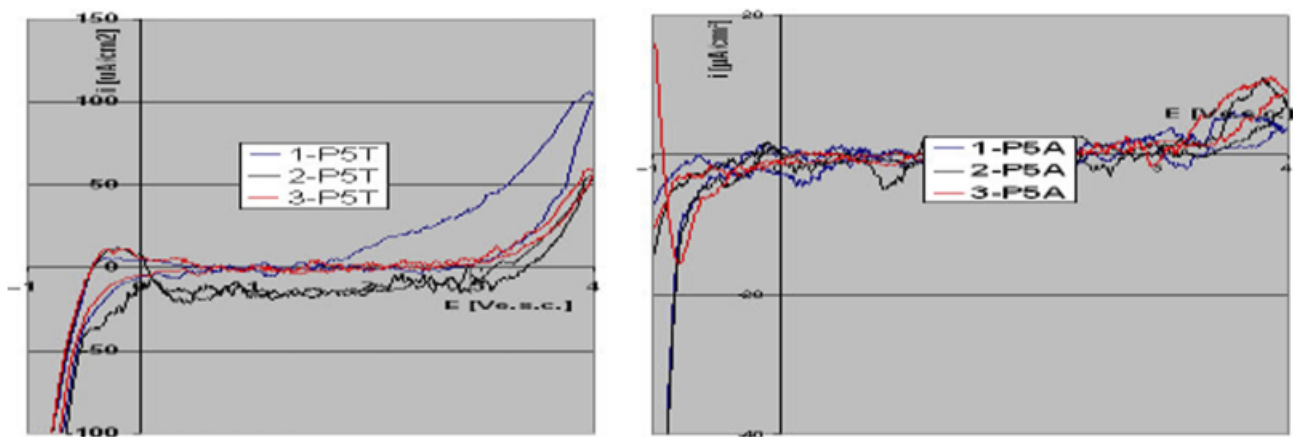
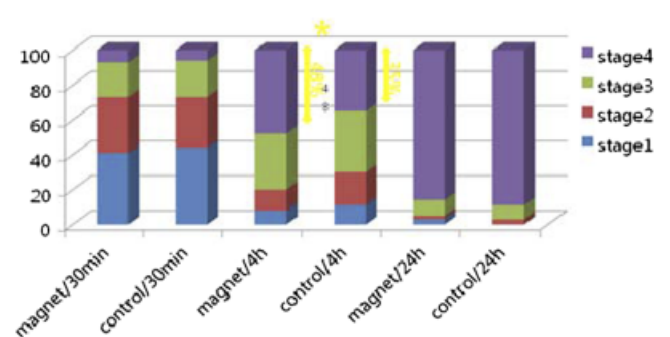




Fig. 1. Cyclic voltammograms recorded in Ringer solution at 27°C, 100 mV/s.

**Materials and methods:** Dental implants connected with a magnet-inserted abutment were used. Two methods were used to compare cell behavior: (1) A cell-spreading assay in which percentages of cells at four different stages of attachment were identified by scanning electron microscopy and quantified within 30-min, 4-h and 24-hour attachment periods. (2) Implants were placed in 'pocket culture' within gauze mesh sacs in contact with explanted calvarial bone fragments for 3-, 5-day, 2 and 4-week.

**Results:** The surfaces of dental implant connected with a Mag-Screw showed significantly enhanced rates of cell spreading in comparison with the others. Differential cell morphology was observed in both suspension assays and pocket cultures. In the latter, cells migrated onto all surfaces. Especially in the Mag-Screw group, at days 3 and 5, it was observed that migration and proliferation of cells from bone fragments on the implant surface occurred more actively. Multicellular layers with extracellular matrix (ECM) were present between the layers and on the material surfaces after 2 weeks. After 4 weeks, cell layers were more consolidated, and microstructures were obscured by layers of cells and ECM. Mineralized tissue was seen in association with ECM on entire surfaces of implants.



**Conclusion:** Based on these observations, it appears reasonable to suggest that magnetic fields promote the differentiation and maturation of osteoblasts by affecting the expression of adhesion proteins imbedded in the cell membrane (such as integrin) and may have a favorable effect on immediate-loading implant treatment by reducing the processing time for mineralization. In this study, the pocket method was a useful means of comparison of cell behavior within a three-dimensional osseous environment simulating an *in vivo* system and it provided information complementary to that obtained from cell culture assays.



## Past-like inorganic bone matrix – preclinical testing of a prototype preparation in the porcine calvaria

**Presenter: Busenlechner D**

*Dental School Vienna, Vienna, Austria*

**Co-authors: Busenlechner D, Fitzl C, Tangl S, Bernhart T, Gruber R, Watzek G**

*Department of Oral Surgery, Vienna, Austria*

**Background and aim:** Injectable bone substitutes satisfy the demand for minimal invasive surgery. The past-like inorganic bone matrix (PBM) was composed of Bio-Oss<sup>®</sup> with a particle size ranging from 250 to 500 µm and a hydrogel-carrier of carboxymethylcellulose (CMC) and collagen.

**Materials and methods:** We created six circumferential defects in the calvaria of 12 adult iberico pigs. The defects were filled which either PBM, Bio-Oss<sup>®</sup> of different particle size, the carrier alone, or left empty. After 6 and 12 weeks, undecalcified ground sections were prepared and subjected to histologic and histomorphometric analysis. To quantify the osteoconductive properties of PBM, 'bone volume per tissue volume' (BV/TV) in the defect area was determined. To determine the volume stability 'bone substitute volume per tissue volume' (BSV/TV) was measured.

**Results:** After 6 weeks, PBM particles in the centre of the defect were surrounded by fibrous connective tissue which was replaced by bone within the following weeks. BV/TV in the PBM group increased from 29.7% ± 12.7 after 6 weeks to 43.9% ± 14.9 after 12 weeks ( $P < 0.05$ ). BV/TV in groups containing Bio-Oss<sup>®</sup> of different particle size, the carrier, and the empty defects was similar to the results obtained with PBM. BSV/TV in the PBM group was stable over time, with 10.1% ± 9.0 and 16.5% ± 12.9, after 6 and 12 weeks, respectively ( $P < 0.05$ ). BSV/TV in the PBM group was comparable with results obtained with the Bio-Oss<sup>®</sup> particles of different size.

**Conclusion:** The results of this preclinical study showed that the past-like inorganic bone matrix is biocompatible, osteoconductive, and maintains the volume, similar to commercial Bio-Oss<sup>®</sup>. These data suggest that the osteoconductive properties of Bio-Oss<sup>®</sup> are maintained at the small particle size and in the presence of the carrier.

parameter that indicates the cell activity at the biomaterial surface. The analysis of cell morphology, including ultrastructure, is either performed by light microscopy, scanning electron microscopy and transmission electron microscopy. Often the cells and extracellular matrix is embedded in epoxy resin, cut and stained for subsequent analysis. Most of these techniques either involve laborious and time-consuming preparation and analytical stages. In cell cultures, the 2D *en face* morphology of cells is usually described by qualitative descriptions and semi-quantitative estimation, e.g. shape. Therefore, is urgently required to develop tools which permit rapid preparation and quantitative analysis of 3D morphology of cells on substrates.

**Materials and methods:** Here is presented a technique to characterize cell morphology that provides both qualitative and quantitative data. There are no requirements for flat or transparent substrates and several parameters can be selected to describe cell morphology. The interferometer microscope is routinely used to evaluate material surface topography with lateral/vertical resolution of 0.5 µm/0.1 nm. In this study, human monocytes were isolated from buffy coats and cell morphology (diameter/height/volume) was evaluated with different treatments. The monocytes ( $5 \times 10^5$  cells/ml) were seeded on glass slides and evaluated after 24 and 48 h. In selected experiments, the cells were treated with 100 ng/ml lipopolysaccharides (LPS) and polystyrene beads of 3 µm in diameter. After culture, cells were fixed with 2.5% of glutaraldehyde in 0.2 M sodium cacodylate buffer, pH 7.4, and dehydrated in a graded series of ethanol.

**Results:** Non-treated monocytes (control) exhibited a diameter (µm)/ height (µm)/ volume (µm<sup>3</sup>) (d/h/v) of 6.2/2.4/69.1 and 8.0/3.2/161.2 after 24 and 48 h, respectively. LPS-treated monocytes exhibited a d/h/v of 7.6/2.0/88.7 (24 h) and 11.0/0.8/62.2 (48 h). The monocytes treated with polystyrene beads (3 µm) exhibited a d/h/v of 15.6/6.1/1564.3 µm and 51.1/12.0/28,780.0 after 24 and 48 h, respectively.

**Conclusion:** The present technique provides a quantitative analysis of cell morphology high resolution, low cost of sample preparation and fast acquiring time. The technique offers numerous possibilities for the evaluation of cell behaviour on implant surfaces with different properties as well as the effect on cells of biological constituents.

## A novel technique for quantification of cells on material substrates

**Presenter: Meirelles L**

*Institute of Odontology, Gothenburg, Sweden*

**Co-authors: Meirelles L<sup>1</sup>, Almqvist S<sup>2</sup>, Johansson A<sup>3</sup>, Thomsen P<sup>3</sup>**

<sup>1</sup>Department of Prosthetic Dentistry/Dental Materials Science, Sahlgrenska Academy at Gothenburg University, Gothenburg, Sweden, <sup>2</sup>Mölnlycke Health Care AB, Gothenburg, Sweden, <sup>3</sup>Department of Biomaterials, Sahlgrenska Academy at Gothenburg University, Gothenburg, Sweden

**Background and aim:** Interactions between cells and materials are determined by surface properties. Cell morphology is one

## Evidence of revascularization and cell colonization of anorganic bovine bone

**Presenter: Galindo-Moreno P**

*University of Granada, Granada, Spain*

**Co-authors: Galindo-Moreno P<sup>1</sup>, Padial-Molina M<sup>1</sup>, Avila G<sup>2</sup>, Fernandez-Jimenez A<sup>1</sup>, Wang H-L<sup>2</sup>, O'Valle F<sup>1</sup>**

<sup>1</sup>University of Granada, Granada, Spain, <sup>2</sup>University of Michigan Ann Arbor, USA

**Background and aim:** It has been suggested that deproteinized cancellous bovine bone can induce new bone formation through osteoinductive mechanisms. However, there is little published information on the microvessel density in sinus augmentation, nor have there been many previous publications of morphological

evidence of vessels or cells into ABB particles. The aims of this study were to evaluate vascular and cellular colonization of anorganic bovine bone (ABB) used in maxillary sinus grafting after 6 months of wound healing.

**Materials and materials:** Fifty-four maxillary sinus augmentations with delayed implant placement in 35 consecutive patients were performed. Six months later, bone core biopsies were obtained for histological, histomorphometric, immunohistochemical and ultrastructural analysis.

**Results:** Implant survival rate was found to be 100% at 24 months after loading. Morphometric study showed average values of  $42.94 \pm 15.2\%$  of connective tissue,  $43.52 \pm 16.5\%$  of vital bone, and  $38.52 \pm 25.1\%$  of ABB particles in our samples. Presence of vessels inside ABB particles was found in a total of 46.3% of biopsies. Cells colonizing some ABB lacunae were observed in 25.9% of the samples. ABB particles revascularization was inversely related to age ( $\rho = -0.590$ ,  $P < 0.001$ , Spearman's test), and directly with osteoclast number per  $\text{mm}^2$  ( $\rho = 0.441$ ,  $P = 0.001$ , Spearman's test). There was no relationship between the presence of periodontitis or tobacco/alcohol consumption and ABB revascularization. The number of CD34-positive vessels was  $97.68 \pm 58.6/\text{mm}^2$  in grafted tissue. Osteopontin expression was primarily detected in the interstitial boundaries of bone with ABB particles and inside osteocyte lacunae and bone canaliculi, without expression in the trabecular bone or the interstitium.

**Conclusion:** Revascularization and cell colonization of ABB were histologically validated. In a significant number of samples, xenogenic graft particles are revascularized with microvessels and colonized with cells and new bone in repair and regeneration process in sinus augmentation with the proposed composite bone graft.

#### 007 Basic Research Competition

### Effect of diabetes on WNT protein signalling during the guided bone regeneration healing process

**Presenter: Retzeppi M**

Periodontology Unit, UCL Eastman Dental Institute, London, UK

**Co-authors: Retzeppi M, Donos N**

Periodontology Unit, UCL Eastman Dental Institute, London, UK

**Background and aim:** Experimental diabetes may compromise the initial stages of the osseous healing process following Guided Bone Regeneration (GBR), although the implicated pathogenetic mechanisms remain largely unknown. The WNT family of proteins have an essential role in regulating bone formation by controlling mesenchymal stem cell proliferation and osteoblast differentiation, proliferation, survival and function during skeletal embryonic development and throughout adult life. To explore on a gene expression level the molecular pathways implicated in the impaired osseous healing process following GBR application in the presence of uncontrolled and insulin controlled diabetes.

**Materials and methods:** Eighteen Wistar male rats were allocated in three experimental groups: (1) streptozotocin -

induced experimental diabetes; (2) insulin -controlled diabetes; (3) healthy controls. Critical size calvarial defects were created in each parietal bone and treated with intracranial and extracranial placement of ePTFE membranes. Subgroups of three animals from each experimental group were sacrificed following healing periods of 7 and 15 days and tissue samples were harvested from within the defects. Total RNA was isolated from the tissue samples and hybridised to Affymetrix 230 GeneChips. Differential gene expression between experimental groups was statistically tested, using the Linear Models Bioconductor test. Gene ontology analysis was conducted using GenMAPP for identification of global biological trends in gene expression data.

**Results:** At 7 days of healing, the *negative regulation of the Wnt receptor family* was overexpressed in the diabetic vs. the healthy group. This was evidenced by upregulation of genes encoding several antagonists of the WNT family of proteins, including secreted Frizzles proteins (*Frzb*), Dkkopf proteins (*Dkk3*) and low-density lipoprotein receptor protein 4 (*Lrp4*). At 15 days of healing, the *positive regulation of the Wnt receptor signalling pathway* presented downregulated in the diabetic vs. the healthy group. This was evidenced by downregulation of genes encoding complement factor B (*cfb*), casein kinase 2, beta polypeptide (*csnk2b*), dimethylarginine dimethylaminohydrolase 2 (*ddah2*), mouse MutS-like protein (*msh5*) and ng23 protein (*Ng23*). No differences in terms of the gene expression pattern were observed between the healthy and controlled diabetic groups.

**Conclusion:** Downregulation of the WNT signalling pathway may constitute a plausible molecular link between uncontrolled experimental diabetes and impaired osteogenesis during the initial stages of intramembranous bone formation following GBR application.

#### 008 Basic Research Competition

Soft tissue augmentation by the use of collagen-based matrices: an experimental comparative study in the dog mandible

**Presenter: Thoma DS**

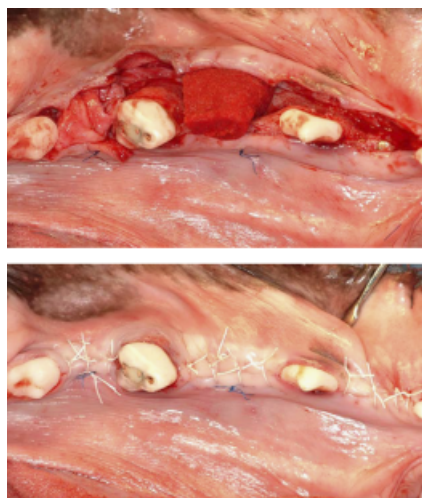
University of Zurich, Zurich, Switzerland

**Co-authors: Thoma DS<sup>1</sup>, Jung RE<sup>1</sup>, Schneider D<sup>1</sup>, Ender A<sup>3</sup>, Görlach C<sup>4</sup>, Übersax L<sup>4</sup>, Cochran DL<sup>2</sup>, Hämmerle CH<sup>1</sup>**

<sup>1</sup>Clinic For Fixed and Removable Prosthodontics and Dental Material Science, Zurich, Switzerland, <sup>2</sup>Department of Periodontics, UTHSCSA, San Antonio, U SA, <sup>3</sup>Department of Preventive Dentistry, Cariology, and Periodontology, Zurich, Switzerland, <sup>4</sup>Geistlich Biomaterials, Wolhusen, Switzerland

**Background and aim:** The aim of the present study was to test whether or not soft tissue augmentation with a newly developed collagen matrix (CM) leads to volume gain in chronic ridge defects similar to those obtained by an autogenous subepithelial connective tissue graft (SCTG).





Following extraction of all mandibular P2, P4, the distal root of M1, and root canal treatment of the mesial root of M1, chronic ridge defects were prepared in all extraction sites of six American foxhounds. Two months later, soft tissue volume augmentation was performed by randomly allocating three treatment modalities to the defects (CM, SCTG, and a sham-operated control [SO]). Impressions were taken before augmentation (baseline), after augmentation (post-op), at 10, 28, 56, and 84 days and casts obtained. The animals were sacrificed at 28 days ( $n=3$ ), or 84 days ( $n=3$ ). For the evaluation of the dimensional changes, the casts were optically scanned with a 3D camera and the images digitally analyzed. A defined region of interest was measured in all sites and the volume differences between the time-points calculated according to the formula  $[\Delta d \text{ (mm)} = \Delta vol \text{ (mm}^3\text{)} / \text{area (mm}^2\text{)}]$ .

**Results:** No soft tissue complications occurred throughout the entire study period. The mean volume increase before and after surgery amounted to 2.5 mm (CM), 2.4 mm (SCTG), and 1.7 mm (SO). A decrease in volume between post-op and 10 days was observed in all groups. At 28 days, the mean volume differences to baseline measured a gain of 0.7 mm (CM), 0.9 mm (SCTG), and 0.6 mm (SO). The greatest mean difference between 84 days and baseline were observed for the CM group (gain of 1.1 mm), followed by the SO group (0.6 mm), and the SCTG group (0.5 mm). The mean shrinkage between 10 days and 84 days was 77.3% (SCTG), 62.4% (SO) with the least shrinkage for the CM group (40.8%).

**Conclusion:** The tested collagen matrix revealed superiority over the SCTG group and SO group at 10, 56 and 84 days with respect to gain in soft tissue volume. A gain in soft tissue volume was observed for the CM group between 28 and 84 days, whereas the two other groups showed a decrease. The CM group revealed the greatest amount of regenerated soft tissue at 84 days compared with the other treatment modalities. The experimental collagen sponge may represent a viable treatment alternative to autogenous soft tissue grafts in the future.

## Bone regeneration using a synthetic matrix containing enamel matrix derivate

**Presenter: Schneider D**

University of Zurich, Zürich, Switzerland

Co-authors: Schneider D<sup>1</sup>, Weber F<sup>2</sup>, Hämmerle C<sup>1</sup>, Jung R<sup>1</sup>

<sup>1</sup>Department of Fixed and Removable Prosthodontics and Dental

Material Science, University of Zurich, Zürich, Switzerland,

<sup>2</sup>Department of Cranio-Maxillofacial Surgery, Section Oral Biotechnology & Bioengineering, University Hospital Zurich, Zürich, Switzerland

**Background and aim:** The aim of the present study was to determine whether delivery of EMD via synthetic PEG-based hydrogels with and without RGD sequences enhances bone formation *in vivo*.

**Materials and methods:** In each of nine rabbits four titanium cylinders were screwed into slits in the perforated external cortical bones of their calvaria. The following four treatment modalities were randomly allocated: one of the four cylinders was left empty (control), the other three were filled with a combination of PEG matrix with HA/TCP granules and EMD in a concentration of 100 µg/ml (Test 1) or 500 µg/ml (Test 2) or 500 µg/ml and RGD peptide (Test 3). After 8 weeks the animals were sacrificed and ground sections were obtained for histological analysis. For statistical analysis ANOVA using the post hoc Scheffee test was applied ( $P < 0.05$ ).

**Results:** The histomorphometric analysis revealed a statistically higher area of bone regeneration in the EMD 500/RGD group ( $54.81 \pm 14.53\%$ ) compared with the control group ( $28.66 \pm 10.32\%$ ) and the EMD 500 group ( $31.24 \pm 14.09\%$ ) and non-significantly higher area compared with the EMD 100 group ( $38.22 \pm 10.35\%$ ). The percentage of mineralized bone showed no statistically significant differences among the four groups. The mean percentage of mineralized bone was  $13.57 \pm 3.33\%$  in the control group,  $14.19 \pm 5.8\%$  in the EMD 100 group (Test 1),  $11.69 \pm 5.93\%$  in the EMD 500 group (Test 2) and  $15.66 \pm 5.23\%$  in the EMD 500/RGD group (Test 3). No statistically significant difference regarding the bone to graft contact between the EMD 500 group ( $50.8 \pm 13.4\%$ ) and the EMD 500/RGD group ( $51.5 \pm 13.4\%$ ) was observed.

**Conclusion:** The combination of a polyethylene glycol (PEG) matrix containing enamel matrix protein (EMD) with HA/TCP granules had a limited effect on the formation of mineralized bone tissue in rabbit calvaria. The addition of RGD peptide to the PEG/EMD 500 combination increased the area of bone regeneration compared with the other treatment groups. Further studies are indicated to study a possible synergistic effect of EMD and RGD.

## Healing of bundle bone and immediate implant installation following tooth extractions

**Presenter: Cardaropoli G**

*UMDNJ, New York, USA*

**Co-authors:** Cardaropoli G<sup>1</sup>, Monticelli F<sup>2</sup>, Osorio R<sup>3</sup>, Toledano M<sup>3</sup>, Pisani Proeca J<sup>3</sup>, Thomsen P<sup>4</sup>, Froum S<sup>5</sup>

<sup>1</sup>UMDNJ, Newark, USA, <sup>2</sup>University of Zaragoza, Huesca, Spain,

<sup>3</sup>University of Granada, Granada, Spain, <sup>4</sup>University of Goteborg

Sweden Sweden, <sup>5</sup>New York University, New York, NY, USA

**Background and aim:** Several studies showed that marked hard tissue alterations occurred following tooth extractions (Schroop et al., 2003 and Araújo and Lindhe, 2005). It was demonstrated that immediate implant installation do not prevent the buccal bone loss, moreover, it was claimed that the collapse of the ridge is due to the resorption of bundle bone following tooth extraction (Botticelli et al., 2004, Araújo et al., 2005, 2006). In all these studies surgical preparation of the alveolus (implant site) was performed, the flap was open, however, the percentages of bundle bone was never measured to support the hypothesis. The aim of the investigation: was to study the healing following tooth extraction and immediate implant installation using a root shape implants with and without the preparation of the recipient site.

**Materials and methods:** In the current experiment, eight beagle dogs were used. The mandibular premolars were extracted. In one side of the mandible immediate implant installation ( $n = 16$ ) ( $3.3 \times 9$  mm CV<sup>®</sup> Exacta Dental Implant, Italy) was performed without preparation of the recipient site (test) in the contralateral side the implants ( $n = 16$ ) were inserted following the preparation of the recipient site (control). After 3 months of healing, the animals were sacrificed and the mandible were processed for ground section in buccal lingual direction. Histometric measurements were performed by a blind investigator.

**Results:** A buccal bone loss of 1.78 mm was recorded (test) and 1.95 in the (control). The bone implant contact was 68% and 65%. The percentage of bundle in direct contact with the implant surface was 35% in the test group and 5% in the control group ( $P < 0.05$ ).

**Conclusion:** The results of the present study revealed for the first time, that after 3 months of healing bundle bone was in direct contact with the implant surface (test), therefore the biological mechanisms of bone loss in not related to the bundle bone.

## Implants in periodontally compromised partially edentulous patients: long-term (10 year) results of a three arms blinded prospective study

**Presenter: Rocuzzo M**

*Private Practice, Torino, Italy*

**Co-authors:** Rocuzzo M<sup>1</sup>, Aglietta M<sup>2</sup>, Blasi A<sup>2</sup>, Bonino F<sup>1</sup>

<sup>1</sup>Private Practice, Torino, Italy, <sup>2</sup>Department of Periodontology,

University of Bern, Bern, Switzerland, <sup>3</sup>Department of Periodontology,

University Federico II, Naples, Italy

**Background and aim:** It is frequently debated whether implant treatment in patients with periodontitis is associated with an

increased risk of biological complications. The 2006 EAO Consensus Conference concluded that prospective-controlled clinical trials, involving a sufficient number of patients, are needed before final conclusions can be drawn about this topic. The aim of this study is to compare the 10-year implant outcomes of patients, who have been treated for periodontitis, with periodontally healthy subjects.

**Materials and methods:** At baseline, full -mouth plaque score; full mouth bleeding score; number of missing teeth; pocket depths were collected on 112 patients. Patients were divided in two groups, based on diagnosis. Group A: periodontally healthy patients; group B: periodontally compromised patients. Moreover, patients of group B received a score on the basis of the number and depth of periodontal pockets according to the following formula: (No. of pockets 5–7 mm) + 2 (no. of pockets > 8 mm). Thereafter, patients scoring < 25 were placed in group B1 (moderate periodontitis), those scoring > 25 in the group B2 (severe periodontitis). Periodontal and non-submerged implant surgery (TPS implants, Institut Straumann AG, Waldenburg, Switzerland) were performed only after assurance of excellent compliance (FMPS < 25%; FMBS < 25%). Supporting periodontal therapy (SPT) including motivation, reinstruction, instrumentation and treatment of re-infected sites was offered, throughout the entire period of observation, as needed.

**Results:** After 10 years, clinical and radiographic parameters were compared with the baseline values. Moreover, mPI, BOP and sites with marginal recession > 3 mm were registered at four aspects per implant. Eleven patients were lost at follow-up. The final analysis was performed on 101 subjects: 28 (group A), 37 (group B1) and 36 (group B2). Mean bone loss was equal to 0.75 (± 0.88) mm in group A, 1.14 (± 1.11) mm in group B1 and 0.98 (± 1.22) mm in group B2. On a patient based analysis, implant survival rate was 97.9%, 91.4% and 91.5% for all implants. No early failure or implant fracture was registered. In group A, B1 and B2, respectively, 4.7%, 11.2% and 15.1% of sites had bone loss > 3 mm. Difference between groups A and B2 was statistically significant ( $P < 0.05$ ). Non-ideal SPT was correlated with higher risk of implant loss in both group B1 and B2 ( $P < 0.05$ ).

**Conclusion:** Patients with a history of periodontitis should be informed that they are more at risk for peri-implant disease. Moreover, periodontally compromised patients, who do not completely adhere to the SPT, have a higher incidence of implant failure rate.

## Histological analyses of biopsies harvested 11 years after maxillary sinus floor augmentation with an 80:20 mixture of deproteinized bovine and autogenous bone

**Presenter: Mordenfeld A**

*Folk tandvården i Gävleborg AB, Gävle, Sweden*

**Co-authors:** Mordenfeld A<sup>1</sup>, Hallman M<sup>1</sup>, Johansson C<sup>2</sup>, Albrektsson T<sup>2</sup>

<sup>1</sup>Department of Oral & Maxillofacial Surgery, Folk tandvården i

Gävleborg AB, Gävle City, Sweden, <sup>2</sup>Department of Biomaterials/

Handicap Research, Institute for Surgical Sciences, Göteborg, Sweden

**Background and aim:** Deproteinized bovine bone (DPBB) has been extensively used with excellent results for sinus floor

augmentation in patients with severely resorbed alveolar ridges in the posterior maxilla. There is a controversy in the literature whether DPBB is resorbable or not. The purpose of the present study was to morphometrically evaluate the long-term tissue response to DPBB particles and to compare particle size after 6 months and 11 years, in the same patients, in order to determine possible resorption.

**Materials and methods:** Twenty consecutive patients (14 women, and six men) with a mean age of 62 years (range; 48–69 years) with severe atrophy of the posterior maxilla were included in this study. Thirty maxillary sinuses which had < 5 mm subantral alveolar bone were augmented with a mixture of 80% DPBB and 20% autogenous bone. Eleven years (mean 11.5 years) after augmentation 11 patients approved to have a biopsy taken from the grafted area. The following morphometrical measurements were performed on undecalcified cut and ground sections, in the light microscope: Total bone area in percentage, total area of the DPBB, total area of marrow space, the degree of DPBB-bone contact (% of total surface length for each particle), the length of the DPBB particles and the area of the DPBB particles. The length and the area of the particles were compared with samples harvested from the same patients at 6 months (nine samples) and particles from the manufacturer.

**Results:** The specimens (11 years) were occupied by 44.7% ± 16.9% lamellar bone, 38.0% ± 16.9% marrow space and 17.3% ± 13.2% DPBB. The degree of DPBB to bone contact was 61.5% ± 34.0%. The size of the particles varied considerably in all specimens (Figs 1 and 2). The mean length and area of the particles from the manufacturer, at 6 months and at 11 years are presented in Table 1.

Table 1. Length and area of the DPBB particles

Time of biopsy	Number of particles	Mean length (mm)	Mean area (mm <sup>2</sup> )
0 = from manufacturer	139	0.34 ± 0.18	0.065 ± 0.060
6 months (n = 9)	163	0.30 ± 0.24	0.061 ± 0.055
11 years (n = 10)	118 (length)/ 150(area)	0.34 ± 0.22	0.063 ± 0.051

There were no statistically significant differences between the length and area of the particles after 11 years compared with those measured after 6 months or particles from the manufacturer.

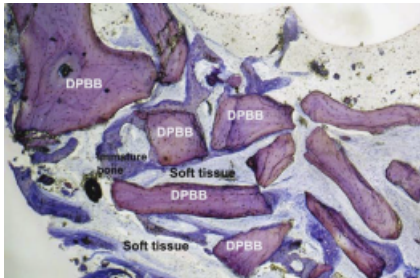

Fig. 1. Six months biopsy.

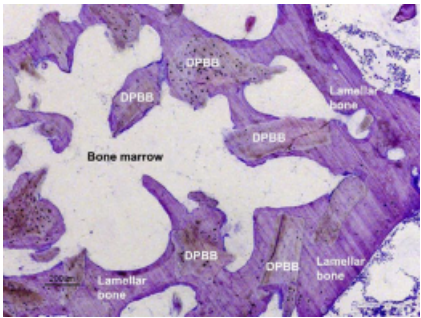


Fig. 2. Eleven years biopsy.

**Conclusion:** In this study of sinus floor augmentation, DPBB particles were found to be well integrated in bone, showing no obvious signs of resorption after 11 years.

013

Clinical Research Competition

Vertical ridge augmentation of the atrophic posterior mandible with inlay grafts: bone from the iliac crest vs. bovine anorganic bone. Results up to 1 year after loading from a randomized controlled clinical trial

**Presenter:** Felice P  
*University of Bologna, Bologna, Italy*  
**Co-authors:** Felice P<sup>1</sup>, Esposito M<sup>2</sup>, Iezzi G<sup>3</sup>, Piattelli A<sup>3</sup>, Lizio G<sup>1</sup>, Marchetti C<sup>1</sup>

<sup>1</sup>University of Bologna, Bologna, Italy, <sup>2</sup>University of Manchester, Manchester, U K, <sup>3</sup>University of Chieti-Pescara, Chieti, Italy

**Background and aim:** To compare inlay grafting procedures performed bilaterally in posterior atrophic mandibles for implant-borne prosthetic rehabilitation, using autologous iliac bone bloc and inorganic bovine bone bloc (Bio-Oss); histomorphometry of samples obtained at implant placement was performed; prosthetic and implant outcomes were evaluated up to 1 year since implant loading.

**Materials and methods:** Ten partially edentulous patients with bilateral mandibular vertical bone height of 5–7 mm posteriorly to the mental foramen, insufficient for implant insertion, underwent inlay bone grafting techniques on both sides. After elevation of a mucoperiosteal flap posterior to the mental foramina, a horizontal osteotomy approximately 3–4 mm above the mandibular canal and two oblique cuts were performed with piezosurgery. The osteotomized segment obtained was then raised in a coronal direction sparing the lingual periosteum. The iliac bone graft on a one side and inorganic bovine bone bloc (Bio-Oss) contralaterally (according to randomization) were fitted between the raised fragment and the basal bone, fixed with titanium miniplates and miniscrews, and covered with a resorbable collagen membrane. After 4 months implants were inserted and samples trephined for histomorphometry; provisional and definitive prostheses were delivered after further 4 and 8 months, respectively.

**Results:** Histomorphometry showed more residual graft in the Bio-Oss group (10–13%); no significant differences were noted in failures and complications between the two groups. The graft procedure failed in one patient of the autogenous group, so two implants could not be placed, whereas in the Bio-Oss group one implant and its prosthesis failed after loading. Only a

peri-implantitis occurred at one implant in the autogenous group. The peri-implant marginal bone loss up to 1 year of loading (0.82 and 0.59 mm in autogenous and Bio-Oss groups, respectively) was significant in both groups, with no significance between the groups. **Conclusion:** Both procedures obtained good results, but the use of bovine blocs was less invasive and may be preferable than harvesting bone from iliac crest.

#### 014 Clinical Research Competition

Computer-guided implant placement: 3D planning software, fixed intraoral reference points and cad/cam technology. A clinical trial and an *in vitro* study

**Presenter:** Tahmaseb A

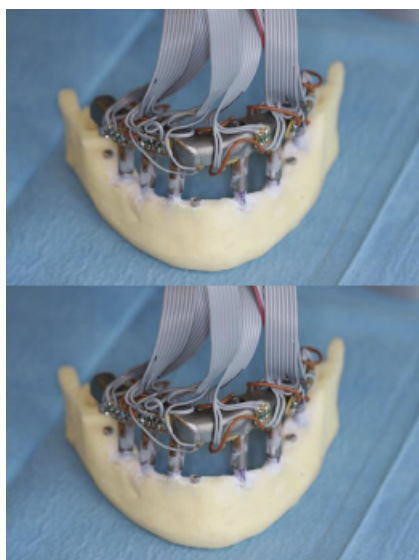
ACTA, Amsterdam, The Netherlands

**Co-authors:** Tahmaseb A, Wismeijer D

Acta Amsterdam, The Netherlands

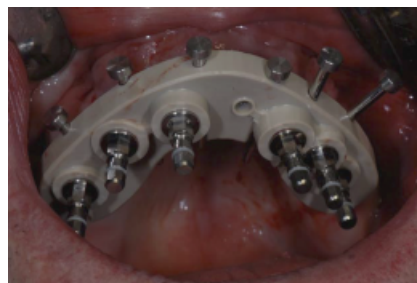
**Background and aim:** The aim of this article is to explain the use of computer-aided 3D-planning protocol in combination with pre-installed mini-implants and CAD/CAM-technology to restore fully edentulous patients. Mini-implants are used to fix the CT-setup during the CT-imaging and the surgical template during the surgery. The software allows us to plan the ideal implant placement digitally regarding both prosthetic and anatomic situations to design the final superstructure. The CAD-/CAM superstructure is produced digitally with a precise fit and is installed immediately after the surgery. The study has been designed in an *in vitro* and a clinical trial.

**Materials and methods:**



A master cast of edentulous mandible was fabricated with barium-sulphate resin. After placement the mini-implants, a CB-CT-scan was executed. The images were imported into planning software and six implants were planned in the test model. The planning data were imported into the CAD/CAM designing software where the surgical guide and superstructures were designed and then fabricated by a milling centre. The implants were inserted using the surgical template, connected to the mini-implants. The measurements were done using four strain gauges per implant connection.

This can provide 3D analysis of fit. The same measurements were done on a milled structure, made on a copy of our test model after impression taking.



**Clinical trial:** Thirty patients with 33 edentulous jaws were treated according to the described protocol.

**Results:** The max. measured misfit of the milled structure on the model was 57  $\mu$ . The average misfit on X, Y and Z -axes was, respectively 36, 23 and 36  $\mu$ m with Sqrt (Som qu; ABS) of 55  $\mu$ m. After an evaluation period of 6–24 months, 196 implants out of 199 survived. The Ostell and Rx analysis confirmed the stability of the implants. All superstructures were successful. In one case, the lost implant was replaced using the original surgical guide attached to the remaining implants. The same superstructure was then attached. Even the implants with poor primary stability seem to osseointegrate probably because of intra-arch connection.

**Conclusion:** The structures made according to this fully digital approach showed a high level of precision. The strain gauge measurements and the optical scan analysis both supported, on a comparable way, the passive fit. There were no significantly differences between digital framework and the milled structure (impression-scan procedure). Based on our experience, this reference-based procedure is predictable when treating edentulous jaws with implants.

#### 015 Clinical Research Competition

Gel-pressure technique (GPT) for flapless transcrestal maxillary sinus floor elevation

**Presenter:** Pommer B

Medical University of Vienna, Vienna, Austria

**Co-authors:** Pommer B, Watzek G

Department of Oral Surgery, Medical University of Vienna, Vienna, Austria

**Background and aim:** Preliminary results on a novel surgical technique for flapless transcrestal maxillary sinus elevation using gel-pressure are presented.

**Materials and methods:** The gel-pressure technique was performed in 10 patients with deficient posterior maxillary ridges. Surgical templates were fabricated to facilitate puncture of the bony sinus floor without perforation of the adherent sinus membrane. After soft tissue punch and transcrestal osteotomy a radiopaque gel was administered through an injection nozzle to separate and elevate the Schneiderian membrane from the bony sinus floor until a total postoperative alveolar height of at least 13 mm was attained. Then the graft material and implants were placed.



**Results:** A total of 13 sinuses were elevated and 29 implants were placed. The mean height of elevation amounted  $9.1 \pm 2.1$  mm. Membrane perforation could be avoided successfully in all cases. One patient had to be reoperated due to a planning error. All planned implants could be inserted with adequate primary stability. Two implants (6.9%) failed to osseointegrate and were successfully replaced. Postoperative discomfort and swelling was minimal compared with sinus elevation via lateral osteotomy.

**Conclusion:** The gel-pressure technique for flapless transcrestal maxillary sinus floor elevation represents a minimally invasive method to increase bone volume in the resorbed posterior maxilla. The results of the present study indicate that this new surgical technique may reduce patient morbidity and extend the indication for transcrestal maxillary sinus floor elevation.

016	Clinical Research Competition
-----	-------------------------------

The implant-supported maxillary overdenture; a prospective study on four vs. six implants

**Presenter:** Slot W

*University Medical Center Groningen, Groningen, The Netherlands*

**Co-authors:** Slot W, Meijer H, Raghoobar G

*University Medical Center Groningen, Groningen, The Netherlands*

**Background and aim:** An overdenture supported by endosseous implants gives the opportunity to improve retention and stability. In case of insufficient bone a maxillary sinus floor elevation procedure is carried out. After a 3-months healing period the implants are inserted in the posterior areas of the maxilla. However, in case of sufficient bone in the anterior area of the maxilla it is possible to insert the implants without a bone augmentation procedure. There are a number of prospective studies on overdentures retained by implants in the anterior area of the maxilla. A clinical trial in which a different number of implants are compared, has not been published yet. The aim of the study is to compare four or six implants in the anterior area of the maxilla to support an overdenture during a 1-year follow-up period.

**Materials and methods:** Twenty fully edentulous patients with problems with retention and stability of the upper denture were selected for the study. All patients had sufficient bone to place the implants anterior region without augmentation of the sinus floor.

After randomization patients were assigned to:

Group 1: Four implants (ASTRA-Tech) of at least 10 mm length inserted in the anterior area or

Group 2: Six implants (ASTRA-Tech) of at least 10 mm length inserted in the anterior area and bicuspid area.

In each patient also four implants were placed in the interforaminal region of the mandible.

After 3 months of osseointegration, a bar-supported overdenture was constructed.

In this clinical trial the following items are evaluated: Implant survival, overdenture survival, peri-implant bone changes and patient satisfaction.

**Results:** After a functional period of one year implant and overdenture survival was 100% in both groups. The mean marginal bone resorption was 1.3 mm (SD 1.2 mm) in group 1 and 1.4 mm (SD 1.6 mm) in group 2. Patient satisfaction was measured with a general satisfaction score (from 1 to 10). General satisfaction improved from score 4 (pre-treatment) to score 9 (1 year) in both groups.

**Conclusion:** In this study, no significant differences could be detected between the two groups. For reason of cost-effectiveness, four bar-connected implants to support a maxillary overdenture is the method of choice.

017	Clinical Research Competition
-----	-------------------------------

Immediate vs. conventional single implant loading in the aesthetic zone: an 18 months randomized controlled trial

**Presenter:** Groningen

**Co-authors:** den Hartog L, Meijer H, Stellingsma K, Raghoobar G

*University Medical Center Groningen, Groningen, The Netherlands*

**Background and aim:** In implant literature, reports of well-designed controlled studies on immediate single implant loading in the anterior zone are scarce. Consequently, there is little evidence whether this approach would result in comparable – or even better – treatment outcomes than conventional loading. The aim of this randomized controlled trial was to compare an immediate single implant loading protocol with a conventional loading protocol thereby addressing aesthetic, radiographic and clinical outcome measures together with patient satisfaction.

**Materials and methods:** For this study, 61 consecutive patients (mean age 39.5 years, range 18–67) with a single missing tooth in the maxillary aesthetic zone were included. Each patient was randomly allocated to one of two study groups to receive an implant (Nobel Replace Groovy) that was either subjected to a 3 months load-free integration period (control group) or was restored within 24 h after implant placement (test group). After provisionalization, the implants were restored with a definitive full ceramic crown. Pre-operatively, 2 weeks, 6 months and 18 months after implant placement, clinical data were collected and standardized X-rays and photographs were taken. Patient satisfaction was explored using a self-administered questionnaire.

**Results:** During follow-up, one immediate implant failed to integrate, resulting in an implant survival rate of 96.6% for the immediately loaded implants vs. 100% for the conventional ones. After 18 months, a mean marginal bone resorption of  $0.92 \pm 0.8$  mm in the immediate group and  $0.98 \pm 0.8$  mm in the conventional group was found ( $P > 0.05$ ). Furthermore, no statistical significant differences were observed in Aesthetic Index, Papil index, Modified Plaque- and Bleeding Index, probing depth and patient satisfaction ( $P > 0.05$ ). In both groups, patients rated their general satisfaction with a mean score of 9.2 on a VAS-scale ranging from 0 to 10.

**Conclusion:** It was concluded from this study that immediate single implant loading in the maxillary aesthetic zone is a

reliable treatment strategy leading to outcomes comparable to a protocol of conventional integration.

## The effect of surface topography of screw-shaped titanium implants in humans on clinical and radiographic parameters: a 12 year prospective study

**Presenter:** Vroom M

*ACTA-University of Amsterdam, Amsterdam, The Netherlands*

**Co-authors:** Vroom M<sup>1</sup>, Sipos P<sup>1</sup>, de Lange G<sup>2</sup>, Grundemann L<sup>1</sup>, Timmerman M<sup>3</sup>, Loos B<sup>1</sup>, Van der Velden U<sup>1</sup>

<sup>1</sup>*Academic Centre for Dentistry Amsterdam (ACTA), University of Amsterdam, and VU University, Amsterdam, Department of Periodontology, Amsterdam, The Netherlands,* <sup>2</sup>*Centre for Oral Implantology and Periodontology, Amstelveen, The Netherlands,*

<sup>3</sup>*Practice for Periodontology and Implantology, Nijmegen, The Netherlands*

**Background and aim:** Although implants with a roughened surface are widely used today, little is known about the long-term effect of a roughened surface compared with the conventional machined surface on clinical and radiographic parameters. The purpose of this study is to investigate the long-term differences between rough (TiOblasted) titanium implants and smooth (machined/turned) surfaces with respect to marginal bone resorption and the peri-implant soft tissues within the same patient.

**Materials and methods:** In 20 fully edentulous patients, with severely resorbed mandibles, a total of 80 Astra Tech dental implants were placed in the mandible to support a bar construction with a full overdenture. In each patient, two smooth surfaced (machined) and two rough surfaced (TiOblast) implants were placed alternately. In two patients, during the abutment surgery, one machined implant showed insufficient osseointegration and was replaced. One implant showed an abutment fracture after 9 years and was kept as a sleeper. Clinical evaluation was carried out at base-line (prosthetic installation), 6 months, 1, 2, 3, 4, 5 and 12 years. Radiographic evaluation by using standardized individual filmholders was carried out at base-line (prosthetic installation), 6 months, 1, 5 and 12 years. The reproducibility of the examiners was tested. Furthermore the reproducibility of the filmholder devices was determined by using double base-line radiographs.

**Results:** From base-line up to 12 years no implant was lost. No significant differences were found between both implant surfaces concerning the clinical parameters such as plaque, calculus, bleeding and probing pocket depth. The mean (SD) marginal bone changes up to 12 years varied between  $-0.11$  and  $+0.01$  mm for the machined and  $-0.2$  and  $+0.01$  mm for the TiOblast implants. No significant difference in marginal bone loss was found between both implant surfaces.

**Conclusion:** We conclude that after 12 years follow-up, no differences could be assessed between the machined and TiOblasted implants, both for soft and hard tissue parameters.

**Acknowledgement:** This study was supported in part by Astra Tech AB, Mölndal, Sweden.



# Short Communications (Oral Presentations)

## (Abstracts 19 to 39)

019 | Short Oral Communications

Life quality after iliac crest bone graft harvesting over an anterior vs. posterior approach

**Presenter: Becker ST**

*Christian-Albrechts University of Kiel, Kiel, Germany*

**Co-authors: Becker ST, Warnke PH, Behrens E, Wiltfang J**

*Christian-Albrechts University, Kiel, Germany*

**Background and aim:** For larger augmentations before implant insertions the iliac crest is the standard source of bone grafting. This study assesses the life quality reduction after bone graft harvesting from the anterior and posterior ileum.

**Materials and methods:** A total of 97 patients who underwent corticocancellous iliac crest bone harvesting for augmentations of the jaws in the years 2004–2007 in the Department of Oral and Maxillofacial Surgery of the University Hospital Kiel were included. Their life quality was assessed with specially designed questionnaires.

**Results:** Pain levels were rated nearly equal on a visual analogue scale (1=no pain; 10=strongest pain). One week after bone harvesting from the anterior approach pain was rated 4.9 and 4.8 for posterior ( $P=0.89$ ). The corresponding values after six months were 1.4 and 1.6 ( $P=0.64$ ). The evaluation of the scars revealed 2.7 (anterior) and 3.0 ( $P=0.76$ ). Harvested bone volumes were 12 and 18 cm<sup>3</sup>. Eighty-one percent (anterior), respectively, 88% (posterior) of the patients would opt for the operation again.

**Conclusion:** Patients reported a noticeable reduction of life quality after elective bone graft harvesting for the donor site. Alternatives without the need to harvest bone would unburden the patients for that problem. Both approaches were rated similar, so that for smaller amounts of bone graft needed, the anterior and the posterior approach can be recommended, while the posterior approach is suitable for even larger amounts.

implant in a fresh extraction site. The implants which were used had a small diameter (3.25 mm) and a submerged healing.

**Materials and methods:** The experimental procedures were performed on five beagle dogs. The third premolar and first molar in both quadrants of the mandible were used. The distal roots of the selected teeth were removed. Implants were placed in the fresh extraction socket, the large peri-implant bone defect at the molar sites were grafted with a corticocancellous porcine bone (MP3, Osteobiol, Tecno, Coazze, Italy) and a collagen membrane (Evolution, Osteobiol). Two beagle dogs were sacrificed at 1 month and three beagle dogs at 3 months. The specimen of each implant site was dissected and processed for histologic and histomorphometric evaluations.

**Results:** Crestal bone resorption occurred during healing after tooth extraction and implant insertion in fresh extraction sockets. The granulation tissue, which was present in the early phase of healing (15 days), was at 1 and 3 months evaluations replaced with provisional matrix and woven bone. The buccal bone at the premolar sites showed a mean vertical bone resorption which was  $1.4 \pm 0.9$  mm, on the other hand the premolar sites which received the augmentation procedure showed a mean vertical resorption of  $0.2 \pm 1.4$  mm. The resorption of buccal bone walls was more pronounced at the premolar than at the molar sites, which received a guided bone regeneration procedure.

**Conclusion:** The buccal as well as the lingual bone walls were resorbed after tooth extraction and implant placement in fresh extraction sockets. Although, the use of small diameter implant (3.25 mm) in the beagle dog mandibular premolar sites showed a lower vertical bone resorption when compared with previous studies. Moreover, the molar sites, which received implants into extraction sockets and simultaneous augmentation procedures, showed a stability of buccal bone walls around the implants. It could be suggested that the corticocancellous porcine bone acted as osteoconductive biomaterial which prevented the buccal bone walls from resorbing.

020 | Short Oral Communications

Crestal bone remodeling around implants placed in fresh extraction sockets

**Presenter: Barone A**

*University of Genova, Camaiore, Italy*

**Co-authors: Barone A<sup>1</sup>, Calvo JL<sup>2</sup>, Quaranta A<sup>3</sup>, Covani U<sup>4</sup>**

<sup>1</sup>University of Genova, Camaiore, Italy, <sup>2</sup>University of Murcia, Murcia, Spain, <sup>3</sup>University of Roma, Rome, Italy, <sup>4</sup>University of Pisa, Pisa, Italy

**Background and aim:** It has been well established that tooth extraction will result in dimensional changes of the alveolar ridge with an apico-coronal as well as bucco-lingual remodelling of the involved area. A marked hard tissue alterations at the buccal aspect resulted in some marginal loss of integration. The aim of the present experimental study in a beagle dog model was to evaluate the bone remodelling that occurs following the placement of an

Peri-implant endosseous healing properties of dual acid-etched mini-implants with a nanometer-sized deposition of cap: a histological and histomorphometric human study

**Presenter:** Telleman G

*University Medical Center Groningen, Groningen, The Netherlands*

**Co-authors:** Telleman G<sup>1</sup>, Albrektsson T<sup>2</sup>, Hoffman M<sup>2</sup>, Johansson C<sup>2</sup>, Vissink A<sup>1</sup>, Meijer H<sup>1</sup>, Raghoobar G<sup>1</sup>

<sup>1</sup>Department of Oral & Maxillofacial Surgery, University Medical Center Groningen, University of Groningen, Groningen, The Netherlands, <sup>2</sup>Department of Biomaterials/Handicap Research, Institute for Clinical Sciences, Sahlgrenska Academy, University of Gothenburg, Gothenburg, Sweden

**Background and aim:** Surface modifications of endosseous implants are of growing interest from a perspective of improving osseointegration. A complex surface microtopography or surface roughness and, to a lesser extent, calcium phosphate deposits on an implant surface have been suggested to accelerate early peri-implant bone healing by increasing activation of platelets. The aim of this histological and histomorphometric study was to compare the early peri-implant endosseous healing properties of a dual acid-etched (DAE) surface (Osseotite<sup>®</sup>, Biomet 3i, Palm Beach Gardens, FL, USA) to a DAE-surface modified with nanometer-sized CaP particles (NanoTite<sup>™</sup>, Biomet 3i) in grafted and mature maxillary bone.

**Materials and methods:** Fifteen patients with insufficient retention of their upper denture related to a severely resorbed maxilla were included. The maxilla was reconstructed with autologous iliac crest bone grafts to enable insertion of dental implants in a second stage surgery. The iliac crest bone graft was fixated to the maxilla with (among other screws) two mini-implants, one with a DAE surface (control) and one with a DAE + CaP surface (test). Part of each mini-implant was in contact with grafted bone and a part extended into native maxillary bone. After a healing period of 3 months the specimens were harvested with a trephine. Histological and histomorphometrical analyses were performed in a light microscope. To evaluate the process of osseointegration in the maxilla and the remodelling process in the grafted area, a distinction in percentages of bone -to- implant contact (BIC) and bone areas (BA) was made between old bone and newly formed bone.

**Results:** Overall the highest percentages of BIC and BA were seen around the test mini-implants in the native bone of the maxilla (Table 1). However, only the old bone measured by percentages BIC and BA were statistically significant ( $P = 0.025$ , respectively,  $P = 0.042$ ).

**Conclusion:** The peri-implant endosseous healing properties of the NanoTite<sup>™</sup> surface are more favourable compared with the healing properties of the Osseotite<sup>®</sup> surface in the native bone of the maxilla, while this difference was not visible in a recently grafted area.

**Table 1. Bone to implant contact BIC (%) and bone area (%) of the control (DAE) and test (DAE + CaP) mini-implant per patient**

Patient	Control (DAE) BIC%	Test (DAE + CaP) BIC%	Control (DAE) BA%	Test (DAE + CaP) BA%
1	2.52	9.06	9.09	12.86
2	7.29	12.45	13.56	22.90
3	4.86	11.53	3.19	7.69
4	16.40	7.34	23.13	11.27
5	14.47	15.54	19.04	25.22
6	0	5.50	0	11.14
7	3.16	10.29	7.16	10.56
8	8.15	8.70	9.78	12.00
9	5.42	8.53	12.65	12.00
10	4.66	6.63	6.69	10.94
11	1.36	4.11	2.20	9.44
12	17.11	14.68	12.23	20.80
13	12.78	6.39	9.55	15.80
14	11.51	8.76	14.10	11.09
15	11.78	6.53	8.51	5.00
Mean ± SD	8.68 ( ± 5.29)	9.07 ( ± 3.30)	10.78 ( ± 5.66)	13.25 ( ± 5.62)

Comparative clinical analyses of immediate and early loaded SLA and SLActive Straumann<sup>®</sup> TE<sup>™</sup> implants

**Presenter:** Kokovic V

*Faculty of Stomatology, Belgrade, Serbia*

**Co-authors:** Kokovic V, Andric M, Jurisic M

*Clinic of Oral Surgery, Faculty of Stomatology, University of Belgrade, Belgrade, Serbia*

**Background and aim:** The aim of this prospective study was to compare clinical results of immediate and early loading of Taper Effect implants with SLA and chemically modified SLA surface placed in posterior mandibles. The implant stability, vertical bone resorption and peri-implant soft tissue health (modified plaque index MPI, modified bleeding index MBI, probing pocket depth PPD) were assessed according two different functional loading.

**Materials and methods:** Twenty-seven patients with bilateral edentulous posterior mandibles areas and in need of prosthetic reconstruction were recruited. 162 Straumann<sup>®</sup> TE<sup>™</sup> implants (72 SLA and 90 SLActive), a diameter 4.1/4.8 mm and length 8 and 10 mm were installed bilaterally in positions of second premolar, first and second molar according to a one-stage surgical protocol. Equal number of implants (81) was in two different loading groups. Temporary restorations were placed on implants from immediate loaded group (IL) at the same day of implants placement and on early -loading implants (EL) restorations were placed after 3–6 weeks. Implant survival, implant stability and changes in crestal bone level from placement to 12 months were evaluated

**Results:** After 12 months, implant survival rate was 100% in the immediate and early loading groups. Mean value of primary stability for all 162 implants was  $79.07 \pm 0.46802$  ISQ. Statistically significant differences for primary implant stability have been noted between SLA and SLActive implants (76.92 vs. 80.8) and between length 8 and 10 mm in the SLA group (74.15 vs. 76.92). Decrease of implant stability has been noted in IL group between first and second week of loading and in EL group it was in the first week of loading ( $P < 0.05$ ). Statistically significant increase of

implant stability has been found in IL and EL group between 6th and 12th week ( $P < 0.05$ ). The mean bone level change from baseline was not statistically significant different for SLA implants ( $0.21 \pm 0.12$  mm and  $0.5 \pm 0.34$  mm in IL and EL group) and for SLActive implants ( $0.27 \pm 0.09$  mm and  $0.29 \pm 0.1$  mm in IL and EL group) ( $P > 0.05$ ). No statistically significant differences for MPI, MBI and PPD were found between analyzed groups.

**Conclusion:** Presented study showed that design of Straumann® TE™ implants provides successful results in the protocol of immediate loading in posterior part of lower jaw, even in the using of 'nonstandard length' (8 mm) of implants. Two different implant surfaces (SLA and chemically modified SLA) are confirmed as safe and predictable in immediate and early loading protocol.

## 023 Short Oral Communications

Seven-year results of implants with an oxidized surface placed predominantly in soft bone and subjected to immediate occlusal loading

**Presenter:** Glauser R

*Zahnärzte Zentrum, Zurich, Switzerland*

**Co-authors:** Glauser R, Meier M

*Zahnärzte Zentrum, Zurich, Switzerland*

**Background and aim:** Numerous studies have demonstrated the feasibility and predictability of immediate implant loading or immediate implant restoration on a short-term basis. The aim of this report is to summarize on the 7-year outcome of immediately loaded oxidized implants placed to support fixed prostheses in various regions of the jaws.

**Materials and methods:** Thirty-eight patients received a total of 102 implants (Brånemark System Mk IV, TiUnite; Nobel Biocare AB, Gothenburg, Sweden) for support of 51 fixed restorations at the day of implant placement. Twenty-nine patients with 73 implants supporting 36 restorations have been followed for 7 years. The 7-year follow-up included clinical, radiographic and microbiological evaluations to assess treatment outcome. An independent radiologist performed the radiographic evaluation using the top of the implant as the reference point with negative values indicating a level below the reference point. Intrabuccal bacterial sampling was performed at implant sites (test,  $n = 73$ ) and neighbouring teeth (control,  $n = 35$ ). DNA probes were used to quantify four marker species (*actinobacillus actinomycetemcomitans*, *bacteroides forsythus*, *porphyromonas gingivalis*, *treponema denticola*). In addition, the total bacterial load (TBL) in terms of colony forming units (CFU) at implants and teeth was assessed.

**Results:** Three implants were removed, although stable, in one patient at the 2-month follow-up due to post-operative infection in the adjacent guided bone regeneration area. No additional implants were lost, resulting in a cumulative implant survival rate of 97.1% (7 years). At the 7-year examination, absence of plaque and absence of bleeding on probing was reported for 82% and 86% of the sites, respectively. The mean marginal bone remodeling after 7 years of function was  $-1.51$  mm (SD 1,  $n = 73$ ). The mean TBL was  $17.35 \times 10^6$  CFU at implant sites and  $13.55 \times 10^6$  CFU at teeth, respectively. No differences were detected with regard to quantification of marker species at implant sites and teeth.

**Conclusion:** The 7-year follow-up data indicate that the applied immediate loading protocol using a slightly tapered implant design with an oxidized surface is a successful treatment alternative. The long-term outcome is similar to that documented for delayed loading protocols.

## 024 Short Oral Communications

Immediate function with scalloped implants in the esthetic zone biologic rationale and clinical results

**Presenter:** Noelken R

*University of Mainz, Mainz, Germany*

**Co-authors:** Noelken R<sup>1</sup>, Wagner W<sup>1</sup>, Kunkel M<sup>2</sup>

<sup>1</sup>Department of Oral and Maxillofacial Surgery, University Hospital Mainz, Mainz, Germany, <sup>2</sup>Department of Oral and Maxillofacial Surgery, University Hospital Bochum, Bochum, Germany

**Background and aim:** The study examined the clinical performance of scalloped implants (NobelPerfect™ and NobelPerfect™ Groovy) in a one-stage procedure with immediate provisionalization in the esthetic zone.

**Materials and methods:** One hundred and fifty-eight scalloped NobelPerfect™ and NobelPerfect Groovy implants were inserted in 81 patients. All patients received immediate prosthetic restorations cleared for occlusal load. Primary outcome variables were implant success, marginal bone levels and pink esthetic score (PES).

**Results:** All implants achieved excellent primary stability. Within a follow up period of up to 35 months, there were two implant losses (one NobelPerfect™ and one NobelPerfect™ Groovy). Further five implants showed bone loss beyond the first thread and are therefore classified as failures. Overall cumulative success rate was 90.6%. Interproximal marginal bone levels averaged 1.7 mm above the first thread for both groups. Mean PES ratings were 11.3 (range, 7–14). By and large, marginal esthetics, as assessed by the 'P E S' was preserved under the surgical intervention.

**Conclusion:** Survival rates, marginal bone levels and esthetic results suggest proof of principle for the scalloped implant design.

## 025 Short Oral Communications

Agreement of 2D histomorphometry with 3D µCT measurement?

**Presenter:** Stadlinger B

*University of Technology, Faculty of Medicine, Dresden, Germany*

**Co-authors:** Stadlinger B<sup>1</sup>, Mai R<sup>1</sup>, Eckelt U<sup>1</sup>, Göbbels J<sup>2</sup>, Kuhlisch E<sup>3</sup>, Scharnweber D<sup>4</sup>, Bernhardt R<sup>4</sup>

<sup>1</sup>Department of Oral & Maxillofacial Surgery, Faculty of Medicine, University of Technology, Dresden, Germany, <sup>2</sup>Federal Institute for Materials Research and Testing, Berlin, Germany, <sup>3</sup>Institute for Medical Informatics and Biometry, Faculty of Medicine, University of Technology, Dresden, Germany, <sup>4</sup>Max-Bergmann Center of Biomaterials, University of Technology, Dresden, Germany

**Background and aim:** Histomorphometry of soft and hard tissue serves to quantify the degree of osseointegration. However, changes in axis during the sawing process and differences in

the amount of histological sections gained for analysis may lead to differences in measurement. This study compares high-resolution synchrotron radiation micro-computed tomography (SR $\mu$ CT) to histomorphometry.

**Materials and methods:** Six experimental titanium implants containing a chamber were placed in the maxilla of six minipigs. Bone-implant contact (BIC) and volume (BV) within the chamber were determined after 8 weeks of submerged healing, using both histomorphometry and SR $\mu$ CT. SR $\mu$ CT allows for a high precision of bone detection due to 276 analysed slices per implant and a resolution of 9  $\mu$ m. A comparison of BIC and BV was performed for the single SR $\mu$ CT slices, matching the histological sections and for all SR $\mu$ CT slices.

**Results:** The comparison of BV inside the chamber between identical slices gained from histology and SR $\mu$ CT showed no significant difference ( $P=0.315$ ) in mean values for both methods. The values determined for the entire BV showed an intraclass correlation coefficient of 0.705 for SR $\mu$ CT data and of 0.493 for the histological data. The analysis of BIC inside the chamber showed a systematic underestimation of the SR $\mu$ CT data in comparison with the matching histological slices at the same position.

**Conclusion:** The results support the use of histomorphometry to approximate peri-implant B V and BIC. Nevertheless in order to analyse small but significant histological differences of bone formation, volume data from SR $\mu$ CT showed that the number of histological slices per sample has to be increased.

026 | Short Oral Communications

## Interaction of different bone graft materials with bone marrow stromal cells, *in vivo* and *in vitro* studies

**Presenter: Foschi F**

University of Genoa, Genova, Italy

Co-authors: Foschi F<sup>1</sup>, Conserva E<sup>2</sup>, Mastrogiacomo M<sup>1</sup>, Pera P<sup>2</sup>, Cancedda R<sup>1</sup>

<sup>1</sup>Dipartimento di Biologia Oncologia e Genetica, University of Genoa, Genoa, Italy, <sup>2</sup>Department of Prosthodontic, University of Genoa, Genoa, Italy

**Background and aim:** For the repair of bone defects, a tissue engineering approach would be to combine cells capable of osteogenic activity with a scaffolding material to stimulate bone regeneration and repair. Bone graft materials (BGMs) constitute an adjuvant for bone tissue regeneration in oral surgeries to achieve osteosynthesis, bone augmentation and implant osseointegration. Human bone marrow stromal cells (hBMSCs), are prone to differentiate towards osteoblastic lineage with osteogenic medium. When hBMSCs are combined with hydroxyapatite/ $\beta$ -tricalcium phosphate (HA/TCP) ceramic scaffolds have been shown to induce bone formation in long bone defects. Aim of our study was to investigate whether BGMs may improve the natural osteogenic differentiation of hBMSCs.

**Materials and methods:** Three successfully isolated hBMSCs cultures were pooled together and seeded onto different biomaterials. Four different BGMs were selected: equine bone (Biogen); natural bone mineral (BioOSS); HA/TCP composite (BONIT); bovine bone conjugated with a synthetic peptide (PepGen P15)

and synthetic HA/TCP composite (skelite). Seeded cells were cultured for 14 and 28 days. Appropriate positive and negative control were studied. mRNA was isolated from cell cultures, early and later osteogenic gene expression (OC, BSP, ALP, COL1 $\alpha$ ) was analyzed by quantitative real-time PCR. Morphology and interaction of cells with BGMs was observed with optical and scanning electron microscopy. Tissue construct were implanted in mice and processed.

**Results:** SEM showed an early adhesion of hBMSC to the different BGMs within 6–72 h. An increment of cell density was revealed on the surface of animal derived BGM with respect to the others. Early and later osteogenic markers revealed by quantitative real time PCR throughout the experimental time-course were expressed from the hBMSC cultured in presence of animal derived BGMs, an high induction of BSP and COL1 $\alpha$  genes was detected. These markers resulted to be upregulated in presence of BGMs when compared with the cells cultured without BGMs. *In vivo* implants of biomaterials seeded with hBMSCs in immunodeficient mouse animal model showed a significant bone neo-formation in presence of BGMs of animal origin.

**Conclusion:** BMSCs expressed osteogenic markers when cultured on BGMs with different chemical composition and geometry demonstrating the capability of scaffold to support their proliferation and differentiation. BGM of animal origin induced an osteogenic differentiation of hBMSC osteoprogenitor. hBMSCs seeded onto implanted biomaterials in an ectopic bone formation murine model induced significant bone formation. The application of autologous expanded *in vitro* bone marrow stromal cells could implement the function of BGMs.

027 | Short Oral Communications

## Early results of 409 consecutively placed novel tapered, variable thread design implants

**Presenter: Navarro Jr JM**

Branemark Osseointegration Center, Las Palmas, Spain

Co-authors: Navarro Jr JM<sup>1,2</sup>, Navarro JM<sup>1</sup>

<sup>1</sup>Branemark Osseointegration Center, Las Palmas, Spain, <sup>2</sup>New York University College of Dentistry, Department of Biomaterials and Biomimetics, New York, NY, USA

**Background and aim:** A novel tapered, variable-thread design implant (NobelActive) has been developed. It has been designed to provide stable tissue support and immediate function. As for all newly developed implant systems, documentation of treatment success, marginal bone levels and soft tissue conditions over time are needed. The primary objective of this retrospective study was to evaluate the differences in bone level and bone remodelling with a novel implant design (NobelActive) in various clinical situations.

**Materials and methods:** Four hundred and nine implants were consecutively placed into 138 patients in this retrospective study. One hundred and twenty-one implants were placed immediately after tooth extraction, 151 implants were placed in combination with grafting procedures, 237 implants were placed in a flap-less manner, and 116 were immediately loaded. Clinical and radiographical examinations to evaluate the

treatment outcome were performed at implant placement and after 12 months.

**Results:** Eight implant failures, in eight patients, occurred during the first year resulting in cumulative survival rates of 98.04%. Stable hard and soft tissues and an increase in papilla index during the first year were observed in the majority of the cases.

**Conclusion:** The results show stable bone and soft tissue levels after the first year in function for this novel variable-thread design implant (NobelActive). In experienced hands this implant can be used under demanding treatment conditions, i.e. immediate placement, immediate provisionalization. However, further long-term controlled investigations are needed in order to evaluate the long-term outcome of any new implant system.

028	Short Oral Communications
-----	---------------------------

### Osseointegrated implant rehabilitation in previously irradiated jaws without the use of adjunctive hyperbaric oxygen treatment

**Presenter:** Marker P

*Odense University Hospital, Odense C, Denmark*

**Co-authors:** Marker P, Eckerdal A, Thygesen T

*Odense University Hospital Dept. Oral & Maxillofacial Surgery, Odense C, Denmark*

**Background:** The treatment of oral cancer usually involves extensive resection of the mandible or maxilla, excision of orofacial soft tissue and often radiation therapy. The anatomical changes, as well as the changes caused by radiation therapy present difficulties in the subsequent oral rehabilitation. However, retention of dental prosthesis, and thereby reestablishment of the oral functions, are substantially improved by the use of osseointegrated implants. The question as to whether hyperbaric oxygen treatment (HBO) should be employed in connection with implantation has been a frequent subject of debate.

**Aim:** To evaluate the survival of dental implants in previously irradiated jaws without the use of adjunctive HBO.

**Materials and methods:** From 1989 to 2007, 137 dental implants were installed in 35 patients (22 M, 13 F). All patients received radiotherapy, and no patients had HBO.

**Results:** One hundred and two implants were installed in the mandible and 35 in the maxilla. The mean observation time after implantation was 42 months (range 4–165). The interval from cessation of radiotherapy to surgery was 4–312 months (mean 48).

All implants osseointegrated without complications. Two patients died before loading of the implants. Nine implants were lost, two after 9 years due to a new cancer, and seven due to bad hygiene after in average 50 months. Eleven patients died during follow-up, five from recurrence and six from other causes. The overall survival rate of the 130 implants was 95% after follow-up of in average 42 months.

**Conclusion:** Osseointegration of dental implants in irradiated jaw bone without the use of adjunctive HBO is uncomplicated providing certain guidelines are employed. The survival rate in the present study is comparable to the well-known survival rate

for dental implants in uncompromised patient. Furthermore, the use of osseointegrated implants after oral cancer therapy is a rapid method to achieve early dental rehabilitation. Still, the most advantageous time for implantation after radiotherapy remains to be determined.

029	Short Oral Communications
-----	---------------------------

### Osseointegration of zirconia dental implants: a biomechanical and histomorphometrical study in mini pig

**Presenter:** Gahlert M

*Private Dental Clinic, Munich, Germany*

**Co-authors:** Gahlert M<sup>1</sup>, Roehling S<sup>2</sup>, Sprecher C<sup>2</sup>, Eichhorn S<sup>3</sup>, Steinhäuser E<sup>3</sup>, Wieland M<sup>4</sup>, Kniha H<sup>1</sup>, Milz S<sup>2</sup>

*<sup>1</sup>Private Dental Clinic, Munich, Germany, <sup>2</sup>AO Research Institute, Davos, Switzerland, <sup>3</sup>Klinik für Orthopädie und Sportorthopädie der TUM, Munich, Germany, <sup>4</sup>Institut Straumann, AG Basel, Switzerland*

**Background and aim:** The use of zirconia for dental implants has become an alternative to titanium because of its biocompatibility and its tooth like colour. The purpose of the present study was to investigate the osseointegration of zirconia implants with a new rough surface topography in comparison with the well-documented titanium implants with a sandblasted and acid-etched surface (SLA).

**Materials and methods:** Cylindrical zirconia implants 4.1 mm in diameter and 10.0 mm in length were acid etched to modify the surface topography. Standard Ti-SLA implants of the exact shape served as controls. After extraction of incisors 2 and 3 and after a 6 months healing period, 16 adult miniature pigs received both types of implants in the maxillae using a randomized scheme. The animals were euthanized after 4, 8 and 12 weeks. Fifty-nine implants were subjected to removal torque testing (RTQ) and 28 implants to histomorphometrical analysis.

**Results:** Both materials showed similar RTQ results. The average mean value for zirconia was 60.4 Ncm (42.4–69.6 Ncm) and 63.4 Ncm for Ti-SLA (42.1–75 Ncm). There was no significant difference in RTQ value at 8 weeks. The histomorphometrical evaluation showed direct osseous integration for both materials. Zirconia implants revealed mean peri-implant bone density values of 42.3% at 4 weeks, 52.6% at 8 weeks, and 54.6% at 12 weeks after implantation, whereas Ti-SLA implants demonstrated mean values of 29%, 44.1% and 51.6% at corresponding time intervals. Concerning bone implant contact ratio the mean values for zirconia ranged between 27.1% and 51.1% and for Ti-SLA between 23.5% and 58.5%. Non-inflammatory inhibition of osseointegration occurred when the implants were placed at least in part into non-osseous growing or moving structures. The histomorphometrical evaluation detected no significant differences between both types of implant at any given time point.

**Conclusion:** The biomechanical and histomorphometrical results clearly indicate that zirconia implants have a comparable capacity for osseous integration as the titanium implants from the control group.

Implant surface characteristics influence the outcome of treatment of peri-implantitis: an experimental study in dogs

**Presenter: Albouy JP**

*The Sahlgrenska Academy at University of Gothenburg, Gothenburg, Sweden*

**Co-authors: Albouy JP, Abrahamsson I, Berglundh T**

*The Sahlgrenska Academy at University of Gothenburg, Gothenburg, Sweden*

**Background and aim:** The aim of the present study was to analyze the effect of surgical treatment of peri-implantitis without systemic antibiotics at commercially available implants in dogs.

**Materials and methods:** Mandibular premolars and the three anterior premolars in the maxilla were extracted in six Labrador dogs. At 3 months four implants representing four different systems – turned (Biomet 3i), TiOblast (Astra Tech AB), SLA (Straumann AG) and TiUnite (Nobel Biocare AB) were placed in a randomized order in the mandible. Three months after implant installation experimental peri-implantitis was initiated using ligatures and plaque formation until 40–50% of the supporting bone was lost. The ligatures were removed and daily cleaning with toothbrush initiated. Four weeks later, surgical therapy was performed, without systemic or local antimicrobial therapy. Meticulous mechanical cleaning of the implant surfaces using cotton gauze soaked in saline and profuse saline irrigation was used before suturing the flaps around the neck portion of the implants. The 5-months follow-up period was clinically and radiographically monitored. Block biopsies were retrieved for histological analysis.

**Results:** Surgical therapy resulted in improved clinical conditions at implants with turned, TiOblast and SLA surfaces, while at implants with a TiUnite surface swelling and redness in the peri-implant mucosa persisted. In addition, two of the TiUnite implants were lost at 10 and 18 weeks after surgery, respectively. The radiographic analysis revealed that bone gain occurred at implants with turned (2.22 mm), TiOblast (1.59 mm) and SLA (0.89 mm) surfaces following treatment. At TiUnite implants, however, a mean bone loss of 1.58 mm was found after treatment. The results from the histological analysis disclosed that resolution of peri-implantitis was achieved in tissues surrounding implants with turned and TiOblast surfaces and, to a smaller degree, also SLA surfaces. No signs of resolution were seen in sections representing TiUnite implants.

**Conclusion:** It is suggested that (i) resolution of peri-implantitis following treatment without systemic or local antimicrobial therapy is possible and that (ii) the outcome of therapy is influenced by implant surface characteristics.

Matrix-metalloproteinases and bone loss at implants restored according to the platform switching concept: a randomized controlled trial on the influence of different mismatching

**Presenter: Canullo L**

*University of Bonn, Bonn, Germany*

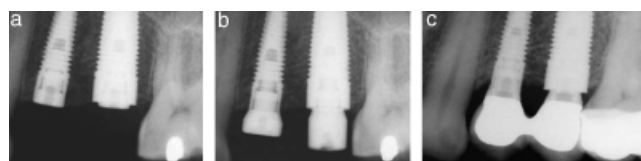
**Co-authors: Canullo L<sup>1</sup>, Iannello G<sup>2</sup>, Jepsen S<sup>1</sup>**

<sup>1</sup>University of Bonn, Bonn, Germany, <sup>2</sup>Data Analyst, Rome, Italy

**Background and aim:** Matrix metalloproteinases (MMPs) are important mediators of tissue degradation. This randomized controlled clinical trial aimed to evaluate bone responses to implants restored with different implant/abutment mismatching and to assess the correlation between peri-implant bone remodeling and peri-implant sulcular fluid levels of matrix metalloproteinases.

**Materials and methods:** A total of 80 implants (Global<sup>®</sup>, Sweden & Martina, Italy) were divided according to platform diameter in four groups: 3.8 (Control Group), 4.3 (TestGroup<sub>1</sub>), 4.8 (TestGroup<sub>2</sub>) and 5.5 mm (TestGroup<sub>3</sub>), 20 implants each group. They were randomly placed in the posterior maxilla of 30 patients. Two months later, all implants were connected to a 3.8 mm diameter abutment and definitive prosthetic rehabilitation was performed. Radiographic bone levels were measured independently by two calibrated examiners immediately after implant placement (baseline) and every 6 months after loading using an image analysis software. Patients were followed up for 30 months after prosthetic loading

(Fig. 1)



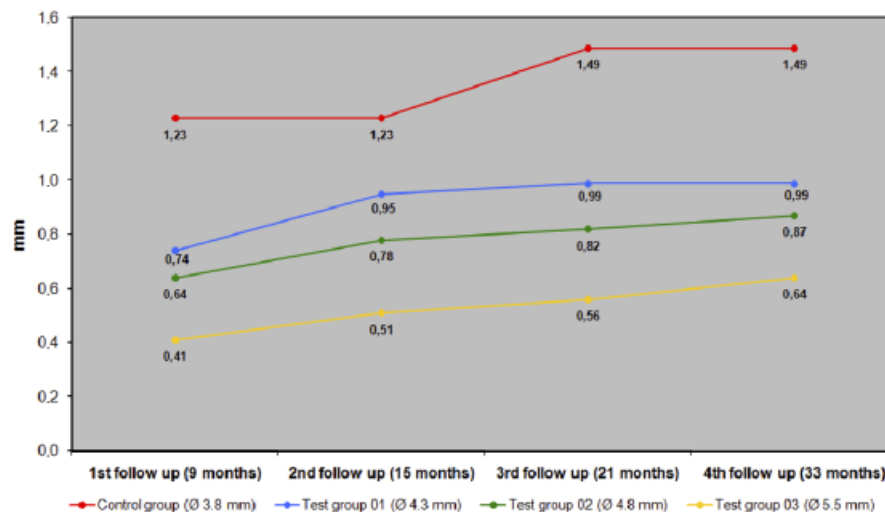
At the last follow-up visit, in addition to a standard clinical and radiographic exam, peri-implant sulcular fluid samples were obtained. Activated matrix metalloproteinase-8 (aMMP-8) was quantified by ELISA (Dentognostics, Jena, Germany).

**Results:** Five patients were lost to follow-up after 33 months. A total of 70 implants remained in the study and all of them were clinically osseointegrated. Radiographic analysis showed a mean bone loss of 0.97 mm (SD = 0.42 mm) for Test Group<sub>1</sub>, 0.77 mm (SD = 0.43 mm) for Test Group<sub>2</sub>, 0.64 mm (SD = 0.32 mm) for Test Group<sub>3</sub>.

(Fig. 2)

These values were statistically significant lower ( $P < 0.005$ ) than the Control Group mean values (1.48 mm, SD = 0.42 mm). There was an inverse correlation between the amount of bone loss and the degree of mismatching ( $-0.63$ ,  $P < 0.001$ ). For MMP-8, the respective mean values were: 4.139 ng (SD: 3.25 ng) for the ControlGroup; TestGroup<sub>1</sub>: 2.894 ng (SD: 3.17 ng); TestGroup<sub>2</sub>: 3.534 ng (SD: 3.64 ng), TestGroup<sub>3</sub>: 3.278 ng (SD: 3.25) and 2.8 ng (SD: 4.45 ng) for samples from adjacent control teeth (probing





depth  $\leq 3$  mm). No significant differences between the groups and no significant correlation between MMP-8 levels and the extent of past bone loss at individual sites was observed.

**Conclusion:** This study confirmed an inverse correlation between that extent of implant/abutment mismatching and the amount of peri-implant bone loss. Longitudinal monitoring of peri-implant sulcular levels of MMP-8 may be warranted to determine their suitability as predictors for future peri-implant attachment loss.

#### 032 Short Oral Communications

### Free microvascular transfer of segmental cortico-cancellous femur – a new technique for alveolar ridge reconstruction

**Presenter:** Gaggl A

*General Hospital LKH-Klagenfurt, Klagenfurt, Austria*

**Co-authors:** Gaggl A, Buerger H, Virnik S, Chiari F

*General Hospital, Klagenfurt, Austria*

**Background and aim:** Poor transplant bed conditions are often seen in patients after tumour surgery, posttraumatic defects or severe atrophy of the maxilla or mandible. In these cases microvascular transplants are often chosen to correct combined soft and hard tissue defects. For defect coverage an individually shaped bone transplant with a thin soft tissue layer is the aim. The microvascular osteoperiosteal flap from the distal femur is a cortico-cancellous bone flap to be used for individual defect coverage of segmental defects of the jaws. In this study, the surgical technique of ridge reconstruction using this type of microvascular bone transplant is described and initial clinical results are reported.

**Materials and methods:** In 12 patients with alveolar ridge deficiency of the maxilla or mandible after tumour surgery (four), trauma (three) or atrophy (five), defect coverage was carried out with the help of this femur transplant, designed according to the defect. The defects to be corrected measured from 3 to 10 cm in length and 1.5 to 4 cm in width. The height to be augmented was between 1 and 2.5 cm. The length of the microvascular pedicle was between 4 and 10 cm. The arterial anastomosis was performed

between the descending genicular artery and the facial or labial superior artery as end-to-end or end-to-side anastomosis. The venous anastomosis was performed between the accompanying veins of the descending genicular artery and the facial vein or angular vein as end-to-side anastomosis. The anastomoses were performed via intraoral approach. Therefore, extraoral incisions have been avoided. After 4–6 months 34 dental implants were placed in the transplanted bone for later prosthetic treatment.

**Results:** There were no severe complications or transplant loss. In all patients the defect coverage was performed in the correct size and design. All patients were treated with dental implants (34) 4–6 months after ridge reconstruction. There was one implant loss. All other implants were osseointegrated. A successful prosthetic treatment was performed with fixed or removable superstructures in all cases.

**Conclusion:** The microvascular osteoperiosteal femur graft can be used successfully in individual reconstruction of alveolar ridge defects of up to 10 cm in length. The transplant can be individually shaped according to the defect and can be used for placement of dental implants later on. Intraoral anastomosing techniques are new and successful. Extraoral scars can be avoided. The technique is a new and important step for alveolar ridge augmentation in difficult augmentative cases. Long-term success is being followed-up.

Early loading of non-submerged titanium implants with a chemically modified sandblasted and acid-etched surface: 2-year results of a prospective 2-center study regarding clinical and radiographic data

**Presenter: Bornstein M**

*University of Bern, Bern, Switzerland*

**Co-authors:** Bornstein M<sup>1</sup>, Morton D<sup>2</sup>, Hart C<sup>1</sup>, Wittneben JG<sup>3</sup>, Ruskin J<sup>4</sup>, Buser D<sup>1</sup>

<sup>1</sup>Department of Oral Surgery and Stomatology, University of Bern, Bern, Switzerland, <sup>2</sup>Department of Diagnostic Sciences, Prosthodontics and Restorative Dentistry, University of Louisville, Louisville, USA, <sup>3</sup>Department of Crown- and Bridge Prosthetics, University of Bern, Bern, Switzerland, <sup>4</sup>Department of Oral and Maxillofacial Surgery, University of Florida, Gainesville, USA

**Background and aim:** The aim of this two-center study was to evaluate screw-type titanium implants with a chemically modified, sandblasted and acid etched surface (mod SLA), when placed in the posterior maxilla or mandible, and loaded early healing period of 21 days after placement.

**Materials and methods:** The 56 included patients met strict inclusion criteria, and all provided informed consent. Each patient displayed either a single tooth gap (ST), an extended edentulous space (EES), or a distal extension situation (DES) in the posterior mandible or maxilla. Eighty-nine implants were inserted according to an established non-submerged protocol, and underwent undisturbed healing for a period of 21 days. Where appropriate, the implants were loaded after 21 days of healing with provisional restorations in full occlusion. At weeks 4, 7, 12 and 26 Implant Stability Quotient (ISQ) was measured to monitor early healing and osseointegration in one center (56 implants). Definitive metal ceramic restorations were fabricated and positioned on each implant after 6 months of healing. Clinical measurements regarding soft tissue parameters and radiographs were obtained at different time points up to 24 months after implant placement.

**Results:** Of the 89 inserted implants, two implants failed to integrate and were removed during healing (2.2%), and two additional implants required a prolonged healing time (2.2%). Eighty-five implants were therefore loaded without incident after 21 days of healing (95.6%). At the time of implant placement, the range of ISQ values exhibited a mean of 74.33, and by week 26 a mean value of 83.82 was recorded. No additional implant was lost throughout the study period, whereas one implant was lost to follow-up and therefore considered a drop-out. The remaining 86 implants all exhibited favorable radiographic and clinical findings. Based on strict success criteria, these implants were considered successfully integrated 2 years after insertion, resulting in a 2-year success rate of 97.7%.

**Conclusion:** The results of this prospective two-center study demonstrate that titanium implants with the modified SLA surface can predictably achieve successful tissue integration when loaded in

full occlusion 21 days after placement. Integration could be maintained without incident for at least 2 years of follow-up.

Stability of crestal bone level at platform switched non-submerged titanium implants: a histomorphometrical study in dogs

**Presenter: Ferrari D**

*Heinrich Heine University, Düsseldorf, Germany*

**Co-authors:** Ferrari D<sup>1</sup>, Schwarz F<sup>1</sup>, Mihatovic I<sup>1</sup>, Schaer A<sup>2</sup>, Becker J<sup>1</sup>

<sup>1</sup>Department of Oral Surgery, Heinrich Heine University, Düsseldorf, Germany, <sup>2</sup>Camlog Biotechnologies AG, Basel, Switzerland

**Background and aim:** To investigate the influence of platform switching on crestal bone level changes at non-submerged titanium implants over a period of 6 months.

**Materials and methods:** Titanium implants ( $n = 72$ ) were placed at 0.4 mm above the alveolar crest in the lower jaws of 12 dogs and randomly assigned to either matching or non-matching (circumferential horizontal mismatch of 0.3 mm) healing abutments. At 4, 8, 12, and 24 weeks, dissected blocks were processed for histomorphometrical analysis. Measurements were made between the implant shoulder (IS) and: – the apical extension of the long junctional epithelium (aJE), – the most coronal level of bone in contact with the implant (CLB), and – the level of the alveolar bone crest (BC).

**Results:** At 24 weeks, differences in mean IS – aJE, IS – CLB, and IS – BC values were  $0.2 \pm 1.2$ ,  $0.3 \pm 0.7$ , and  $0.3 \pm 0.8$  mm at the buccal aspect, and  $0.2 \pm 0.9$ ,  $0.3 \pm 0.5$ , and  $0.3 \pm 0.8$  mm at the lingual aspect, respectively. The comparisons between groups revealed no significant differences at either the buccal or lingual aspects.

**Conclusion:** It was concluded that (i) bone remodeling was minimal in both groups, and (ii) platform switching may not be of crucial importance for a maintenance of the crestal bone level.

Influence of anatomic variability in sinus grafting outcomes

**Presenter: Avila G**

*University of Michigan, Ann Arbor, USA*

**Co-authors:** Avila G<sup>1</sup>, Wang HL<sup>1</sup>, Rudek I<sup>1</sup>, Galindo-Moreno P<sup>2</sup>, Moreno-Riestra I<sup>1</sup>, Padial-Molina M<sup>2</sup>, Misch C<sup>1</sup>, Bagramian R<sup>1</sup>, Neiva R<sup>1</sup>


<sup>1</sup>School of Dentistry, University of Michigan, Ann Arbor, MI, USA,

<sup>2</sup>School of Dentistry, University of Granada, Granada, Spain

**Background and aim:** Bone availability is a key factor to achieve success in implant dentistry. Inadequate alveolar bone height is a common limitation for proper implant placement in the posterior atrophic maxilla. Grafting of the maxillary sinus has been regarded as one of the most reliable alternatives to overcome this problem. There are several factors that may influence the outcomes of this procedure such as remaining alveolar bone height, type of material and technique used, presence of concomitant pathology and

anatomic variations. The aim of this study was to evaluate the influence of the distance from the lateral to the medial wall of the maxillary sinus on the outcomes of a sinus augmentation.

**Materials and methods:** A total of 25 patients in need of sinus grafting were recruited for the study. After initial exam customized radiographic guides were fabricated and a cone-beam CT scan was done. Sinus grafting was performed by a lateral approach using a particulated allograft. Patients were followed-up during 6 months, then bone core biopsies were harvested using the same radiographic guide as a reference. Sections of the core at 8, 10 and 12 mm from the alveolar crest were histomorphometrically analyzed. The proportion of vital bone was correlated with the distance from the medial to the lateral wall of the sinus using a statistical model.



**Results:** Twenty-one patients received sinus grafting for a total of 24 sinuses. One sinus developed an infection after grafting. This translates into a success rate of 96% for our patient pool. Radiographic analysis of the distance between the lateral and medial wall consistently showed that this distance increased in an apical direction. Mean vital bone proportion was around 40% in the 8 mm samples, while approximately 20% of vital bone was observed at a height of 12 mm. This difference was statistically significant.

**Conclusion:** These results indicate that the more the distance between the sinus walls the lower the proportion of vital bone that can be expected after 6 months of healing. Our findings may have an

important impact on surgical planning before implant placement after a sinus grafting technique has been performed and provides new information about bone remodeling patterns in the oral cavity.

036 Short Oral Communications

**Gingivomorphometry – esthetic evaluation of the periimplant mucogingival complex: a new method for collection and measurement of standardized and reproducible data in oral photography**

**Presenter: Weinländer M**

*City Implant Vienna, Vienna, Austria*

**Co-authors: Weinländer M<sup>1</sup>, Lekovic V<sup>2</sup>, Krennmair G<sup>3</sup>, Spadijer S<sup>4</sup>**

<sup>1</sup>City Implant, Vienna, Austria, <sup>2</sup>Department of Periodontology,

Belgrade, Serbia, <sup>3</sup>Department of Prosthodontics, Vienna, Austria,

<sup>4</sup>Department of Periodontology, Belgrade, Serbia

**Background and aim:** A new method for the esthetic evaluation of the peri-implant mucogingival complex through collection of standardized oral photographs and computer-assisted measurement of reproducible data is introduced. Using this method, different soft tissue and crown parameters in the dentogingival complex can be measured and the esthetic outcome monitored.

**Materials and methods:** A photographic device and a standard protocol for the esthetic evaluation of implant supported restorations is presented, comprising the six soft tissue parameters mesial and distal papilla areas, mesial and distal papilla heights, as well as soft tissue contour and recession. In order to demonstrate the reproducibility of standardized oral photography and the accuracy of the measurement of the six parameters, the data obtained in each of two standardized clinical photographs of the anterior maxillary region from 10 patients with no apparent dental disease taken at different time intervals (10–14 days) were compared. The statistical analysis included paired *t*-test, one-way ANOVA and coefficient of variation.

**Results:** Statistical analysis revealed high reproducibility with no significant differences between the measurements on the first and second standardized oral photograph of each patient, respectively.

**Conclusion:** Gingivomorphometry on standardized oral photographs can be considered to be an accurate and reproducible method for the evaluation and measurement of different dentogingival parameters.

037 Short Oral Communications

**Sinus lift procedure in presence of mucosal cyst: a clinical prospective study**

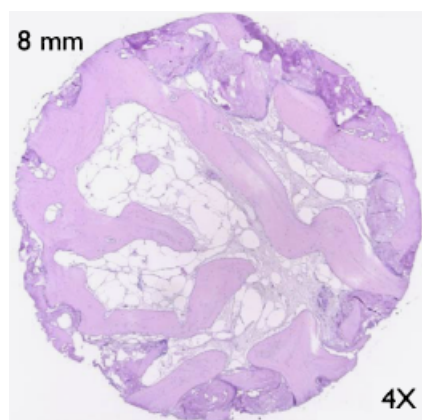
**Presenter: Beretta M**

*University of Milan, Milan, Italy*

**Co-authors: Beretta M, Cicciu M, Grossi GB, Maiorana C**

*University of Milan, Milan, Italy*

**Background and aim:** Mucocoele is a pseudocystic expanding formation with a secretive epithelial layer filled with a dense aseptic and slimy mucous liquid. Sinus lift procedure is a safe



and literature supported reliable surgical technique indicated for implant supported maxillary restoration. The aim of this prospective study was to evaluate, by means of clinical and radiological (CT scan) examination, the effectiveness of a modified sinus lift procedure in case of severe pneumatization of the maxillary sinus associated with the presence of antral cysts.

**Materials and methods:** Ten patients edentulous in the posterior maxilla with a severe pneumatization of the sinus and presence of an antral cyst, were enrolled in the study, 14 sinuses were treated. Radiographic examination included panorax and coronal and axial CT scans. All patients were referred to a otorhinolaryngologist in order to perform an endoscopic examination to exclude other pathological conditions. Sinus augmentation was performed following the guidelines stressed by Tatum.

After administrating antibiotic 24 h before surgery (Amoxicillin 1 g cpr), the later wall of the maxillary sinus was exposed and an osteotomic window was performed using a round bur. Perforation through the vestibular wall of the maxillary sinus was made 5 mm over the upper side of the bony window using a 2 mm round bur. The liquid contained in the lesion was sucked out by means of a syringe inserted into the previously created access. Sinus lift procedure was concluded according to the standard technique.

**Results:** No intra and post-operative complications occurred. Thirty-four implants, 16 in one -stage procedure and 18 in two -stage procedures had been placed after 6–8 months healing period. No patients reported sinusitis or inflammatory and infective reactions after the surgical procedure. Six months CT scan control reported good graft integration in all cases. All the patients showed reduction of the lesion volume and the absence of mucosal cyst radiological findings was revealed in nine patients. The Scheiderian mucosa thickness was reduced in all patients with a range from 1 to 2 mm after 6 months healing. No relapses were presented at the most recent follow-up. Implant survival rate was 100%.

**Conclusion:** The clinical results show that for the patient treated in our investigation, the surgical procedure proposed represents a reliable and predictable technique which could be considered a valid option in the treatment of mucosal cyst, minimizing the surgical stages and giving the possibility to reduce the lesion volume during the sinus lift procedure.

#### 038 Short Oral Communications

Treatment outcome and patients' satisfaction of two adjacent implant-supported restorations in the aesthetic zone: preliminary results

**Presenter:** Tymstra N

*University Medical Center Groningen, Groningen, The Netherlands*

**Co-authors:** Tymstra N, Meijer HJ, Stellingsma K, Raghoobar GM, Vissink A

*University Medical Center Groningen, Groningen, The Netherlands*

**Background and aim:** Placement of two adjacent implant-supported restorations is still considered a treatment of which it is difficult to establish a predictable beautiful and harmonious

result. The purpose of this randomized clinical trial was to compare the aesthetic results of two implant platform designs by assessing treatment outcome (clinical and radiographic parameters and patients' satisfaction) of two adjacent implant-supported restorations in the maxillary aesthetic zone.

**Materials and methods:** Twenty patients with two missing adjacent teeth in the maxillary aesthetic zone were randomly allocated to one of two study groups, viz. two adjacent implants with a flat implant platform (NobelReplace Groovy, Nobel Biocare, 10 patients, group I) or two adjacent implants with a scalloped platform design (NobelPerfect Groovy, Nobel Biocare, 10 patients, group II). After a 3 months provisionalization period, all implants were restored with ceramic restorations (Procera, Nobel Biocare). Pre-operatively, 2 weeks and 18 months after implant placement, clinical data were collected and standardized radiographs and clinical images were taken. Patient satisfaction was explored using a self-administered questionnaire.

**Results:** Implant survival during follow-up was 100%. Eighteen months after implant placement a marginal bone resorption of  $1.1 \pm 0.8$  mm in group I and  $2.4 \pm 1.4$  mm in group II ( $P < 0.05$ ) was observed. Patients in groups I and II rated their aesthetics as 8.8 and 8.4 (range 0–10), respectively. No statistical significant differences were noted between groups I and II regarding the papilla index.

**Conclusion:** The results demonstrate favorable survival rates and very satisfied patients for both types of implants. There was a significant difference in marginal bone loss observed. In addition, there were no significant differences between the two implant types regarding the papilla index.

#### 039 Short Oral Communications

Vertical bone augmentation vs. 7 mm long implants in posterior atrophic mandibles. Results up to 1 year after loading

**Presenter:** Felice P

*University of Bologna, Bologna, Italy*

**Co-authors:** Felice P<sup>1</sup>, Checchi L<sup>1</sup>, Marchetti C<sup>1</sup>, Pellegrino G<sup>1</sup>, Lizio G<sup>1</sup>, Esposito M<sup>2</sup>

<sup>1</sup>University of Bologna, Bologna, Italy, <sup>2</sup>University of Manchester, Manchester, UK

**Background and aim:** To compare the outcomes obtained with the placement of 7 mm long implants vs. the placement of longer implants in vertically augmented bone for the treatment of atrophic posterior mandibles.

**Materials and methods:** Sixty partially edentulous patients, with a residual bone height above mandibular canal of 7–8 mm were distributed in two treatment groups: the first group (30 patients) underwent the insertion of two/three submerged 7 mm long implants, whereas the second one (30 patients) underwent inlay augmentation procedure and subsequent insertion of  $\geq 10$  mm long implants.

After the elevation of a mucoperiosteal flap a horizontal osteotomy and two oblique cuts were made in the coronal third of the mandibular bone; the osteotomised segment was then raised in a coronal direction sparing the lingual periosteum and Bio-Oss<sup>®</sup> blocs were interposed between the raised fragment and the mandibular

basal bone. The grafts were left healing for 5 months before inserting the implants. Provisional and definitive prostheses were placed 4 and 8 months, respectively, thereafter both in the short implant group and in the augmented group.

**Results:** Three implants in three patients failed in the augmented group vs. one implant in the 7 mm short implant group up to the placement of the final prostheses. Consequently three prostheses vs. one prosthesis could not be placed at the planned time, though all implants were successfully replaced and loaded. Four complications (dehiscence) occurred in four patients of the augmented bone group vs. none in the

7 mm short implant group (no significant statistical difference). In two cases a partial loss of the graft occurred. Only patients subjected to vertical augmentation complained of temporary mental nerve sensitivity disturbances. No permanent sensitivity alterations of the alveolar inferior nerve occurred in both groups.

**Conclusion:** The results of this study suggest that, when the residual bone height over the mandibular canal is between 7 and 8 mm, 7 mm short implants might a preferable choice since the treatment is faster, cheaper and associated with less morbidity than vertical bone augmentation.

# Posters

## (Abstracts 40 to 425)

040 | Poster – Topic Implant Aesthetics

Clinical success of implant supported zirconium abutments in the aesthetic region

**Presenter:** Atalay S

*Istanbul University, Istanbul, Turkey*

Co-authors: Atalay S, Gultekin BA, Siraliyev S, Ozgen M, Abdel-Hak J, Yalcin S

*Istanbul University, Istanbul, Turkey*

**Background and aim:** Rehabilitation of complete or partial edentulism with implant-supported superstructures has become a well-accepted treatment choice. Recently increasing patient demands and technological advances have led to the development of new dental materials. Usage of zirconium abutments and full ceramic restorations have been dramatically increased over the past 5 years.

**Materials and methods:** The purpose of our study was to evaluate the clinical success of implant -supported zirconium proceras abutments with all ceramic zirconium proceras crowns and bridges in the maxillary aesthetic zone. From January 2006 to 2009, 40 Nobel Biocare Replace and 15 Camlog Screw line implants were inserted to 36 patients. Clinical evaluation was started at the beginning of implant insertion. Radiographic parameters were analyzed on panoramic radiographs right after implant insertion, permanent prosthesis delivery and every 1 year after operation. Furthermore, Plaque and gingival index scores were analyzed 1 week after Procera restoration delivery, and every 1 year. Furthermore, all surgical and restorative complications such as implant, abutment, Procera crown fractures, loosening of components like abutment screw, crown, breakage or chipping of porcelain were examined at these 3 years study.

**Results:** Two Nobel Biocare implants were lost during 3 years. Twenty-five restorations were single tooth crowns and 12 were bridges. Neither breakage nor chipping were observed of any Procera crowns or bridges except one bruxism patient. Two zirconium abutments of Nobel Biocare implants placed in 14 and 22 region were fractured at the same severe bruxism patient. After replacement with titanium abutments and porcelain fused metal restoration no abutment and superstructure fractures were observed. In three cases, loosening of the abutment screw was observed. After 3 years plaque and gingival index scores were < 1. The mean plaque index was 0.25 and the mean gingival index was 0.5 on abutments. The mean marginal bone loss was  $0.7 \pm 0.06$  mm.

**Conclusion:** Within the limitations of this study, it seems that rehabilitation of edentulous aesthetic regions with implant supported zirconia abutments and zirconia -based all ceramic Procera restorations fulfill the biomechanical and aesthetic requirements. Especially, in bruxism patients increasing the implant number consequently the zirconium abutment number or to use titanium abutments instead of zirconium abutments could offer sufficient stability to support reconstructions in an aesthetic region. Healthy peri-implant soft tissue conditions and stable marginal bone resorption, we achieved in this study.

041 | Poster – Topic Implant Aesthetics

Surgical treatment of peri-implantitis using water cooled Nd:YAG laser alone or in combination with GBR: clinical study

**Presenter:** Lioubavina N

*Kliniek De Meern, De Meern, The Netherlands*

**Background and aim:** Periimplantitis is a growing problem in dentistry. Several lasers were tested to decontaminate the implant surface during the treatment. The aim of the study was to evaluate the effect of disinfection of the implant surface with water cooled Nd:YAG laser during the flap surgery alone or in combination with GBR.

**Materials and methods:** Thirty-one patients exhibiting non-mobile 41 dental implants with PPD of  $\geq 6$  mm and radiological peri-implant defects of  $\geq 4$  mm were included in the study were subjected either to surgical laser treatment (SL) or SL combined with GBR (SL/GBR).

Following flap surgery the implants were exposed. The granulations were removed with metal curettes. In 15 patients (23 implants, SL-group) the exposed implant surface was disinfected with curettes and water/air cooled Nd:YAG laser (Genius Dental ApS, Tureby, Denmark) (power 4 W, water/air 9, frequency 50 Hz, pulse duration 250  $\mu$ s) before flap closure. In the remaining 16 patients (18 implants, SL/GBR-group) after the laser treatment peri-implant defects were grafted with autogenous bone/Bio-Oss and were covered with Bio-Gide membrane and sub-epithelial palatal graft. After surgery all patients received similar antibiotic, antiseptic and maintenance therapy. Clinical measurements, slides and radiographic bone loss (RBL), calculated as percentage of the non-osseointegrated implant height, were obtained at 0 and 6 months.

**Results:** The average initial PPD was 8.3 mm in the SL group and 8.4 mm in the SL/GBR group with 100% BOP at all implants. Suppuration was found at 18 implants in LS group and at 14 implants in SL/GBR group. All implants were present at 6 months. No adverse effect of the laser treatment was reported. The average PPD reduced significantly to 4.5 mm in the LS group and to 3.3 mm in the SL/GBR group after 6 months. The average RBL (measured blindly) was reduced from 46.8% to 36.4% in the SL group and from 49.1% to 9.7% in the SL/GBR group ( $P < 0.05$ ). BOP index reduced from 100% to 25.8% in the SL group and to 15.6% in the SL/GBR group. No suppuration was found at 6 months. The SL/GBR treatment led to significant esthetical improvements of peri-implant mucosa at upper front implants.

**Conclusion:** The water cooled Nd:YAG laser can be safely used for disinfection of the diseased implant surface. The combined laser/GBR therapy resulted in significantly greater clinical, radiological and esthetical improvement of severely infected implant sites.



Immediate implant placement and restoration in the esthetic zone: a prospective study with 18-month follow-up

**Presenter:** Tortamano P

*School of Dentistry of the University of São Paulo, São Paulo, Brazil*

**Co-authors:** Tortamano P, Camargo LO, Kanashiro LH

*School of Dentistry of the University of São Paulo, São Paulo, Brazil*

**Background and aim:** This clinical study aimed to assess the dimensional stability of peri-implant soft tissues around immediate placed and restored implants in the maxillary esthetic zone during 18-month follow-up.

**Materials and methods:** Twelve systemically healthy patients presenting a hopeless maxillary central incisor were selected. Provisional restorations were delivered immediately after tooth extraction and implant placement. Peri-implant soft tissue dimensions were measured either by direct clinical examination and evaluation of study casts. Measurements were performed before tooth extraction, immediately after implant and restoration placement, after 6 weeks, 3, 6, 12, and 18 months post-operatively. The distances assessed were: tip of the mesial papilla to the mesio-incisal edge of the adjacent central incisor; tip of the distal papilla to the mesio-incisal edge of the adjacent lateral incisor; length of the clinical crown of the definitive restoration.

**Results:** All patients completed the study, and no implants failed within the 18-month follow-up period (100% survival rate). No statistical differences were observed in the distances between the incisal edge of the adjacent teeth and the mesial and distal papilla tips ( $P=0.303$  and  $0.099$ , respectively), at any follow-up session. Likewise, there were no alterations on the definitive clinical crown dimensions during the follow-up period ( $P=0.406$ ).

Distance

	Central incisor	Lateral incisor	Definitive restoration
Baseline	$6.34 \pm 1.17$	$6.13 \pm 1.03$	–
6 weeks	$6.35 \pm 1.21$	$6.24 \pm 1.8$	$10 \pm 1.12$
3 months	$6.24 \pm 1.31$	$6.24 \pm 1.02$	$9.96 \pm 1.17$
6 months	$6.21 \pm 1.27$	$6.21 \pm 1.08$	$10.01 \pm 1.24$
12 months	$6.19 \pm 1.2$	$6.13 \pm 1.02$	$9.94 \pm 1.23$
18 months	$6.2 \pm 1.2$	$6.10 \pm 0.99$	$9.97 \pm 1.26$

**Conclusion:** The findings of this 18-month prospective study indicates that within the selection criteria and technique presented in this study, immediate implants with immediate restorations can be a predictable option for the replacement of teeth in the esthetic zone, providing stability to the peri-implant soft tissue.

Clinical evaluation of immediate single tooth implants and same day provisional crowns: a new approach

**Presenter:** Borges T

*Portuguese Catholic University, Bragança, Portugal*

**Co-authors:** Borges T<sup>1</sup>, Carvalho V<sup>1</sup>, Carvalho Á<sup>2</sup>, Carvalho C<sup>2</sup>, Leitão J<sup>1</sup>

<sup>1</sup>Portuguese Catholic University, Viseu, Portugal, <sup>2</sup>CMEB, Centro Médico Privado de Bragança, Bragança, Portugal

**Background and aim:** Good osseointegration outcomes have been described following provisionalization of single tooth immediate implants in extraction sites. Improved aesthetics results on the same day of the surgical procedures and maintenance of the soft tissue contours are the main advantages of this protocol. The aim of this study was to determine the level of bone lost around single tooth implants with same day provisional crowns adapted with a new technique of marginal adaptation.

**Materials and methods:** Ten patients, who required single-tooth rehabilitation in the area of the 15 –25, were included in this study. Ten dental implants were placed in fresh extraction sockets followed by a provisional crown adaptation and connection, without functional loading. Marginal bone loss was assessed by standardized radiographic control at the end of first year in function. Two examiners made measures in the mesial and distal aspects, from a defined point at the top of the implant to the bone crest, with a digital X-ray system.

**Results:** All implants were successfully osseointegrated in this study. None of the 10 implants presented marginal soft tissue recession or other gingival complication during the first year. After 1 year the mean bone level lost was 0.5 mm apical to the top of the implant.

**Conclusion:** It is suggested that immediate implant placement followed by provisional crown placement and adaptation, with this new technique, is a viable solution for the maintenance of the peri-implant tissues and aesthetics results.

The immediate temporization of maxillary single tooth implants

**Presenter:** Piombino S

*Clinic for Periodontal and Implant Surgery, Grumo Nevano, Italy*

**Co-authors:** Eccellente T, Piombino M, Piombino S, Capasso S

*Napoli Italy*

**Background and aim:** Many clinical studies reported high success rate using immediately loaded implants. Experimental studies have demonstrated histologically that osseointegration occurs after immediate loading of titanium implants. The immediate loading of endosseous dental implants has the advantage of significantly reducing the entire duration of the treatment, which have a positive effect on the patient from a social and psychological point of view. This study will report on

the clinical result of 24 immediately loaded implants in the anterior region of maxilla.

**Materials and methods:** Twenty-four ankylos implants were placed in 21 patients to restore 10 central incisors, 11 lateral incisors and three canine. Sixteen implants were inserted without flap elevation. All implants were immediately restored with pre-fabricated abutments cement-retained provisional crowns. At insertion, none of the restorations had occlusal contacts (immediate non-occlusal loading). Seven days antibiotic therapy (amoxicillin 2 g pro die) and chlorhexidine 0.2% mouth rinse was given as preventive measure. Additionally, 2 months nutritional limitations are advised. The implants were restored with definitive restorations (fully functional occlusion) 4–6 months after implant placement. Periapical radiographs, mSBI and mPLI, technical complications, were recorded in different time intervals. Patient's satisfaction was also evaluated.

**Results:** Two implants were removed for mobility during healing phase. All other implants became osseointegrated. After a total observation period of 34 months (range 24–58) the overall survival rate was 91.7%. All implants presented a healthy peri-implant soft tissue conditions (mSBI > 1; mPLI > 1) and stable gingival contour. Radiographic mean bone loss evaluating both interproximal surfaces was 0.56 mm (range 0.37–1.43 mm). No technical complication occurred. All patients appreciated treatment modality, one patient was not satisfied with the aesthetic of the rehabilitation.

**Conclusion:** The results of this study suggest that immediate temporization of maxillary single tooth implants is a technique that seems to give a satisfactory results in selected cases. Primary stability of implants is a prerequisite to achieve osseointegration. The implant design makes a significant contribution to the initial stability of the implant during placement surgery. In general, when implants must be loaded immediately, a screw thread implant design with rough surface is recommended.

045 Poster – Topic Implant Aesthetics

Teeth- and tissue-supported restorations utilized for the interim rehabilitation in full arch implant reconstructions

**Presenter: Sava K**

*University of Athens, Elefsina, Greece*

**Co-authors: Sava K, Chronopoulos V, Kourtis S, Orfanou A**  
*University of Athens, Athens, Greece*

**Background and aim:** Dental implants have been used successfully for decades in the treatment of edentulous patients and offer great comfort compared with complete dentures. However, completely edentulous patients or patients with several teeth with poor prognosis that will be all extracted have to be provided with an interim complete denture until the implants have been uncovered. Complete dentures are a less attractive option for the patients because of functional, esthetic, and psychological reasons. The use of complete dentures over implants during the patients's healing period has been associated with numerous complications. The aim of this poster is to present a new type of interim restoration supported by hopeless teeth and soft tissues.

**Materials and methods:** Interim restoration supported by teeth with poor prognosis and soft tissues that can be used to avoid the use of a complete denture during the osseointegration period.

**Results:** These provisional restorations can be used during the osseointegration period to avoid the use of a complete denture. The teeth can thus be restored with fixed restorations during the whole osseointegration period to provide better comfort and avoid the psychological stress of using a removable prosthesis. Additionally, the problems associated with dentures over implants or grafts (pressure, implant exposure, etc.) can be eliminated. An additional clinical advantage is the possibility of applying selective pressure for proper soft-tissue management. The patient can also evaluate the esthetics and phonetics of the future restoration without the difficult adaptation to a complete denture. Furthermore, the provisional restoration can be used as a guideline of the laboratory construction of the framework by using silicone impressions (index) and the cutback technique.

**Conclusion:** The use of a long-term fixed provisional restoration supported by teeth with poor prognosis and retromolar soft tissues can be very helpful to restore a patient during the osseointegration period. The hopeless teeth may be extracted before the final impression but can contribute significantly to the patient's comfort. Although the patient may be restricted to soft foods and these constructions are prompt to frequent decementation, they are well accepted by the majority who choose this alternative solution instead of a complete denture.

046 Poster – Topic Implant Aesthetics

Combining fixed dental prosthesis and removable partial denture prosthesis in reconstructing the complete edentulous arch

**Presenter: Petropoulou A**

*National and Kapodistrian University of Athens, Athens, Greece*

**Co-authors: Petropoulou A, Petropoulou A, Chronopoulos V, Kourtis S**

*National and Kapodistrian University of Athens, Athens, Greece*

**Background and aim:** In clinical practice, we are often called to rehabilitate the maxilla, mandible or both arches of edentulous patients. In earlier time the selected treatment used to be the construction of a complete removable denture. Nowadays with the evolution of implants, it is our everyday practice to treat these patients with the placement of implants and overdentures or full arch fixed prosthesis, depending on the number of the implants. However, implant placement in the posterior areas is sometimes not permitted by anatomic and/or financial restrains, or patients' unwillingness to have extensive surgical/augmentation procedures. This is why in current literature, there are case reports which demonstrate the possibility of achieving positive results with a removable prosthesis connected to an implant- supported fixed prosthesis. The aim of this poster is to present the treatment methodology of this prosthetic solution.

**Materials and methods:** Bilateral distal extension RPDs in combination with anterior fixed implant prosthesis with semi-precision attachments, as a treatment to a completely edentulous patient.

**Results:** This prosthetic treatment can solve a lot of problems of implant overdentures. Patient self-confidence may be increased by the use of an anterior fixed restoration instead of an unesthetic bar of an overdenture. Additionally, it is observed that there is minimal component wear, stable tissue condition, and treatment time and cost can significantly be decreased.

**Conclusion:** The use of removable partial prosthesis to an implant-supported fixed prosthesis can be an effective and viable clinical solution in selected cases of complete edentulous patients who can be completely satisfied with the treatment result.

047	Poster – Topic Implant Aesthetics
-----	-----------------------------------

### Clinical and radiological evaluation of single-tooth implants after bone augmentation procedures in the esthetic zone

**Presenter: Hof M**

*Bernhard Gottlieb University Clinic of Dentistry, Vienna, Austria*

**Co-authors: Hof M, Strbac G, Zechner W, Watzek G**

*University Clinic of Dentistry, Vienna, Austria*

**Background and aim:** The need for bone augmentation before implant placement in the anterior maxilla may compromise the esthetic outcome of the peri-implant soft tissue. The aim of this study was to evaluate peri-implant bone loss and soft tissue esthetics around single-tooth implants after bone augmentation procedures in the esthetic zone with the use of the pink esthetic score (PES).

**Materials and methods:** Twenty-eight patients with a total of 45 single-tooth implants in the anterior zone of the maxilla who required bone augmentation were included in the study. Autogenous bone was harvested from the chin area, ramus area, iliac crest and tuber maxillae for augmentation. Orthoradial intraoral images were taken of the soft tissue around single tooth implants and the contralateral tooth as a reference to evaluate the PES.

Marginal periimplant bone loss was evaluated by extraoral rotational panoramic radiographs. In addition, factors such as patient age and sex, pocket depths, nicotine use, implant position and site of measurement were recorded. Statistical analysis was performed with a mixed model with data given as least-square means and standard errors of the mean.

**Results:** The PES reveals a mean overall of 10.76 (3.04 SD), varied from 4 to 14. No significant correlation was found between the Pink Esthetic Score and periimplant bone loss ( $P = 0.8258$ ). Bone harvested from the ramus area and from tuber maxillae showed more peri-implant bone loss (3.46 mm 0.7 SD and 2.03 mm 0.65 SD) than bone harvested from chin or iliac crest (1.32 mm 0.27 SD and 1.24 mm 0.54 SD). The difference was not significant ( $P = 0.0521$ ).

**Conclusion:** With the use of autogenous bone harvested from the chin area, ramus area, iliac crest and tuber maxillae for augmentation, reliable esthetic results can be achieved in the anterior maxilla for single-tooth implants. The esthetic outcome of soft tissue around single-tooth implants after bone augmentation procedures seems to be comparable with the soft tissue outcome of single tooth implants without bone augmentation.

048	Poster – Topic Implant Aesthetics
-----	-----------------------------------

### Combining esthetics and retrievability in restoring BIOMET 3i implants

**Presenter: Papavasiliou G**

*School of Dentistry, Athens, Greece*

**Co-authors: George P, Phophi K, Spiridon S**

*School of Dentistry, Athens, Greece*

**Background and aim:** One of the major advantages of implant-retained restorations is retrievability. This is easy to achieve with screw-retained restorations. A problem with restorations in the esthetic zone is that for anterior implants, the access hole may lie on the facial surface of the restoration. Cement retained restorations solve such problems, but they also reduce the ability to retrieve the restoration, depending on the cement used. The aim of this study was to investigate the long-term clinical performance of implant supported restorations, combining cement retained telescopic abutments for anterior implants and screw retention for the most posterior implant.

**Materials and methods:** Fifteen consecutive patients combining osseointegrated anterior and posterior Biomet 3i implants were selected. Of those, five needed full arch restorations and 10 needed unilateral ones. The implants ( $n = 75$ ) presented with no symptoms and their position and spread was judged to be satisfactory for restoration. Titanium or custom telescopic abutments were placed on anterior implants and custom screw-retained abutments on the most posterior implant (bilaterally for full arch restorations). Temporary cement was used for anterior abutments and the screws of the posterior ones were torqued according to manufacturers' instructions. The patients were followed for a period of 2–5 years (mean 3.6 years). At recall appointments (every 6 months), peri-implant health, fit of restoration, integrity of prosthesis including screw retention and occlusion were monitored. Each restoration was retrieved once after 1 year of clinical performance.

**Results:** For the observation period no implants were lost or presented irreversible peri-implant inflammation. No retention screws were lost or broken, but three (unilateral restorations) had to be retorqued once and the occlusion was adjusted. There were two fractures, both at the margins of anterior retainers which were repaired at the retrieval appointment. All restorations were easily retrieved, inspected, cleaned and placed back on the implants with new retaining screws. Three telescopic abutments presented mobility and had to be retorqued, with no further symptoms. One patient was lost from recall after 3 years of follow-up. All restorations were judged to present satisfactory clinical performance.

**Conclusion:** In conclusion, full arch and unilateral restorations retained on BIOMET 3i implants by a combination of cement on anterior abutments and screws on the most posterior ones present with excellent retrievability and very good clinical performance for the implants as well as for the restorations.

## A new way to achieve stable, easy-to-repair esthetic implant -supported crown

**Presenter:** Chen JH

*Kaohsiung Municipal Hsiaokang Hospital, Kaohsiung, Taiwan*

**Co-authors:** Chen JH<sup>1</sup>, Lei YN<sup>2</sup>, Lan TH<sup>2</sup>, Wu YT<sup>2</sup>, Yang YL<sup>2</sup>

<sup>1</sup>*Kaohsiung Municipal Hsiaokang Hospital, Kaohsiung, Taiwan,*

<sup>2</sup>*Kaohsiung Medical University Chung-Ho Memorial Hospital, Kaohsiung, Taiwan*

**Background and aim:** A review article by Elliot Abt concluded recently that the 5 years survival rate of implant-supported single crown in metal-ceramic was 95.4% and the one in all-ceramic crown was 91.2%. Furthermore the cumulative incidence of ceramic or veneer fractures was 4.5%. With the tendency of escalating cost of precious metals and the better esthetic quality of all ceramics, the latter one is getting more competitive with the former one. Fracture and loss of the veneering ceramic was sometimes an inevitable and troublesome problem. However, it was still not predictable to repair the fractured porcelain with direct composite resin. The aim of the short clinical study was to achieve a new design of stable, easy-to-repair and esthetic implant supported crown.

**Materials and methods:** This randomized controlled clinical trial was to compare the early clinical outcome of implant-supported metal-ceramic crowns and implant-supported CAD/CAM Zirconia-resin composite crowns. Thirty patients were randomly divided into two groups of 15 subjects each. Both groups received crowns on titanium or gold abutments. The low gold metal-ceramic crowns and CAD/CAM zirconia – resin composite crowns were fabricated and cemented. At baseline, 6-month, and 1-year recall appointments, patient satisfaction, the fracture rate of crowns and the plaque and gingival index scores around the crowns were evaluated and measured.

**Results:** All CAD/CAM Zirconia – resin composite crowns survived during the 1-year period, although one metal-ceramic crown experienced the fracture of the veneering porcelain. Patient satisfaction were encouraging, and the maintenance of esthetics were good at both groups. Moreover plaque and gingival index scores was mostly zero and almost constant over time for each group.

**Conclusion:** This short -term clinical trial demonstrates that the easy-to- repair CAD/CAM Zirconia – resin composite crowns have comparable early clinical outcome, including esthetic satisfaction, fracture rate of crowns and periodontal effect of implant abutments.

## CAD/CAM investigation of implant superstructures made of zirconia all-ceramic

**Presenter:** Ohya T

*JSOI, Sendai, Japan*

**Co-authors:** Ohya T

*JSOI, Sendai, Japan*

**Background and aim:** Zirconia is a new esthetic material. Zirconia all-ceramic systems are being clinically applied in

metal-free dental prostheses as a breakthrough in terms of compatibility with the periodontium. Here, we evaluate the use of zirconia all-ceramics as superstructures of implants.

**Materials and methods:** A total of 106 patients (355 teeth), who underwent implant therapy at our hospital from November 2005 to August 2008, were included in this investigation. The superstructures (101 bridges and five single crowns) were made of zirconia ceramic. In these patients, 304 Replace Select Tapered implants were placed and Easy Abutments were used. For CAD/CAM, Cerec 3 was employed and superstructures were prepared on a model by indirect method in all cases. Vita InCeram zirconia (33%), and ceravian were used for the structure.

**Results:** Two of the implants had to be removed within 2 months, but were replaced with thicker fixtures and bone grafting was done. In two patients, superstructures in the molar region fractured. One patient lost the ceramic portion, and one patient had a fracture at the junction.

**Conclusion:** Implant superstructures made of zirconia ceramic were found to be superior in terms of esthetics, function, and affinity with periodontal tissues. As for the technical aspects, the ratio of the thickness of zirconia frames and ceramic was judged to be important in determining color and fracture resistance.

## Evaluation of soft tissue stability with immediate post-extractive implants in the aesthetic area: a 12-months clinical follow-up

**Presenter:** Cremonesi S

*University of Milan, Milan, Italy*

**Co-authors:** Cremonesi S, Benigni M, Bett F, Maiorana C

*Department of Implantology, Dental Clinic, University of Milan, Milan, Italy*

**Background and aim:** The success of implant therapy in the anterior maxilla depends not only on osseointegration, but also on obtaining healthy and stable peri-implant tissues. The achievement of predictable peri-implant aesthetics is possible by preserving hard and soft tissues around the failing teeth, inserting the implant in a proper 3D position and having a correct prosthetic management. Nowadays it is possible to perform immediate implants and immediate prostheses to improve aesthetics and to simplify the treatment, but in the aesthetic area this type of procedure has been associated with premature loss of the buccal mucosa. The aim of this prospective study is to observe the dimensional alterations of the peri-implant tissues after immediate implants and single-tooth provisional restorations, performed on seven patients. The mean follow-up is 1 year.

**Materials and methods:** Seven patients were treated to rehabilitate mono-edentulousness using eight 31<sup>st</sup> implants. For each of the seven patients, treatment involved the anterior maxilla, from left to right cuspid. Patients with severe parafunction, periodontitis, serious gingival inflammation, poor oral hygiene or high caries rates were excluded from this study. After the extraction of the compromised tooth, the alveolar bone was explored by a periodontal probe to assess its integrity. The implant was inserted with a proper 3-D placement and a screwed temporary crown was immediately

relined and then placed. Photographs and data forms were used as documentation tools in this study. Patients were re-examined by the authors at intervals of 1 month for 1 year by means of a periodontal probe, radiographs and clinical photographs.

**Results:** At the 1 year mean follow-up, all the implants were stable and without any sign of inflammation nor pain. The soft-tissues aspect was excellent, after a sharp observation and a computer analysis. The authors assessed the stability of the soft tissue, noting the absence of macroscopic changes from the beginning of therapy to the end of the follow-up period.

**Conclusion:** In contrast with the existing data, the documented sites showed buccal soft tissue stability and absence of recession. The recruitment of more patients in this particular protocol and new prospective studies are necessary to confirm the data resulting from this study.

052	Poster – Topic Implant Aesthetics
-----	-----------------------------------

### Implant-supported maxillary overdentures retained with conical double crown attachments: a case report

**Presenter:** Woo Yi-Hyung

Seoul

**Co-authors:** Pae A<sup>1,2</sup>, Shim JS<sup>1,2</sup>, Kim HS<sup>1,2</sup>, Kwon KR<sup>1,2</sup>, Woo YH<sup>1,2</sup>

<sup>1</sup>Department of Prosthodontics, School of Dentistry, Kyung Hee University, Seoul, Korea, <sup>2</sup>Department of Oral and Maxillofacial Surgery, School of Dentistry, Kyung Hee University, Seoul, Korea

**Background and aim:** When restoring patients with advanced bone resorption, increased intermaxillary space would result in fixed implant prostheses that feature teeth with excessive lengths. Gingival colored porcelain or acrylic resin can be utilized to restore the deficient soft tissues. Lip and soft tissue support is subsequently provided through the buccal prosthesis flange that facilitates compensation for discrepancies between the implant and crown positions. Implant-supported overdentures have been shown to provide a successful long-term outcome, particularly when used to restore edentulous patients. A novel technique to achieve secondary splinting and passive fit of implant fixtures with conical double crown attachments in fabrication of a maxillary overdenture is described.

**Materials and methods:** The patient in this case report had four implants placed in the edentulous maxilla. Removable prosthesis with buccal flange was considered because of the insufficient facial support. The definitive restoration consisted of four conical double crowns with 4° taper and a removable overdenture without palatal coverage. In conventional methods, the outer crowns would be soldered or laser welded to the metal framework, but in this case, the outer crowns were cemented to the metal framework to achieve passive fit and secondary splinting with less deflection of the implants. This technique can also simplify the laboratory and clinical procedures.

**Results:** Favorable force transfer to the individual implants can be attained by secondary splinting of the implants with a removable overdenture and conical double crowns. Also, by

using conical double crowns as attachments to retain the overdenture, palatal coverage can be reduced to the minimum. Considering the prosthodontic maintenance requirements, the frequency of the technical complications of the double crown attachments can be less than ball or bar attachments.

**Conclusion:** Edentulous patients with severe resorption can be provided with more esthetic results by a removable prosthesis with buccal prosthesis flange than fixed implant prosthesis. Conical double crowns as anchors for implant-retained overdentures can provide simplified procedures and successful outcomes.

053	Poster – Topic Implant Aesthetics
-----	-----------------------------------

### Evaluation of soft tissue characteristics around implant and natural tooth

**Presenter:** Moslemi N

Tehran University of Medical Sciences, Tehran, Iran

**Co-authors:** Paknejad M<sup>1</sup>, Moslemi N<sup>1</sup>, Kashfi M<sup>2</sup>

<sup>1</sup>Tehran University of Medical Sciences, Tehran, Iran, <sup>2</sup>Private Practice, Tehran, Iran

**Background and aim:** Soft tissue condition around dental implant is an essential part for long-term healthy and esthetic outcome. While main part of dental implant researches are focused on hard tissue, soft tissue characteristics are considered in few studies. The aim of this study was to compare soft tissue dimensions around one-stage/two-stage implant-supported prosthesis and the contra-lateral natural tooth.

**Materials and methods:** This retrospective case-control study was performed on 28 healthy dentate patients with anterior implant supported single-unit prosthesis. Implants with the following criteria were selected: at least 1 year had been passed from installation, position of implant shoulders had been placed at crestal level at surgical time, no need for guided bone regeneration during surgical procedure, and all of implants were in healthy condition. Widths of all implants were 4.1 mm and were placed prosthetic-driven. Of 28, 14 implants with one-stage surgical technique and 14 implants with two-stage surgical technique were selected. Biologic widths (BW) around implants and contra-lateral teeth were evaluated with a periodontal probe. Mucosal thickness (MT) were assessed in mid-buccal area with endodontic rimmer in midbuccal area and then measured with a caliper. Wilcoxon's test, Mann-Whitney test and Student's pair *t*-test were used to assess the differences.

**Results:** The mean BW around one-stage implants, two-stage implants, and contra-lateral teeth were  $1.42 \pm 0.48$ ,  $1.67 \pm 0.48$ , and  $1.47 \pm 0.6$  mm, respectively. The mean MT around one-stage implants, two-stage implants, and contra-lateral teeth were  $3.1 \pm 0.48$ ,  $3.09 \pm 0.75$ , and  $2.57 \pm 0.88$ , respectively. There was no statistically significant difference among one-stage implants, two-stage implants, and contra-lateral teeth with regard to measured variables.

**Conclusion:** Based on the results of this investigation, it seems that there is no noticeable difference in terms of biologic width and mucosal thickness around one-stage implants, two-stage implants, and contra-lateral teeth.

Molar intrusion induced by progressive increase of the height of antagonist implant-supported prosthesis: a series of five cases

**Presenter:** Serfaty E

*Private Practice, Paris, France*

**Co-authors:** Serfaty E<sup>1</sup>, Szmukler-Moncler S<sup>2</sup>, Davarpanah M<sup>1</sup>

<sup>1</sup>Private Practice, Paris, France, <sup>2</sup>Department of Stomatology and Maxillofacial Surgery, Paris, France

**Background and aim:** After teeth extraction, supraeruption of opposite teeth happens where occlusion is missing. When rehabilitation of the missing teeth is considered, too little room may be available for prosthetic rehabilitation because of the supraerupted teeth. The way to recreate an adequate prosthetic space is to intrude the supraerupted teeth. Intrusion of supraerupted molars has been impossible to achieve until the recent use of skeletal anchorage with mini-screws. This paper presents five patients that have been treated with a non-invasive method that leads to progressive intrusion of supraerupted molars in the maxilla without mini-screws and skeletal anchorage.

**Materials and methods:** Aim was to recreate a lacking prosthetic space due to supraerupted molars in the maxilla. Implants were placed in the edentulous area of the mandible and were left to heal for 3–6 months. By that time, the teeth to be intruded were connected together with an orthodontic wire to enlarge the periodontal ligament before starting moving teeth. Crowns of reduced height were connected to the implants. Obturation composite material was added on the occlusal face of the prosthesis. Patients were asked to close the mouth and were stopped when 2 mm of inoclusion were measured in the anterior area, corresponding to a 1 mm premature contact with the prosthetic crowns. The composite was photo-polymerized and patients were left to exert occlusion forces on the implants.

**Results:** Every 4–6 weeks patients were recalled and occlusion was checked. When occlusion was achieved due to teeth intrusion, the procedure was carried out as previously described again and again until reaching a prosthetic space compatible with a functional rehabilitation. All implants were placed in the mandible. In two patients, three implants helped to intrude two molars; in two patients, two implants intruded two molars, in one patient one implant intruded one molar. Supraerupted teeth were intruded over 2–5 mm. Radiographs taken at the end of the treatment showed no specific crestal bone loss beyond the first implant thread and no root resorption of the intruded teeth.

**Conclusion:** This case series suggest that (1) implants are able to resist without damage the forces exerted by mastication on a soft composite, (2) supraerupted molars in the maxilla can be intruded with this method, (3) 0.75–1 mm of intrusion per 4–6 weeks is achievable, (4) the use of mini-implants to achieve skeletal anchorage might be avoided. More cases with a longer follow-up are warranted with this protocol before it can be used routinely by the orthodontic and implantology community, but the present case series open intriguing treatment possibilities.

Anterior tooth replacement with implants in alveolar cleft sites: a clinical evaluation of aesthetics

**Presenter:** Nakata H

*Dental Hospital Implant Dentistry, Tokyo, Japan*

**Co-authors:** Nakata H<sup>1</sup>, Tachikawa N<sup>1</sup>, Takafuji K<sup>1</sup>, Shiota M<sup>2</sup>, Kasugai S<sup>2</sup>

<sup>1</sup>Dental Hospital Implant Dentistry, Tokyo Medical and Dental University, Tokyo, Japan, <sup>2</sup>Oral Implantology and Regenerative Dental Medicine, Tokyo Medical and Dental University, Tokyo, Japan

**Background and aim:** Background: Approximately one of 500–700 live births in Japan has an associated cleft lip and/or palate (Kochi 1997; Sumiyoshi, 1998). To restore the anatomy and integrity of the arch for subsequent orthodontic treatment, primary and secondary bone grafting are widely performed. When a residual edentulous space in the anterior region remains after surgical and orthodontic treatments, implant placement is utilized for prosthetic restoration. However, the dimensions of the recipient site are relatively often inadequate to allow implant placement and relapse is another important concern with respect to prognosis. The purpose of this study is to evaluate aesthetics of clinical outcome, analyze of prognosis including relapse, and identify prognosis-relevant factors.

**Materials and methods:** In a prospective evaluation, 15 implants placed in combination with or without bone grafting at cleft sites in 12 patients were examined. Details of the patients were five male and seven female, two bilateral, nine left sides and one right side. Patients' age of implant placement was varied from 18 to 37 years. At one case any bone grafting was preformed before implant placement. Most of CLP patients have small alveolar arch in upper jaw. Thus, in many cases, arch expansion was performed within orthodontic treatment. Since implants can not maintain the width of the arch, bridge from canine to canine remains a popular procedure. Hence, we analyzed the change in width between the first premolar and the opposite first premolar to evaluate the relapse.

**Results:** No implants were lost of these cases, and all implants functioned without any problems. Aesthetical recoveries were almost satisfactory, and which has been kept successfully. With regard to relapse, no remarkable change was observed and the patients were satisfied with the outcome of implant treatment.

**Conclusion:** Implant treatment could be an available procedure for CLP patients. However, preoperative examination based on prognosis-relevant factors is necessary. In this study, we analyzed under seven years prognosis. Nevertheless, the cases, which have undergone arch expansion, must be followed-up for longer-term.



## Esthetic evaluation of single-tooth restorations on narrow-diameter implants in anterior region: 12 months follow-up

**Presenter:** Miketic D

*School of Dentistry, University of Belgrade, Serbia, Belgrade, Serbia*

**Co-authors:** Miketic D, Jurisic M

*School of Dentistry, University of Belgrade, Belgrade, Serbia*

**Background and aim:** Narrow diameter implants (NDI) are possible alternative for challenging clinical situations such as narrow edentulous space, thin alveolar crest and replacement of teeth with small cervical diameter. Aim of this prospective case study was to evaluate esthetic success of NDI placed in the esthetically sensitive anterior region.

**Materials and methods:** Eight patients were treated with eight mini implants, 1.8 and 2.4 mm in diameter (IMTEC, USA), placed in anterior region. Provisional, interim crowns were fabricated and cemented on the day of the surgery. Depending on the loading protocol, definitive crowns were cemented 2–6 months post-operatively. Pink and white esthetic scores (PES/WES) were used to evaluate esthetic outcome at the time of the placement, as well as 12 months after the cementation of single-tooth restorations.

**Results:** At 12 months follow-up, all eight implants were osseointegrated, with absence of radiolucency, suppuration, implant mobility and pain. The esthetic outcome analysis, assessed by PES/WES objective criteria, showed satisfying result overall, which has been improved over 12 months period (from  $14.6 \pm 1.59$  to  $15.1 \pm 2.23$ ). Regarding papilla enhancement, mesial and distal papilla variables in PES increased over time (mesial papilla: from  $1.5 \pm 0.53$  to  $1.9 \pm 0.35$ ; distal papilla: from  $1.4 \pm 0.41$  to  $1.8 \pm 0.46$ ). On the other hand, root convexity parameter showed low values in mandible ( $0.8 \pm 0.84$ ) where inadequate width of keratinized tissue was present.

**Conclusion:** This study demonstrated that narrow diameter implants can be used to solve both functional and esthetic problems successfully. The short-term follow-up of 12 months revealed pleasing esthetic outcomes overall, as assessed by objective parameters. Therefore, they may represent the preferred choice in cases where space problems limit the use of standard or wide diameter implants.

## Clinical and radiological evaluation of a new implant connectionabutment system

**Presenter:** Sacco LM

*Università di Chieti, Chieti, Italy*

**Co-authors:** Sacco L<sup>1</sup>, Vrespa G<sup>2</sup>, Scarano A<sup>1</sup>, Vrespa D<sup>2</sup>

*<sup>1</sup>Università di Chieti, Chieti, Italy, <sup>2</sup>Istituto scientifico S. Raffaele, Milan, Italy*

**Background and aim:** After implant insertion and loading, crestal bone usually undergoes remodelling and resorption. If the horizontal relationship between the outer edge of the implant and a smaller-diameter component ('platform switching') is altered,

there seems to be a reduced crestal bone loss, a tissue stability and a good aesthetic and functional outcome for the final prosthetic restoration. Aim of this work was the clinical and radiologic evaluation of a new implant abutment connection system.

**Materials and methods:** Twenty patients had part at this study. Sixty implants were inserted anterior area; 45 in maxilla and 15 in mandible. After 2–4 months, all this patients were prosthetically finalized and after 2–5 months were clinically and radiologically examined.

**Results:** The results were increase of tissues stability, no inflammatory tissue was present in periimplants areas and no bone loss was showed at the radiologic examination.

**Conclusion:** This study concluded that this new implant abutment connection system showed good a tissues stability an we obtained aesthetics and functional results; but we will reserve better evaluation with more examination cases.

## Clinical outcomes of the immediate single implant placement-short time results

**Presenter:** Sapundzhiev D

*University Medical Centre Ljubljana, Ljubljana, Slovenia*

**Co-authors:** Kocar M<sup>1</sup>, Sapundzhiev D<sup>1</sup>, Kansky A<sup>1</sup>, Gorjanc M<sup>2</sup>

*<sup>1</sup>Department of Oral and Maxillofacial Surgery, University Medical Centre Ljubljana, Ljubljana, Slovenia, <sup>2</sup>Implant Institute, Ljubljana, Slovenia*

**Background and aim:** The immediate implant placement for reconstructing the single missing tooth is a predictable procedure in the implant dentistry that minimises morphological changes of the alveolar bone and consecutively occurring changes of the surrounding soft tissues after tooth extraction. Immediate implant placement can be undertaken in replacing the missing teeth do to a trauma, injury or after the failure of periodontal and periapical surgery.

**Materials and methods:** In 48 patients (20 male, 28 female) 50 implants, Ankylos, Friadent Dentsply, Mannheim, Germany (16 in the mandible, 34 in the maxilla) were placed according to immediate non-functional loading protocol. Reasons for tooth extractions were: root fracture (27), failure of treatment of cronical periapical periodontitis (22), resorption after luxatioin injury (8). In 27 patients with 27 implants signs of inflammation were present. Implants were always placed subcrestally beyond the level of the socket. Incongruities between the sockets and the implants were corrected with deproteinized bovine bone. In 30 patients immediate non-functional prosthetic temporalisation was done. The rest were delivered with sulcus formers. Antibiotics were prescribed for 10 days. Clinical and radiographic controls were performed according to the protocol (1/6/12/24 weeks).

**Results:** Susses rate was 98% (49/50). Fistulas were closed in approximately 2 weeks. One patient appeared with postoperative haematoma that resorbed uneventfully. One implant was lost because the patient did not respect soft diet regiment. The loosened implant was immediately removed and the implant treatment was postponed after the socked healing. The patient

with failed implant did not adopt soft diet regiment. All radiographs showed subcrestally positioned implants. In 47 implants apposition of bone was seen over the implant shoulder on X-rays after 24 weeks, with only three unilaterally.

**Conclusion:** Atraumatic surgery and meticulous curettage is of great importance for successful outcome. The use of antibiotics overwhelmed the threat for infection. Only one implant failed to osseointegrate due to the poor patient compliance. According to our experience the patient's compliance is of paramount importance for successful outcome in immediate implant placement for restoring a single missing tooth.

059 | Poster – Topic Implant Aesthetics

## Cerec 3D application in restoring dental implants

**Presenter:** Juciute R

*Vilnius University, Vilnius, Lithuania*

**Co-authors:** Juciute R, Rutkunas V, Sabaliauskas V

*Division of Prosthodontics, Vilnius University, Vilnius, Lithuania*

**Background and aim:** Recently chair-side CAD/CAM systems have improved considerably. Besides their application with natural teeth possibilities of restoring dental implants have to be considered.

**Materials and methods:** Ten patients were selected for treatment with dental implants. Temporary and permanent restorations were fabricated with Cerec MC XL milling unit from Vitablocks. Functional and aesthetic parameters were recorded throughout follow-up period.

**Results:** Fabrication of temporary and permanent restorations with Cerec 3D system is efficient and well patient accepted treatment modality. As advantages reduced treatment time and improved marginal aesthetics were identified.

**Conclusion:** Implant restoration with Cerec 3D can be applied in properly selected cases. However, long-term results are necessary to substantiate these findings.

060 | Poster – Topic Implant Aesthetics

## Inter-implant papilla reconstruction in the upper central incisors: two case reports

**Presenter:** Tagahara A

*Osseo Skarp Institute, Nagoya Aichi, Japan*

**Co-authors:** Tagahara A

*SJCD, Nagoya, Japan*

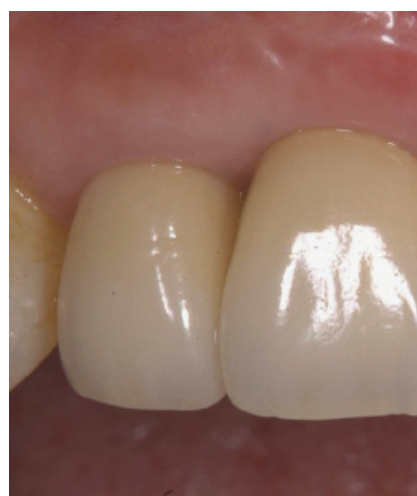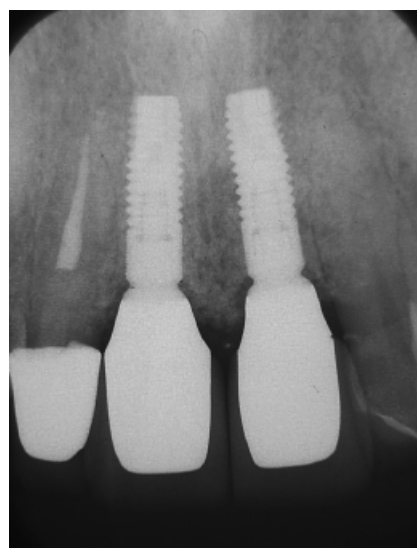
**Background and aim:** A case of anterior two adjacent implants is very difficult to achieve the aesthetic result. For inter-implant papilla reconstruction, it is important to preserve or augmentate the inter-proximal bone and soft tissue. And for long-term maintenance of vertical height of inter-proximal bone and soft tissue, horizontal bone and soft tissue thickness is also important. However, bone resorption around implants would cause inter-implant papilla disappearance and labial soft tissue recession. The aim of these case reports is to present successful approach to inter-implant papilla reconstruction.

**Materials and methods:** Case 1: Patient is 18-year-old male without smoking habit. Both of upper central incisors had been extracted two months before. Localized orthodontic treatment was performed to obtain the inter-implant distance of over 3 mm. Two implants (TiOblast,  $3.5 \times 13$  mm, Astra Tech, Mölndal, Sweden) were placed with G.B.R. technique. Before second surgery, connective tissue graft was performed.

Case 2: Patient is 48-year-old male without smoking habit. Two upper incisors had root fracture, so they were extracted with socket preservation technique. Two months later, two implants (OsseoSpeed,  $3.5 \times 11$  mm, Astra Tech) were placed with GBR technique. After a month, additional G.B.R. procedure had been performed for obtaining labial thickness of bone.

With regard to the both cases, the distance of inter proximal height of bone were measured radiographically.

**Results:**



Case 1

The distance of inter proximal height of bone was 1.5 mm over the implant shoulder. The distance between the top of the soft tissue and the implant shoulder was 5.0 mm. Thick tissue of labial site was obtained.

The distance of inter proximal height of bone was 3.0 mm over the implant shoulder. The distance between the top of the soft tissue and the implant shoulder was 6.5 mm. Thick tissue of labial site was obtained.

**Conclusion:** The both cases indicate that to achieve the aesthetic result it is important next things ; (1) the choice of implant system that prevent the marginal bone loss, (2) preservation or augmentation the inter-proximal bone and soft tissue, (3) thick tissue of labial site. Further long-term study should be made to better understand the inter-implant papilla reconstruction.

## Implant esthetics: immediate implant placement flap vs. flapless surgery

**Presenter:** Wu YT

*Nobel Dental Clinic, Kaoshiung, Taiwan*

**Co-authors:** Wu YT<sup>1</sup>, Chen ZH<sup>2</sup>

<sup>1</sup>NDC, Kaoshiung, Taiwan, <sup>2</sup>KMU, Kaoshiung, Taiwan

**Background and aim:** Purpose: The aim of this study is to compare the esthetic outcome and clinical success of immediate flap vs. flapless implant placement.

**Materials and methods:** Fifteen patients were selected for this study. Ten implants were subjected to immediate flap elevation and 10 implants were placed without flap elevation. All the selected sites had intact buccal plates and had no infection. The flap elevation group was subdivided as follows: five implants with no soft tissue graft (G1) and five implants combined with a connective tissue graft and bone graft; implants were submerged and had healed by 3 months and then the implants (G2) were uncovered. In the flapless group the bone gap was filled with a bone graft. After the implants were placed, the provisional prostheses were cemented at the temporary abutment to retain the soft tissue profile. All the provisional prostheses were not in contact with the opposed dentition. 3 months after they had healed, the definitive prostheses were placed (G3). During the 7-year follow-up period, the esthetic scores, gingival level and buccal contour change with time were observed.

**Results:** A total of 20 implants were placed (10 flap raised, 10 flapless). During the observation, all the implants were functioning successfully, and all the implants showed healthy soft and hard tissue peri-implant conditions. The group with the raised flap immediate implants with no soft tissue graft showed more buccal soft tissue recession. The flapless group showed the least buccal soft recession. The buccal contour morphology showed depression at G1 > G3 > G2.

**Conclusion:** Within the limitations of this study, it can be concluded that the immediate implants have a high success rate similar to that of conventional implant placement. The buccal contour depression cannot be prevented even with flapless immediate implants placement. The soft tissue augmentation appears to be beneficial to maintain soft tissue contour, which may help achieve the esthetic outcomes.

## Spontaneous recovery of maxillary diastema with implant prosthetics treatment of collapsed posterior occlusion

**Presenter:** Chung HW

*Jeonju MIR Dental Hospital, Jeonju, Korea*

**Co-authors:** Chung HW<sup>1</sup>, Han TJ<sup>2</sup>, Oh SH<sup>1</sup>, Kim JH<sup>1</sup>, Song GY<sup>3</sup>

<sup>1</sup>JeonjuMIR Dental Hospital, Jeonju, Korea, <sup>2</sup>WpDI, LA, USA,

<sup>3</sup>Jeonbuk National University, Jeonju, Korea

**Background and aim:** Sometimes, occlusal collapse due to severe periodontal disease, attrition and missing posterior teeth can cause masticatory discomfort and TMD, and moreover it might cause an aesthetic problem because of maxillary anterior teeth diastema that may occur due to the occlusal force of anterior teeth. At this time, resin or laminate treatment without consideration of occlusion may cause a relapse of diastema. In this case, if the basic cause of diastema is considered, it is expected that diastema may resolve on its own after recovery of complete oral function by adequate vertical dimensional reconstruction with implantation.

**Materials and methods:** This case is of a 52-year-old woman who had a chief complaint of discomfort due to the removable partial denture that she had been using for 10 years. She had missing teeth on #24, 25, 26 and #35, 36, 37 and #47 and a poor prognosis of teeth #14, 27 due to severe periodontitis. In addition, there was a diastema between #11 and #12. Thus, we extracted hopeless teeth (#14 and #27) and performed periodontal treatment on residual dentition, and then carried out implantation on the missing area with a bone graft. After the healing period, we increased the patient's occlusal vertical dimension using a provisional prosthesis. This was done two times using a leaf gauge (0.7 and 1.0 mm anterior teeth in standard).

At this time, no treatment was performed for diastema.

After the final prosthesis, a splint for occlusal stabilization and protection of a porcelain prosthesis was performed, and continuous periodontal care and occlusal check was carried out by a periodical examination.

**Results:** When the treatment was completed, we confirmed that the diastema had resolved on its own, and then we observed stable oral condition during the follow-up check period for 4 years.

There has been no recurrence of diastema.

**Conclusion:** In this case, reconstruction of posterior missing teeth by an implant yielded additional therapeutic result in that there was self-closure of the maxillary anterior diastema. It is necessary that we know the treatment of maxillary anterior diastema which occurred at the patient who has loss of adequate vertical dimension due to various cause should not be qualified to typical treatment method such as resin build-up, laminate, orthodontic treatment but approach in a viewpoint of occlusal rehabilitation.

## Rehabilitation of a patient after segmental resection of the mandible, using free fibula flap and an implant supported removable telescopic prosthesis

**Presenter: Dounis A**

*Athens Dental School University of Athens, Athens, Greece*

**Co-authors: Dounis A<sup>1</sup>, Pelekanos S<sup>1</sup>, Polyzois G<sup>2</sup>**

*<sup>1</sup>National and Kapodistrian, University of Athens, Athens Dental School, Graduate Prosthodontics, Athens, Greece, <sup>2</sup>National and Kapodistrian, University of Athens, Athens Dental School, Removable Prosthodontics, Athens, Greece*

**Background and aim:** This clinical report describes the oral rehabilitation of a 60-year-old patient who underwent resection of a leiomyosarcoma of the mandible. After the segmental resection of the mandible, the defect was reconstructed with a free fibula flap followed by placement of three Bicon implants. An implant supported removable telescopic prosthesis was used to restore function and esthetics. The aim of this report is to provide the technical aspects for the prosthetic resoration of such defects.

**Materials and methods:** An implant supported removable telescopic partial denture was constructed to restore function and esthetics.

**Results:** The defect was successfully reconstructed with the free fibula flap, and the implants integrated. Function and esthetics, as well as patient's quality of life improved dramatically.

**Conclusion:** Such cases demand a multidisciplinary approach to achieve a high standard of rehabilitation and improvement on the patient's quality of life.

## Restoration of severely absorbed maxilla with cement and screw retained restorations

**Presenter: Tsoutis K**

*University Of Athens, Galatsi/Athens, Greece*

**Co-authors: Tsoutis K, Kourtis S, Chronopoulos V**

*University of Athens, Athens, Greece*

**Background and aim:** Restoration of the severely absorbed maxilla is a challenge for the whole dental team as it includes augmentation of the bone substrate, strategical implant placement, functional and esthetic rehabilitation of the patient. The aim of this poster is to present the stage approach for the restoration of a patient with severely absorbed maxilla. In this patient both sinuses were augmented vertically and the premaxilla was increased horizontally using autogenous iliac bone.

**Materials and methods:** Seven implants were inserted after 3 months and the osseointegration was uneventful although the patient used a transitional complete denture. At the end of the osseointegration period a screw-retained implant-supported transitional restoration was fabricated as a guide to predict the final result and also improve patient's function.

**Results:** The final implant supported restoration included a screw-retained metal-polymer superstructure restoring the

missing alveolar bone and soft tissue. On the superstructure single cement-retained metal-ceramic crowns were constructed to harmonize the white and pink esthetic performance.

**Conclusion:** The utilization of a screw-retained superstructure that restores the missing pink tissues in combination with single crowns cemented on this superstructure that restore the missing teeth has both the advantage of retrievability that screw retained restorations provide, as well as the advantage of esthetics that cement-retained restorations have.

## Implant reconstruction in facial traumatism: a clinical case

**Presenter: Renard E**

*Faculty of Dental Surgery, Nantes, France*

**Co-authors: Renard E<sup>1</sup>, Duguet V<sup>2</sup>, Mutet Y<sup>3</sup>, Saffarzadeh A<sup>1</sup>**

*<sup>1</sup>Faculty of Dental Surgery, Nantes, France, <sup>2</sup>Clinique Jules Verne, Nantes, France, <sup>3</sup>Prothésiste Dentaire Vannes, France*

**Background and aim:** In case of facial traumatism, patients sometimes need dental prosthetic or reconstruction by implants. This kind of complex treatment, requires coordination between different practitioners, who contribute to the achievement of cares. In general dental care have to be overall supported, more in case of traumatic injuries and esthetics reconstructions. Indeed practitioners have to handle bones and gums defects, aesthetics and psychological aspects, because the facial traumatism often occur in the anterior zone. The clinical case we present, is the case of a young woman (21 years old), who had received a horse kick on her face when she was 13 years old. The impact had induce the loss of six teeth, from the second incisor in the right maxillary (12), to the first premolar in the left maxillary (24), and the loss of the alveolar bone of the anterior sector maxillar.

**Method:** We realized a simulation of the esthetic result that we wanted to get. This simulation had been validate in mouth with the patient and after that had been our reference during the different steps of the achievement.

**Results:** It permitted us to extrapolate the bone defect, by using a resin visible in radiography, which reproduced the ideal level of the alveolar bone. So we decided to realize an onlay bone graft with mandibular bone sample. In the second step, we used the temporary prosthesis as surgical guide to implant the patient with five implants [Straumann Bone Level(r)]. The temporary prosthesis was designed from the esthetic simulation and permitted us and the patient to project the final result. The third step was the prosthetic reconstruction, this step had been facilitate by the previous steps. We realized a new esthetic simulation, to confirm the good position of the implants. We chose ceramo-ceramic crowns to get the best esthetics result.

**Conclusion:** The esthetic prosthetic result must be the guideline during steps of treatment. Patient, who had undergone facial traumatic injuries, wait for a result which make them forget the traumatism.

## Wireless orthodontics and flapless implants

**Presenter: Moneim AA**

*Los Gatos Dental Center, Los Gatos, USA*

**Co-authors: Moneim A, Souza D**

*Los Gatos Dental Center, Los Gatos, USA*

**Background and aim:** Two new innovative dental techniques are gaining popularity: Wireless orthodontics and flapless implants. Wireless orthodontics consists in a series of clear plastic removable appliances digitally fabricated that move the patient's teeth in small increments from their original state to a final treated state. The system uses a computer as a tool to assist in creating series of sequential movements to assure light and consistent forces on the patient's teeth. The flapless implants is a minimally invasive technique for implant placement that purposely avoids elevation, advancement and closure of a flap over the implant. The rationale for flapless approach is preserving circulation to the site and minimizing the post-operative discomfort. This study illustrates how to combine both of them to achieve more predictable results. The aim of this study is to evaluate the success rate of wireless orthodontics to create or to close space in order to place dental implants with flapless technique.

**Materials and methods:** Thirteen patients (seven females/six males), with an average age of 41-year-old (ranging from 32 to 59) enrolled in the study from 2003 to 2008. The treatment planning of the clinical cases for each patient was first to use wireless orthodontics to modify, to open or to close spaces by intrusion, extrusion, tipping, bodily movement or angulation correction of teeth and secondly, to place either single or multiple one-stage dental implants with the flapless technique.

**Results:** One patient could not achieve proper space to receive the dental implant using wireless orthodontics and had to continue treatment with conventional orthodontics (success rate of wireless orthodontics = 92.31%). The other 12 patients had 16 dental implants placed after wireless orthodontics with success implant rate of 100% after at least 6 months follow-up. The average treatment time from beginning of wireless orthodontics to the placement of dental implants was 20.66 months (ranging from 10 to 38).

**Conclusion:** Using wireless orthodontics visualized through 3D Software to modify spaces between teeth to place flapless dental implant can be, in most cases, a predictable treatment for patients who seek highly aesthetic treatments and results.

## Esthetical buccal flap (EBF) for correction of buccal fenestration defects during flapless immediate implant surgery

**Presenter: Steigmann M**

*icoi, Neckargemünd, Germany*

**Co-authors: Steigmann M**

*Private Practice, Boston University, Neckargemünd, Germany*

**Background and aim:** Clinically, it is a tremendous challenge to create natural gingival esthetics following immediate or delayed implant placement. Hence, flapless immediate implant surgery

was proposed to overcome the shortfalls of these techniques. Nonetheless, one of the major limitations for this technique is its inability to correct localized horizontal/vertical deficiency, dehiscence, or fenestration without jeopardizing esthetical outcomes. Therefore, the aim of this paper is to present a new flap design, esthetical buccal flap, that is aimed at overcoming this potential problem while maintaining the optimal esthetical appearance.

**Materials and methods:** Twenty consecutively esthetical buccal flap treated patients with simultaneous implant placement were included in this pilot case report. Clinical measurements were taken at the time of prosthesis insertion, 6 and 12 months after surgery. These include: soft tissue height, papillae appearance, scar appearance and mid-buccal probing pocket depth.

**Results:** Data obtained from this pilot case report showed soft tissue height was preserved and papillae appearance remained the same as pre-surgery. No scar tissue was reported in any cases. Mid-buccal probing depths remained consistent throughout the study.

**Conclusion:** The result indicates that esthetical buccal flap together with simultaneously guided bone augmentation allows clinicians to correct apical buccal fenestration defects while maintains the supraosseous soft tissue during flapless immediate implant surgery.

## The CAD/CAM guided re-entry with individualized zirconia abutments: new perspectives in soft tissue management

**Presenter: Ponte A**

*Studio dentistico Dr. Ponte, Rivoli (Torino), Italy*

**Background and aim:** In the last years the esthetic demand of the patients in implant surgery is constantly increased. Even in the posterior area dark borders are seen with criticism. The purpose of the presented technique is to insert during the re-entry stage a CAD/CAM individualized zirconia abutment: the pre-programmed harmonious diameter, the biological and optical characteristics of the material allows to reach quick optimal esthetic results with constant peri-implant hard and soft tissue stability.

**Materials and methods:** A 46-year-old male non-smoker presented: the first and the second molar on the right side of the mandibula were missing and the residual ridge showed severely horizontal deficiency. A CT scan was taken before surgery to assess the anatomy of the site. The Materialise® software reconstructed in the three-dimensional (3D) site. Two Dentsply Friadent Xive® implants were inserted in combination with a bone splitting and spreading surgical technique. An intrasurgical impression was taken connecting the impressions copings with the surgical stent. A new model in order to evaluate the 3D position of the inserted implants was done. Zirconia ceramic abutments individualized with the Cercon Arts® software according to the anatomical design of a molar were inserted directly during the re-entry 4 months later. After 2 months an intrasulcular thread was inserted to take the definitive impression without removing the Cercon abutments. The definitive crowns were cemented adhesively 2 weeks later.

**Results:** Already 2 weeks after the re-entry a good soft tissue contour was achieved: no inflammatory processes were detected.

After the insertion of the definitive crowns an optimal esthetic result is obtained. The X-ray analysis showed constant peri-implant hard tissue stability.

**Conclusion:** The technique of taking an intrasurgical impression and to put an individualized well biotolerate ceramic abutment gives the possibility to protocol the soft tissue healing compromising the peri-implant physiology at all: the constant taking out of healing caps or provisional abutments causes 'microtraumata' for the hard and soft tissue. The choice to utilize a pre-programmed individualized abutment with optimal mechanical and optical characteristics seems to be an alternative to the common protocol. More studies are needed to evaluate the long-term results of the peri-implant hard and soft tissue stability according to this low invasive, quick and easy prosthetic protocol.

069	Poster – Topic Implant Aesthetics
-----	-----------------------------------

New technique for interimplant papilla reconstruction between two or more implants in patients with variably reabsorbed ridges and flat anatomy. Results of a series of nine consecutive clinical cases

**Presenter: Tizzoni R**

*Tizzoni Medici Chirurghi e Odontoiatri Associati, Milano, Italy*

**Co-authors: Tizzoni R**

*Tizzoni Medici Chirurghi e Odontoiatri Associati, Milan, Italy*

**Background and aim:** With increased demand for natural prosthetic restorations in the aesthetic zone, and more functional restorations with no food impaction, the highest level of skill and knowledge to reconstruct the interdental papilla between adjacent implants is essential. Interimplant papilla reconstruction is difficult because the biologic width around a flat platform implant is apical to the implant abutment connection. Because currently all implants but one have flat platforms at the top, the implant is almost always positioned below the interimplant bone crest. This location of the implant platform interdentially positions the biologic width subcrestally. This differs from a natural tooth, in which the biologic width always forms supra-crestally. Consequently, the interdental tissue lacks the crestal support that exists between an implant and a tooth or two adjacent teeth. Therefore, this study was conducted to assess whether the reconstruction of interimplant papillae could be achieved by the use of an innovative surgical technique combined with scalloped implants, in the most severe surgical conditions, i.e. in variably reabsorbed ridges with flat anatomy.

**Materials and methods:** Nine surgical sites in eight consecutive patients, requiring at least two adjacent implants and fixed prosthesis in any region of both jaws, were treated with at least two scalloped implants. Twenty-three scalloped implants were placed using this surgical technique on bone and soft tissue structures. One flat platform implant was also placed between two other scalloped implants. Notably, all treated areas presented variably reabsorbed ridges with flat anatomy. A total of 15 interimplant papillae were examined.

**Results:** 100% of the embrasure spaces analysed showed papilla reconstruction at first prosthesis insertion, 13.3% failed to

maintain interimplant papillae after 6 months and 20% after 12 months. Also, papilla reconstruction was achieved and maintained for 12 months in the mesial and distal embrasure spaces of the flat platform implant.

**Conclusion:** These results seem to suggest that the combination of the use of adjacent scalloped implants with this surgical approach, even in reabsorbed ridges with flat anatomy, may reform interimplant bone peaks as support for the papillae. Further research especially with dedicated surgical instruments is needed to confirm the validity of this new surgical technique.

070	Poster – Topic Implant Aesthetics
-----	-----------------------------------

Facilitating anterior esthetics

**Presenter: Kamposiora P**

*School Of Dentistry, Athens, Greece*

**Co-authors: Kamposiora P, Papavasiliou G, Madianos P**

*School of Dentistry, Athens, Greece*

**Background and aim:** Esthetics is a major concern for dental patients, especially since many of them depend on their smile for social and professional recognition. Implants have become a preferred and many times conservative treatment modality for a growing population of very young patients. The demand for real life looking implant-supported restorations in the esthetic zone is met by qualified dental professionals. Improvements in implant micro surfaces and placement techniques reduce the healing time and increase survival rates. Soft and hard tissue management through innovative techniques lead to less tissue deterioration and esthetically favorable implant positioning. CAD-CAM technology and improved ceramic materials allow for achievement of esthetics to the implant level. The aim of this study was to investigate the viability of a novel approach for immediate restoration of implants in the esthetic zone.

**Materials and methods:** Two variables for esthetic restorations are flapless surgery and placement of final prosthetic abutment at the time of implant placement. Both techniques require excellent presurgical planning and precise implant placement. In this presentation, an insight will be given to the preliminary findings of an ongoing clinical trial. The main features of the study are as follows. Patients that are missing single teeth in the esthetic zone are selected. Using Facilitate (Materialize) software, digital reconstruction of CT scans is performed and stereolithographic models and tooth supported surgical guides are fabricated. Using the guides, implant dummies are placed in the models. Ceramic abutments are adapted on the models and a provisional crown is fabricated. At the time of surgery the implant is placed via the same surgical guide using the flapless method. The final ceramic abutment is secured on the implant and the provisional is cemented.

**Results:** None of the implants placed so far ( $n=10$ ) was lost. The restorations were placed with minor adjustments of the temporaries, but none of the ceramic abutments. The patients experienced no adverse effects, recovery time was minimal and so was discomfort.

**Conclusion:** In conclusion, although patient selection should be careful and the protocol needs to be followed accurately as the technique is sensitive, preliminary outcomes are quite promising.

## How is a beautiful tooth?

**Presenter:** Moya-Villaescusa MJ

*University Clinic of Dentistry, Murcia, Spain*

**Co-authors:** Moya-Villaescusa MJ, Sánchez-Pérez AJ, Jornet-García A

*University Clinic of Dentistry, Murcia, Spain*

**Background and aim:** Although an important number of population cohort studies have been performed on the tooth aesthetics, little it is known of the aesthetic standards of edentulous in general Caucasian population. The aim of this study is to establish parameters of the average teeth in healthy population and to compare them with those of the aesthetic ideals.

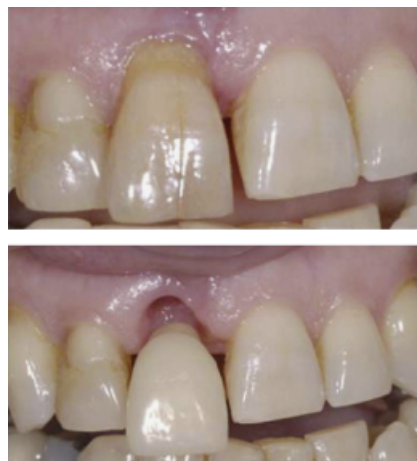**Materials and methods:** Ethical approval was obtained to recruit a cohort of students from the dental school of Murcia. Fifty healthy Caucasian volunteers (aged between 18 and 25); 25 women and 25 men were included in the study. Aesthetic dental proportions of this sample were measured on two photographs (anterior and right lateral) where the following parameters were taken: the height and the width of the right central and lateral upper incisors and of the right upper canine. The data obtained were analyzed using a correlation coefficient and a lineal regression straight. The parameters were also compared with the Simbashi's number and the 'gold' proportions in order to obtain aesthetic ideals.

**Results:** The height of an upper central incisor is  $(SN \times 1)/1.618$  and its width is SN less its height. The height of an upper lateral incisor is 80 or 75 divided by its width and its width is the width of the upper central incisor multiplied by  $1/1.618$ . The height of an upper canine is 80 or 75 divided by its width and its width is the width of the upper central incisor multiplied by  $0.618/1.618$ .

**Conclusion:** Rigid applications of principles by dentist to set a formula are not always those that patient prefer. Concepts such as 'beauty' or 'aesthetic' are social constructs and can not be standardized according to a system of universal laws. They have been shown to vary both between cultures and over time. We have encountered realistic proportions to simulate a golden proportion between central, lateral incisors and canine teeth and Simbashi's number that could help us to rehabilitate edentulous patients, with adequate aesthetic proportions.

ques. The aim is to present the use of removable partial dentures with anatomically shaped pontics to enhance and guide tissue healing in extraction sites.

**Materials and methods:** Twenty patients were enrolled for this pilot study. They need extraction of one or more teeth for periodontal disease or root fractures and asked a fixed partial implant supported prosthesis. Twenty-eight implants were positioned. Only patients with a favourable scalloped architecture and aesthetic contour of soft tissues were included. Before the surgery, alginate impression were recorded and the technician made a removable partial denture 'flipper'. The prosthetic resin elements which substituted teeth to be extracted were done as follows. The plaster teeth were removed, a 3 mm deep extraction socket was simulated on the cast and an anatomically shaped pontic was moulded with fluid composite. It is important to drill the cervical line on the pontic with a round bur. After extraction the scalloped contour of soft tissues adhered to the pontic which maintained the original shape. In the clinical phase, the pontic was trimmed with fluid composite achieving the right shape and depth.



**Results:** After 8 weeks the aesthetic line of soft tissues was evaluated to plan the surgical treatment. When the three-dimensional healing contraction of the buccal wall was about 0.5–1 mm a roll-flap technique was used and the implant was

## Removable partial dentures with anatomically shaped pontics to guide tissue healing

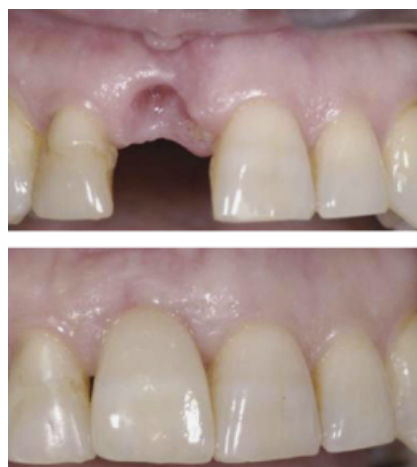**Presenter:** Longoni S

*Università Degli Studi di Milano-Bicocca, Lazzate (Milano), Italy*

**Co-authors:** Sartori M<sup>1</sup>, Longoni S<sup>1</sup>, Baldoni M<sup>1</sup>, Duvina M<sup>2</sup>, Brancato L<sup>2</sup>, Tonelli P<sup>2</sup>, Tonelli P<sup>2</sup>

<sup>1</sup>Università Degli Studi di Milano-Bicocca, Monza, Italy, <sup>2</sup>Università degli Studi di Firenze, Firenze, Italy

**Background and aim:** Several solutions have been proposed in order to maintain the scalloped architecture of the buccal plate of the alveolar ridge after teeth loss: GBR, soft tissues graft, modified implants design and mucosal microsurgical techni-





inserted screwing the healing cap. If the healing contraction was about 1–2 mm a soft tissue graft was positioned between the healing cap and the buccal soft tissues. After this phase the pontic was adapted onto the healing cap. In 19 implant sites was used only the roll-flap technique and in all patients the aesthetic line of scalloped contour was maintained without any regeneration material.

**Conclusion:** This pilot study gives clinical evidence that removable partial dentures with anatomically shaped pontics may guide soft tissues healing. The hypothesis is that positive and negative pressures of masticatory and swallow function are transferred by the flipper into the extractions sockets playing a conditioning role in wound healing.

#### 073 | Poster – Topic Implant Aesthetics

### Dental implant supported prosthetic rehabilitation following surgical treatment for an oral cavity cancer: case report

**Presenter:** Gunbay S

*Oral Surgery, Izmir, Turkey*

**Co-authors:** Gunbay S<sup>1</sup>, Sezer B<sup>1</sup>, Comlekoglu E<sup>2</sup>, Ozveri Koyuncu B<sup>1</sup>

<sup>1</sup>Department of Oral and Maxillofacial Surgery, Izmir, Turkey,

<sup>2</sup>Department of Prosthetic Dentistry, Izmir, Turkey

**Background and aim:** Oral rehabilitation of resected tumor patients often requires, besides the use of dental implants, the improvement of the soft tissue condition. In this clinical report, we describe a simple and effective surgical and prosthetic treatment procedure to achieve adequate long-term soft tissue conditions.

**Materials and methods:** A 43-year-old female suffered from a squamous cell carcinoma of the floor of the mouth. She was treated with wide local excision, including a marginal mandibulectomy with a neck dissection. One year postoperatively, she was feeling well and desired prosthetic rehabilitation. Four implants (ITI) were installed in the intraforaminal region of the mandible. Another 4 months later, healing abutments were placed and a bar-retained overdenture was made in the mandible.

**Results:** She was now fully satisfied with the function of this construction, which has been in use for 3 years without further complications.

**Conclusion:** Surgery for oral cancer results in loss or alterations of anatomical structures, which may impair oral functions, such as speech, mastication, and swallowing. Improvement of oral functions may be achieved by implant-supported prosthetic rehabilitation. The recommended treatment is a four implants-retained overdenture.

#### 074 | Poster – Topic Implant Aesthetics

### Microsurgery in implant dentistry: a new approach

**Presenter:** Rego D

*Federal University of Rio Grande do Norte-Natal-Brazil, Natal-RN, Brazil*

**Co-authors:** Rego D, Barbosa R, Pinto L, Barboza C

*Federal University of Rio Grande do Norte, Natal, Brazil*

**Background and aim:** The use of magnification, in particular the use of surgical operating microscopes, has increased in many areas of dentistry. The surgical microscope allows high-level motor skills and accuracy in clinical care. The purpose of this case series is to show the usefulness of microscope-enhanced cosmetic surgery in its application to the implantology.

**Materials and methods:** This study comprises a case series of four patients in private practice requiring anterior esthetic implants. Preoperative and postoperative images were digitally recorded and cataloged. Preoperative and postoperative radiographs were taken. The incisions were accurately mapped, the flaps were elevated and connective tissue graft were removed from palato with minimal damage. The wound was closed precisely using of 7.0–9.0 microsutures without tension. During the reentry surgery was obtained a biopsy and histologic analysis was performed from one patient.

**Results:** The clinical results showed absence of pain, less inflammation during the healing and better appearance of soft tissue. The histologic analysis of gingival tissue evidenced a minimal inflammatory infiltrate.

**Conclusion:** Microsurgery in implant dentistry offers new possibilities to improve the care in a variety of ways. Its benefits included less inflammation, better healing and improved cosmetic.

#### 075 | Poster – Topic Implant Aesthetics

### Healing of marginal defects in immediate implants

**Presenter:** Negri B

*University of Murcia – Spain, Pilar de la Horadada, Alicante, Spain*

**Co-authors:** Negri B, Pardo Zamora G, Calvo Guirado JL

*School of Dentistry, Murcia, Spain*

**Background and aim:** The purpose of this study was to evaluate the soft- and hard- tissue response to immediately placed implants. In addition, assessment was conducted to evaluate the 18-month clinical success of 14 implants inserted immediately after tooth extraction.

**Materials and methods:** The immediate placement of and implant in a fresh extraction socket seems to be a predictable technique with high survival rates. However, many authors have shown that after tooth extraction, the soft- and hard tissues experiment several changes. Twelve screw-shaped implants (13–15 mm length and 4 mm diameter) in 12 patients were placed in fresh extraction sockets in the aesthetic area. Bone defects around the implants were recorded, then filled up with porcine-collagened bone and protected with collagen membranes. The defects and bone resorption were evaluated. Clinical and

radiographic parameters of the peri-implant conditions were assessed at the moment of prosthesis placement and a follow-up within 18 months.

**Results:** The cumulative survival and success rate was 100% after 18 months period. At this time, the linear distance between implant-shoulder to the bone crest remains stable with a bone resorption of  $0.81 \pm 0.3$  mm. Optimal value of width of the keratinized mucosa was recorded.

**Conclusion:** In our experience, several clinical situations are suitable to follow immediate placement protocols that simplify the stages for the patient and the clinician. However, the clinician is recommended to be reserved when considering immediate implant placement for replacing single maxillary teeth.

076	Poster – Topic Implant Aesthetics
-----	-----------------------------------

Management of postoperative soft tissue deficiencies in anterior implant-supported restorations a case series

**Presenter:** Lorenzoni M

*University Dental Clinic, Medical University Graz, Graz, Austria*

**Co-authors:** Platzer S, Wimmer G, Stopper M, Lorenzoni M

*University Dental Clinic, Medical University Graz, Graz, Austria*

**Background and aim:** Tooth loss in the anterior maxilla represents an esthetic and functional challenge. The objective is to copy natural teeth in all qualities of appearance. Disharmonious soft tissue volume, contour and texture are often limiting the esthetic outcome and various surgical techniques have been introduced to increase the appearance of the peri-implant mucosa. The purpose of this case series is to present different treatment concepts to cope with soft tissue deficiencies in the esthetic zone.

**Materials and methods:** Case 1 describes the loss of papillary height between adjacent anterior implants after 7 years. The treatment protocol included connective tissue grafting with tunnelling technique, disconnection of the lateral implant and fabrication of a cantilevered bridge to establish harmonious soft tissue contours. Case 2 presents multiple soft tissue recessions. After removal of all implants and reinsertion of two implants vestibuloplasty utilizing an acellular dermal matrix was performed to create new masticatory mucosa before provisionalization. Case 3 demonstrates facial recession and lack of soft tissue thickness after provisional restoration of an implant. Utilizing tunnelling technique, soft tissue grafting and coronal positioning of the mucosal margin, a stable peri-implant contour could be established up to 9 months.

**Conclusion:** Several authors demonstrated that following implant surgery remodelling takes place resulting in diminished soft tissue conditions (Cardaropoli et al. 2006). Pouch techniques, vestibuloplasty and tissue conditioning represent feasible protocols for improving the esthetic outcome in the anterior maxilla. Based on sufficient bone volume the treatment objective must be an increase of the soft tissue volume in combination with coronal positioning of the mucosal margin. Increased

quantity of keratinized mucosa around dental implants might affect esthetics, clinical and immunological parameters. These findings are of special importance in the esthetic zone, where narrow and thin keratinized mucosa may lead to greater mucosal recession (Zigdon & Machtei 2008). Further studies will have to evaluate long-term results of treatment concepts for esthetic insufficiencies around implant restorations.

077	Poster – Topic Implant Aesthetics
-----	-----------------------------------

Histological analysis of the ability of osseointegration of zirconium implants in a dog model

**Presenter:** Taleb Bendiab C

*Laboratoire BioSanté @ NanoScience EA-4203, Montpellier, France*

**Co-authors:** Taleb Bendiab C<sup>1</sup>, Khaldi L<sup>1</sup>, Tournier H<sup>1</sup>, Victoria Herrera J<sup>2</sup>, Flores Reyes HE<sup>2</sup>, Torres JH<sup>1</sup>, Cuisinier F<sup>1</sup>

<sup>1</sup>*Laboratoire BioSanté @ NanoScience EA-4203, Montpellier, France,*

<sup>2</sup>*Universidad Autónoma de San Luis Potosí (UASLP) – Facultad de Estomatología San Luis Potosí Mexico*

**Background and aim:** Mechanical properties and biocompatibility make zirconia ceramics suitable implant material. Histological observations and animal studies showed the capacity of ZrO<sub>2</sub> for osseointegration. This work aims to analyze the ability for osseointegration of zirconium implants and evaluate cell adhesion of human fibroblasts to zirconium implants.

**Materials and methods:** Seven screwed Zir.Roc implant from Paris implants were inserted within the jaws of two Creole dogs. After a healing period of 2 months the animals were euthanized and implants with surrounding tissues were collected. No decalcified transverse sections were prepared according to an improved micro-CT process and analyzed by light microscopy. Histomorphometry analysis were used to determine percentage of the bone-implant contact surface and bone density (ratio between mineralized bone tissue and mineralized bone marrow).

**Results:** ZIR.ROC implants achieved osseointegration demonstrating direct bone contact. Percentage of the bone-implant contact surface varies between 15% and 64% depending on the implantation site and surgical conditions.

**Conclusion:** Zirconium implants allows osseointegration in dog. Results have to be validated in human clinical study.

078	Poster – Topic Implant Aesthetics
-----	-----------------------------------

Esthetic evaluation of implant overdentures: case series

**Presenter:** Artunc C

*Ege University, School of Dentistry, Izmir, Turkey*

**Co-authors:** Artunc C<sup>1</sup>, Tekin U<sup>2</sup>, Dundar M<sup>1</sup>, Gungor MA<sup>1</sup>

<sup>1</sup>*Department of Prosthodontics, School of Dentistry, Ege University, Izmir, Turkey,* <sup>2</sup>*Department of Oral and Maxillofacial Surgery, School of Dentistry, Ege University, Izmir, Turkey*

**Background and aim:** Smile line design, quality and quantity of the hard and soft tissues and early and non-traumatic surgery are parameters affecting the esthetic outcome of complicated cases

treated with implant -supported overdentures. The aim of this study was to describe the esthetic restoration of edentulous patients by using advanced surgical and prosthetic management.

**Materials and methods:** Factors influencing the final esthetics of the implant-supported overdentures in esthetically compromised situations have been described in this clinical report through (Bego-Semados, Straumann) implant rehabilitation.

**Results:** Cases were treated with implant overdentures using different bar and retentive anchor (Locator) designs to restore esthetic and functional deficiencies. Advanced surgical techniques for soft and hard tissue management.

**Conclusion:** Implant localization, framework material, retentive system type, natural appearance and morphology of the prostheses are significant factors related with the esthetic outcome of the implant -supported overdentures.

079 | Poster – Topic Implant Aesthetics

### Immediate implant placement in a fresh socket in the aesthetic area: surgical approach and long-term evaluation

**Presenter: Lenzi CC**

*Dentist, Private Practice, Bologna, Italy*

**Co-authors: Lenzi CC**

*Private Practice, Bologna, Italy*

**Background and aim:** The immediate implant placement in a fresh socket after tooth extraction is considered a reliable therapeutic procedure and it presents the advantage of having a considering amount of native bone. This technique also reduces the number of surgical procedures and the overall treatment time, obtaining the patient's approval and satisfaction. The anterior aesthetic area is considered critical to treat: in fact it is of paramount importance to obtain an hard and soft tissue stability in order to obtain long -term biological and aesthetic success. Clinical studies showed that in several situations the technique here reported is applicable also in the aesthetic area and if exclusion criteria are respected, the results obtained can be predictable. These two case reports show the replacement of a single incisor lost for a trauma in patients with two different biotypes.

**Materials and methods:** After a minimally traumatic extraction of the tooth, a different surgical approach was used, depending on the presence of thin or thick gingiva and on the residual volume of buccal plate. In the case with thick biotype the buccal bone was preserved and the soft tissues were in good conditions, so after the extraction an immediate loaded implant was placed without filling the gap. In the case with thin biotype, the tooth was extracted for a vertical fracture and bone loss in the buccal plate occurred, thus in this case an integration with GBR techniques and the use of biomaterials were necessary to fill the buccal gap. Good primary stability of the implant and a non-functional load were achieved in both cases.

**Conclusion:** The follow-up after 24 months, performed by clinical and radiographic evaluation, shows that the post -extractive implant with immediate non -functional load can be used in selected cases; the results obtained are good in both thin and thick biotype

cases and it seem evident that a predictable long -term functional and aesthetic success is possible to obtain.

080 | Poster – Topic Implant Aesthetics

### Contribution of mesostructures to compromised esthetics due to insufficient bone quantity: case series

**Presenter: Comlekoglu E**

*Ege University, School of Dentistry, Izmir, Turkey*

**Co-authors: Comlekoglu E<sup>1</sup>, Sezer B<sup>2</sup>, Gunbay T<sup>2</sup>, Parlar A<sup>1</sup>**

*<sup>1</sup>Department of Prosthodontics, School of Dentistry, Ege University, Izmir, Turkey, <sup>2</sup>Department of Oral and Maxillofacial Surgery, School of Dentistry, Ege University, Izmir, Turkey*

**Background and aim:** Vertical and horizontal quantity of the hard and soft tissues with early and non-traumatic surgery are is an important parameter affecting the esthetic outcome of complicated cases treated with implant -supported dentures. The aim of this study was to describe the esthetic rehabilitation of three patients with vertical bone defects by using advanced prosthetic treatment.

**Materials and methods:** Three patients (age range: 38–54) each having an impacted maxillary canine tooth received surgical interventions for extraction. Immediately after extraction, dental implants (SLA-Straumann, Xive-Frialit) were placed through the alveolar ridge into the extraction sites ( $N=7$ ). The unfilled areas in the extraction sites, around the dental implants, were packed and covered with demineralized freeze-dried bone allograft in conjunction with a collagen membrane barrier. After 24 weeks of healing time, definitive implant-supported ceramometal fixed partial dentures were fabricated. Pink ceramic material infiltrated screw-retained mesostructures were applied to imitate gingival tissues. Metal–ceramic restorations were cemented onto these mesostructures.

**Results:** Six months after implantation, OPG revealed complete osseous fill of the extraction defects and no bone loss around the implants. Using a mesostructure veneered with pink porcelain restored the soft tissue loss and allowed to fabricate metal ceramic restorations with size and contours imitating the teeth and the gingiva. The esthetic result was acceptable for the patients.

**Conclusion:** Esthetic treatment outcome can be achieved by advanced prosthetic design for the patients with severe vertical bone defects despite the compromised clinical situation. Combining the implantation with bone augmentation preserved the alveolar bone and shortened the treatment period.

081 | Poster – Topic Implant Aesthetics

### Immediate implant placement without flap elevation in the maxillary esthetic zone

**Presenter: Akay M**

*Oral Surgery, Izmir, Turkey*

**Co-authors: Mert Z, Akay MC, Tekin U, Mert S**

*Oral Surgery, Izmir, Turkey*

**Background and aim:** Dental implants have become an accepted treatment modality for aging patients with either completely or

partially edentulous arches. Provisionalization of dental implants at placement has become more prominent in the field of implantology over the past several years, especially in the esthetic zone. The benefits of this treatment option include immediate tooth replacement, formation and maintenance of esthetic soft-tissue contours, containment for bone-grafting and tissue-regenerative procedures, and an improved sense of the patient's perception of the implant process. The aim of this study is to assess soft tissue and esthetic outcomes at single-tooth immediate implants placed without flap elevation in maxillary esthetic zone.

**Materials and methods:** In this case report, a 32-year-old female treated by placing four dental implants in the extraction socket is presented. After extraction of maxillary right canine, lateral and left central, lateral and canine teeth, implants were placed immediately. Implants and bone grafts were covered with a resorbable collagen membrane. Following a healing period of 16 weeks, final definitive ceramometal restorations were delivered to the patient.

**Results:** All four immediate implants osseointegrated uneventfully with no complications and all implants were successfully restored. Implants were stable and successful at the 12- and 24-month post-restoration evaluations.

**Conclusion:** Immediate implantation decreased the recession of the marginal mucosa that may compromise the esthetic appearance of the maxillary anterior restorations. Flapless approach showed lesser crestal bone height reduction. However, additional clinical and experimental studies are needed to provide guidelines for predictable esthetic outcomes.

082	Poster – Topic Implant Aesthetics
-----	-----------------------------------

### Soft tissue healing around zirconia abutments: clinical case presentation

**Presenter: Mõttus M**

*CityMed Institute, Tallinn, Estonia*

**Co-authors: Mõttus M, Mõttus E**

*CityMed Institute, Tallinn, Estonia*

**Background and aim:** Long-term functional and esthetic success with implant-supported restorations include many important parameters: the initial clinical situation, the surgical approach (guided surgery, implant design selection), the healing and provisional phase, and the choice of the abutment material and design as well as the definitive restoration. Patients with zirconia abutments seem to have more stable soft tissue volume and regain some soft tissue around zirconia abutments. It can then be assumed that zirconia abutments and full-ceramic restorations can give more stable long-term aesthetic outcome. This clinical case presents the main aspects of current treatment and discuss material options and clinical techniques to achieve predictable outcomes. *The aim* of this case was to evaluate the clinical performance of soft tissue around zirconia abutments and full-ceramic crowns.

**Materials and methods:** Four study implants (NobelReplace, NobelBiocare, Sweden) were inserted in posterior maxilla by using surgical guide (NobelGuide, NobelBiocare). Early loading (14 days later) of the implants was performed by using Procera CAD/CAM manufactured individualized zirconia abutments

(Nobel Biocare) and e.Max full-ceramic bridge (Ivoclar Vivadent, Germany). Soft tissue volume was measured and parallel X-rays were taken in study implants at the base line and 1 year later.

**Results:** All case abutments exhibited increased 'gingiva growing' up to 2 mm after 1 year of abutment connection and restoration placement.

**Conclusion:** The soft tissue volume seem to have 'growing' potential around zirconia abutments and full-ceramic crowns using early loading protocol. More scientific studies is needed to show the biological potential of the zirconia abutments and full-ceramic crowns.

083	Poster – Topic Implant Aesthetics
-----	-----------------------------------

### Multidisciplinary approach in oral rehabilitation of patients with ectodermal dysplasia

**Presenter: Tomas J**

*FMED Coimbra University, Sta Comba Dão, Portugal*

**Co-authors: Tomaz J, Tondela JP, Dias R, Oliveira R, Sampaio N, Angelo A, Nicolau P**

*Coimbra University, Coimbra, Portugal*

**Background and aim:** Ectodermal dysplasia (ED) is a group of hereditary disorders involving tissues and structures derived from the embryonic ectoderm. They are characterized by the presence of abnormalities at birth. Various forms exist, including anhidrotic and hidrotic dysplasias, focal dermal hypoplasia and aplasia cutis congénita. They are generally nonprogressive and diffuse characterized by a lack or scarcity of hair, teeth, nails and eccrine sweat glands. Intraorally, common findings are anodontia or hypodontia, conical teeth and generalized spacing. The treatment of such patients requires early treatment with a multidisciplinary team composed of a pediatric dentist, a prosthodontist, an orthodontist, and oral and maxillofacial surgeons to ensure proper treatment of ED patients. In this presentation, the authors describe the experience of multidisciplinary rehabilitation of patients with ED in the Dentistry Department of Coimbra University.

084	Poster – Topic Implant Aesthetics
-----	-----------------------------------

### Reconstruction of avulsive maxillary defects using dental implants in growing child

**Presenter: Kim HS**

*Chung-Ang Medical Center, Seoul, Korea,*

**Co-authors: Kim HS<sup>1</sup>, Chung EM<sup>2</sup>, Choi YJ<sup>1</sup>, Yun KI<sup>1</sup>**

<sup>1</sup>*Chung-Ang Medical Center, Oral and Maxillofacial Surgery, Seoul, Korea,* <sup>2</sup>*Chung-Ang Medical Center, Prosthodontics, Seoul, Korea*

**Background and aim:** Maxillofacial trauma may destroy large areas of the dentoalveolar process and underlying structures, resulting in the loss of bone and teeth. These may create defects that are challenging to restore.

**Materials and methods:** Twelve-year-old child was referred to our hospital for reconstruction of maxillary defect. Iliac bone was harvested as two-staged method during 2 years and dental implants were placed at 6 months following the second bone

graft. Fixed-type implant prosthetic treatment was completed with double casting abutment at the age of 15 years.

**Results:** Avulsive maxillary defect was successfully treated using dental implant after free tissue transfer in growing child in our hospital.

**Conclusion:** Placement of a dental implant may be the treatment available for a growing child if little or no further restriction can be expected, to be inserted by dental implants placed into the ablative defect, and there are functional and psychosocial problems.

085	Poster – Topic Implant Aesthetics
-----	-----------------------------------

## Rehabilitation of a bruxism patient with dental implants: case report

**Presenter: Brkic A**

*Faculty of Dentistry, Istanbul University, Istanbul, Turkey*

**Co-authors:** Brkic A<sup>1</sup>, Eyupoğlu E<sup>1</sup>, Koçak-Berberoglu H<sup>1</sup>, Gürkan-Köseoglu B<sup>1</sup>, Özcan<sup>2</sup>

<sup>1</sup>Department of Oral Surgery, Faculty of Dentistry, University of Istanbul, Istanbul, Turkey, <sup>2</sup>Department of Oral Diagnosis and Radiology, Faculty of Dentistry, University of Istanbul, Istanbul, Turkey

**Background and aim:** Bruxism is a parafunctional activity characterized by day time and/or sleep-related teeth grinding or clenching caused with strong rhythmic contractions of masticatory muscles. The overloading influence of bruxism on implant and surrounding structures yields a higher risk of biological and biomechanical complications during physiological masticatory activities. Bruxism can cause excessive occlusal load of dental implants and their suprastructures, resulting in bone loss around the implants or even the implant failure. The aim of this case report is to present a case of prosthetic rehabilitation with dental implants in a patient with bruxing habits, who is followed -up for 5 years without any complications.

**Materials and methods:** In May 2004, a 50-year-old man patient referred to our department seeking a suitable prosthetic rehabilitation with dental implants in the left side of lower jaw, to improve his aesthetics and oral functions. Patient's health history and clinical examinations revealed the presence of bruxism. Two weeks before surgical procedure, 'Paraflex' (Chlorzoxane 250mg) tablets were prescribed, to alleviate the presence of myofascial pain. The surgery was done under local anesthesia, following the routine oral implant protocol. There were used (Dentsply Friadent XIVE S plus) implants with lengths of 11 and diameters of 3.8 and 4.5 mm, which were respectively placed at the former element sides of second premolar and second molar tooth.

**Results:** In the period of almost 5 years follow-up, there were no complaints or complications such as infection, occlusal load of implants and their suprastructures, bone loss around the implants or the implant failure.

**Conclusion:** For successful therapy, the influence of bruxism must be reduced by using proper number, dimension and design of dental implants, design of the occlusion, articulation

patterns and the protection of the final result with occlusal stabilization splint (night guard).

086	Poster – Topic Implant Aesthetics
-----	-----------------------------------

## Immediate implant placement and provisionalization after tooth extraction in the esthetic zone: surgical and prosthodontic protocols

**Presenter: Albert B**

*Universitat Internacional de Catalunya, Girona, Spain*

**Co-authors:** Barroso A, Altuna P, Cabratosa J

*Universitat Internacional de Catalunya, Barcelona, Spain*

**Background and aim:** Nowadays patient demands are focused in the rapidness and effectiveness of the dental treatment from the first day. Following the established protocols and making an accurate treatment plan we can provide these benefits to the patient. Focusing in implant dentistry we can think of immediate implant installation after tooth extraction and moreover, immediate function of these implants. We know by literature that this kind of protocols can be of a great benefit for the patients and that by making a good selection of the case and good planification can be as safe as the delayed protocols.

**Materials and methods:** The patient is a 35-year-old healthy female who came to our dental office presenting inappropriate provisional restorations on the upper incisors. In the clinical examination, we observed a fixed partial denture on 1.2, 1.1, 2.1 and 2.2. The teeth supporting these prostheses were not appropriate due to decay and insufficient healthy dental structure remaining and the colour. Once the extractions of the two central and lateral upper root incisors were done and after examining the integrity of the walls of the sockets, two implants were immediately placed in the position of 1.1 and 2.2. Socket preservation was done where implant were not placed (1.2 and 2.1). The size of the two implants was 4.3 × 16 mm. Following the literature, we wanted to reach an insertion torque greater than 30 Ncm to permit immediate function of the implants. The implants were immediately loaded following Gallucci's protocol and avoiding any contact in centric and excentric mandibular movements.

**Results:** There are several loading protocols in modern implant dentistry and in this case we followed the immediate loading protocol published by Gallucci. It consists of fixing a resin partial denture to the implants using temporary immediate loading abutments. Applying this protocol we achieve very satisfactory results in terms of aesthetics and satisfaction of the patient during the osseointegration of the implants.

**Conclusion:** An immediate fixed provisionalization of the implants in the aesthetic zone can be of a great benefit for patient expectations. By the day there is sufficient scientific evidence that supports the immediate function of the implants. Although it is very important to make an accurate selection of the case and controlling all the parameters that could make the case go wrong.

## Nine year clinical evaluation of short dental implants placed in posterior areas

**Presenter:** Anitua E

*Private practice in implantology and oral rehabilitation in Vitoria, Spain, Vitoria, Spain*

**Co-authors:** Anitua E<sup>1</sup>, Orive G<sup>1</sup>

*Private Practice in Implantology and Oral Rehabilitation, Vitoria, Spain*

**Background and aim:** The aims of this study were to evaluate the long-term survival rates of short dental implants (short BTI implants, Biotechnology Institute BTI, Vitoria, Spain) humidified with plasma rich in growth factors and to analyze the influence of different items on implant survival.

**Materials and methods:** A retrospective cohort study design was used. Seven hundred and forty patients received 1577 short implants in the posterior areas during the years of 2001–2009 in Vitoria, Spain. All implant installations were performed by two experienced surgeons and rehabilitations were done by three prostodontists. Each implant failure was carefully analyzed. The potential influence of demographic factors, clinical factors, surgery-depending factors and prosthetic variables on implant survival was studied. Implant survival was analyzed using a life-table analysis (Wilcoxon's test, Gehan).

**Results:** The overall survival rates of short implants were 99.2% and 98.4% for the implant and patient-based analysis, respectively. The mean follow-up period for the implants was  $39.7 \pm 26$  months. A total of 12 out from 1577 implants were lost during the observation period. None of the variables studied resulted to be statistically associated with implant failure due to the reduced number of failures.

**Conclusion:** Based on the results of the present study, treatment with short implants can be considered safe and predictable if used under strict clinical protocols.

## Immediate vs. one-stage restoration of small diameter implants in case of single missing maxillary lateral incisor: a 3 years randomized clinical trial

**Presenter:** Degidi M

*Private Practice, Bologna, Italy*

**Co-authors:** Degidi M<sup>1</sup>, Nardi D<sup>1</sup>, Piattelli A<sup>2</sup>

<sup>1</sup>Private Practice, Bologna, Italy, <sup>2</sup>Dental School, Chieti, Italy

**Background and aim:** The aim of this study was to compare the bone loss pattern and the soft tissue healing of the immediately vs. the one-stage loaded 3.0 mm diameter implant in case of single missing lateral maxillary incisor.

**Materials and methods:** Sixty patients with a missing lateral incisor in the maxilla were planned to be randomized to one of the treatments: 30 to the immediate restoration group and 30 to the one-stage healing group. All implants were placed in healed sites and had to be inserted with a torque of  $>25$  Ncm. The implants of the immediate restoration group were provided with a non-occluding temporary restoration at the day of surgery. Both groups received a full occluding final restorations 6 months

after surgery. Mean marginal bone loss, probing depth and bleeding on probing were assessed at 6, 12, 24 and 36 months follow-up examinations by a blinded assessor.

**Results:** A total of 60 3 mm diameter implant were placed in the period between July 2003 and February 2006, of which 27 (45%) in men and 33 (55%) in women. All implants osseointegrated and were clinically stable at the 6-month follow-up. No statistical differences were observed for either bleeding or plaque index. No implant fractures occurred. At the 36-month follow-up the accumulated mean marginal bone loss and probing depth were, respectively, 0.85 mm (SD=0.71) and 1.91 mm (SD=0.59) for the immediate loading group (n=30) and 0.75 mm (SD=0.63) and 2.27 mm (SD=0.81) for the one-stage group (n=30). There was no statistically significant difference ( $P>0.05$ ) for the tested outcome measures between the two procedures.

**Conclusion:** In the rehabilitation of a single missing lateral maxillary incisor no statistically significant difference was assessed between immediately vs. one-stage restored small diameter implants regarding mean marginal bone loss and pocket probing depth. The immediate restoration protocol with the use of 3.0 mm diameter implants proved to be a predictable treatment option if a strict clinical protocol is followed.

## Blood contamination of surgical tools and protective barriers during implant placement surgery

**Presenter:** Kashiwai N

*Tohoku University, Tokyo, Japan*

**Co-authors:** Kashiwai N, Tamazawa K, Shimauchi H

*Division of Periodontology and Endodontology, Tohoku University Graduate School of Dentistry, Sendai, Japan*

**Background and aim:** Infection control is a key factor for the successful implant placement surgery. For preventing the operator and assistants from transmission of infectious diseases, it is also important to avoid the blood exposure during the surgical procedure. However, little is known about the severity and extent of blood contamination on surgical tools and personal protect equipments (PPE) for assistants during the surgery. The remaining blood contamination of implant drills and the aerosolized blood attached on PPE of assistants were investigated in this study.

**Materials and methods:** Used surgical tools and PPE (face-shields and gowns) were collected after the implant surgery performed on 20 patients (6 males and 14 females). Blood residues was assessed by the following methods: (1) Test for blood contamination on implant drills (Straumann, Switzerland): Immediately after operation, cleaning with Ultrasonic cleaners (Morita Production, Japan), or Washer-disinfector (Getinge Disinfection, Sweden), the remaining blood was detected by Bioluminescent method for determination of adenosine triphosphate (ATP) (Kikkoman, Japan) (2) Test for aerosolized blood on face-shield (Yamamoto Kogaku, Japan) and sterile gown (Hogy Medical, Japan): PPE surfaces were wiped with cotton swab and the attached blood was detected by Distill method for determination of protein.

**Results:** The remaining blood on implant drills was significantly decreased during the washing/disinfection process; immediately after operation (mean = 6455 RLU, max.: 73494, min.: 129); after cleaning with Ultrasonic cleaner (mean = 154 RLU, max.: 569, min.: 6); after cleaning with Washer-disinfector (mean = 18.2, max.: 57, min.: 1), respectively. Aerosolized blood was detected from four face-shields and eight gowns of tested samples.

**Conclusion:** Bioluminescent method measuring ATP was found to be highly sensitive for detecting the blood residuals even after washing/disinfection procedures. The Washer-disinfector is also effective to remove blood contamination on surgical tools used for implant surgery. Aerosolized blood was detected from PPE worn by assistants, suggesting that they were also at risk of blood exposure during the surgery as well as operators. Therefore, our study emphasized that all assistants and operators should routinely use appropriate barrier precautions to prevent skin and mucous membrane exposure from the blood contamination.

#### 090 Poster – Topic Implant and Guided Surgery

A comparison of piezoelectric and Er:Yag laser osteotomy for harvesting intraoral bone grafts

**Presenter:** Stübinger S

*Competence Center for Applied Biotechnology and Molecular Medicine, Zurich, Switzerland*

**Co-authors:** Stübinger S<sup>1</sup>, Ghanaati S<sup>2</sup>, Landes C<sup>3</sup>, von Rechenberg B<sup>4</sup>, Kirkpatrick C<sup>2</sup>, Sader R<sup>3</sup>

<sup>1</sup>Competence Center for Applied Biotechnology and Molecular Medicine, Zürich, Switzerland, <sup>2</sup>Institute of Pathology, Mainz, Germany, <sup>3</sup>Department for Oral, Cranio-Maxillofacial and Facial Plastic Surgery, Frankfurt, Germany, <sup>4</sup>MSRU, Equine Hospital, Vetsuisse Faculty, Zürich, Switzerland

**Background and aim:** The aim of this study was to compare the surgical feasibility, benefits and limitations of piezoelectric and Er:YAG laser osteotomy for harvesting intraoral bone grafts from the chin region in humans.

**Materials and methods:** In 20 patients (12 females, 8 males) either a variable square pulse (VSP) Er:YAG laser (10) or a piezoelectric device (10) were used to harvest bone grafts from the symphyseal area. For the osteotomies, the Er:YAG laser was applied with a pulse energy of 1000 mJ, a pulse duration of 300 µs, and a frequency of 12 Hz (energy density 157 J/cm<sup>2</sup>). The spot size was 0.9 mm and the handpiece was kept at a distance of about 10 mm from the bone surface. The piezosurgery device was employed with power settings "bone" level 1–3 using OT2 and OT7 surgical tips. In addition to a clinical evaluation, a histological and ultrastructural [scanning electron microscopy (SEM)] evaluation of lasered bone surfaces as well as those obtained by the piezoelectric device were performed.

**Results:** All osteotomies could be performed without any thermal damage to the bone or surrounding soft tissue. Histologically, Er:YAG laser application left behind a 5- to 10-µm demarcation zone as a characteristic fingerprint. There was no osseous debris on the surface of the osteotomy gap. SEM analysis revealed a preservation of the osteocyte lacunae and demonstrated the absence of serious harmful effects of both

surgical osteotomy techniques on bone microstructures. Regarding precision and accuracy, piezoelectric cuts were more parallel and smooth. Cutting efficiencies were dependent on individual surgical, anatomical and technical issues. The missing depth control of the laser limited its usability for clinical applications. Owing to a free manual positioning of the laser beam in the non-contact mode, it was difficult to get a well-defined osteotomy line without irregularities on the surface.

**Conclusion:** In spite of some technical drawbacks contact-free laser osteotomy with a vibration reduced mechanical stress on bone and free cut geometry seems to be a reliable and advanced osteotomy technique which will have a major influence on general bone surgery in the future.

#### 091 Poster – Topic Implant and Guided Surgery

Baseline data from a multi centre study replacing single anterior tooth with narrow, 3 mm diameter, OsseoSpeed<sup>TM</sup> implants

**Presenter:** Galindo-Moreno P

*University of Granada, Granada, Spain*

**Galindo-Moreno P<sup>1</sup>, Nilsson P<sup>2</sup>, King P<sup>3</sup>, Becktor J<sup>4</sup>, Maiorana C<sup>5</sup>, Schramm A<sup>6</sup>**

<sup>1</sup>University of Granada, Granada, Spain, <sup>2</sup>Käkkirurgiska kliniken, Jönköping, Sweden, <sup>3</sup>Bristol Dental Hospital and School, Bristol, United Kingdom, <sup>4</sup>Specialtandlægerne, Hellerup, Denmark,

<sup>5</sup>University of Milan, Milan, Italy, <sup>6</sup>Bundeswehrkrankenhaus, Ulm, Germany

**Background and aim:** Early loading of anterior single narrow implants may not be considered as predictable and safe as placement of standard length implants due to less bone to implant surface and reduced mechanical strength compared to standard diameter implants. Still there is a clinical need for using narrow diameter implants, particularly in the anterior region. This study was designed to evaluate the clinical performance of the newly developed OsseoSpeed<sup>TM</sup> 3 mm implant.

**Materials and methods:** A six centre international study was designed. Subjects with a missing single tooth in positions 12, 22, 32, 31, 41 and 42 were recruited. Main inclusion criteria were 18–70 years of age, edentulous in the study area for at least 2 months and presence of natural tooth roots adjacent to the study implant. Main exclusion criteria were smoking more than 10 cigarettes per day and a health status that would not allow implant placement. Implants (OsseoSpeed<sup>TM</sup>, Astra Tech AB, Mölndal, Sweden) were loaded 6–10 weeks after installation. Implants used in the study were of 3 mm diameter and 11, 13 or 15 mm length. Primary variable in the study is implant survival 5 years after implant placement. Secondary variables are overall implant survival, implant success, implant stability, marginal bone level alterations, soft tissue status, gingival zenith score and safety. Study subjects will be followed 6 months after implant placement and then once yearly until 5 years after implant placement.

**Results:** The inclusion and treatment of study subjects is completed and all study subjects have entered the follow-up phase. The study population represents a wide variety of patients with respect to age, gender, cause of edentulism and smoking history.



Seventy-five subjects have been recruited, 14 subjects have carried out their 6 months visits without any complications.

**Conclusion:** Early results from this multi-center study indicates that treatment with OsseoSpeed™ 3 mm implant is a safe and reliable treatment option in situations where the space is limited.

092	Poster – Topic Implant and Guided Surgery
-----	---

### Clinical success rates of submerged and non-submerged implant placement

**Presenter:** Puisys A

*Vilnius Implantology Center, Vilnius, Lithuania*

**Co-authors:** Puisys A, Krukonis G, Grybauskas S, Linkevicius T, Vindasiute E, Vladimirovas E

*Vilnius Implantology Center Clinic, Vilnius, Lithuania*

**Background and aim:** There are two surgical approaches towards dental implant placement: a submerged, two-stage implant placement procedure and a nonsubmerged, one-stage procedure. Well-documented, long-term clinical studies have revealed that one stage surgery has good and predictable outcomes. Using nonsubmerged protocol patients spend less time in the office reducing the cost of the procedure. Moreover the implant healing period is reduced. However, many practitioners still prefer submerged implant placement. The aim of this study was to compare the success rates of single and two-stage implant placement performed in private practice.

**Materials and methods:** This retrospective research involved 738 patients who received 2147 implants during the period from 2006 to 2008 in Vilnius Implantology Center. In total 1330 (62%) of the implants were placed for 472 women and 817 (38%) for 266 men. The mean age was 45 years (varying from 17 to 76 years). From all amount, 1640 (76.4%) implants were placed in single stage and 507 (23.6%) in two-stage procedure. After appropriate healing time all implants were evaluated according to osseointegration success criteria. Thus, before loading 42 implants were replaced (27 one-stage and 15 two-stage implantation). Data were collected from computer data base and case histories and analyzed using SPSS 16.

**Results:** The total success rate was 98%. One stage implantation – 98.4%, two-stage implantation – 97%. Statistical analysis showed that there is no statistically significant difference between single and two-stage implantation success rate.

**Conclusion:** Our research showed that there is no statistically significant difference between single and two-stage implantation success rate before implant loading. A one-stage procedure might be preferable, as additional surgical intervention is avoided and healing period is reduced. However in some cases, when implants lack primary stability or are placed during bone augmentation procedures, two-stage procedure might be more adequate.

093	Poster – Topic Implant and Guided Surgery
-----	---

### CT-based evaluation of template (NOBELGUIDE®) guided implant positions: a prospective radiological study

**Presenter:** Vasak C

*Medical University Vienna, Vienna, Austria*

**Co-authors:** Vasak C, Watzak G, Strbac G, Gahleitner A, Watzek G, Zechner W

*Department of Oral Surgery, Medical University, Vienna, Austria*

**Background and aim:** The challenge of every complex implant supported prosthetic restoration is the connection of prosthetical and surgical planning. Treatment concepts for restorative-driven implant surgery were developed to enable sophisticated guided implant placement without any complications. The purpose of this study was the evaluation of the overall deviation in a clinical treatment situation to assess the possible impact on the treatment safety of computer assisted, template guided implantology.

**Materials and methods:** After computer aided planning (Procera® Software, Nobel Biocare, Sweden) 86 implants were placed in 18 partially or fully edentulous patients with the NobelGuide® treatment concept (NobelBiocare). On the basis of the merged preoperative and postoperative CT-scans (fusion) the deviations between the virtually planned and the actually placed implants were measured to assess the treatment safety.

**Results:** All patients underwent an uneventful one-stage implant surgery and were provided with healing abutments during conventional healing times of 2 months (lower jaw) and 3 months (upper jaw). The average linear deviation measured on implant shoulder was  $0.43 \pm 0.32$  mm for the mesio-distal direction and  $0.46 \pm 0.35$  mm for the oro-vestibular direction. The average measured deviations at the implant apices were  $0.59 \pm 0.44$  mm for the mesio-distal direction and  $0.7 \pm 0.49$  mm for the oro-vestibular direction. Additionally the average depth deviations along the z-axis were coronal  $0.53 \pm 0.38$  mm and apical  $0.52 \pm 0.42$  mm. The mean angular deviation between the proposed and the actual direction was  $3.53^\circ \pm 1.77^\circ$  with a maximum deviation of  $8.1^\circ$ .

**Conclusion:** The computer aided NobelGuide® template enables a guided flapless implant surgery. The study outcome of the NobelGuide® concept demonstrates those high-accuracy required for transferring complex preoperative planning into surgical reality.

094	Poster – Topic Implant and Guided Surgery
-----	---

### Conical vs. cylindrical implants in immediate loading cases: a controlled, split-mouth clinical study. Preliminary report

**Presenter:** Ortiz-Puigpelat O

*Universitat Internacional de Catalunya, Esplugas de Llobregat, Spain*

**Co-authors:** Ortiz-Puigpelat O, Torroella-Saura G, Cantó O, Alaejos F, Lluch A, Cabratosa J, Hernandez-Alfaro F, Ferres E

*Universitat Internacional de Catalunya, Barcelona, Spain*

**Background and aim:** Original implant design for Branemark implant system is a cylindrical shaped implant, and has been

used in implant dentistry for many decades. Recently, it has been demonstrated that conical implants contribute to achieve better primary stability, so its use for immediate loading can be recommended. However, there is a lack of clinical studies, that demonstrates the effectiveness of such design in immediate loading cases. The aim of the study was to evaluate the effect of two different designs, conical vs. cylindrical implants, on the primary stability of implants placed with an immediate loading protocol in edentulous mandibles to support a full arch fixed prostheses.

**Materials and methods:** A total of 10 patients (from the dental school of the Universitat Internacional de Catalunya) underwent implant surgery with an immediate loading protocol. All cases consisted in a complete fixed rehabilitation using four to six implants in the mandible. Patients have been treated with MIS implant system<sup>®</sup>. This study was split mouth, where the control site was: a cylindrical shape (Biocom<sup>®</sup> model) and the test group was: a conical shape (Seven<sup>®</sup> model). The distribution of both models were equal in the same patient and in the patient's sample. Bone quality was evaluated in each implant site. Resonance frequency analysis was performed to measure the primary stability of both groups at the time of implant placement and at 3 months after implant surgery. Also periapical X-rays were taken at implant placement, 1, 2, 3 and 6 months after surgery. Both implant designs have the same internal hexagon connection and same SLA surface. Length and diameter of implants were chosen according to bone availability. The definitive screw-retained prosthesis were placed after 3 months of implant surgery.

**Results:** Preliminary mean ISQ values for the control group (Biocom<sup>®</sup>) were: 72.6; mean ISQ values for the test group (Seven<sup>®</sup>) were: 72.8. ISQ and quality of bone was: for type I bone was 71.7, type II bone was 74.4, type III bone 70 and type IV 69.

**Conclusion:** Independent of the implant design, implants placed in good quality of bone, type II, showed higher ISQ values. Although implant design can play an important role in primary stability, in order to achieve implant success in immediate loading cases, patient's presenting anatomy and biology of the existing bone has to be understood and diagnosed by the clinician.

095 | Poster – Topic Implant and Guided Surgery

Conical vs. cylindrical implants in immediate loading cases. A controlled, split-mouth clinical study. Preliminary report

**Presenter:** Torroella Saura G

*Universitat Internacional de Catalunya, Barcelona, Spain*  
Co-authors: Torroella G, Ortiz O, Cantó O, Alaejos F, Lluch AM, Cabratosa J, Hernández-Alfaro F, Ferrés E

*Universitat Internacional de Catalunya, Barcelona, Spain*

**Background and aim:** Original implant design for Branemark implant system is a cylindrical-shaped implant, and has been used in implant dentistry for many decades. Recently, it has been demonstrated that conical implants contribute to achieve better primary stability, so its use for immediate loading can be recommended. However, there is a lack of clinical studies, that

demonstrates the effectiveness of such design in immediate loading cases. The aim of the study was to evaluate the effect of two different designs, conical vs. cylindrical implants, on the primary stability of implants placed with an immediate loading protocol in edentulous mandibles to support a full arch fixed prostheses.

**Materials and methods:** A total of 10 patients (from the dental school of the Universitat Internacional de Catalunya) underwent implant surgery with an immediate loading protocol. All cases consisted in a complete fixed rehabilitation using four to six implants in the mandible. Patients have been treated with MIS implant system<sup>®</sup>. This study was split mouth, where the control site was: a cylindrical shape (Biocom<sup>®</sup> model) and the test group was: a conical shape (Seven<sup>®</sup> model). The distribution of both models were equal in the same patient and in the patient's sample. Bone quality was evaluated in each implant site. Resonance Frequency Analysis was performed to measure the primary stability of both groups at the time of implant placement and at 3 months after implant surgery. Also periapical X-rays were taken at implant placement, 1, 2, 3 and 6 months after surgery. Both implant designs have the same internal hexagon connection and same SLA surface.

**Results:** Preliminary mean ISQ values for the control group (Biocom<sup>®</sup>) were: 72.6; mean ISQ values for the test group (Seven<sup>®</sup>) were: 72.8. ISQ and quality of bone was: for type I bone was 71.7, type II bone was 74.4, type III bone 70 and type IV 69.

**Conclusion:** Independent of the implant design, implants placed in good quality of bone, type II, showed higher ISQ values. Although implant design can play an important role in primary stability, in order to achieve implant success in immediate loading cases, patient's presenting anatomy and biology of the existing bone has to be understood and diagnosed by the clinician.

096 | Poster – Topic Implant and Guided Surgery

The effect of thick mucosa on peri-implant tissues: an experimental study in dogs

**Presenter:** Jeong S

*Yonsei University Wonju College of Medicine, Wonju, Korea*  
Co-authors: Jeong SM<sup>1</sup>, Choi BH<sup>2</sup>, Xuan F<sup>1</sup>, Lee DH<sup>1</sup>, Hsu KM<sup>1</sup>

<sup>1</sup>Yonsei University, Wonju, Korea, <sup>2</sup>Yonsei University, Seoul, Korea

**Background and aim:** Findings from animal studies have indicated that the implant–mucosal barrier consists of a junctional epithelium; 2 mm long and a connective tissue compartment about 1–1.5 mm high. It may be argued that different features develop in the implant–mucosal barrier when it is placed within the alveolar bone with thick mucosa. The aim of this study was to examine the influence of a thick mucosa on peri-implant tissue healing around dental implants.

**Materials and methods:** The bilateral fourthmandibular premolars and all maxillary premolars were removed in six mongrel dogs. On one side (test side) of the mandible, a standardized bone defect (8.0 mm in height) was created in the premolar region, whereas no defect was created on the other side (control side). After 3 months of healing, one implant was placed on each side

of the mandible; a long abutment (12 mm in height) was connected to the fixture on the bone defect side, whereas a normal abutment was connected to the fixture on the control side. After a healing period of 6 months, all dogs were sacrificed to evaluate peri-implant tissues.

**Results:** The height of the mucosa, the length of the junctional epithelium, and the height of the zone of connective tissue integration were significantly greater in the thick mucosa than in the normal mucosa ( $P < 0.05$ ). No significant difference was found between the control and test sides in the marginal level of bone-to-implant contact.

**Conclusion:** The junctional epithelium extended more apically in the thick mucosa than in the normal mucosa. However, additional marginal bone resorption was not observed at the thick mucosa sites.

097	Poster – Topic Implant and Guided Surgery
-----	---

### The osseointegration of the implant with poor primary stability: a canine study

**Presenter:** Kim KW

*School of Dentistry, Chosun University, Kwang-ju, Korea*

**Co-authors:** Kim KW, Lee JW, Kim HS, Jang HS, Kim BO  
*Chosun University, Gwang ju, Korea*

**Background and aim:** Osseointegration has a very important role in success of implantation. Osseointegration is a direct structural and functional connect on the interface of live bone and loaded implant. Especially Albrektsson et al. reported that essential conditions for osseointegration are delicate bone preparation to reduce the damage of bone tissue, initial stability, adequate loading during healing time, biocompatible materials, favorable surface form for bone deposition and tissue morphology on peri-implant. Among those factors, initial stability of implant is closely connected with osseointegration, so that it has to be concerned very carefully. This study evaluated the effect of poor primary stability on the osseointegration of implants.

**Materials and methods:** After 4 months teeth were extracted, implants were placed into the mandibular premolar areas of six adult mongrel dogs. To evaluate the initial healing response of bone around the implants without primary stability, implants with 3.3 mm diameter were inserted within 3.5 mm diameter bone hole at the premolar areas. In control group, implants with 3.3 mm diameter were inserted within 2.7 mm diameter at the premolar area. After the implants were inserted, the Periotest® value (PTV, Medizintechnik Gulden, Germany) to measure the primary stability and the histologic findings to observe the new bone formation were analyzed at 2, 4 and 8 weeks.

**Results:** The results showed that PTV of experimental group was higher than that of control group at implantation. But 8 weeks later, the PTV of experimental group was similar with control group. In histologic results, the less primary stability in implant was, the later osseointegration was occurred. Although primary stability was not obtained at initial placement, osseointegration was occurred at 8 weeks later. And the osseointegration of experimental group and control group was similar at 8 weeks later.

**Conclusion:** We evaluating the study in mobility and histologically, if implant with unfavorable initial stability was placed in two stages, favorable osseointegration was obtained with 8-week healing time. It is considered when favorable initial stability of implant could not be obtained in clinics, two-stage surgery with sufficient healing time would acquire osseointegrated implant. In the future, researches to improve osseointegration in placing the implant without initial stability will be required.

098	Poster – Topic Implant and Guided Surgery
-----	---

### Bone loss around immediately loaded implants in the edentulous jaw following computer-assisted virtual treatment planning and flapless surgery

**Presenter:** Komiyama A

*Karolinska Institutet, Huddinge, Sweden*

**Co-authors:** Komiyama A, Klinge B, Hultin M  
*Karolinska Institutet Huddinge Sweden*

**Background and aim:** Recently, a new treatment approach for dental implants has been developed, including a pre-treatment planning procedure based on three-dimensional (3D) computed tomography (CT) scan images. In this system, implants were inserted by the aid of a surgical template based on the 3D virtual treatment planning. A prefabricated suprastructure was immediately connected to the implants after surgery. Despite, positive results being presented in several reports, only a few studies have evaluated marginal bone loss. The aim of this study was to evaluate marginal bone loss around immediately loaded implants and fixed prosthesis after more than 1 year of function.

**Materials and methods:** Twenty-nine completely edentulous jaws (21 maxillae, 13 mandibles), consecutively treated according to Teeth-in-an-Hour™ (Nobel Biocare AB, Gothenburg, Sweden), were included. Patients' mean age at re-evaluation was 71.9 years (range: 44–92 years, males: 18, females: 11). A dental panorama was taken immediately after surgery and after > 1 year follow-up. Marginal bone level at distal and mesial fixture sites were assessed on the dental panorama and evaluated as the number of fixture threads counted from the most coronal thread to bone-to-fixture contact in all 29 cases. Additional intra-oral radiographs were also taken in 12 cases, both after surgery and at follow-up. On intraoral radiographs, marginal bone level was measured as the distance (mm) from the most coronal thread to the bone-to-fixture contact. Bone loss was evaluated by calculating the difference between the radiographs taken immediately after surgery and at follow-up.

**Results:** Owing to low resolution in the dental panorama, only 193/326 sites (59.2%) were included for evaluation. Mean marginal bone loss on the panorama was 1.3 threads (SD = 1.4) in the maxilla and 1.4 threads (SD = 2.0) in the mandible, estimated to -0.8 and -0.85 mm, respectively, using a distance of 0.6 mm between fixture threads. On the intraoral radiographs, 121/136 sites (89%) were readable. Mean marginal bone loss was -1.17 mm (SD = 1.22) in the maxilla and -1.37 (SD = 1.74) mm in the mandible.

**Conclusion:** The results showed that marginal bone loss around immediately loaded implants with prefabricated prosthesis was similar to that found in other studies on immediate

loading, and the two-stage surgical procedure according to the original Brånemark protocol. This study also indicated that a dental panorama is not a sufficient tool to evaluate marginal bone loss. Further long-term monitoring is required for evaluation of marginal bone condition following this new technique.

099 | Poster – Topic Implant and Guided Surgery

## Implant supported restorations in the edentulous maxilla: results and selected cases

**Presenter:** Platzner S

*University Dental Clinic, Medical University Graz, Graz, Austria*

**Co-authors:** Platzner S<sup>1</sup>, Heschl A<sup>1</sup>, Clar V<sup>1</sup>, Payer M<sup>2</sup>, Wegscheider W<sup>1</sup>, Lorenzoni M<sup>1</sup>

<sup>1</sup>Department of Prosthodontics (Prosthetics, Periodontology, Restorative Dentistry and Implantology, Graz, Austria, <sup>2</sup>Department of Oral Surgery and Radiology, Graz, Austria

**Background and aim:** Proper planning before implant placement and its exact intraoperative transfer are keys for successful implant supported rehabilitation of the edentulous maxilla. The purpose of this case series is to present different maxillary restorative concepts based on evaluation of alveolar bone morphology including 3D treatment planning and guided implant insertion.

**Materials and methods:** Between 1985 and 2009 158 patients who suffered from edentulous maxillas were treated with 1179 dental implants [XIVE 352, Frialit-2 660 and others (3i, Replace, Ankylos) 165] at the University Clinic of Dentistry and Maxillofacial Surgery, Graz. Six representative cases treated with six to eight implants and subsequently restored with removable and fixed prosthetic treatment concepts are presented.

**Results:** The presented cases showed stable implant integration and successful reconstruction of physiologic function and aesthetics. No implant failed in the presented cases. The overall survival rate of 97.3% after an observation time of 23 years indicates that implant supported rehabilitation of the edentulous maxilla with six to eight implants seems to be a feasible protocol for reconstructing physiologic function and aesthetics.

**Conclusion:** The long-term data demonstrate predictable results for implant-supported restoration of the edentulous maxilla. Further studies are needed to evaluate the number of implants and optimal restorative concepts for maxillary rehabilitation.

100 | Poster – Topic Implant and Guided Surgery

## Validation of a template guided treatment accuracy (NOBELGUIDE®). A prospective CT-based study with a novel validation software tool

**Presenter:** Vasak C

*Medical University Vienna, Vienna, Austria*

**Co-authors:** Vasak C, Watzak G, Illic D, Gahleitner A, Watzek G, Zechner W

*Department of Oral Surgery, Medical University Vienna, Vienna, Austria*

**Background and aim:** Template guided treatment concepts for restorative-driven implant surgery were developed to enable the transfer of complex prosthetic planning into the clinical situa-

tion. The possible deviations between the computer planned implant positions and the implant positions post-surgery are very important, especially when flapless surgery is applied. The purpose of this validation study was the evaluation of the overall deviation in a clinical treatment situation to assess the possible impact on the treatment safety of computer-assisted, template-guided implantology.

**Materials and methods:** After computer-aided planning (Procera Software, Nobel Biocare, Sweden) 86 implants were placed in 18 partially or fully edentulous patients with the NobelGuide® treatment concept (NobelBiocare, Sweden). On the basis of the merged preoperative and postoperative CT-scans (fusion) the deviations between the virtually planned and the actually placed implants were measured to assess the treatment safety.

**Results:** All patients underwent an uneventful one-stage implant surgery and were provided with healing abutments during conventional healing times of 2 months (lower jaw) and 3 months (upper jaw). The average deviation measured was  $1.19 \pm 0.5$  mm on implant shoulder and  $1.47 \pm 0.54$  mm on implant apex. Additionally the average depth deviation along the z-axis was  $0.42 \pm 0.7$  mm. The mean angular deviation between the proposed and the actual direction was  $3.42 \pm 1.73^\circ$  with a maximum deviation of  $8.19^\circ$ .

**Conclusion:** The computer-aided NobelGuide® template enables a guided flapless implantology. The NobelGuide® treatment concept seems to provide the required accuracy for transferring complex preoperative planning into surgical reality without any complications observed.

101 | Poster – Topic Implant and Guided Surgery

## Early dimensional variations at implant installed in fresh extraction sockets: radiographic evaluations performed by accuitomo

**Presenter:** Rossi F

*Private Practice, Bologna, Italy*

**Co-authors:** Fabio R<sup>1</sup>, Daniele B<sup>2</sup>, Piero R<sup>3</sup>, Claudio M<sup>3</sup>

<sup>1</sup>Private Practice, Bologna, Italy, <sup>2</sup>Ariminum Research and Dental Education, Rimini, Italy, <sup>3</sup>Reparto di Chirurgia Orale e Maxillofacciale, Dipartimento di Scienze Odontomatologiche, Università di Bologna, Bologna, Italy

**Background and aim:** The objectives of the present investigation is (i) to evaluate bone resorption after tooth extraction and immediate implant installation in a 4-month healing interval and (ii) to compare the outcomes of clinical measurement with those performed with intraoral X-rays and with a CBCT Accuitomo radiological instrument.

**Materials and methods:** The trial is designed as a prospective clinical study. All 12 patients received an implant Prevail (3i Implant Innovation Inc., Palm Beach Gardens, FL, USA). The implant was installed, submerged, in a fresh extraction socket. Clinical measurements of bone crest were performed during surgeries (implant installation T1 and re-entry T2). The patients underwent radiological examination using intraoral standardized X-rays and the Accuitomo apparatus, both immediately after the implant installation and at T2 (after 4 months of healing). The

following landmarks were considered for bone crest analysis: M (margin of the implant); B (most coronal bone to implant contact); C (top of the bone crest); OC1 (outer border of the bone crest, 1 mm below the bone crest) and only on radiographic images OCrx (outer border the bone crest, 3 mm apically to the implant margin).

**Results:** No implants failed. The total of patient drop-out was three (one for pregnancy, the other two refusing the second CT). Bone-to-implant gap existing at the moment of implant insertion was filled at re-entry with new-formed bone. The augmentation of bone to implant contact was at 6.23%. During 4 months of healing the buccal bone wall underwent marked changes:  $0.75 \pm 0.6$  mm of vertical resorption and reduction of thickness by  $1 \pm 0.5$  mm. The mesial, distal and palatal/lingual bone crests were absorbed at  $0.5 \pm 0.5$  mm.

**Conclusion:** The results proved the success of the implant installation in fresh extraction socket in the early healing period. The buccal bone resorption level was higher than the other bone aspects. The immediate implants do not limit the post-extractive resorption of alveolar bone.

102	Poster – Topic Implant and Guided Surgery
-----	---

### Immediate loading of mandibular short implants with a complete prosthesis: 191 cases 8 years report

**Presenter:** Chausse L

*Clinique d'implantologie dentaire Dr Luc Chausse, Beloeil, Canada*

**Background and aim:** Few studies have analysed the immediate or rapid loading of short implants in the anterior lower jaw. The aim of this prospective study is to report the results of the rehabilitation of patients presenting very much resorbed edentulous mandibles, with short titanium implants immediately loaded by a complete prosthesis.

**Materials and methods:** From June 2000 to February 2008, out of 1094 patients treated in our clinic with an immediately loaded implant-supported mandibular prosthesis, 191 received four short implants (8 or 9 mm of threaded length) in the interforamina region. Fixed prosthesis or 'U'-shaped bars and removable overdentures were delivered in 6–14 days after implants placement. The patients were restrained to a soft diet for 4 months. Clinical and panoramic evaluations were performed after 4 months.

**Results:** Of the 764 short implants used, 760 healed uneventfully and at the end of the observation period were clinically stables and asymptomatics. One patient lost three implants, one patient lost one implant. Integrated implants were showing normal peri-implant status, with no bleeding on gentle probing and no inflammation, except for occasional transient hygiene deficiencies from some patients. Mean marginal bone loss after 4 months is 0.1 mm. Mean loading time is 46 months (4–98 months). Survival rate was 99.4%, success rate according to Zarb and Albrektsson's criterias was 98.5%. These results shows that immediate loading of mandibular short implants with overdentures is a safe protocol, as long as the implants are installed in normal density bone of at least 8 mm height, and as long as a good primary stability is achieved. Most very resorbed mandibles present dense to very dense bone, hence the predictable results

of the technique. Great care must be exercise to avoid mandibular fracture. A maximum of 35–40 N cm insertion torque is recommended. Use of narrow implants (3.5 mm diameter) is recommended in very resorbed and very narrow jaws; all 116 used in this study healed uneventfully under rapid loading.

**Conclusion:** The simplicity, efficiency and safety of this protocol should make it the standard of care in the treatment of the very resorbed edentulous mandible. Avoidance of unnecessary invasive grafting, rapid stabilisation of the implants, controlled initial loading, more comfortable healing, immediate aesthetic and better treatment acceptance by the patients are the main advantages of this protocol.

103	Poster – Topic Implant and Guided Surgery
-----	---

### Peri-implant bone level around implants with platform-switched abutments: a prospective clinical study

**Presenter:** Fickl S

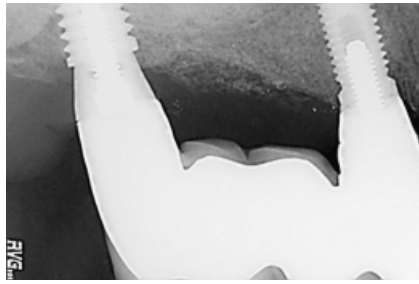
*New York University College of Dentistry, New York, USA*

**Co-authors:** Fickl S<sup>1</sup>, Zuhr O<sup>2</sup>, Stein J<sup>3</sup>, Hürzeler M<sup>2</sup>

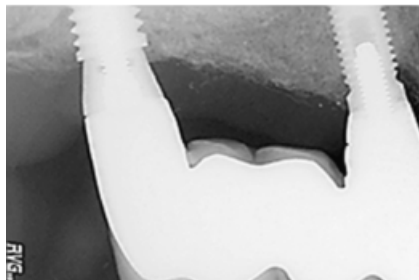

<sup>1</sup>Department of Periodontology and Implant Dentistry, New York University College of Dentistry, New York, NY, USA, <sup>2</sup>Institute for Periodontology and Implantology, Munich, Germany, <sup>3</sup>Department of Operative Dentistry, Periodontology and Preventive Dentistry, University Hospital (RWTH), Aachen, Germany

**Background and aim:** During the first year of loading particularly two-piece dental implants are frequently associated with post-restorative crestal bone level alterations of about 1–2 mm. This has been explained by an inflammatory cell infiltrate, which is located 1–1.5 mm adjacent to the implant–abutment junction (IAJ). The concept of platform-switching refers to the use of a smaller-diameter abutment on a larger-diameter implant collar. By placing smaller prosthetic components on the implant platform, the IAJ is moved inward from the implant shoulder and further away from the bone, shifting the inflammatory cell infiltrate to the central axis of the implant and away from the adjacent crestal bone. The purpose of this prospective clinical trial was to evaluate if the crestal bone height around dental implants could be influenced using a platform-switch protocol.

**Materials and methods:** Altogether 89 dental implants were placed in 39 patients. All implants were placed by the same surgeon and inserted into the healed ridge. All implants requiring additional bone augmentation were excluded from the study. The following groups were created: (i) wide diameter implants ( $n = 75$ ) were placed subcrestally and regular diameter cover screws were connected. (ii) Regular diameter implants ( $n = 14$ ) were placed epicrestally and regular diameter cover screws were connected. All implants were submerged. Second stage surgery and immediate connection of an implant-supported provisional were performed following 3 or 6 months of healing period depending on the location of the implant (mandible/maxilla). Standardized X-rays were obtained after insertion of the final prosthesis and at 1-year follow-up. Measurements were performed using digital image analysis.



**Results:** The implants with a platform-switch configuration exhibited statistically significant less bone loss at time of insertion of the final prosthesis ( $0.3 \pm 0.07$  vs.  $0.68 \pm 0.17$  mm;  $P < 0.05$ ) and at 1-year follow-up ( $0.39 \pm 0.07$  vs.  $1 \pm 0.22$  mm,  $P < 0.01$ ) when compared with the non-platform-switched implants. The mean crestal bone loss between insertion of prosthesis and 1-year follow-up were  $0.1 \pm 0.05$  mm for the platform-switched implants and  $0.23 \pm 0.18$  mm for the non-platform-switched implants respectively. When tested with a two-tailed *t*-test the differences were not statistically significant ( $P > 0.05$ ).



**Conclusion:** Platform-switching seems to limit crestal bone remodelling to a certain extent. This may particularly be beneficial in aesthetically demanding locations, in order to support soft tissue structures more effectively.

104 | Poster – Topic Implant and Guided Surgery

**Bactericide effect of vibrating ultra-sonic (Piezo-Surgery) tips. An in vitro study**

**Presenter:** Blus C

University of Cagliari, Torino, Italy

Co-authors: Blus C<sup>1</sup>, Szmukler-Moncler S<sup>2</sup>, Orrù G<sup>1</sup>, Denotti G<sup>1</sup>, Piras A<sup>1</sup>, Piras V<sup>1</sup>

<sup>1</sup>Department of OBL, University of Cagliari, Cagliari, Italy,

<sup>2</sup>University Paris 6, France, <sup>3</sup>University Cagliari, Cagliari, Italy

**Background and aim:** In 1973, Thacker published a paper suggesting the possibility of killing yeast cells in suspension with ultrasound. We hypothesized that, ultrasonic surgery devices also known

as piezo-surgery devices, might interfere with bacterial growth involved in infection by the virtue of the power of ultrasound waves and the generated cavitation. This paper reports on an *in vitro* experiment that was undertaken to verify the hypothesis set above.

**Materials and methods:** *Escherichia coli* bacteria at initial concentration of  $8 \times 10^6$  were treated in a special set sterile set up with a UBS (RESISTA, Omegna, Italy) device. The used tip was flat, corresponding to the bone scrapper tip. The power of the UBS varies from level 1 to 9. The first *in vitro* experiment consisted in varying the power of the device from 1 to 8 while maintaining the vibrating time constant at 20 s. The amount of surviving colonies after a 15-h incubation was measured as a function of the power delivered by the ultrasonic surgery device. After that, *Bacillus subtilis* was used at  $7 \times 10^6$ . This Gram-negative bacteria becomes Gram positive when the membrane is damaged. The experiment consisted in maintaining the power constant at level 6 (72 W) while time was increased from 20 to 160 s, each time doubling the previous exposure time to the ultrasonic vibration. The percentage of damaged cells was measured at each milestone to assess the bactericide effect of the generated vibration.

**Results:** The absorbed power of each arbitrary power level of the UBS device, from 1 to 8, was first measured; it varied from 13 to 84 W, reaching 90 W at level 9. The number of surviving colonies of *E. coli* decreased with the power. At level 1 (42 W), 66% of the colonies were not affected; at level 6 (72 W), 50% were not affected while at level 8 (84 W), 35% only of the colonies were not affected. In the second experiment, the *B. subtilis* Gram-negative bacteria turned into Gram positive, in addition to the reduction of Gram-negative coloration, the length of the bacteria was also reduced. After 20 s, less than half of the cells were damaged, after 40 and 80 s, there was not any statistical difference, at 160 s, 12% of the cells survived the ultrasound vibration and cavitation effect.

**Conclusion:** Confirming the set hypothesis, this paper shows for the first time that the vibration waves and cavitation effect generated by a piezo-surgery device can have a bactericide effect on various bacteria. The bactericide effect increased with the delivered power. A power of 72 W (level 6) was required to affect half of the bacteria colonies. Enhancing the power increased the bactericide effect. Simultaneously, increasing the ultrasound time also increased the bactericide effect. The further step is to investigate the ultrasound capacity to affect the biofilm on implants and to study the clinical relevance of this bactericide effect obtained in a relatively short time at a power of 72–90 W.

105 | Poster – Topic Implant and Guided Surgery

**Immediate loading of fixed protheses for the rehabilitation of the edentulous jaw: 1-year preliminary data of a prospective clinical study**

**Presenter:** Hinze M

Private Institute of Periodontology and Implantology, Munich, Germany

Co-authors: Hinze M, Bolz W, Zühr O, Wachtel H, Hürzeler M  
Private Institute of Periodontology and Implantology, Munich, Germany

**Background and aim:** A technique using tilted implants to avoid bone-augmentation procedures has been documented as a

means of restoring fully edentulous jaws while providing bone-driven implant placement and immediate loading (Krekmanov et al. 2000, Malo et al. 2003). Published clinical data indicate that immediately loaded tilted implants may achieve the same outcome as upright implants in both jaws with respect to survival rates and marginal bone resorption after 1 year (Capelli et al. 2007, Testori et al. 2008). The purpose of this prospective clinical trial was to evaluate the treatment outcome over up to 5 years for immediately loaded full-arch fixed prostheses supported by two axial and two tilted implants used to rehabilitate edentulous jaws.

**Materials and methods:** Thirty-seven patients were recruited for treatment with either mandibular or maxillary full-arch fixed prostheses supported by four implants. Within 24 h, the implants were immediately loaded with screw-retained full-arch all-acrylic resin provisional restorations. Definitive reconstructions were delivered 6 months post-implant placement. Complete full-arch prostheses were supported by metal frameworks combined with high-density acrylic resin. Follow-up visits were scheduled for 6 and 12 months after the initial prosthetic loading and then annually for up to 5 years. Digital radiographs were obtained immediately after surgery and at each follow-up visit. Marginal peri-implant bone levels were assessed using digital image analysis.

**Results:** The 1-year implant success rate was 96.0% for axially positioned implants and 94.6% for tilted implants. The success rate was 96.6% for the maxillary and 98.7% for the mandibular implants. The prosthetic success rate was 83.8%. One year post-loading, the mean values of marginal bone loss were  $0.82 \pm 0.31$  mm around the axially oriented implants and  $0.76 \pm 0.49$  mm around the tilted implants. When tested with the repeated measure ANOVA, no statistically significant difference in peri-implant bone loss around the axial and tilted implants was detected ( $P \leq 0.05$ ).

**Conclusion:** Preliminary data from this clinical trial show high implant-survival rates for immediately loaded full-arch prostheses supported by four implants. Immediate loading of tilted implants may be considered a viable treatment option for the rehabilitation of edentulous patients.

#### 106 | Poster – Topic Implant and Guided Surgery

Prospective study on the result of sinus floor augmentation with xenogenic bone and simultaneous implant placement in the severely resorbed posterior maxilla: consecutive 466 implants in 220 sinuses up to 6 years

**Presenter: Choi BK**

*University of Ulsan, Asan Medical Center, Seoul, Korea*  
Co-authors: Choi BK<sup>1</sup>, Kim JJ<sup>2</sup>, Cha HS<sup>1</sup>, Kim YJ<sup>1</sup>, Lee SH<sup>1</sup>, Jeon JH<sup>1</sup>, Kim MJ<sup>2</sup>, Ahn KM<sup>1</sup>

<sup>1</sup>University of Ulsan, Seoul, Korea, <sup>2</sup>Seoul National University, Seoul, Korea

**Background and aim:** The purpose of this prospective study was to evaluate the effect of residual bone height and other factors on survival and success rate of the implants simultaneously placed

into grafted sinus using only xenogenic bone when optimal initial stability was gained by careful planning and surgical techniques.

**Materials and methods:** A total of 182 healthy patients (average age:  $53.5 \pm 9.7$ ) underwent 220 sinus lifting through lateral approach and 466 simultaneous implant installation. Rough surfaced implant (Implantium) and only xenogenic bone was used. After second surgery, temporary prosthesis was used to perform progressive loading for average 3 months. Implants were divided into two groups according to residual alveolar bone (Group 1: 1–4 mm and Group 2: 5–8 mm). Statistical differences of success rate between groups were analyzed with  $\chi^2$  test. Cox' proportional hazard regression was employed to identify risk factors related to implant failure.

**Results:** The mean follow-up was  $43.9 \pm 14.5$  months. Of the 466 implants, 221 implants (47.8%) were Group 1 and 245 implants (52.2%) were Group 2. The cumulative survival rate was 98.0% (460/466). Fourteen implants were considered as failure and the cumulative success rate was 96.0% (452/466). There was no statistically significant difference in success rate between the two groups ( $P = 0.577$ ). However, significant differences were found in female ( $P = 0.027$ ) and smoker ( $P < 0.001$ ) groups.

**Conclusion:** Sinus lifting with simultaneous implant placement using only xenogenic bone graft could be used to treat atrophic maxilla in patients with minimal residual bone heights when initial stability can be obtained by using appropriately designed implants and careful surgical techniques.

#### 107 | Poster – Topic Implant and Guided Surgery

Immediate rehabilitation of edentulous jaws with fixed prostheses supported by implants placed into fresh extraction sockets and in healed sites: a 4-year clinical evaluation

**Presenter: Covani U**

*Department of Surgery, University of Pisa, Camaiore, Italy*

Co-authors: Covani U<sup>1</sup>, Alfonsi F<sup>2</sup>, Orlando B<sup>2</sup>, Barone A<sup>3</sup>

<sup>1</sup>Department of Surgery, University of Pisa, Pisa, Italy, <sup>2</sup>Versilia Hospital, Lido di Camaiore, Italy, <sup>3</sup>Department of Biophisic Medical and Dental Sciences and Technologies, University of Genova, Genova, Italy

**Background and aim:** Over the last two decades some of the original concepts have been reassessed to satisfy the patients' expectation for shorter rehabilitation time. To reduce comprehensive treatment duration, attention has been paid to timing of restoration. The aim of the present paper was to evaluate the treatment outcome with the rehabilitation of edentulous jaws by an immediately loaded full-arch screw-retained prosthesis supported by a combination of implants placed into fresh extraction sockets and implants inserted in healed sites after up to 4 years of function.

**Materials and methods:** At three study centers, 355 patients received a total of 2935 implants (1256 were placed immediately after extraction and 1679 were placed in healed sites). Immediately after surgical procedure, all patients received the temporary prosthetic reconstruction. Three months postsurgery, definitive metal-ceramic restorations were cemented on



abutments. Follow-up visits were performed for the assessment of clinical parameters.

**Results:** According to Kaplan–Meier method, the cumulative survival rate (CSR) was determined to be 95.9% at 4 years with 121 failures (46 immediate, for a CSR of 94.4% and 75 delayed, for a CSR of 96.4%). The CSR for implants in the maxilla was 95.4% whereas in the mandible was 96.3%. The lowest CSR was recorded for the 5.0-mm-wide implants (93.4%), while the 4.3-mm-wide implants had the highest CSR (98.4%).

**Conclusion:** The results of this study suggest that the rehabilitation of the edentulous maxilla and mandible by an immediate loaded prosthesis supported by immediate and delayed implants represents a viable alternative treatment to classic loading protocols. A relatively high CSR was found and, surprisingly, the low number of failures occurred in few patients, and consisted in the loss of all the adjacent implants splinted together to complete the full-arch rehabilitation. It seems to be critical to carefully check the occlusion of the provisional restoration over the initial healing period before finalize the definitive prosthodontic framework.

108	Poster – Topic Implant and Guided Surgery
-----	---

Immediate loading of implants with interim implant supported fixed prostheses in edentulous maxillae and mandibles: a 2-year prospective clinical and radiological follow-up on straumann slactive implants

**Presenter: Bergkvist G**

*Malmö University, Norrköping, Sweden*

**Co-authors: Bergkvist G<sup>1</sup>, Lindh C<sup>2</sup>, Sahlholm S<sup>3</sup>**

<sup>1</sup>Private Practice, Norrköping, Sweden, <sup>2</sup>Department of Oral

Radiology, Faculty of Odontology, Malmö University Malmö Sweden,

<sup>3</sup>Department of Oral and Maxillofacial Surgery, University Hospital, Linköping, Sweden

**Background and aim:** An increasing number of studies show that one-stage surgery and immediate loading of implants, in both edentulous mandibles and maxillae, is a treatment alternative with success rates comparable with two stage-surgery and conventional loading. Furthermore, the development of new implant surfaces has shortened the healing time after implant placement. Such a new surface texture is the sand-blasted, large-grit and acid-etched, active surface (SLActive). Using implants with a shortened healing period can presumably be advantageous when immediate loading implants. The aim of the study was to prospectively evaluate the survival rate of splinted and immediately loaded SLActive implants in edentulous mandibles and maxillae after 2 years of loading.

**Materials and methods:** Thirty-three patients (mean age 70 years) with 23 edentulous maxillae and 14 edentulous mandibles received five to six implants each in maxillae and four to five in mandibles. An implant-supported fixed interim prosthesis was connected and immediately loaded within 24 h after surgery. After a mean healing time of 15 weeks the patients received a permanent screw-retained implant supported fixed prosthesis. A total of 204 Straumann Standard Plus SLActive

implants were placed. Bone quality and jaw shape were classified according to Lekholm and Zarb (1985). Implant stability was measured with Resonance Frequency Analysis at placement, after 2, 4 and 8 weeks and at the 1 year follow-up. Implant rotational stability was measured with a torque control device at placement and after 1 year. Radiological examinations and assessments were made at implant installation and after 1 and 2 years.

**Results:** The mean marginal bone level at baseline for implants placed in maxillae was measured at a point 1.74 (SD 0.94) apical of the reference point (the implant shoulder) and in mandibles 1.73 (SD 1.23). Change in mean marginal bone level from baseline to the 1-year follow-up was 1.18 mm (SD 0.98) in maxillae and 1.15 (SD 1.23) in mandibles. For almost 80% of the implant surfaces marginal bone loss was  $\leq 1$  mm. The cumulative implant survival rate was 100% after 1 and 2 years of loading.

**Conclusion:** Within the limitations of the study Straumann Standard Plus SLActive implants – immediately loaded within 24 h in combination with interim fixed prostheses – had successful survival rates and was found to be a viable treatment alternative in edentulous mandibles and maxillae.

109	Poster – Topic Implant and Guided Surgery
-----	---

Appearance of lingual vascular foramina in the canine/premolar region of the mandible

**Presenter: Kawai T**

*Nippon Dental University, Tokyo, Japan*

**Co-authors: Kawai T, Asaumi R, Sato I, Yosue T**

*Nippon Dental University, Tokyo, Japan*

**Background and aim:** There are some reports of bleeding while installing implant fixture or after placement, although dental implant procedures for inter-foraminal region are considered relatively safe. These complications would be arisen when the mandibular lingual cortex is perforated, because of branches of arteries running through the lingual foramina (LF). By preventing the damage of these arteries, implant treatment would be safer. This study investigated the variations of the lingual foramina in the canine/premolar region of the mandible (LLF, lateral lingual foramina), using cone beam CT (CBCT) images. Also, macroscopic observations of dissected cadavers were performed to identify the arteries.

**Materials and methods:** The 60 Japanese dry mandibles were used. The CBCT (Alioth: Asahi Roentogen Industry, Kyoto, Japan) images were acquired after the menton and gonions of the dry mandibles were placed parallel to the floor. The frequency, location, and course of consecutive canal of LLF were evaluated from CBCT images. The intraosseous vessels of LLFs were identified from 25 cadavers.

**Results:** At least one (1–4) LF was observed in 38 dry mandibles; 19 unilaterally, and 19 bilaterally. Total number of LLFs was 66. The average height of LLF from the mandibular plane was 3.8 mm (SD 1.7 mm), and 9.7 mm (SD 2.3 mm) inferior from the mental foramen (MF). The mean vertical angle of the bony canal from the inferior mandibular plane was 27.5°, and mean horizontal angle from the tangential surface of the cortex was 22.6°. In cadaver study, 14 of the 25 mandibles presented at least

one LLF, with the total number of the LLF 22. Ten mandibles presented the LLF unilaterally, and four bilaterally. From dissection, the arteries could be identified in 19 LLFs; all of them were submental arteries which had anastomoses with incisal branch of inferior alveolar arteries.

**Conclusion:** In this study, LLFs excluding ones around mid-mandibles were observed in about 2/3 of all mandibles, and located about 10mm inferior to the MF. Intraosseous canals from LLF run slightly upward and anteriorly in the mandible. It is confirmed that they finally anastomosed with the incisal branch of inferior alveolar artery in the dissected cadavers. The possible injury of the vessels and the consecutive complication during implant surgery could be reduced by recognizing LF in the canine/premolar region of the mandible in the preoperative 3D imaging. The use of CBCT seemed to be critical to avoid complications.

#### 110 Poster – Topic Implant and Guided Surgery

Morphometric analysis of the alveolar bone of the maxillary anterior regions for immediate implant placement using micro-CT

**Presenter: Kim JH**

*Yonsei University College of Dentistry, Seoul, Korea*

**Co-authors: Kim JH, Han DH, Kim HJ**

*Yonsei University College of Dentistry, Seoul, Korea*

**Background and aim:** The purposes of this study were to elucidate the relationship between the maxillary incisor and canine roots and surrounding alveolar structures using the micro-CT images to verify the topography of the alveolar bones in jaws for the immediate implant placement. Furthermore, these results can provide the guideline in choosing the implant fixture which has proper diameter, length, location and drilling procedure to get the optimal primary stability, emergency profile and marginal gap, in ultimate prosthesis fabrication as well.

**Materials and methods:** Nineteen maxillae from 14 Korean cadavers (eight males, six females; mean age 58.3 years, five bilaterals and nine unilaterals) were used in this study. All specimens were scanned and reconstructed into a 3D structure using a micro-CT system (Skyscan 1076). The data were then digitized by the frame-grabber and transmitted to a computer with the tomographic reconstruction software and the projection image data were reconstructed to create 3D images and analyzed using a computer program. From the 3D images of the maxillary specimen, six categories of the measurement were made with image-analysis software.

**Results:** The thickness of the labial alveolar plate (0.41–1.11 mm) of the incisors and canine was thinner than that of the palatal aspect (0.55–10.05 mm). In the anterior maxilla region, the thickness of the labial alveolar plate increased to the level of the root apex. Especially, the labial alveolar plate of the canine showed remarkably thinner than those of the central and lateral incisor. The distance from the root apex to the outer alveolar bone surface on the labial aspect was 1.98 mm on central incisors, 2.08 mm on lateral incisors, 1.85 mm on canine.

All of the root apices were labially located near to the labial alveolar plate. With a reference of whole width of the alveolar bone at the level of each root apex, the root apex of the central incisor, lateral incisor and canine was located within labial 1/5 region.

**Conclusion:** In order to prevent damage and pressure on the thin labial bone and to leave a proper gap, the long axis of the drill during the drilling procedure in the maxillary anterior area should be parallel to the labial alveolar plate and drill apical 2/3–3/4 of the palatal wall. Also, directing the access hole slightly labial to the incisal edge is needed to prevent perforation of the labial alveolar plate. A tapered implant may be recommended to minimize this labial inclination.

#### 111 Poster – Topic Implant and Guided Surgery

A 3-year prospective multi-center study of marginal bone level and soft tissue health of a one-piece implant: a report of preliminary results

**Presenter: Russell B**

*University Associates in Dentistry, Chicago, IL, USA*

**Co-authors: Baer R<sup>1</sup>, Clark P<sup>2</sup>, Medley M<sup>3</sup>, Shanaman R<sup>4</sup>**

*<sup>1</sup>University Associates of Dentistry, Chicago, IL, USA, <sup>2</sup>Paul Clark, USA, <sup>3</sup>Michael Medley, USA, <sup>4</sup>Richard Shanaman, USA*

**Background and aim:** A one-piece implant, (NobelDirect<sup>®</sup>; Nobel Biocare) with the body of the implant and the integral abutment machined out of a single piece of titanium has been assessed in this study. The implants incorporate a groove at the implant thread along the entire length of the intraosseous portion of the implant. An anodically oxidized surface (TiU-nite<sup>®</sup>) extends through the soft tissue penetrating part. The aim of the study was to evaluate the long-term stability of the biological complex surrounding the implant, to determine the clinical efficacy of the implant design and placement technique.

**Materials and methods:** One hundred and fourteen implants restoring both single teeth and partially edentulous sites in 83 treated patients were included. Implants were inserted in healed and fresh extraction sites. A single stage procedure was used with immediate provisionalization within 24 h after surgery. The definitive prosthesis was delivered within 6 months of implant insertion. Marginal bone level was evaluated on radiographs made at implant insertion, 6-month follow-up, and annually thereafter. Radiographic evaluation has been performed by an independent radiologist. The reference point used was the lower corner of the cylindrical implant collar. The bone level coronal or apical to this point was recorded with positive or negative values, respectively. Presence of plaque and the soft tissue response were evaluated using modified indexes by Silness and Löe and papilla index by Jemt at the follow-up visits. The papilla index was determined at implant insertion with the provisional restoration in place.

**Results:** Sixty subjects with 86 implants have completed the 1-year follow up. Two implant failures, in two patients, occurred during the first 6 months resulting in cumulative survival rate of 98.2% (1 year). Two subjects withdrew from the study (three implants). The mean bone level at implant insertion, 6 months

and the 1-year follow-up was reported as 0.35 mm (SD 0.99,  $n=82$ ), -0.64 mm (SD 1.06,  $n=84$ ) and -0.63 mm (SD 1.16,  $n=80$ ), respectively. The mean change in bone level from 6 months to 1 year was -0.03 mm (SD 1.02,  $n=77$ ). Normal peri-implant mucosa and no visible plaque were observed in majority of the implants.

**Conclusion:** At this stage, the implant survival rate, the stable marginal bone level and soft tissue health indicate that the one-piece implant tested has the ability to preserve both hard and soft tissue architecture.

**Acknowledgement:** This study has been supported by Nobel Biocare Services AG, Study code: T-128.

## 112 Poster – Topic Implant and Guided Surgery

The effects of loading time on osseointegration and new bone formation around dental implants: a histological and histomorphometrical study in dogs

**Presenter:** Ghanavati F

Newcastle General Hospital, Newcastle Upon Tyne, UK  
Co-authors: Ghanavati F<sup>1</sup>, Ghanavati F<sup>2</sup>

<sup>1</sup>Oral and Maxillofacial Surgery Department, Newcastle General Hospital, Newcastle Upon Tyne, UK, <sup>2</sup>Iran Centre for Dental Research, Tehran, Iran

**Background and aim:** Immediate loading of dental implants has been introduced as a method of reducing implant treatment time without compromising its prognosis. In this research, the effects of loading time on the amount of bone-to-implant contact and bone formation around dental implants were evaluated histologically.

**Materials and methods:** Three months before implantation, the lower premolar teeth of 15 dogs were extracted. Three or four dental implants were placed in the healed extraction sites for each dog ( $N=48$ ). Dividing the dogs into three groups, the implants were either loaded 48 hours or 1 week later with metallic or prefabricated acrylic crowns or were left unloaded until the time of sacrifice. Three months after implant insertion, the animals were sacrificed and samples were investigated to define the amount of bone-to-implant contact, lamellar and woven bone percentage, and local inflammation of the newly formed bone.

**Results:** No significant difference in the observed criteria was reported among the three groups ( $P>0.05$ ); however, the unloaded group had the highest degree of bone-to-implant contact and the group loaded 48 h after the primary implant insertion had the least. The prosthesis type had no significant effect on the implant success rate ( $P>0.05$ ). The lamellar and woven bone percentage of newly formed bone also did not differ in the three groups ( $P>0.05$ ). One implant from each group failed in this study.

**Conclusion:** Loading time does not seem to significantly affect the degree of osseointegration and bone-to-implant contact and the composition of newly formed bone around dental implants.

## 113 Poster – Topic Implant and Guided Surgery

Clinical benefits, risks and accuracy of cone beam CT based guided implant placement

**Presenter:** Abboud M

University of Bonn, Bonn, Germany

Co-authors: Abboud M, Wahl G

University of Bonn, Bonn, Germany

**Background and aim:** The aim of this study is to analyse the benefits, risks and accuracy of Cone Beam Dental CT (CBCT) based implant planning and guided implant placement. Next to an *in vivo* study showing clinical cases with guided surgery and immediate loading of the implants, an *in vitro* analysis has been added to evaluate the theoretical accuracy of the CBCT technology.

**Materials and methods:** In the clinical study, implants are placed with a stereolithographic drill guide to the planned location with immediate provisionalization after CBCT-based implant planning with the SimPlant software (Materialise, Leuven/Belgium). A prefabricated provisional restoration is placed at the day of surgery. The function and esthetic of the restoration is evaluated based on clinical criteria. Periotest (Gulden Medizintechnik, Modautal/Germany) measurements and radiographs have been taken at baseline, 6 and 12 months postoperatively. Furthermore the accuracy of the CBCT scan (Morita Accuitomo, J. Morita MFG. Corp., Kyoto, Japan; Sirona Galileos, Bensheim, Germany; Koadak 9000 3D, Rochester, USA) is shown *in vitro* on a model and compared with a conventional CT (Philips Brilliance 64, Amsterdam, the Netherlands). Prefabricated highly precise geometric models and anatomic bone and teeth structures are scanned and evaluated.

**Results:** Twenty-five implants have been placed and immediately loaded within 2 years. The mean change in cortical bone level after 12 months is -0.1 mm. Only minor differences in Periotest measurements occurred. Implant placement after virtual planning of implant positions using CT data and surgical templates is reliable for preoperative assessment of implant size, position, and anatomical complications. Immediate loading with prefabricated restorations in combination with passive cementation in the mouth of the patient is significantly better regarding function and esthetics. The model experiment showed an overall maximum deviation of >2.5 mm for the CBCT scans. The human bone measurements were within <0.8 mm, but 87% of the scanned geometric objects showed deviations of >1.3 mm. The CT scans were highly precise for the geometric objects and the human bone and teeth structures. The maximum deviation was under 0.15 mm.

**Conclusion:** The probability for a successful operation with a CT/CBCT-based implant planning and guided surgery seems to be increased due to a thorough knowledge of anatomy. The function and esthetic of the prefabricated provisional restoration can be significantly enhanced by CT-guided implant insertion. Based on this data a CT scan is highly recommendable. Still the results from the *in vitro* experiment indicate that there is room for improvement regarding the accuracy of CBCT scans.

## Evaluation of prognosis of re-implanted dental implants after removal of failed implants

**Presenter:** Lee HJ

*Seoul National University Bundang Hospital, Gyeonggi-do, Korea*

**Co-authors:** Hyo-Jung Lee L, Young-Kyun K, Pilyoung Y, Jin-Young P

*Snubh Gyeonggi-do, Korea*

### Background and aim:

**Objective:** The aim of this study is to evaluate the survival rate and surrounding tissue condition of re-implanted dental implants after removal of failed implants.

**Materials and methods:** We selected 49 patients (60 implants) who had experienced implant failure and re-implantation. We investigate used additional operation technique, used biomaterials, whether or not immediate implanted, complications after first implantation, the type of prosthesis used in the removed implants, healing time after re-implantation, whether or not immediate re-implanted, the survival rate of re-implanted dental implant, and crestal bone loss around implant and surrounding tissue conditions at the final recall time.

**Results:** The most failure of implant occurred in the maxillary first molar area. Used additional operations in the previously failed implants were bone added osteotome sinus floor elevation (22.0%), guided bone regeneration (16.9%), simple bone graft (10.2%) and sinus lateral approach technique (8.5%). The complications after first implantation were osseointegration failure (86.7%), peri-implantitis (5%) and infection (5%), etc. The failure types in the first implantation were divided into failure after loading (31.7%) and failure during healing (68.3%).

**Conclusion:** The most failure of implant occurred in the maxillary first molar area. We can improve the survival rate of re-implanted dental implant after removal of failed implant using additional implant fixture or various bone graft techniques.

## Stability development during healing of immediately loaded dental implants

**Presenter:** Simunek A

*Charles University in Prague, Faculty of Medicine in Hradec Kralove, Hradec Kralove, Czech Republic*

**Co-authors:** Simunek A<sup>1</sup>, Strnad J<sup>2</sup>, Kopecka D<sup>1</sup>, Brazda T<sup>1</sup>, Pilathadka S<sup>1</sup>, Chauhan R<sup>1</sup>, Slezak R<sup>1</sup>, Capek L<sup>3</sup>

<sup>1</sup>Department of Dentistry, Faculty of Medicine in Hradec Kralove, Charles University in Prague, Hradec Kralove, Czech Republic,

<sup>2</sup>Lasak Ltd., Prague, Czech Republic, <sup>3</sup>Department of Mechanical Engineering, Technical University of Liberec, Liberec, Czech Republic

**Background and aim:** To investigate the parameters that can affect the primary stability of dental implants, to find out, how the primary stability influences the post-healing stability and to ascertain the effect of primary stability and insertion parameters on marginal bone loss.

**Materials and methods:** In this study, total of 940 immediately functionally loaded implants in the mandibular interforaminal region were considered. Using the resonance frequency analysis, the primary stability (pISQ) and stability after 4 months (tISQ) were recorded. When the differences between tISQ and pISQ (DISQ) exceeded 5 U, then marginal bone loss was measured. The implants were distributed into three groups namely, high primary stability (pISQ > 72), low primary stability (pISQ < 68), moderate primary stability. The stability development after 4-month loading was evaluated. The relationship between pISQ, insertion torque, implant diameter, implant length, bone quality, and marginal bone loss was analysed. The Student's *t*-test, one-way ANOVA test and Spearman's non-parametric correlation coefficient were employed for statistical evaluation and defined at significant level  $P \leq 0.05$ .

**Results:** From 940 implants, tISQ was recorded in 526 implants and marginal bone loss was measured in 76 implants. There was no statistical significance between pISQ and final insertion torque. pISQ was influenced by the implant diameter but not by the implant length. There was high significant difference between implant insertion torque and bone quality. The low primary stability group significantly showed the increase in stability during healing phase (from ISQ of  $64.2 \pm 2.8$ – $66.8 \pm 5.0$ ,  $P < 0.001$ ). However, high primary stability implants demonstrated significant reduction in their stability (from  $75.9 \pm 2.6$  to  $72.0 \pm 5.0$ ,  $P < 0.001$ ). The linear regression analysis demonstrated that at pISQ of 69.2, tISQ value has just reached pISQ value. Furthermore, marginal bone loss was not significantly influenced by the pISQ value. Finally, the significant correlation was found between marginal bone loss and final insertion torque and between marginal bone loss and DISQ value.

**Conclusion:** This study demonstrated that: (a) The stability of immediately loaded implants with high primary stability significantly decreased, however, the stability of implants with low primary stability significantly increased during initial 4 months of healing. (b) Implants with primary stability 68–72 ISQ maintained their stability during healing phase. (c) DISQ and insertion torque showed significant correlation with marginal bone loss.

## Termical and voluminous bone effect comparison between ER-YAG laser and cortical drill: an experimental study

**Presenter:** Gabrić Pandurić D

*School of Dental Medicine, University of Zagreb, Zagreb, Croatia*

**Co-authors:** Gabrić Pandurić D<sup>1</sup>, Anić I<sup>2</sup>, Katanec D<sup>1</sup>, Žabkar J<sup>3</sup>, Ban T<sup>4</sup>, Kuna T<sup>1</sup>, Sušić M<sup>1</sup>

<sup>1</sup>Department of Oral Surgery, School of Dental Medicine, University of Zagreb, Zagreb, Croatia, <sup>2</sup>Department of Endodontics and Restorative Dentistry, School of Dental Medicine, University of Zagreb, Zagreb, Croatia, <sup>3</sup>Fotona d.d., Ljubljana, Slovenia, <sup>4</sup>Institute for Physics, Zagreb, Croatia

**Background and aim:** Mechanically rotating instruments such as drills or mills for bone treatment have the disadvantage of

damaging the surrounding bone by the generated frictional heat. Cooling of the instrument cannot avoid this damage completely. Laser systems are an alternative solution for bone removal. Areas of application for bone treatment laser systems are the dental implantology, bone surgery and osteotomy. The aim of presented experimental study was the comparison of temperature caused bone surface changes and removed bone volume after bone treatment with the Er-YAG laser and cortical drill.

**Materials and methods:** An experimental study was performed on the 10 pig ribs. Each rib was prepared with sagittal osteotomy to get two equal parts of the rib. Each part then was separated in equal plates. All plates had the similar thickness of cortical and spongy bone mutually. The idea was to simulate the height and the width of intraoral autologous bone blocks commonly used in bone management in dental implantology. Calibration of the laser parameters was done. Each plate was treated with the Er-YAG laser with a sapphire tip on a contra-angle hand piece with a 0.9 mm diameter glass fiber in a max mode (with 1000 mJ and 20 Hz) to make bone site within the full thickness of the plate. The other preparation was made next the previously prepared laser site with the 1.0 mm cortical drill, commonly used for the fixation screws preparations, at 40000 rpm with simultaneous saline irrigation. The drill rotation was higher to achieve the same level with calibrated lasers parameters.

**Results:** Surface termical changes were measured with infra-red camera in the whole interval of the bone exposure and preparation period. The removed bone volume for each exposure and preparation was calculated by modified mathematical algorithm. Time of the laser bone exposure was within the 15 s, and drill preparation within 60 s. The removed bone volume was higher in the laser group, and needed considerably less time, which resulted in minor termical surface changes (some amorphous surface tissue caused by the carbonization of bone during the laser exposure), in comparison with the cortical drill preparation usually caused by extended preparation time.

**Conclusion:** In comparison with the cortical drill preparation, the possibility of using Er-YAG laser in future clinical cases of bone surgery and dental implantology can be considered efficient without inducing irreversible bone damages.

117 | Poster – Topic Implant and Guided Surgery

## Clinical experience in cais: three guided surgery systems

**Presenter: Shibahara K**

*Private Practice, Kurume, Nagasaki, Japan*

**Co-authors: Shibahara K<sup>1</sup>, Tajima N<sup>2</sup>, Jimbo R<sup>3</sup>, Asahina I<sup>2</sup>**

<sup>1</sup>Private Practice, Kurume, Japan, <sup>2</sup>Regenerative Oral Surgery, Nagasaki University, Nagasaki, Japan, <sup>3</sup>Institute for Surgical Science, Department of Biomaterials, Goteborg University, Goteborg, Sweden

**Background and aim:** Computer-assisted implant surgery (CAIS) is extremely powerful tool to safely operate implant placement. We use three computer softwear to simulate implant placement to fabricate three types surgical guides, bone supported, mucosal supported and tooth supported. The aim of this study is to analyse the merits and demerits of computer-simulated surgical guides.

**Materials and methods:** We selected 21 sites of 17 patients in seven males and 10 females performed guided implant surgery, and checked computer softwear, guide supporting system, open-flap or flapless, immediate function and implant losts.

**Results:** Three computer softwares were used to simulate implant placement and to fabricate surgical guides, 10DR (10DR Co., Ltd., Osaka, Japan) in six cases, NobelGuide (Nobel Biocare, Sweden) in 11 cases and SimPlant (Materialise, Belgium) in four cases. We performed CAIS to placement total 105 implants, included 12 flapless surgery, nine immediate function. Total eight implants have lost, and all of them were mucosal supported-flapless surgery. The present clinical study suggest that CAIS might be useful in implant placement, especially in All-on-4 surgery. However, several problems were clear during mucosal supported-flapless surgery, for example, requirement a certain degree of mouth opening to insert surgical guide and burn of bone by insufficiency of water pouring.

118 | Poster – Topic Implant and Guided Surgery

## Conventional versus computer aided implantology: comparative evaluation of the prosthetic outcome

**Presenter: Karabuda ZC**

*Istanbul University, Faculty of Dentistry, Istanbul, Turkey*

**Co-authors: Arisan V, Karabuda ZC, Ahmet S**

*Department of Oral Implantology, Faculty of Dentistry, Istanbul University, Istanbul, Turkey*

**Background and aim:** Computer-aided implant surgery provides significant benefits for the patient and clinician. However, tangible benefits of computer-aided implantology with regards to prosthetic outcome are scarce when compared with classic implantology.

**Materials and methods:** Twelve maxillary total edentulous patients were included in this surgery. Implant planning was performed on six patients by the help of CT-driven images including the scan prosthesis. Implants were then placed using stereolitografhic guides (COM method). Implant planning and placement was performed following the planning on panoramic X-rays (PAN method) in remaining six patients. All implants were restored with metal-ceramic fixed prosthesis at the end of 6 months healing period and evaluated by an independent prosthodontist unaware of the mentioned groups. All implants were evaluated and scored as + and – for the following criteria; Invasion of any proximal teeth region by the implant, over-angulation of implant, paralleling to neighboring implants, accurate vestibule-lingual position. Results were then compared by Wilcoxon's signed rank test at a significance level of  $P < 0.05$ .

**Results:** A total of 72 implants were evaluated. Result of the scoring was as follows: invasion of interproximal region: 4 and 15 ( $P < 0.01$ ), over angulation of the implant: 8 and 13 ( $P < 0.08$ ), paralleling to neighboring implants: 29 and 15 ( $P < 0.03$ ), accurate vestibule-lingual position: 28 and 26 ( $P < 0.08$ ) for COM and PAN groups, respectively.

**Conclusion:** COM method involves additional steps which have to be undertaken prior to implant installation resulting with the increase of total chair time and treatment costs. However, present

results suggest that invasion of proximal region by the faulty positioned implants and improper implant paralleling may be avoided with the utilization of COM method. Computer aided implantology may prevent the occurrence of interproximally positioned and non-parallel implants which may compromise the esthetics and loading conditions of the final restoration.

## Immediate placement of implants following tooth extraction: 1–3 years clinical and radiographic study

**Presenter: Gisakis I**

*School of Dentistry, University of Athens, Larissa, Greece*

**Co-authors: Gisakis I, Kalyvas D**

*Department of Oral & Maxillofacial Surgery, School of Dentistry, University of Athens, Athens, Greece*

**Background and aim:** Ridge resorption proceeds quickly after tooth extraction and significantly reduces the possibility of placing implants without grafting procedures. Immediate implant placement after tooth extraction, in order to prevent bone resorption, is becoming a common procedure in implant-supported oral rehabilitation. The aim of this study was to evaluate the survival and success rates, along with the clinical and radiographic outcomes, associated with immediate implant placement, for a follow-up period of 1–3 years.

**Materials and methods:** Fourteen patients (10 men, four women), with no medical history, ranging in age from 30 to 66 years (mean 48.1), were selected for this study. A total of 37 implants were placed immediately after each failing tooth had been removed. After implant placement and achievement of primary stability, flaps were coronally repositioned and sutured allowing a transmucosal healing. In all cases, peri-implant marginal defects were treated according to the principles of GBR by means of deproteinized bovine bone mineral particles in conjunction with a bioresorbable collagen membrane. Distance between the alveolar crestal bone and the coronal aspect of the implant was measured at time of implant placement and at second stage surgery (SSS) (horizontal defect width, HDW). Standardized radiographs were obtained at baseline, at SSS and every 6 months thereafter. Changes in depth from the implant shoulder to the bottom of the defect (vertical defect depth, VDD) were assessed at mesial and distal implant sites.

**Results:** All implants healed uneventfully, yielding an osseointegration rate of 100%, and healthy soft tissue conditions at the time of SSS and thereafter. Twenty-six implants (70.3%) were placed in the maxilla and 11 (29.7%) in the mandible. Fifteen implants (40.5%) were placed in the anterior area, 12 (32.4%) in premolar region and 8 (21.6%) in molar region. HDW was (mean) 1.9 mm (SD: 1.16) at time of implant placement and 0.1 mm (SD: 0.1) at SSS, with the difference to be statistically significant ( $p < 0.001$ ). No important post-surgical complications were observed. Minor complications such as early wound exposure occurred in five cases (13.5%). Radiographically, mean VDD was 0–0.8 mm (SD: 0.26) at mesial sites and 0–0.7 mm (SD: 0.22) at distal sites, with the difference in crestal bone levels to be no statistically significant ( $p > 0.05$ ). There was no implant loss after loading.

**Conclusion:** The findings of this study showed that immediate implant placement represented a predictable treatment option for the replacement of failing teeth, with survival rates comparable to implants in healed ridges. Bone grafting significantly reduced horizontal resorption of buccal bone. In most patients marginal mucosa and bone levels remained stable following restoration. Implant osseointegration and survival rates were 100%.

## Sparing sufficiency strategy in dental implantology

**Presenter: Nikolsky V**

*Samara State Medical University, Samara, Russian Federation*

**Co-authors: Nikolsky V<sup>1</sup>, Maksyutov A<sup>3</sup>, Nikolskaya G<sup>2</sup>, Nikolskaya L<sup>2</sup>**

<sup>1</sup>Samara State Medical University, Samara, Russian Federation,

<sup>2</sup>Kirov (Vyatka) State Medical Academy, Kirov, <sup>3</sup>Moscow Dental Business Implant Training Center, Moscow, Russia

**Background and aim:** Sparing sufficiency strategy in dental implantology means to do quite enough for achieving good and long-lived results, but the treatment procedure must not to be too complicated, too long duration and too expensive. Really, a complication (complexity) leads to a complication (complicating circumstance). The aim of our study is to report the survival rate of short (8 mm) Pitt-Easy dental implants.

**Materials and methods:** The research design is 1–5-years randomized and multicenter clinical study, included 162 patients with 347 Pitt-Easy (Oraltronic, Sybron) dental implants. Implantation sites located in the posterior area. A types of bone were 1, 2, 3 and B, C, D (U. Lekholm and G. Zarb, 1985). All implants were submerged. Test: 94 patients and 162 implants 8 mm long, 3.25 and 3.75 mm wide, without any augment procedures. Control: 88 patients and 185 implants 10, 12 and 14 mm long, 3.75, 4.0 and 4.9 mm wide, with crestal bone augmentation in the time of implantation.

**Results:** Five test (3.09%) and six control (3.24%) implants were lost before loading because of infection and inflammation. After 2–3 months of healing period 157 test and 179 control implants were osseointegrated. Fourteen implants were restored with single crowns, 72 implants were loaded with united crowns, 47 implants with 14 bridgework and 24 implants to supports three full-arch bridges in test group. Thirty-four implants were loaded with single crowns, 63 implants were restored with united crowns, 50 implants with 15 bridgework and 32 implants to supports four full-arch bridges in control group. During total loading period three test (1.85%) and four control (2.16%) implants were lost because of bone resorption. No significant differences were found between test and control implants.

**Conclusion:** The study has shown nearly identical survival rate of short and small wide Pitt-Easy dental implants without bone augmentation and the normal size implants with augment procedures. The using of the short Pitt-Easy (Oraltronic, Sybron) implants in a good bone quality of mandible and maxilla posterior area, as the Sparing Sufficiency Strategy, might be considered an adequate alternative to more complicate implant–prosthetic treatment.

## Histometric analysis of bone regeneration guided with resorbable membrane and autogenous block graft

**Presenter:** Micheletti Hespanhol A

*University of São Paulo, São Paulo, Brazil*

**Co-authors:** Micheletti Hespanhol A, Albuquerque Basilio dos Santos R, Emilio Pustiglioni F, Pugliesi Alves de Lima LA

*University of São Paulo, São Paulo, Brazil*

**Background and aim:** The purpose of this study was to quantitatively analyze the healing pattern of onlay autogenous block graft covered with resorbable membrane (GBR) after 0, 14, 21, 45 and 150 days.

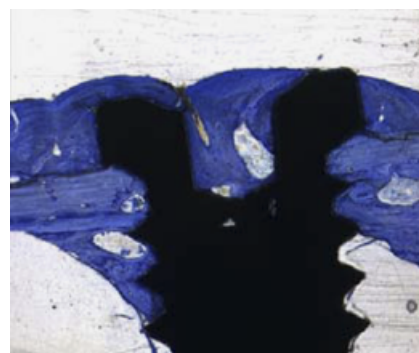
**Materials and methods:** Sixty, male, adult, Wistar rats were randomly included into one of two groups: machined titanium surface (MS) or oxide grit-blasted titanium surface (OTS) (INP). A block graft was harvested from the rat calvarium, laid and stabilized on the external cortex near the angle of the mandible with mini-implants. A collagen membrane (Biogide) was adapted to completely cover the bone graft in both groups. The animals were euthanized at 0, 14, 21, 45 and 150 days after surgery, and non-decalcified histological sections were processed. Quantitative and descriptive histology were carried out and data analyzed statistically (Tukey's and T-tests).

**Results:** Mean bone defect (BD) size of 604.13 µm (MS) and 585.90 µm (OTS), and block graft width of 379.89 µm (MS) and 368.32 µm (OTS) were observed at zero hour.



The amount of regenerated bone (RB) increased from day 21 (MS = 621.78 ;OTS = 611.18) to day 150 (MS = 860.89; OTS = 869.72), ( $p = 0.12$ ). The percentage of RB achieved 124% (MS) and 153% (OTS) of the BD size after 150 days, ( $p = 0.087$ ). The mean mandible bone width (MBW) after 150 days was 1254.40 and 1141.85 µm for MS and OTS, respectively. The final mean MBW after 150 days achieved 4.8 (MS) and 4.6 (OTS) times the original mandible width ( $p = 0.220$ ). No statistically significant differences between groups were observed.

**Conclusion:** GBR was effective to increase the MBW by almost five times. Although almost two-thirds of the regenerated bone was observed after 21 days, more regeneration took place up to 150 days.



## The use of one-piece implant in maxilla anterior single -tooth immediate replacement: a clinical and CT-scan appraisal study

**Presenter:** Chou TCT

*Taiwan Academy of Implant Dentistry, Taipei, Taiwan*

**Co-authors:** Chou TCT

*Taiwan Academy of Implant Dentistry, Taipei, Taiwan*

**Background and aim:** The aim of this study was to evaluate the clinical survival rate of using one-piece implant in maxilla immediate single-tooth replacement and compare the outcome of bone healing around the implant site among with or without bone grafting and barrier membrane by appraisal of bone density in CT-scan.

**Materials and methods:** Sixty-two one-piece (Q- Implant<sup>®</sup>) implants were immediately placed in the maxilla anterior single extraction site of 60 consecutive patients from January 2005 to July 2008 at Dr. Chou's dental implant center in Taipei. Twenty implants were inserted under fresh extraction socket without any grafting (group A), 12 implants were inserted with grafting and without membrane (group B), 18 implants were inserted with grafting and barrier membrane (group C). Analyze and account implant site bone healed situations from the time of implant insertion 6 months later to 18 months by PaX-Uni3D CT-scan in bone density profile analysis.

**Results:** 95.6% survival rate was found in this study no significant difference among those groups. Comparison of different grafting approach methods amongst in group A, B and C there are also no significant bone repairing in volume and density of peri-implant site.

**Conclusion:** One-piece implant obtained a high survival rate in maxilla immediate anterior single tooth replacement. Osseointegrated immediately loaded implants have shown a clinical long-term predictability similar to those of conventionally loaded implants. A steady primary stability, obtained by the large and deep threads of the screw-shaped implant was the key factor in the high success rate and the precise fit of the implant in the bone socket also was a key factor for the high bone implant contact percentage.



## Indications, contraindications and outcomes of stereolithographic template surgery

**Presenter:** Lomzynski L

*Medical University of Warsaw, Poland, Warsaw, Poland*

**Co-authors:** Lomzynski L, Mierzwinska-Nastalska E

*Department of Prosthodontics, Medical University of Warsaw, Warsaw, Poland*

**Background and aim:** The use of stereolithographic templates in implant dentistry is a valuable add-on to the conventional treatment protocols. CT analysis allows accurate implant positioning and flapless surgery is much less traumatic for the patient. On the other hand any mistakes made at every step of diagnostic and planing phases may sum up at the 'keyhole surgery' stage. The aim of the study is to present the outcomes of the implant treatment with the use of described techniques and to propose several modifications of the manufacturer-prescribed treatment protocols in order to avoid future complications and failures.

**Materials and methods:** The material consists of 40 patients qualified for the diagnostic procedures aiming at the stereolithographic template surgery. After the CT diagnostics and treatment planning the initial group diminished to 13 patients finally qualified for the flapless surgery with the use of the surgical templates. Seventy-three implants were placed (Nobel-Biocare Branemark Groovy) – 59 in the maxilla and 14 in the mandible. Twenty-two implants were placed in the partial cases and 51 in the full cases. Six cases were loaded immediately and in seven cases the loading was delayed according to the Brånemark protocol. The treatment planning was performed and the surgical templates were prepared in the NobelGuide concept (NobelBiocare Procera System). The surgery was performed flapless, and in cases of immediate loading, the temporary acrylic prosthetic solutions were delivered.

**Results:** 32.5% of initially qualified patients were treated with the use of stereolithographic templates – 67.5% did not have the required bone quality and quantity and were needing the augmentation procedures before the implantations. Out of the 73 implants placed 11 were lost at the time of 6–12 months from the surgery. The success rate was 100% in the group of partial cases and 78.43% in the group of full cases. In the group of delayed loading the success rate was 100%, and in the group of immediate loading it was 68.57%.

**Conclusion:** (1) All lost implants were in the immediately loaded full cases and they were the last implants in the arch which may indicate at the overloading as the cause of the failure. (2) The use of CT based stereolithographic surgical templates may be helpful to avoid the augmentation procedures, but in the two-thirds of the cases the CT diagnostics confirmed the need to augment. (3) To avoid overloading it is advised to perform a delayed loading, particularly in the full cases (six–eight implants) with patients posterior teeth present in the opposite arch.

## The biological stability of immediately placed tapered implants in tooth extraction sites

**Presenter:** Park SJ

*School of Dentistry, Kyung Hee University, Seoul, Korea*

**Co-authors:** Park J<sup>1</sup>, Park SJ<sup>1</sup>, Pae A<sup>1</sup>, Kwon Y<sup>2</sup>, Lee B<sup>2</sup>, Kwon KR<sup>1</sup>

*<sup>1</sup>Department of Prosthodontics, School of Dentistry, Kyung Hee University, Seoul, Korea, <sup>2</sup>Department of Oral and Maxillofacial Surgery, School of Dentistry, Kyung Hee University, Seoul, Korea*

**Background and aim:** Immediate implant placement has many advantages such as, reduction in the number of surgical interventions and treatment time required, ideal orientation of the implant, and preservation of the bone at the extraction site. Studies of healing of immediate non-submerged implant sites are limited. Tapered, root-form implants can be placed to replace multi-rooted teeth to increase the initial stability at the cervical area. This study evaluated implant success and biological stability of immediate transmucosal placement of tapered implants into tooth extraction sockets.

**Materials and methods:** Thirteen patients (13 males and 3 females) over age of eighteen participated in this study and 15 tapered implants (SuperLine; Dentium Co., Seoul, Korea) were placed. The extraction sites displayed sufficient residual bone volume to allow primary stability of all implants. Following tooth extraction, tapered implants were immediately placed into the sockets. Teeth with evidence of acute periapical pathology were excluded. After implant placement, soft tissue was managed to achieve non-submerged, transmucosal healing. The implants and peri-implant tissues were clinically and radiographically evaluated 0, 8, 12, 20, and 32 weeks after implant placement. Changes in depth of the distance from the implant shoulder (IS) and from the alveolar crest (AC) to the bottom of the defect (BD) were assessed.

**Results:** The mean surgery time was  $41 \pm 10$  min. All implants healed uneventfully yielding a survival rate of 100%. Mean ISQ values were relatively stable. Interproximal crestal bone decreased  $1.69 \pm 1.2$  mm (mesial),  $1.65 \pm 1.2$  mm (distal) from baseline to 32-week follow-up. No statistically significant changes with respect to full-mouth plaque score, full-mouth bleeding score, probing pocket depth, and width of keratinized gingiva were observed.

**Conclusion:** Within the limitations of this study, the peri-implant tissue response of immediately placed tapered implants loaded at 8 weeks was favorable and represented a predictable treatment option.

## The clinical use of super-wide diameter implants in the posterior regions

**Presenter:** Ahn M

*Daegu Mir Hospital, Daegu, Korea*

**Co-authors:** Ahn M<sup>1</sup>, Park K<sup>1</sup>, Park K<sup>2</sup>

*<sup>1</sup>Daegu Mir Hospital, Daegu, Korea, <sup>2</sup>Busan Mir Hospital, Busan, Korea*

**Background and aim:** Despite the high success rates of edentulous oral implants, restrictions still exist with regard to the bone available in height and volume. These restrictions are more

common in the posterior regions of the maxilla and the mandible due to the pneumatization of maxillary sinus and position of mandibular nerve. It is generally claimed that the best treatment in these situations is surgical modification of the patient's anatomy by bone grafting techniques, vertical ridge augmentation, inferior alveolar nerve repositioning, sinus graft. However, the use of short or nonstandard-diameter implants should now be considered as a more appropriate procedure.

**Materials and methods:** In first case, sinus bone graft surgery was done with the placement of two fixtures. However, the surgery was not successful, the sinus graft failed to integrate and the fixtures had to be removed. At the removal of the fixtures, sinus membrane appeared to be too severely damaged to perform sinus elevation. The remaining bone height was about 5–6 mm in height and the width was sufficient for short and super-wide implant. Thus, without bone grafting, implant placement was to be performed. The first molar area had a  $7.0(D) \times 5.0(L)$  mm fixture and the second molar area had a  $6.5 \times 5.0$  mm fixture. An additional fixture of  $7.0 \times 8.5$  mm was placed in the third molar area after careful consideration of the compromised condition. In second case, the patient had lowered ridge due to early two implant failure on right mandibular molar area. Residual ridge height was only 6–7 mm due to significant vertical resorption. Two  $6.0 \times 5$  mm fixtures and one  $4.0 \times 7.0$  mm fixture were placed.

**Results:** The follow-up periods of both cases have been > 3 years. Both cases are showing the excellent maintenance of implants.

**Conclusion:** Increased failure rates of short and wide-diameter reported in some studies have been mainly associated with operators' learning curve, poor bone quality, implant designs and site preparation, and the use of wide-diameter implant as a 'rescue' implant. More recent studies which have used surgical preparation adapted to the bone density and textured-surfaced implants have reported survival rates for short and wide-diameter implants comparable with those of standard-diameter implants. In the posterior area having vertical deficiency, short and wide-diameter implants should be considered comparing the outcomes of wide-diameter implant and morbidity of advanced surgical procedures such as bone grafting, sinus lifting, alveolar nerve repositioning.

#### 126 | Poster – Topic Implant and Guided Surgery

**A comparative study of two non-invasive techniques to evaluate implant stability: Periotest<sup>®</sup> and Osstell<sup>™</sup> Mentor**

**Presenter: Kim S**

*Chosun University, Gwangju City, Korea*

**Co-authors: Kim SG, Oh JS, Kim HK, Moon SY**

*Chosun University, Gwangju, Korea*

**Background and aim:** A more accurate and objective evaluation of mobility is available. Quantitative and reproducible measurement can be achieved with the use of Periotest<sup>®</sup> (Siemens AG, Bensheim, Germany) and resonance frequency analysis (RFA) (Osstell<sup>™</sup> Mentor). Both are non-invasive means of measurement that can be applied easily in clinical cases. The purpose of this study was to examine the usefulness of Periotest<sup>®</sup> and Osstell<sup>™</sup> Mentor (a resonance frequency analysis) as non-destructive analytical tools for

determining implant stability in clinics, to evaluate the precision of both instruments, and to determine the applicability of these measured values as clinically relevant indices.

**Materials and methods:** Four adult mongrel dogs weighing about 12–15 kg were used in this study. Bilateral extractions of the first through the fourth mandibular and maxillary premolars were performed and a total of 48 commercially pure titanium screw implants (USII Plus; OSTEM Implant, Seoul, Korea) were placed at 4 weeks after extraction. All implants (10 mm length and 3.3 mm diameter) were self-tapping and surface-treated with resorbable blast media (RBM). Periotest values (PTVs) obtained from Periotest<sup>®</sup>, and Implant Stability Quotient (ISQ) obtained from Osstell<sup>™</sup> Mentor, were measured at the time of implantation, and 3 and 6 weeks after implantation. At 3 and 6 weeks after implantation, four dogs were sacrificed and histomorphometric analysis was performed. The new peri-implant bone formation rate (NBFR) were measured.

**Results:** The PTV value was lower and ISQ value was higher at 6 weeks when compared with data collected at 3 weeks after implantation. The PTVs of the maxilla were higher than the mandible and the ISQ values of the maxilla was lower than the mandible. Based on the NBFR, the 6-week group showed higher bone formation when compared with the 3 week group, correlating to the observed PTV and ISQ values. Additionally, the NBFR was higher in the maxilla than the mandible. No significant difference between PTV and ISQ was also observed when PTV and ISQ were compared with NBFR.

**Conclusion:** The results indicated that the Periotest<sup>®</sup> and Osstell<sup>™</sup> Mentor, both non-invasive diagnostic devices, were useful and comparably reliable, showing a strong association with each other in assessing implant stability.

#### 127 | Poster – Topic Implant and Guided Surgery

**The effect of length or width of implant on the immediate implant stability: a human cadaver study**

**Presenter: Lee CW**

*St. Mary's Hospital Catholic University of Korea, Seoul, Korea*

**Co-authors: Lee CW<sup>1</sup>, Lee HC<sup>2</sup>, Kim SJ<sup>2</sup>, Ko YM<sup>1</sup>**

<sup>1</sup>*St. Mary's Hospital Catholic University of Korea, Seoul, Korea,*

<sup>2</sup>*Graduate School of Clinical Dental Science the Catholic University of Korea, Seoul, Korea*

**Background and aim:** The purpose of this study is to evaluate the relationship of immediate implant stability and serial increase of width or length of implant size at the same extraction site.

**Materials and methods:** Maxillary and mandibular canines and premolars were atraumatically extracted in five fresh frozen human cadavers. Three different width of implants (Replace Select implants Nobelbiocare Co. Sweden) were used on canine extraction site. Three different length of implants (Xive Plus implants Dentsply Friadent Co. Germany) were used serially on the premolar extraction site. On each extraction site, first implant was selected as usual clinical guidelines depend on the extraction socket dimension. Second and third of next size length or width implants were inserted after cautious removal of first selected implant. All

implants were inserted by self tapping procedure without tap drilling. In order to measure immediate implant stability, peak insertion torque value was measured during implant insertion, Resonance frequency analysis and periotest values were measured after implant insertion. And also, gaps between extraction socket and implant were measured with perioprobe.

**Results:** (1) As the width of implant increase, immediate implant stability was significantly increase ( $p < 0.05$ ). (2) As the length of implant increase, primary stability of immediate implant was not significantly increased ( $P > 0.05$ ). (3) Horizontal and vertical bone gaps between socket wall and implant were decreased as implant width increase.

**Conclusion:** To get the enough primary stability of immediate implant, primary stability of first implantation is so important, and if second or third implantation is needed, increasing the implant width might be more useful compare with increasing the length of implant.

## 128 Poster – Topic Implant and Guided Surgery

### Primary stability determination: operating surgeon's perception and objective measurement

**Presenter:** Daprile G

*Private Practice, Bologna, Italy*

**Co-authors:** Degidi M<sup>1</sup>, Daprile G<sup>1</sup>, Piattelli A<sup>2</sup>

<sup>1</sup>Private Practice, Bologna, Italy, <sup>2</sup>Dental School, Chieti, Italy

**Background and aim:** The aim of the study is to evaluate the difference between the dental surgeon's perception and the real values of RFA and insertion torque during implant insertion surgery.

**Materials and methods:** One hundred and fifty-two patients who needed one or more dental implants were selected. A total of 514 of Xive implants were inserted. For all the 514 implants, after the insertion, the oral surgeon was asked to indicate the probable RFA values (ISQ). For 483 implants the surgeon was also asked to indicate the probable insertion torque values (N/cm). Real values were then measured. The RFA and insertion torque values were grouped as low, medium and high.

**Results:** The mean perceived RFA (pRFA) was  $72.2 \pm 9.8$  ISQ. The mean real RFA (rRFA) was  $73.5 \pm 10.2$  ISQ. This difference was statistically significant ( $P = 0.01$ ). The mean perceived insertion torque (pIT) was  $39.1 \pm 20.1$  Ncm. The mean real insertion torque (rIT) was  $39.9 \pm 20.7$  Ncm. The mean difference between rRFA and pRFA was  $-1 \pm 14.9$  with a range from  $-60$  to  $59$ ; the mean difference between rIT and pIT was  $-1.3 \pm 9.9$  with a range from  $-38$  to  $45$ .

**Conclusion:** The results show that Xive implants obtain a good primary stability in all different clinical situations with a standard protocol. Primary stability is generally underestimated, especially in the presence of low/medium ISQ and torque real values. The accuracy of primary stability prediction is not good enough to prevent mistakes when using an immediate loading technique, therefore a more systematic use of objective measurements has to be encouraged.

## 129 Poster – Topic Implant and Guided Surgery

### Reliability of the root-implant interface in unconventionally placed implants: an up to 6-year follow-up of 23 implants covering three distinct clinical applications

**Presenter:** Szmukler-Moncler S

*University Paris 6, Paris, France*

**Co-authors:** Szmukler-Moncler S<sup>1</sup>, Davarpanah M<sup>2</sup>

<sup>1</sup>University Paris VI, Paris, France, <sup>2</sup>American Hospital of Paris, Paris, France

**Background and aim:** Osseointegrated implants are highly reliable in various clinical applications. The assumption behind this predictability is that implants come in direct contact with bone all over the implant surface. To comply with this requirement, every root remains need to be prevented from coming in contact with the implants. In certain cases, this constraint leads to invasive surgery and extensive bone damage; augmentation procedures are further needed and treatment becomes lengthy. This paper presents the follow-up of 23 implants that have been deliberately placed in contact with root fragments of (1) ankylosed teeth, (2) impacted teeth, (3) retained roots, to avoid invasive surgery, extensive bone damage and treatment delay.

**Materials and methods:** In 19 patients, 23 implants have been placed in contact with root fragments to treat six sites with ankylosed incisors, place 11 implants through impacted teeth and seven implants in contact with retained roots. For the ankylosed teeth, the standard drilling sequence started through the root canal; remaining root fragments, if stable, were left in contact with the implants. Impacted teeth that needed otherwise surgical remove to place implants where drilled through and implants were inserted. Sites displaying retained roots where drilled following a standard drilling sequence and implants were placed accordingly. All sites had to be asymptomatic and non-inflammatory; attention was paid to maintain roughly half of the implants surface at least in contact with bone.

**Results:** Of the 23 implants placed in contact with bone and root fragments, a short 8.5 mm implant placed through an impacted canine failed after 4 months of healing. All other implants healed uneventfully and were loaded. Implants have been now in place for 1–6 years (mean 3.3 years) in ankylosed teeth, for 6 months–5 years (mean 2.3 years) through impacted teeth and for 10 months–5 years (mean 3.0 years) in contact with retained roots. Periapical radiographs did not exhibit any specific deleterious pattern at either the bone-implant or the root-implant interface; dentine remodelling was observed at two implants after 2 and 4 years.

**Conclusion:** Histologic data found in the experimental literature supports the non-inflammatory character of the root-implant interface. These data combined with the present positive clinical results suggest that implant placement in contact with root fragments, asymptomatic and free of inflammation, might be considered as a possible alternative protocol if this unconventional implant placement can avoid invasive surgery and extensive bone damage. More cases are warranted to document this unconventional implant placement protocol, however, the present clinical report opens intriguing possibilities.

## Dietary strategies to optimize healing after advanced implant surgery

**Presenter: Fritz P**

*Reconstructive Periodontics and Implant Surgery Clinic  
@ Niagara Health System, Fonthill, Canada*

**Co-authors: Fritz P<sup>1</sup>, Ward W<sup>2</sup>**

<sup>1</sup>*Reconstructive Periodontics and Implant Surgery Clinic @ Niagara Health System, Fonthill, Canada,* <sup>2</sup>*Department of Nutritional Sciences, Faculty of Medicine, University of Toronto, Toronto, Canada*

**Background and aim:** Careful attention to nutritional needs after delicate periodontal procedures such as bone grafts or soft tissue grafts around implants helps ensure a successful outcome. Unlike at other surgical sites, oral surgical sites require additional dietary modifications that factor the texture, temperature and consistency of the diet to prevent damaging the delicate surgical area. Nutrients and food components that attenuate inflammation, oxidant stress, and foster de novo bone formation may facilitate healing. We hypothesize that a dietary strategy to promote healing after advanced implant surgery can be developed through a review of scientific literature and the physiological importance of nutrients in the healing process. This poster identifies such a dietary strategy, and culminates in recommendations of foods and supplements that may benefit patients post-procedure.

**Materials and methods:** No randomized controlled trials have investigated how diet influences healing after a bone graft or soft tissue graft performed simultaneously with implant placement. Thus, a critical review of *in vivo* and *in vitro* studies was undertaken to develop a dietary strategy that may optimize healing after such complicated periodontal procedures. Studies from the peer-reviewed literature (PubMed database, US National Library of Medicine and National Institutes of Health) were reviewed. Practical dietary advice was also incorporated.

**Results:** Twenty-four hours post-procedure: A meal replacement drink and daily multi-vitamin is warranted for the first 24 h to ensure appropriate nutrient intakes within safe levels. 1–14 days post-procedure: soft foods, requiring about three chews or less to swallow are recommended but this limits fruit and vegetable intake and thus antioxidants (vitamins C, E,  $\beta$ -carotene), B vitamins and folate that facilitate healing. Thus, a multivitamin improves status. Fish is an ideal source of protein as well as  $\omega$ -3 polyunsaturated fatty acids, precursors of anti-inflammatory mediators that may assist healing.  $\omega$ -3 supplements are warranted for patients who do not eat fish. Diets low in saturated fat create a less inflammatory milieu. Low-fat milk, providing calcium and vitamin D, is critical. Calcium and vitamin D supplements are warranted if dairy, particularly milk, is not consumed. The poster includes sample meals along with the rationale.

**Conclusion:** Although randomized control trials are needed to confirm the efficacy of a dietary strategy to augment healing, the dietary guidance presented may aid patients eager to optimize their surgical outcome. Attention to nutritional status before

surgical procedures, ensuring that there are no underlying suboptimal nutrient deficiencies, may also promote healing.

## A classification of dental implant dimensions based on the masticatory load of the patient<sup>®</sup>: an finite element analysis study

**Presenter: Chowdhary R**

*Academy of Dental Implant Research, Gulbarga, India*

**Co-authors: Chowdhary R<sup>1</sup>, Wennerberg A<sup>2</sup>, Hormuzd V<sup>3</sup>**

<sup>1</sup>*Academy of Dental Implant Research, Gulbarga, India,* <sup>2</sup>*Department of Odontology, Malmo University, Malmo, Sweden,* <sup>3</sup>*Academy of Dental Implant Research, Hyderabad, India*

**Background and aim:** Today the clinician is faced with widely varying concepts regarding the number, location, distribution and inclination of implants required to support the functional and parafunctional demands of occlusal loading. Planning and executing optimal occlusion scheme is an integral part of implant supported restorations. In its wider sense this includes considerations of multiple inter-relating factors of ensuring adequate bone support, implant location, numbers, length, distribution and inclination, splinting, vertical dimension, aesthetic and dynamic occlusal schemes and more. Smaller dimensional implants placed just based on availability of bone have been cited as the reasons for implant failure. Addition to these factors the masticatory load of individuals varies from person to person, which, if ignored will sometime cause occlusal trauma and fatigue micro damage in bone as well as in implant itself. The aim of this study is to find the appropriate implant dimensions for a defined masticatory load.

**Materials and methods:** A two-dimensional threaded implant finite element model was designed, which was duplicated in total of 28 models with varying dimensions starting from  $3 \times 8$  mm till  $6 \times 14$  mm, with incremental increase of 2 mm in length and 0.5 mm in diameter. All these models were meshed in a block of cancellous bone. Each implant model was loaded with 50–700 N, with an increase of 50 N in load which was applied in vertical direction.

**Results:** Von mises stresses were calculated for all the models with different amount of load. Analysis showed that, with increase in applied masticatory load the smaller dimensional implants showed more stress in the bone, with more concentration at the crest and the apex in relation to the ultimate stress capacity of the bone.

**Conclusion:** Thus, based on the stress analysis results, a classification is made. Which when the masticatory load is measured with a bite gauge of an individual will indicate that for a particular amount of masticatory load, a particular dimension of implant can be selected, rather than just selecting the implant based on the available bone and its dimensions without knowing the load the implant is going to take once it is loaded.

Dental implants inserted in non-sterile surgical conditions in private dental practices: osseointegration success rate of 2082 implants

**Presenter:** Arvanitidou S

*School of Dental Medicine, University of Geneva, Switzerland, Geneva, Switzerland*

**Co-authors:** Arvanitidou S<sup>1</sup>, Vazquez L<sup>1</sup>, Jambrec H<sup>2</sup>, Pessoto S<sup>2</sup>, Didonna D<sup>2</sup>, Belser U<sup>3</sup>, Bernard JP<sup>1</sup>

<sup>1</sup>Department of Oral Surgery, Stomatology and Radiology, School of Dental Medicine, University of Geneva, Geneva, Switzerland,

<sup>2</sup>Private Dental Practice, Geneva, Switzerland, <sup>3</sup>Department of Fixed Prosthodontics and Occlusion, School of Dental Medicine, University of Geneva, Geneva, Switzerland

**Background and aim:** It is frequently claimed that dental implant surgery requires strict sterile operating conditions in order to achieve successful implant osseointegration. However, excellent results may be obtained when practicing implant surgery in traditional dental office settings that do not follow the strict sterile operating room procedures. The aim of this study is to evaluate the osseointegration rate of 2082 non-submerged Straumann implants (Straumann AG, Basel, Switzerland) inserted in 1060 patients, by different surgeons in four private dental practices under conventional operating conditions.

**Materials and methods:** The standard surgical operatory set up involved: (a) a dental unit used for conventional dental treatment, (b) a suction tube that was covered with a sterile disposable cover or wrap and (c) a sterile paper drape that covered the patient's chest. The surgeons used sterile gloves but did wear neither a sterile surgical gown nor any specific dressing. 6–12-mm-long implants were placed following a standardised one-stage surgical procedure. 1233 implants were placed in 607 females and 848 implants in 453 males patients with a mean age of 58.4 years. After a 6–12 week healing period, osseointegration was assessed by controlling the absence of: (a) any clinically detectable implant mobility, (b) pain or any subjective sensation, (c) recurrent peri-implant infection, (d) continuous radiolucency around the implant and its resistance to the abutment tightening with a 35 Ncm torque.

**Results:** During the initial healing period prior to the abutment connection, 10 (0.48%) early implant failures were observed. At the time of the abutment connection, 2072 implants were clinically osseointegrated without peri-implant radiolucency or mobility. Consequently, the overall success rate at the time of the abutment connection was 99.52%.

**Conclusion:** This study confirms that dental implant surgery, performed under non-sterile conditions, achieves high osseointegration success rates and ensures satisfactory results comparable to those reported for implants inserted following a strict sterile protocol.

Anatomic assessment of maxillary sinus septa and of the relevant complications during sinus lift procedures: a cadaveric study

**Presenter:** Rosano G

*University of Milano, Milan, Italy*

**Co-authors:** Rosano G<sup>1</sup>, Gaudy JF<sup>2</sup>, Taschieri S<sup>1</sup>, Del Fabbro M<sup>1</sup>

<sup>1</sup>IRCCS Galeazzi Orthopaedic Institute, Section of Dentistry,

Department of Health Technologies, University of Milan, Milan, Italy,

<sup>2</sup>Department of Cranial Cervicofacial Anatomy, Faculty of Medicine René Descartes, University of Paris, 5 Paris, France

**Background and aim:** The goal of this study was to investigate the incidence, location and height of antral septa and to offer the clinician, through an accurate investigation of the anatomy of the maxillary sinus region, the tools to carry out sinus lifting procedures in safe conditions.

**Materials and methods:** The study consisted of 60 sinuses from 30 human cadavers with an age range of 59–90 years. Only septa measuring  $\geq 3.0$  mm in height were considered in our analysis.

**Results:** A total of 20 incomplete septa were found showing an incidence of 33.3% and no more than one septum per sinus was identified. All septa were located in the anterior lateral wall and were either sagittal or transversal. Six septa (30%) were located in the anterior region of the antral wall (between the second premolar and first molar roots), eight septa (40%) were in the middle region (between the first and second molar roots) and six (30%) were in the posterior region (distal to the third molar roots). Antral septa height showed a great variability with a mean value of 8.72 mm (SD 4.26, range 3.7–18.4 mm). Our study also showed that 40% (12/30 maxillae) of our specimens have bony septa that can partially divide the sinus and they were symmetrical in 8/12 cases; this means that a patient with septa in one sinus may have a 66.6% chance of showing the same configuration on the other side.

**Conclusion:** Despite the great variability of results obtained from the analysis of scientific literature about the prevalence, the location and the height of maxillary sinus septa, the values (included those of our study) are relevant enough to justify their relevance in clinical routine. When septa are present on the sinus floor during sinus lift operations we recommend, as already stated by Boyne and James, cutting them with a narrow chisel and removing them with a haemostat so that the bone graft can be placed over the antral floor without interruption. Such surgical approach is essential to avoid the Schneiderian membrane to be lacerated during its elevation. As a consequence, we recommend to use CT scan imaging, which has been proved to be the preferred radiographic method for detecting any anatomical variation within the sinus, in order to prevent complications during sinus augmentation procedures or any other surgical intervention involving this region.

### The influence of 3-D planning and navigation on success rate and overall treatment time

**Presenter:** Roos HJ

*Dr. Roos @ Kollegen, Memmingen, Germany*

**Co-authors:** Roos HJ

*Dr. Roos @ Kollegen, Memmingen, Germany*

**Background and aim:** Dental implants are a very reliable treatment option when comparing success rates to other treatment options in dentistry. However, most of the literature available is based on studies where implantation was firstly planned analyzing conventional X-rays and models and secondly surgery was performed in a classical two-stage approach. The aim of the study was to evaluate the success rate as well as the overall treatment time of digitally planned and navigated implants in all indications in a dental practice.

**Materials and methods:** Five hundred and seven implants (NobelSpeedy<sup>TM</sup>, Nobel Biocare AB, Sweden) restoring single teeth, partially edentulous sites and edentulous jaws in 115 treated patients were included. Implants were inserted in healed sites minimum 100 days after tooth extraction. The patients were included consecutively. All implants were planned in a 3-D-environment and this planning was transferred into the mouth via a surgical guide according to the clinical protocol recommended (NobelGuide<sup>TM</sup>, Nobel Biocare). A single stage procedure was used with immediate provisionalization within 24 h after surgery in 85.2% of the cases. All other cases were treated in a two-stage procedure. The definitive prosthesis was delivered within 9 weeks in average after implant insertion. Time of planning, surgery and overall treatment time was recorded and compared with the time when performing the classical protocol.

**Results:** The subjects with 507 implants have completed a follow-up between 6 and 26 months with a mean of 14 months. Five implant failures, in three patients occurred resulting in cumulative survival rate of 99.0%. Two of the patients that displayed implant loss had a medical history of smoking, the third patient of alcohol abuse. Four out of five implants were lost in the mandible, one in the maxilla. The mean surgery time for single tooth treatment, partial cases and fully edentulous jaws were 30, 180 and 320 min for the classical technique and 10, 25 and 50 min when used NobelGuide<sup>TM</sup>. Overall treatment time was 20–31 weeks for the classical technique and 15 when used NobelGuide<sup>TM</sup>.

**Conclusion:** At this stage, the high implant survival rate, the reduced overall treatment time as well as the reduced surgery time indicate that implants that are digitally planned and navigated result in a high success rate and reduced treatment time for the patient when used with the recommended protocol.

### Prediction of primary implant stability via CT analysis

**Presenter:** Merheb J

*Catholic University Leuven, Leuven, Belgium*

**Co-authors:** Merheb J<sup>1</sup>, Van Assche N<sup>2</sup>, Coucke W<sup>3</sup>, Jacobs R<sup>3</sup>, Naert I<sup>3</sup>, Quirynen M<sup>3</sup>

*<sup>1</sup>Catholic University Leuven, Leuven, Belgium, <sup>2</sup>Scientific Institute, Brussels, Belgium, <sup>3</sup>Catholic University Leuven, Leuven, Belgium*

**Background and aim:** Explore the relationship between primary implant stability and different parameters related to implant or bone properties.

**Materials and methods:** Twenty-four patients received a total of 136 Straumann SLActive implants. Resonance frequency analysis (RFA) was performed at implant placement, and RFA and Periotest (PTV) were scored at loading. Bone density (Hounsfield scores (HU)) and coronal cortical thickness at osteotomy sites were measured from pre-operative CT scans. Implant length and diameter, type of anchorage (mono vs. bi-cortical) and presence of bony dehiscences were also recorded.

**Results:** Implant length, diameter or presence of bony dehiscence did not have a significant effect on mean RFA scores at implant insertion. Significant linear relations were found between RFA or Periotest scores and HU values ( $p < 0.05$ ), or cortical bone thickness ( $p < 0.01$ ), both at insertion as well as at loading. Some parameters, insignificant in single regression analyses regained significance in the context of a stepwise multiple regression analysis.

**Conclusion:** RFA and PTV scores can be predicted based on implant and especially bone related factors.

### Diabetes in rat models of implant research

**Presenter:** Kuchler U

*Medical University of Vienna, Vienna, Austria*

**Co-authors:** Kuchler U, Glössl B, Spilka T, Watzek G, Gruber R

*Medical University Vienna, Vienna, Austria*

**Background and aim:** Diabetic patients have gained benefit from recent progress in preclinical implant research. Rodent models have helped to better understand the complex process of osseointegration in a diabetic background. Aim of this study is to provide an overview about current protocols of the diabetic rat model. This information should assist in selecting the appropriate conditions for implant research.

**Materials and methods:** In addition to our own findings, we conducted a comprehensive search in PubMed (1966–2008) to identify preclinical studies dealing with osseointegration in rat models of diabetes. Only articles published as full manuscripts in dental journals were considered. The initial search strategy used the terms diabetes, rat, (dental) implants, bone, osseointegration, and combinations thereof. We recorded the following major outcomes of each study: age, method of diabetes induction, time point of implantation, length of observation. Minor

outcomes were the method of anesthesia and disinfection, characteristics of implants, and implant sites.

**Results:** Rats are considered suitable for diabetes induction not before the age of five weeks. Diabetic conditions are established mainly by an intraperitoneal injection of streptozotocin with doses ranging from 45 to 100 mg per kg body weight. The toxicity of streptozotocin is a critical issue in the protocol and depends on various factors such as age and gender. Animals can be considered diabetic when blood glucose levels reach 300 mg per dl. Implants are inserted in tibia or femur ranging from 24 h to 3 weeks after the induction of diabetes. The protocol is based on 8 months old female rats that received intraperitoneal injection of 45 mg streptozotocin per kg body weight, following implant insertion in the tibia after 2 weeks. Histomorphometric parameters of osseointegration are determined 4 weeks after implant insertion.

**Conclusion:** Taken together, the selection of the appropriate protocol is critical when studying osseointegration in diabetic rats. Appropriate criteria for the individual assessments of osseointegration in these models can be selected based on the brought spectrum of protocols in the published literature. A consensus from the scientific community on standardized methodological approaches for preclinical rat models would allow a better comparability of the findings from different studies.

137	Poster – Topic Implant and Guided Surgery
-----	---

### Accuracy and clinical impact of guided implant placement in the posterior mandible

**Presenter:** Möller F

*University Cologne, Köln, Germany*

**Co-authors:** Möller F, Neugebauer J, Ritter L, Dreiseidler T, Mischkowski RA, Zöller JE

*University Cologne, Köln, Germany*

**Background and aim:** Implant placement in the posterior mandible requires a reliable treatment plan to avoid harming the alveolar nerve. Implants were planned with a security distance from 0.5 to 2.0 mm close to the mandibular canal using guided surgery. Postoperatively the distance from implant to nerve was evaluated.

**Materials and methods:** Sixteen patients received 55 implants for 22 superstructures (20 free-end situation, two single tooth). Vertical augmentation was necessary in two patients with hip graft and retromolar bone graft each. For implant planning a CBCT (Galileos, Sirona, Germany) was performed and 3D implant planning was performed for fabrication of surgical guide (Sicat Implant, Sicat, Germany). Depending on the intra-operative finding panoramic radiograph ( $n = 9$ ) or CBCT ( $n = 7$ ) were performed after surgery.

**Results:** CBCT guided treatment plan allowed to reduce the number of vertical augmentation by the use of short implants. The following length were used 8 mm 3.6%, 9 mm 14.5%, 10 mm 36.5%, 11 mm 34.5%, 12 mm 3.6% and 13 mm 7.3%. Twenty percent of the implants were placed before the foramen mentale, 20% at region 5, 36.4% at region 6 and 23.4% at region 7. No perforation of the mandibular canal or the fovea sublingualis occurred. The average distance in vertical dimension was  $1.4 \text{ mm} \pm 0.78$  with a minimum of 0.4 mm and for horizontal dimension of  $1.8 \pm 0.85 \text{ mm}$  with a minimum of 0.8 mm. The

absolute distance was  $1.5 \pm 0.89 \text{ mm}$ . No alteration of sensitivity was observed.

**Conclusion:** Guided surgery allowed a reliable implant placement. Especially in cases with a reduced vertical height additional grafting techniques could be avoided and security distance of 0.5 mm could be reached.

138	Poster – Topic Implant and Guided Surgery
-----	---

### Differential bone densitometry during osseointegration processes. A comparative study: Piezosurgery implant surgical protocol vs traditional rotative instruments protocol

**Presenter:** Di Alberti L

*Private Practitioner, Chieti, Italy*

**Co-authors:** Di Alberti L<sup>1</sup>, Camerino M<sup>1</sup>, Donnini F<sup>1</sup>, Di Alberti C<sup>1</sup>, Vercellotti T

<sup>1</sup>*Private Practitioner, Chieti, Italy*

**Background and aim:** Osseointegration of dental implants is highly predictable with surgical traditional techniques (Brånemark et al 1977). Piezoelectric osteotomy is a technique based on ultrasonic vibration of an osteotomic device that permits precise cutting of bone structures without damaging adjacent soft tissues. The precise nature of the instrument allows exact, clean, and smooth cut geometries during surgery. Postoperatively, excellent wound healing could be observed. The aim of this study is to compare the radiographic differences, through the evaluation the bone perimplant density, between the implant site preparation with traditional surgical technique and piezosurgical technique with implant tips (Piezosurgery, Mectron, Italy).

**Materials and methods:** Twenty patients (12 males and eight females) have been selected to be enrolled in this study. All implant sites have been performed in non-pathologic native bone. To better define and restrict this clinico-radiological study a single kind of implant surface have been chosen, the sand-blasted-acid-etched, and a single diameter was also used. For the control group a traditional multi step drilling procedure has been used to make the surgical preparation for the implant insertion. For the study group the Piezosurgery<sup>®</sup> technique was used. The new Piezosurgery implant tips were used sequentially to surgically shape the implant site. Firstly was used the OP54 tip, then the new IM2 to make a 2 mm diameter cavity, subsequently the OT4 and IM3 made a 3 mm diameter cavity. Using the densitometric application of RVG software analysis the bone density has been studied. For every single implant defined and repeatable points have been chosen.

**Results:** The study demonstrate radiologically an higher bone density around implants threads in the follow-up period for the implant site preparation done with the piezosurgery protocol. The bone higher density has been statistically linked with the specific characteristic of the piezosurgery protocol for implant insertion. Ostell values confirmed the implants stability. This study define a new way to shape and finish off the implant site with a great precision and less bone trauma during surgical procedure.

**Conclusion:** We can conclude that the piezosurgical preparation of the bone implant site leads to an higher density of the bone surrounding the implants threads during initial phases of

osseointegration. This study open a new way to shorter the implant healing timing and shows that two different implant site surgical preparation have different healing time under same condition of implant surface linking the bone healing surrounding the implant to the surgical procedure.

139
Poster – Topic Implant and Guided Surgery

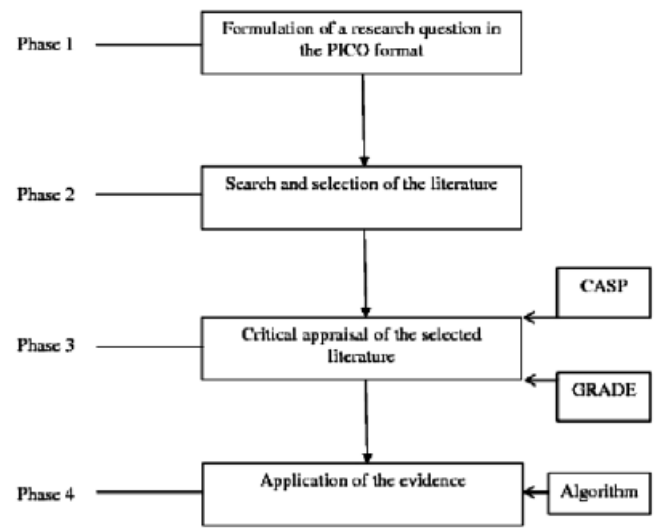
### Making appropriate evidence-based clinical decisions in implant dentistry using the example of peri-implantitis treatment

**Presenter: Faggion C**  
*University of Heidelberg, Heidelberg, Germany*  
**Co-authors: Faggion C, Schmitter M**  
*University of Heidelberg, Heidelberg, Germany*

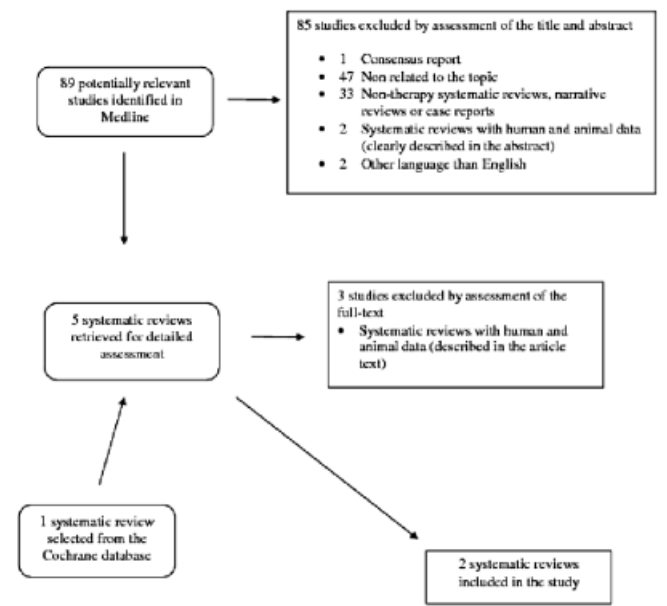
**Background and aim:** The number of clinicians performing dental implant treatments has increased in the last few years. Evidence-based information is necessary to support the dentist’s decision making process. To present an evidence-based model using the example of peri-implantitis treatment that can be used by clinicians.

**Materials and methods:** The model has four steps: formulation of a research question, search and selection of relevant literature, appraisal of quality of information and rational application of evidence to the management of peri-implantitis. A focused question in the PICO format (patient, intervention, comparison and outcome) was developed to optimize the literature searching process. Systematic reviews (SR) of randomised controlled trials (RCT) on the treatment of peri-implantitis were retrieved from Pubmed and Cochrane electronic databases in 1 January 2008. Only SR of RCT conducted in humans were included. Case-series and observational studies were excluded. Critical Appraisal Skills Programme (CASP) checklist helped to assess the methodological quality of selected studies and the Grading of Recommendations Assessment, Development and Evaluation (GRADE) system was used to measure the quality of evidence. A treatment algorithm was used to standardize recommendations of treatments.

Flowchart describing the different steps and components of the evidence-based model



Flowchart of literature search for studies on peri-implantitis therapy



**Results:** Five SR were selected from 90 potentially relevant studies. After detailed assessment, two SR met the inclusion criteria and, therefore were included in the study. The two selected SR suggested that subgingival debridement, subgingival debridement plus use of antibiotics and regenerative procedures can be effective treatments for peri-implantitis. One SR suggested that laser might also be an option for treatment. However, GRADE system indicated a low quality of evidence for RCT included in both SR. Using the available evidence, an algorithm (decision tree) was developed for the management of slight, moderate and severe cases of peri-implantitis.

Assessment of quality of evidence with GRADE system GRADE					
Systematic review	Design	Quality	Consistency	Directness	Overall evidence
Kotsovilis	RCT	Serious limitations (– 2)*	No important inconsistency	No important uncertainty	Low
Esposito	RCT	Serious limitations (– 2)*	No important inconsistency	No important uncertainty	Low

\*Quality dropped by two levels.

**Conclusion:** Although systematic reviews of RCT are considered the best available evidence for therapies, quality of evidence from peri-implantitis studies was considered low and, therefore the results should be taken with great caution. This model may help clinicians to assess the quality of evidence and the strength of recommendations in the decision-making process.



## Prospective study on extra short dental implants supporting an overdenture in the edentulous maxilla

**Presenter:** Van Assche N

*Catholic University Leuven, Leuven, Belgium*

**Co-authors:** Van Assche N, Michels S, Quirynen M, Naert I

*Catholic University Leuven, Leuven, Belgium*

**Background and aim:** The unpreventable resorption of the alveolar crest after tooth extraction and the pneumatization of the sinus can result in a limited bone height in the posterior maxilla. Several surgical techniques exist that allow the insertion of dental implants in these critical areas. The use of short implants offers the advantage of reducing the need for bone augmentation. This study investigates the outcome of short implants (6 mm) additionally placed to support a maxillary overdenture with longer implants.

**Materials and methods:** Twelve fully edentulous patients received six implants (Straumann® Standard Plus SLActive, smooth collar 1.8 mm) to support an overdenture. The distal implant in each quadrant was 6 mm in height (S). The length of the other four implants ranged between 8 and 14 mm (L). All implants were placed according to a one-stage procedure. After 3 weeks of healing, impressions were taken to allow the early loading of the implants. Clinical and radiological parameters were assessed 6 and 12 months after prosthetic loading.

**Results:** Of all implants, one short implant failed 2 weeks after surgery probably due to mobilisation by the provisional prosthesis. The loss of the implant had no real consequences for the function of the prosthesis. Mean success rate was 98.6% after 1 year [95.8% (S), 100% (L)]. Mean bone level (measured from implant shoulder) was 1.3 mm (range 0.5–2.0) (S) vs. 1.4 mm (range 0.2–2.7) (L) after placement and 2.2 mm (range 0.6–3.3) (S) vs. 3.1 mm (range 1.2–5.5) (L) 1 year after loading. Respective mean ISQ values for both moments were 67 (range 48–76) (S) vs. 70 (range 37–81) (L) at placement and 73 (range 58–84) (S) vs. 73 (range 58–89) (L) after 1 year. All prostheses were stable and comfortable worn after 1 year.

**Conclusion:** In patients with reduced alveolar bone height up to 6 mm, an overdenture on six implants, of which two have a reduced length, might represent a successful treatment option at least after 1 year.

## Evaluating bone perfusion status before surgery using laser-doppler flowmetry and tissue spectrometry

**Presenter:** Kessler B

*University of Bonn, Bonn, Germany*

**Co-authors:** Abboud M, Kessler B, Wahl G

*University of Bonn, Bonn, Germany*

**Background and aim:** To systematize a procedure that allows one to characterize the perfusion response pattern of bone to surgery, medical therapy and implants using Laser-Doppler flowmetry (LDF) combined with tissue spectrometry.

**Materials and methods:** A study was carried out with 17 healthy adult subjects of either sex. Bone perfusion was evaluated using a specially designed non-invasive laser-Doppler device (O<sub>2</sub>C). The O<sub>2</sub>C device (Lea Medizintechnik GmbH, Gießen, Germany) combines white light spectrometry and laser spectroscopy to enable non-invasive measures in tissues of various depths of about 100 µm to 16 cm. Monitoring the energetic metabolism of cells by measuring the oxygen uptake with an optical sensor probe is possible. Monitoring of oxygen supply simultaneously in different layers of tissue is possible. Two perfusion recordings were carried out, each one consisting of a 20 s control phase.

**Results:** The O<sub>2</sub>C device measures precisely and reproducibly the oxygen saturation (SO<sub>2</sub>) of the blood in the bone. Regarding the mean values 6% lower oxygen saturation was measured for the maxilla. The P-test reveals a value of 0.00251. The lowest SO<sub>2</sub> measured was 58 in the mandible and 54 in the maxilla. The highest SO<sub>2</sub> measured was 80 in the mandible and 75 in the maxilla. There were no significant differences between male (n = 8) and female patients (n = 9). Pathological O<sub>2</sub>-supply, which can lead to angiogenesis or cell-death and subsequently to organ failure, can now be detected in an early state by use of the new sensor system. The optical sensor is easy to handle and guarantees reproducible examinations of local oxygen supply of tissues. The examinations are without any strain for the patient.

**Conclusion:** The results of the present pilot study suggest that the LDF might present clinical applicability in recording changes in bone blood flow before or following implantation or any kind of bone surgery. In addition it allows monitoring of healing or inflammation processes in the bone.

## Flapless implant surgery with computer-guided surgical approach

**Presenter:** Groselj D

*Medical Faculty of Ljubljana, Ljubljana, Slovenia*

**Co-authors:** Groselj D<sup>1</sup>, Groselj H<sup>2</sup>

<sup>1</sup>Medical Faculty of Ljubljana, Ljubljana, Slovenia, <sup>2</sup>Megfid d.o.o., Ljubljana, Slovenia

**Background and aim:** A technique using a scan prosthesis and computed tomography, three-dimensional surgical planning software, and a stereolithographic surgical template to guide the implant placement with a flapless surgical approach is presented. The recordings of implant stability could increase the clinical success modifying the time needed for osseointegration specially using shorter lengths of implants or placing them in bone of lower density.

**Materials and methods:** The one-stage protocol for implant placement was followed, based on the principles of minimally invasive surgery. For the static method, the system SimPlant was used for placing 34 dental implants (PiH, Lima) in six females and nine males, mean age 61 ± 7 years. Two Surgi-Guides were tooth- and 13 tooth-mucosa-supported. The prostheses were attached after a conventional healing period of 3–6 months or the time of osseointegration was extended when the implants had been placed in soft bone. Clinical stability at

implant placement and at suprastructure fixation was determined. The maximum torsional force (Ncm) during implant tightening has been recorded by dynamometric wrench. The patients were nonsmokers and had no systemic diseases with potential influence on periodontal conditions.

**Results:** Bone densities at baseline outside the implants were distributed between 237 and 1661 Hounsfield units (HU), mean value  $643 \pm 160$ . The primary stabilities at implant placement were 12 times under the level of 30 Ncm and 22 times the applied torsional force reached 30 or more Ncm. The torsional forces for all implants at suprastructure fixation were 30 Ncm, too. The most marked clinical advantages of flapless implant surgery were decreased surgical time, improved patient comfort and accelerated recuperation.

**Conclusion:** Computer-guided flapless surgical approach yielded predictable results even in cases where primary stabilities at implant placement were under the level of 30 Ncm and bone density reached  $<400$  HU.

143	Poster – Topic Implant and Guided Surgery
-----	---

### Accuracy of milled precision-guided surgical template

**Presenter:** Kim Y

*Evergreen Dental, Seoul, Korea*

**Co-authors:** Kim Y<sup>1</sup>, Lee TG<sup>2</sup>

<sup>1</sup>*Evergreen Dental, Seoul, Korea*, <sup>2</sup>*Ezplant, Seoul, Korea*

**Background and aim:** Recently, computer-aided implant surgery using precision-guided surgical template (PGS template) to transfer preplanned location of the implant in the CT scan to the actual surgical site is attempted. PGS template integrates metal bushings to dictate three dimensional orientation and depth of the drilling. Virtual planning information is transferred to the PGS template either by stereolithographic rapid prototyping (NobelGuide from NobelBiocare, SurgiGuide from Materialize) or by milling machine (CompuSurge Template of Implant Logic System, Navis from EZplant). Stereolithographic template is expensive, fragile and takes extensive time to manufacture. In this study, accuracy of milled PGS template (Navis, Seoul, Korea) was analyzed with *in vitro* test and clinical case.

**Materials and methods:** Partially edentulous mandibular stone model with cylinder-shaped gutta percha (GP) stoppings embedded in the posterior segments were constructed. CT scan was taken and the location of the GP stoppings were planned to be the final location of the implant. Navis template was fabricated according to the preplanning. The template was placed in the stone model and 2 mm drilling was performed. CT scan was taken after drilling and the deviation between the drilling and GP stoppings were calculated. In the clinical case, location of the preplanned implant in the preoperative CT scan was compared with postoperative CT scan and angular error and deviation in the entry point and apex was measured.

**Results:** Accuracy of three-dimensional orientation and depth control of Navis template was excellent both in *in vitro* test and clinical cases.

**Conclusion:** Milled PGS template (Navis) was more precise than other PGS template fabricated by stereolithography. Considering

efficiency and financial burden of patients, milled PGS template can be very useful in the clinical situation.

144	Poster – Topic Implant and Guided Surgery
-----	---

### The effect of loading time on osseointegration and new bone formation around dental implants: a histologic and histomorphometric study in dogs

**Presenter:** Ghanavati F

*Shaheed Beheshti School of Dental Medicine, Tehran, Iran*

**Co-authors:** Ghanavati F<sup>1</sup>, Karamlou M<sup>1</sup>, Rahimi H<sup>2</sup>, Ghanavati F<sup>3</sup>

<sup>1</sup>*Shaheed Beheshti School of Dental Medicine Tehran Iran, Islamic Republic of*, <sup>2</sup>*Harvard School of Dental Medicine, Boston, USA*,

<sup>3</sup>*Newcastle Hospital, Newcastle, UK*

**Background and aim:** Immediate loading of dental implants is a method of reducing implant treatment time without compromising its prognosis. In this study, the effect of loading time on the amount of bone-to-implant –contact (BIC) and bone formation around dental implants were evaluated histologically.

**Materials and methods:** Three month before implantation, the lower premolar of 15 dogs were extracted. Three or four dental implants were placed in the healed extraction sites for each dog ( $N=48$ ). Dividing the dogs into three groups, the implants were either loaded 48 h or 1 week later with metallic or prefabricated acrylic crowns or were left unloaded until the time of sacrifice. Three months after implant insertion, the animals were sacrificed and samples were investigated to define the amount of BIC, lamellar and woven bone percentage, and local inflammation of the newly formed bone.

**Results:** No significant difference in the observed criteria was reported among three groups ( $p>0.05$ ); however, the unloaded group had the highest degree of BIC and group loaded 48 h after the primary implant insertion had the least. The prosthesis type had no significant effect on the implant success rate ( $p>0.05$ ). The lamellar and woven bone percentage of newly formed bone also did not differ in the three groups ( $p>0.05$ ). One implant from each group failed in this experiment.

**Conclusion:** Loading time does not seem to significantly affect the degree of osseointegration and BIC and the composition of newly formed bone around dental implants.

145	Poster – Topic Implant and Guided Surgery
-----	---

### Immediate loading of unsplinted implants in the anterior mandible for overdentures: A 1-year pilot prospective study

**Presenter:** Roe P

*Loma Linda University, Loma Linda, CA, USA*

**Co-authors:** Roe P, Kan J, Goodacre C, Lozada J, Kleinman A, Rungcharassaeng K

*Loma Linda University, Loma Linda, CA, USA*

**Background and aim:** Preliminary studies on implant placement and early loading with a mandibular overdenture have shown good success when opposing a maxillary denture. The objective of this 1-year pilot prospective study is to evaluate the clinical

success of immediately loading mandibular overdentures using unsplinted implants with a fluoride-modified micro-roughened titanium surface.

**Materials and methods:** Five male and two female patients, between the ages of 58 and 82 (mean age of 68.7 years) were selected to participate in this study. All participants received new maxillary and mandibular complete dentures prior to implant placement. Two 4.0 × 13 mm threaded implants with a fluoride-modified, micro-roughened, titanium surface were placed mesial to each mandibular canine position. Locator matrices were connected and torqued to 25 Ncm and primary closure was achieved with a nonresorbable suture material. The patrices were picked up with repair resin and light-retention (1.5 lb) inserts were placed. Post-operative instructions were reviewed with the patient. The following parameters were recorded at the time of implant placement (0), 3, 6, and 12 months after surgery when applicable: implant success rates, marginal bone level via standardized periapical radiographs, Periotest values (PTV), modified plaque index (mPI), surgical and prosthetic complications.

**Results:** All implants were successfully osseointegrated (14/14) with a follow-up time of 12 months. The mean marginal bone levels at (0), 3, 6, and 12 months were  $0.12 \pm 0.11$ ,  $-0.18 \pm 0.05$ ,  $-0.22 \pm 0.06$ , and  $-0.25 \pm 0.06$  mm, respectively. The mean PTV following (0), 3, 6, and 12 months were  $-5 + 2.81$ ,  $-5.93 + 1.27$ ,  $-6.29 + 0.76$ , and  $-6.93 + 0.79$ , respectively. The mPI scores showed improved oral hygiene over time. Surgical complications included rotational instability of two implants (2/14) at the time of surgery. One of the two implants was replaced with a larger diameter implant (4.5 × 13 mm) due to the lack of primary stability. Prosthetic complications included matrix loosening on one implant at 5 months and the installation of new patrix inserts for two patients at their 1-year recall examination.

**Conclusion:** This 1-year pilot prospective study has shown that the implant success rate and marginal bone responses around two immediately loaded unsplinted threaded implants with a fluoride-modified, micro-roughened, titanium surface in the anterior mandible retaining an overdenture, were favorable and comparable to that of conventional delayed-loaded implants.

#### 146 Poster – Topic Implant and Guided Surgery

Tomography based guided implant insertion: An alternative with reduced costs and radiation compared with CT/DVT-planning or historical reminiscences?

**Presenter:** Tischendorf L

*Praxis MKG-Chirurgie, Halle, Germany*

**Co-authors:** Tischendorf L

*Praxis MKG Chirurgie, Halle, Germany*

**Background and aim:** Since 1998, we plan implant insertions by means of conventional transversal tomography. Guided implant insertion permits preparation with low vibrations in an exact position. However there are only limited publications about exactly measured results. We developed three accidental devices: (1) X-Ray device with a bite fixation to reproduce adjust-

ment for transversal tomography (2) Indicator for bone and axis measure for the panoramic and transversal tomography (3) Indicator for length measure to determine the free distance to opposite teeth or jaw.

**Materials and methods:** Since 2005, we analysed implant positions in 55 cases. We measured deviations of implants in the models for the definitive abutments from the planning insertion devices. We measured the differences of eccentric length and of the axes.

**Results:** In 94% cases the position of implant corresponded to the planning. In respect to the bone situation the plan was changed in single cases. Insertions were very precise. The mean deviation was 0.44 mm in eccentric and 1.5 grad in axis. It was higher in cases with a difficult access (limited opening of the mouth, distal from long teeth by high-grade bone resorption). The deviation was higher by tapered implants (0.5 vs. 0.38 mm) and in free-end positions (0.53 vs. 0.35 mm). Tomography based guided implant insertion in our modification is a very precise method. It includes insignificant higher costs (200 euro) and radiation (one transversal tomography) compared with the freehand insertion. It includes much lower costs (1000 euro) and much less radiation (four times) compared with CT/DVT planning method. A change to freehand drilling is possible any time. But the combination with very precise inserted implants in these cases can lead to difficulties.

**Conclusion:** Tomography-based guided implant insertion in our modification is a very precise method. The indication is limited for one to three implants and only for cases with the possibility to fix the devices on teeth or implants. The method is indicated in following cases: extremely soft bone, high differences of bone density (e.g. following bone augmentation), in the upper premolar region (there are often misjudgements of inclination axis), in small gaps, in risk situations because of the atraumatic drilling with low vibrations, We cannot recommend immediate definitive bridges or crowns with regard to our results of measurement of deviations.

#### 147 Poster – Topic Implant and Guided Surgery

Oral function reconstruction by vascular fibula bone flap simultaneous dental implants: 15 years experience in chang gung memorial hospital

**Presenter:** Chan YF

*Chang Gung Memorial Hospital, Taipei City 105, Taiwan*  
**Co-authors:** Shen YF

*Chang Gung Memorial Hospital, Taipei, Taiwan*

**Background and aim:** This study is aimed to estimate the cumulative survival rate of implants placed in a vascularized flap for functional oral reconstruction.

**Materials and methods:** From 1993 to June 2005, 76 patients with various composite jaw bone defects were reconstructed with a fibula osteoseptocutaneous free flap with simultaneous placement of dental implants (42 males, 34 females, average age 50.4 years). A total of 297 implants (280 in fibula bone, 17 in native mandible) were placed. The indications for one-stage surgical procedure were: the segmental mandibular defect due to an aggressive benign tumour (52), osteomyelitis (5), and osteoradionecrosis (19). The technique included: (1) Placement of a fibula segment 5 mm higher than the native mandible

border. (2) Placement of an additional reconstruction plate along the mandibular border, (2000–2004). (3) Use of a double-barrelled fibula construct with primary osseointegration (2004–now).

**Results:** All implants osseointegrated (297/297). The bone loss around the implant was <1.5 mm in an average of 46.3 months of oral functional loading follow-up. Keratinized mucosa grafts around the dental implants provided good oral hygiene and proved better than skin grafts for the patients. Lower lip sensation recovered between three and 18 months post-operatively. Implant supported prostheses proved to be better than implant tissue supported prostheses.

**Conclusion:** Use of the vertical ridge distraction technique or a double-barrelled vascularized fibula bone graft were both good methods to correct insufficient alveolar ridge height for segmental mandibular reconstruction.

148	Poster – Topic Implant and Guided Surgery
-----	---

Implants in the maxillary tuberosity (d4 bone) as a possible therapeutic option to sinus lifting: anatomical and surgical considerations

**Presenter: Palazzo L**

*Gubbio Hospital, Perugia, Italy*

Co-authors: Palazzo L, Rossi C, Mannarino MR, Belcastro S, Floridi P, Sessa M, Guerra M

*Gubbio Hospital, Perugia, Italy,*

**Background and aim:** Severe vertical bone deficiency of the rear upper jaw, as a result of damage due to both periodontal disease and expansion of the maxillary sinus, makes the use of implants particularly challenging. Sinus lifting is considered a surgical method for this problem. However it is not always a feasible solution. The aim of this work is to consider the use of implant in the maxillary tuberosity (D4 bone) as a possible therapeutic option.

**Materials and methods:** After reviewing clinical cases of this kind of surgical technique, a sample of 1253 Exacone (Leone®) implants is examined (Gubbio Hospital), 38% of which are located within the rear upper jaw.

**Results:** Overall implant survival is 98.5%. Our clinical experience shows impressive outcomes also for implants positioned in low-density bone (D4).

**Conclusion:** The success rate for implants clearly proves that the positioning of implants in the maxillary tuberosity is an excellent strategy as an alternative to sinus lifting.

149	Poster – Topic Implant and Guided Surgery
-----	---

Guided insertion of implants in extrem atrophic mandible by evaluation with finite element analysis

**Presenter: Baumann A**

*Department of OMFS, Vienna, Austria*

Co-authors: Baumann A<sup>1</sup>, Geml D<sup>2</sup>, Bonitz L<sup>3</sup>

<sup>1</sup>Department of OMFS, Vienna, Austria, <sup>2</sup>Praxis Geml, Vienna, Austria, <sup>3</sup>Department of OMFS, Dortmund, Germany

**Background and aim:** Insertion of short implants in extremely atrophic mandible may be an alternative to augmentation proce-

dure. Innovation in imaging technique and the accompanying software advance preoperative planning and surgical treatment of these patients. In these anatomic difficult situations guided surgery guarantees the implant position. Prosthetic optimized position may differ from the optimal biomechanical position in the extreme atrophic mandible. Therefore, evaluation of biomechanical forces in the bone with finite element analysis (FEA) may be useful to avoid the risk of a fracture out of the stress forces by insertion of the implants. We therefore considered the FEA for implant planning in extrem atrophic mandible.

**Materials and methods:** Four implants were inserted interforaminal by surgical guide system after evaluation of implant position by 3D-FEA. There were used 8.5/10 mm 3i implants with a diameter of 4.1 mm. After implant insertion a cone beam control was done. The 3D-FEA data were compared with the preoperative data.

**Results:** The surgery was proceeded as planned in all of our patients. The 3 D-FEA analysis showed a minimal difference in comparison with the preoperative planning. Stress lines in the interforaminal region were not increased after implant insertion.

**Conclusion:** Planning of implant position under prosthetic premises can be done with the surgical guide system in extreme atrophic mandible. 3D FEA can help to adapt the implant position on individual biochemical conditions, which may be useful in an extreme atrophic mandible.

150	Poster – Topic Implant and Guided Surgery
-----	---

Use of the concept all-on-four and immediate loading simultaneous in maxillae and mandible with zygomatic and conventional implants

**Presenter: Ferreira E**

*Imppar Odontologia, Londrina, Brazil*

Co-authors: Ferreira E<sup>2</sup>, Kuabara M<sup>1</sup>, Paz L<sup>1</sup>

<sup>1</sup>Imppar Odontologia, Londrina, Brazil, <sup>2</sup>Universidade Sagrado Coração USC, Bauru, Brazil

**Background and aim:** The use of the concept all-on-four, installation of four implants with proper biomechanics distribution, associated with the initial stability allow the rehabilitation with immediate loading of edentulous maxillae and mandibles. The objective of this work is to report the total rehabilitation simultaneous in edentulous patient with the use of the hybrid protocol all-on-four in maxilla and the conventional protocol all-on-four in mandible region, under planning prosthetic reverse.

**Materials and methods:** Patient female, with a good general state of health, attended the clinic griping of lack of stability of their prostheses and dissatisfaction with regard to aesthetics. In the clinical examination, radiographic and tomography, showed up in atrophic maxilla bone and insertion loose of teeth remaining in the mandible. Before the surgical procedures, was held to molding the patient, mounting a half-adjustable articulator, registration of the vertical dimension of occlusion, selection of teeth, making the multifunctional guide and the virtual planning system by placing the program Nobel Guide®. Two zygomatic implants were installed bilaterally, two conventional in the pre-maxilla region and four implants in the region between mental foramens under general anesthesia. There was the casting of transfer using

the multifunctional guide and 24 h after the surgical procedures the upper and lower protocols dentures were installed.

**Results:** After a follow-up of 1 year, with clinical and radiological controls, all implants had no bone infections and no bone resorptions.

**Conclusion:** This case shows that the simultaneous rehabilitation with installation of implants with immediate loading in maxilla and mandible using the concept of all-on-four is a viable option, rapid and effective for the rehabilitator treatment of total edentulous patients.

151	Poster – Topic Implant and Guided Surgery
-----	---

## A new method to evaluate bone quality of the jaws before implant placement

**Presenter:** Koppány F

*Semmelweis University, Budapest, Hungary*

**Co-authors:** Koppány F, Szűcs A, Joób-Fancsaly Á

*Department of Oral and Maxillofacial Surgery, Semmelweis University, Budapest, Hungary*

**Background and aim:** The early success of an implant placement is often described by the primary stability. There are several approaches in the literature that help us to evaluate bone quality in the planned implant site (Misch and Judy, Lekholm and Zarb). These studies were built on subjective determination of bone resistance during drilling. In every day practice the surgeon can run into a much lower quality of bone than expected even if the bone mass seems to be more than enough. In our study, we tried to find objective relationship between the width of the lower cortex of the mandible (mandibular cortical index – MCI) and the overall bone quality of the lower jaw. We based our study on the findings of the Osteodent Project 2006. Their result showed a high specificity of the mandibular cortical width for osteoporosis and they suggested that panoramic X-ray could be a useful tool in determining osteoporosis.

**Materials and methods:** Forty-eight patients, 104 implants were examined. We investigated only 'simple' cases in the mandible without any bone grafting procedures. Primary stability values were measured using Periotest. The width of the lower cortex was also measured on specific sites in mm s. Statistical analysis was then performed.

**Results:** Our findings showed a significant relationship between the primary stability values and the MCI, though more of the changes of the primary stability could not be explained by the changes in the cortical thickness.

**Conclusion:** Owing to the relatively small number of cases we could not set the threshold for unfavourable primary stability. Also the implants that were measured had an optimal or around optimal primary stability so we had a small number of cases to investigate the poor primary stability directly. The usefulness of this method involves only implants that were placed in the lower jaw without surgical complications and without any bone grafting procedures. Measuring the width of the lower cortex of the mandible can give us useful data about the bone quality and can help the surgeon in planning and to choose the appropriate technique without running into unexpectedly low bone quality. Regarding that in so-called 'simple' cases only panoramic X-rays

are taken – and the availability of cone beam CT technology is still limited – this method could be helpful in the everyday praxis.

152	Poster – Topic Implant and Guided Surgery
-----	---

## Stereolithography and computer guided oral implant surgery: a systematic review

**Presenter:** Valente F

*Private Practice, Rome, Italy*

**Co-authors:** Valente F<sup>1</sup>, Sbrenna A<sup>2</sup>

*<sup>1</sup>Private Practice, Rome, Italy, <sup>2</sup>Private Practice, Perugia, Italy*

**Background and aim:** Placing implants flaplessly using computer assisted surgical guides is described as an effective technique but placing implants using conventional methods would also be described as an effective technique. Therefore, how do we justify the additional radiation dose, effort and costs for such an approach? Flapless oral implant surgery, also called minimally invasive oral implant surgery (MIOIS), combined with the use of stereolithographic surgical templates (SST) apparently offers several significant advantages over free-hand flapless surgery or free-hand traditional open flap technique and an increasing number of clinicians worldwide are using this new exciting procedure. However, in spite of the recent revival studies focusing on the efficacy of MIOIS, literature about the combination of MIOIS and SST is scarce. The purpose of this presentation is to analyse and summarize the information through a systematic review of the literature available.

**Materials and methods:** The Internet and the medical literature database of PubMed and Medline were used as major data sources. Two different people carried out an independent electronic research to find articles and conference proceedings in the English language published from January 1998 to September 2008. The review procedure consisted of (1) a search into health and medical literature using several key-words and MeSH-terms, (2) a selection of articles based on specific criteria, and (3) a review of each article with regard to the population and sample used, study design, dependent variables addressed, and their findings.

**Results:** Thirty-six studies met the inclusion criteria. Case reports and case series were found with a resulting level of evidence three and strength of recommendation D according to one prominent grading system. Two prospective studies with a 1-year follow-up and one cohort study with a 5-year follow-up were found. No randomized-controlled-trials (RCTs) were found.

**Conclusion:** Based upon these results the following observations were made: (1) literature about the effectiveness of SST in combination to MIOIS is still scarce; (2) there is insufficient reliable evidence to provide recommendations on which are the best effective oral implant surgery procedures (computer-guidance or manual-guidance) or (3) whether the two possible approaches (flapless or flapped) are beneficial to patients/surgeons or not; (4) great caution should be taken when deciding whether to use a computer-guided procedure and (5) consideration must be given to additional radiation exposure dose and costs.

## Sagittal alveolar osteotomy for dental implant placement

**Presenter:** Kayatt F

*Clinica Kayatt, Ponta Pora, Brazil*

**Co-authors:** Esgaib Kayatt F<sup>1</sup>, Kayatt D<sup>2</sup>

<sup>1</sup>*Sioms Campo, Grande, Brazil*, <sup>2</sup>*Clinica Kayatt Ponta, Pora, Brazil*

**Background and aim:** One of the prerequisites for treatment with implants is the presence of an alveolar ridge remaining. However, many patients do not have height or thickness bone enough to meet that condition. The bone resorption after the loss of dental element is a chronic, progressive, irreversible and cumulative, and faster in the first 6 months and continues throughout the life of the patient. The methods available for reconstruction of Atrophic edges are: bone grafts, guided bone regeneration, distraction osteogenesis, and why not, the expansion of the maxillary alveolar ridge.

**Materials and methods:** This technique is taken with the construction of a partial sagittal osteotomy to the most apical portion of the bone present, namely length of the implant to be inserted. Then, with an appropriate instrument, it produces a lateral displacement of slum-plate medullary vestibular and thus the implants are inserted into the alveolar ridge expanded. That is, we will transform a defect in two or three walls. According to Misch, we should make use of a bone substitute, in a defect of five walls, which is an extremely favorable to repair defective bone, where the presence of blood clots is only enough to repair the area. Once the edges are expanded, we make the osteotomy for the insertion of implants, in a conventional way and do the suture and radiographic control.

### Results:

Location of surgery	Number of patients operated	Number of implants inserted
Posterior maxilla	36	77
Anterior maxilla	9	13
Maxilla total	2	16
Posterior Jaw	7	15
Total	54	121

**Conclusion:** According to the results is noticed that the described technique is user-friendly and allows functional-esthetic results with the placement of immediate implants. The predictability between the Branemark protocol and the partial sagittal osteotomy is similar; easy clinical application when indicate.

## A modified approach of sinus floor elevation in the severely resorbed posterior maxilla: a hybrid technique

**Presenter:** Jung UW

*Dental College, University of Yonsei, Seoul, Korea*

**Co-authors:** Jung UW<sup>1</sup>, Hong JY<sup>1</sup>, Hu KS<sup>2</sup>, Kim CS<sup>1</sup>, Choi SH<sup>1</sup>, Cho KS<sup>1</sup>

<sup>1</sup>*Department of Periodontology, Dental College, University of Yonsei, Seoul, Korea*, <sup>2</sup>*Department of Oral Biology, Dental College, University of Yonsei, Seoul, Korea*

**Background and aim:** Sinus elevation procedure using lateral window or crestal approach showed reliable results in implant rehabilitation of maxillary posterior area with limited bone height. However, each procedure has to be performed in relevant indications not to cause complications. In this study, we suggested a hybrid technique which is based on bone-added osteotome sinus floor elevation (BAOSFE) but modified to have a lateral access slot for direct undermining of Schneiderian membrane and also evaluated the results in 11 patients for 2 years.

**Materials and methods:** A total of 22 Straumann SLA<sup>®</sup> implants in 11 patients placed by hybrid technique at the posterior maxillary areas were enrolled in this study. A slot-shaped osteotomy to access was prepared on the lateral wall along the lower border of sinus floor by Piezoelectric device. Schneiderian membrane was reflected through the lateral slot. Following serial sequence of drilling under protection of membrane by periosteal elevator, synthetic bone was grafted through lateral slot and drilled hole. All implants were placed simultaneously with sinus augmentation. Patients were recalled for average of 18.7 months (ranged from 16 to 24 months). The cumulative success rate (CSR) was calculated. Clinical parameters including plaque index (PI), gingival index (GI), probing depth (PD) and peri-implant keratinized tissue (PKT) were recorded. Preoperative residual bone height (RBH) and postoperative augmented bone height (ABH) were measured.

**Results:** Using the hybrid technique, good initial stability was obtained in spite of poor bone quality and quantity. All implants maintained well until last recall and the CSR showed 100%. The mean RBH and ABH were  $4.1 \pm 1.64$  and  $8.76 \pm 1.77$  mm, respectively. There were no specific complications and the clinical conditions around the implants were acceptable.

**Conclusion:** Simultaneous implant placement with sinus augmentation by hybrid technique showed successful clinical results during 2-year observation period and can be a predictable alternative treatment modality in severely resorbed posterior maxilla.

**Acknowledgment:** This work was supported by the Korea Science and Engineering Foundation (KOSEF) grant funded by the Korea government (MEST) (No. R13-2003-013-04002-0).

## Accuracy of the newly developed implant guide system

**Presenter:** Chung SH

*Seoul National University Dental Hospital, Seoul, Korea*  
**Co-authors:** Chung SH<sup>1</sup>, Baek SH<sup>1</sup>, Son WJ<sup>1</sup>, Son WJ<sup>1</sup>

<sup>1</sup>Department of Conservative Dentistry and Endodontics, School of Dentistry, Seoul, National University, Seoul, Korea, <sup>2</sup>Private Dental Practice, Seoul, Korea

**Background and aim:** Precise planning and accurate placement are indispensable for clinical success in dental implantology. With three-dimensional information from computed tomography (CT) and the aid of a surgical guide, surgery can be performed with increased predictability in implant placement. Surgical guides manufactured from the rapid prototyping (RP) method has already proved to be effective in transferring implants to the surgical field. The purpose of this study is to evaluate the total application accuracy of the newly developed implant guide system (EZplant<sup>®</sup>, Seoul, Korea) which is manufactured from the use of the five-axis milling method.

**Materials and methods:** Preoperative CT of the patients and diagnostic casts were taken to decide the implant position on the software. After computer aided planning, a total of 20 implants were placed in 15 partially edentulous patients. Multi-slice CT scan imaging was performed after placement for evaluation. Deviation at hex, deviation at apex, vector deviation were calculated by digital composition of preoperative planning and postoperative CT.

**Results:** All the implant sites healed uneventfully. The deviation calculated was less than other *in vivo* experiments. The surgical guides with the new manufacturing method showed significantly improved performance than other guiding systems with the RP method.

**Conclusion:** In conclusion, this surgical guide can be used as an effective tool in clinical practice.

## Immediate loading of oral implants with advanced surgery: case series

**Presenter:** Dundar M

*School of Dentistry, Ege University, Izmir, Turkey*  
**Co-authors:** Dundar M<sup>1</sup>, Çömlekoğlu E<sup>1</sup>, Kaya E<sup>2</sup>, Gunbay T<sup>2</sup>

<sup>1</sup>Department of Prosthodontics, School of Dentistry, Ege University, Izmir, Turkey, <sup>2</sup>Department of Oral and Maxillofacial Surgery, School of Dentistry, Ege University, Izmir, Turkey

**Background and aim:** Information on immediate loading protocols with advanced surgical techniques is limited. The aim of this clinical case series is to present the preliminary clinical outcome of immediately loaded implants that were placed with advanced surgical procedures, by full-arch fixed dental prostheses (FDPs) in edentulous maxilla and/or mandible.

**Materials and methods:** Total/partially edentulous four patients (age range: 45–65) received a total of 48 sand-blasted, large-grit, acid-etched (SLA-Straumann-ITI) and SLActive dental implants

in the maxilla ( $n = 30$ ) and in the mandible ( $n = 18$ ) and implant-supported fixed provisional prostheses were made within 48 h after surgery. In three cases advanced surgical procedures (bi-maxillary sinus lifting, grafting) were also performed. After 16 weeks of healing time, definitive, solid/angled-screw retained, implant-supported ceramometal FDPs were fabricated. Resonance frequency analysis (RFA) evaluations were recorded at surgery, after 1 month of loading with the provisional implant-supported FDPs as well as 24 months after definitive implant-supported FDPs. Calculations of marginal bone loss (MBL) were performed in radiographs taken at placement, 6, 12, and 24 months of loading.

**Results:** The mean RFA values at surgery, and 1st month were  $63 \pm 2.3$ , and  $71 \pm 2.1$ , respectively, while the mean values at 24-month follow-up were  $83 \pm 2.4$ . MBL (mm) for advanced surgery applied implants were higher ( $2.8 \pm 1.6$ ) than implants placed without advanced surgery ( $1.8 \pm 1.2$ ) during the follow-up.

**Conclusion:** Immediate loading of implants placed with advanced surgical techniques and fixed dental prostheses demonstrated a good short-term clinical outcome, however, long-term studies should be conducted.

## Temperature measurements observed during drilling of implant sites with different irrigation methods

**Presenter:** Strbac GD

*Bernhard Gottlieb University Clinic of Dentistry, Medical University of Vienna, Vienna, Austria*

**Co-authors:** Strbac GD<sup>1</sup>, Hof M<sup>1</sup>, Hoehls S<sup>1</sup>, Unger E<sup>2</sup>, Vasak C<sup>1</sup>, Zechner W<sup>1</sup>, Watzek G<sup>1</sup>

<sup>1</sup>Bernhard Gottlieb University Clinic of Dentistry, Department of Oral Surgery, Medical University of Vienna, Vienna, Austria, <sup>2</sup>Centre for Biomedical Engineering and Physics, Medical University of Vienna, Vienna, Austria

**Background and aim:** High temperature and surgical trauma in bone generated by drills are one of the main factors that may lead to implant failure. The aim of this present study was to investigate temperature changes during implant site preparation with different irrigation methods.

**Materials and methods:** In this study, an *in vitro* bovine rib model was selected to simulate clinical conditions in human bone. To standardise bone density and the relationship between cortical and cancellous bone all bovine bone specimens were taken from the VII.bovine rib. The bovine ribs were cut into sections of 3–2 cm equal vertical thickness samples and stored at  $-30^{\circ}\text{C}$  for investigation. Thermal changes during implant site preparation were recorded at room temperature by two devices with eight calibrated thermocouples (measuring at 2, 4, 10 and 16 mm depths) in a predetermined distance (1 and 2 mm) to the implant drilling sites. A standardised drilling procedure was performed by the use of a computer aided custom surgical unit with reproducible drill cycles. The sequences of each diameter (2/3.5/4.3 mm) and length (10/16 mm) were performed with different irrigation methods (without/internal/external) according to the standard protocol (Nobel Replace<sup>TM</sup> Select Tapered) at 800 rpm.

**Results:** The maximum increase of temperature was recorded at 16 mm depths without irrigation ( $3.898 \pm 1.1645^{\circ}\text{C}$ ) during implant site preparation with cutting drills of 2 mm diameter compared to internal ( $1.536 \pm 0.2420^{\circ}\text{C}$ ) and external ( $1.836 \pm 0.6334^{\circ}\text{C}$ ) irrigation.

In all sequences of each diameter (2/3.5/4.3 mm) and depths (10/16 mm) significant differences were observed between irrigated drills (internal/external saline irrigation) compared to drills without irrigation. No significant differences were recorded between external saline irrigation and implant sites preparation of 4.3 mm diameter without irrigation at depths of 16 mm ( $P = 0.0777$ ).

**Conclusion:** This *in vitro* investigation under standardised conditions confirms the efficiency of saline irrigation during drilling of implant sites as reported in previous published investigations.

158	Poster – Topic Implant and Guided Surgery
-----	---

The comparison of primary stabilization of dental spiral implants according to their size and the technique of preparation of implants' cradle

**Presenter:** Nieckula P

*Medical University of Warsaw, Warsaw, Poland*

**Co-authors:** Wychowański P<sup>1</sup>, Nieckula P<sup>1</sup>, Panek-Nieckula M<sup>2</sup>, Krzywicki D<sup>1</sup>, Marczyński B<sup>1</sup>, Piotrowski P<sup>3</sup>, Syzdół A<sup>1</sup>, Wojtowicz A<sup>1</sup>

<sup>1</sup>Medical University of Warsaw, Warsaw, Poland, <sup>2</sup>Private Practice, Warsaw, Poland, <sup>3</sup>Alpha-Piotr Piotrowski Company, Warsaw, Poland

**Background and aim:** Recently the implantoprosthodontic treatment could be started in cases with poor anatomical conditions. It concerns the patients with the vertical lack of bone due to the localization of inferior alveolar canal and low position of maxillary sinus floor. In these cases the bone augmentation techniques have to be performed or there is the necessity to insert short implants. The procedure of bone regeneration has plenty disadvantages and shortages. The use of short implants seems to be less invasive. Despite of innovation of macroscopic shape and improvements of implant surface there are lots of doubts concerning to the primary stabilization and stress resistance of short implants. The aim of the study is to present the differences in primary stabilization of dental implants depending on the size and technique the implant cradle preparation.

**Materials and methods:** The A.B. Dental Implants of different size starting in the length from 6 to 16 mm and in platform diameter from 3.75 to 6 mm were used in the study. The implants cradles were prepared in three different ways:

(1) In the first group 10 cradles were prepared using cylindrical drills in the dimension adjustable to the producer recommendation.

(2) In the second group ten cradles were prepared using conical drills in the dimension adjustable to the producer recommendation.

(3) In the third group ten cradles were prepared using cylindrical drills, but the only first drill performed full length, next ones prepared the cradle only partially.

The torque, the primary stabilization and the resistance for stretching test were performed.

**Results:** The differences between torque of implant insertion, Periotest values and stretching test in described groups of

implants and implant installation techniques were showed in tables. These results were averaged and statistically analyzed.

**Conclusion:** (1) The short spiral implants are able to endure similar loading than the long ones.

(2) The short spiral A.B. Dental Implants may use as a proper alternative for bone augmentation treatment especially in lateral part of dental arches.

159	Poster – Topic Implant and Guided Surgery
-----	---

Resonance frequency analysis of two unsplinted immediately loaded nanotite implants supporting mandibular overdentures

**Presenter:** Lingbeek S

*Centre Of Oral Implantology C.T.I., Haaksbergen, The Netherlands*

**Co-authors:** Lingbeek S<sup>1</sup>, Goene R<sup>2</sup>

<sup>1</sup>Centre of Oral Implantology C.T.I., Haaksbergen, The Netherlands,

<sup>2</sup>Tendens Tandartsen, Amsterdam, The Netherlands

**Background and aim:** Resorption of alveolar bone in the edentulous mandible can cause inadequate retention and stabilization of conventional tissue-supported dentures compromising the patient's ability to speak and masticate, comfort and appearance. The overdenture restorative approach with placement of two implants splinted with a rigid bar in the interforaminal region and submerged healing for at least 2 month is well documented. Immediate loading of unsplinted implants supporting mandibular overdentures with a chairside technique is a procedure that is possible with Locator abutments. The objective of this prospective, observational study was to immediately load two nanometer-scale textured implants in support of a mandibular overdenture, to assess implant stability with RFA during the first 12 weeks and to evaluate implant survival and prosthesis outcomes for up to 1 year.

**Materials and methods:** Patients to be enrolled in the study had to have worn a full mandibular denture for over 1 year which was to be transformed into the overdenture; otherwise a new denture would be fabricated before implant placement procedures. Two 4-mm diameter implants (NanoTite Prevail<sup>®</sup>, Biomet 3i) were placed in the canine regions and an Ostell Type 15 SmartPeg<sup>®</sup> was attached to each to obtain a baseline Implant Stability Quotient (ISQ) reading. Locator abutments were connected to implants and following a chairside technique the overdenture was fabricated using the lightest retentive male to be more forgiving to the implant. ISQ values were recorded at 3, 6, and 12 weeks and patients were evaluated for prosthesis function and implant survival for up to 1 year.

**Results:** Fifteen patients were enrolled, of which three had existing conventional dentures that could be converted to overdentures. The mean ISQ values were  $80.1 \pm 4.8$  at baseline,  $81 \pm 4.2$  at 3 weeks,  $79.5 \pm 4.0$  at 6 weeks and  $78.7 \pm 5.0$  at 12 weeks. One implant with an ISQ of 73 at placement failed after 3 weeks of function. Two months thereafter the implant was replaced in support of the same overdenture. The 1-year cumulative implant survival rate is 96.7% and 1-year prosthesis success is 100%.

**Conclusion:** The results suggest that two immediately loaded implants can successfully support mandibular overdentures, that implant stability can be assessed with RFA, and that the Locator



system can facilitate the revision of a conventional denture into an overdenture in one appointment. With this technique patients have the pleasure of stability and comfort within a few hours.

160	Poster – Topic Implant and Guided Surgery
-----	---

### Effect of calcium metaphosphate coating on bone-to-implant contact: a study using the rabbit tibia model

**Presenter:** Lee HJ

*Seoul National University Bundang Hospital, Gyeonggi-do, Korea*

**Co-authors:** Yeo IS, Lee HJ

*Seoul National University Bundang Hospital, Gyeonggi-do, Korea*

**Background and aim:** The purpose of this study was to evaluate the effect of calcium metaphosphate (CMP) coating on osseointegration of titanium dental implant using the rabbit tibia model.

**Materials and methods:** Ten screw type titanium (cp-Ti, grade IV) implants were coated with calcium metaphosphate by dip-spin method. Such a coated implant (Osstem Co. Ltd., Busan, Korea) was installed in one tibia of a New Zealand White rabbit and a turned one without any surface modification (control) in the other. Ten New Zealand White rabbits were used. The bone responses, 2 and 6 weeks after implant insertion, were evaluated and compared by histomorphometry.

**Results:** The CMP-coated implants showed significantly superior results in bone-to-implant contact, compared with the control ( $P < 0.05$ ). There were significant differences both at 2 and 6 weeks of healing ( $P < 0.05$ ).

**Conclusion:** It is suggested that calcium metaphosphate coating may play a significant role in faster and stronger osseointegration of dental implant.

161	Poster – Topic Implant and Guided Surgery
-----	---

### Computed tomography-derived stereolithographic surgical guides in implant placement and the prosthodontic rehabilitation of a patient

**Presenter:** Alniacik G

*University of Selcuk, Konya, Turkey*

**Co-authors:** Alniacik G<sup>1</sup>, Inan O<sup>1</sup>, Dolanmaz D<sup>2</sup>, Yildirim G<sup>2</sup>

<sup>1</sup>*Department of Prosthodonti, University of Selcuk, Konya, Turkey,*

<sup>2</sup>*Department of Oral and Maxillofacial Surgery, University of Selcuk, Konya, Turkey*

**Background and aim:** Since the 1990s, many medical teams have approached the problem of implant case planning with the assistance of computer applications. Traditionally the clinician determines the bone quantity using the radiographs and clinical probing of the mucosa. However, with advent of CT scans, three dimensional computer software solutions, and stereolithographic drill guides, the process of determining where ideally to place implants in bone has been greatly enhanced. The use of computer technology in implantology has been a major advantage. Based on the computer-made implant planning, a stereolithographic SuriGuide can be built to transfer the planning towards the surgery.

**Materials and methods:** A 57-year-old man requested to have implants placed to support his total edentulous mandibular ridge and edentulous maxillary posterior ridge. Clinical and radiographical examination revealed an inadequate height in right maxillary posterior ridge which is not suitable for placing implants. For that reason, external sinus lifting operation was made then two implants were placed at the same operation. His total edentulous mandibular ridge was appropriated implant surgery. Fixed partially prosthetic restoration with implants was planned for mandibular prosthodontic rehabilitation. SimPlant was used to simulate the implant placement for his mandibular ridge. The surgery was carried out with careful placement of a bone-supported surgical guide made using stereolithography, and all implants were successfully placed. After surgical treatment all ceramic fixed partial dentures reinforced with zirconia were fabricated.

**Results:** Operation was done successfully. Owing to the implant surgery, postoperative swelling and pain was limited. The patient recalled after a week and a month to examining his oral hygiene. At the last follow-up of the patient, function was well, and no signs of complication associated with new crowns and soft tissue were observed.

**Conclusion:** SimPlant is good and effective method for implant surgery. It reduces operation time and position errors of implant placement.

162	Poster – Topic Implant and Guided Surgery
-----	---

### Dental implants placed in vertically distracted free vascularized fibula flap for mandible reconstruction: survival rate and factors affecting the outcome

**Presenter:** Wu YQ

*Shanghai 9th People's Hospital, Shanghai, China*

**Co-authors:** Wu YQ<sup>1</sup>, Zhang CP<sup>2</sup>, Zhang ZY<sup>1</sup>, Huang W<sup>1</sup>, Zhang ZY<sup>2</sup>

<sup>1</sup>*Shanghai 9th People's Hospital, Shanghai, China*

**Background and aim:** The purpose of this study was to evaluate the survival rate of dental implants placed in vertically distracted free vascularized fibula flap for mandible reconstruction.

**Materials and methods:** The study group included eight patients who had undergone vertical distraction following tumor surgery with subsequent placement of 21 implants between 2003 and 2008. Their age was 28–55 years (mean age: 43 years). Of the eight patients, five were male and three were female. Three of the eight patients were completely edentulous while all other patients were partially edentulous. Vertical peri-implant bone deficit was measured on the distal and mesial surfaces from panoramic radiographs obtained at implant loading and again 1 year later.

**Results:** None of the implants was lost. The increase of vertical bone height was stable and enabled placement of dental implants without any complications. The cumulative implant success and survival rates of implants were 95.2% and 100%, respectively.

**Conclusion:** Implants placed in the distracted areas were demonstrated to integrate normally. The survival rate of the implants placed in distracted fibula bone is similar to implants placed in native bone.

## Maxillary ridge expansion with simultaneous implant placement: a case series

**Presenter:** Leghissa GC

*General Practitioner, Milan, Italy*

**Co-authors:** Leghissa GC<sup>1</sup>, Demarosi F<sup>2</sup>

<sup>1</sup>General Practitioner, Milan, Italy, <sup>2</sup>University of Milan, Milan, Italy

**Background and aim:** The placement of implants in edentulous areas is often compromised by a thin alveolar crest. Thus, widening the space between the two cortical bones offers advantages from an esthetic, biomechanical, and functional point of view. The objectives of this study were to present results obtained with the osteotome technique with immediate implant placement in thin edentulous maxillary ridges, to evaluate the survival and success rates of implants placed in the treated areas, and the stability of bone expansion over time.

**Materials and methods:** The technique consisted of preparing the implant bed by progressively operating the osteotomes until the desired expansion was achieved. Three to four months after implant placement, abutments were connected and prosthetic rehabilitation was initiated. Clinical monitoring was carried out 3, 6, and 12 months after surgery and then annually, with visual and radiographic examinations. Success criteria included effective placement and primary stability of the planned implant, implant stability at each control, absence of pain or any subjective sensation at each control, absence of peri-implant infection with suppuration, and absence of continuous radiolucency around the implant.

**Results:** Twenty-three patients with partial edentulism associated with horizontal resorption of the ridges, were treated by this technique to obtain a wider bony base for better implant placement. In the same procedure, 35 endosseous titanium implants were inserted. The initial alveolar ridge width ranged from 2.5 to 4.5 mm, while at the end of the expansion procedure the width ranged from 6 to 7.5 mm. Follow-up ranged from 6 to 68 months, calculated from the day of the expansion procedure. All 35 completed implants fulfilled the pre-defined criteria of success, based on clinical and radiographic examination, and were classified as successful implants. Moreover, all patients had acceptable function of the implant-supported prostheses, with no pathologic signs or symptoms and a satisfactory esthetic result.

**Conclusion:** Within the limits of this study, the following conclusions can be drawn: the technique appeared to be relatively simple and the incidence of intraoperative and post-operative complications was limited, success and survival rates of implants placed in the expanded areas were within the limits of criteria proposed by Albrektsson and were consistent with those of implants placed in native bone, peri-implant clinical parameters were consistent with those reported in the literature, and the expansion of narrow ridges with osteotomes was stable over time, with limited resorption of buccal bone, as demonstrated by post-operative follow-up.

## Ridge widening and immediate implant placement: a new simplified atraumatological technique

**Presenter:** Camerino M

*Private Practitioner, Chieti, Italy*

**Co-authors:** Di Alberti L, Camerino M, Donnini F, Rossi G, Di Alberti C

*Private Practitioner, Chieti, Italy*

**Background and aim:** Alveolar atrophy may present an anatomical limitation to the placement of endosseous implants. So narrow alveolar ridges remain a serious challenge for the successful placement of implants. This article reports a technique for widening the atrophic ridge by splitting the alveolar bone longitudinally using a novel bone expansion screw kit; treatment of ridges as thin as 2.5 mm at the alveolar crest and simultaneous placement of dental implants. A novel approach for ridge expansion without the use of osteotomes and surgical hammer has been compared with classical techniques. The newly developed compression and expander kit improved the treatment in split crest and soft bone compression. A simple bone expansion procedure had enabled a better implantation and better implant primary stability. The expansion and compression kit has prevented traumatic osteotomy, increased bone density, increased implant primary stability and gave a perfect gradual control of bone expansion.

**Materials and methods:** Ten patients have been divided in two groups of five. The study group has been treated with the novel expander screws and the control group have been treated with classical technique. Single and multiple implants have been positioned in narrow bone using the experimental kit and the commercially available surgical kit. All narrow bone crest have been expanded at the need to fit implant of diameter 3.75 and 4.2 mm.

**Results:** Results showed that the expander screws gave better stability of the implants and better control of the expansion procedure for a more secure and atraumatic surgery. The advantages of this technique for patients include less surgical trauma and reduced treatment time.

**Conclusion:** Based on these findings, split bone with this wider screws are a promising alternative for alveolar ridge reconstruction in dental implantology.

## Rehabilitation of congenitally missing mandibular incisors with autogen bone block graft and implant placement

**Presenter:** Akay MM

*Oral Surgery, Izmir, Turkey*

**Co-authors:** Akay MC, Gunbay T, Sezer B, Ozveri Koyuncu B, Yuce SM

*Oral Surgery, Izmir, Turkey*

**Background and aim:** Oligodontia is agenesis of six teeth or more, excluding third molars. The etiology of congenital absence of teeth is believed to be involved in heredity or developmental

anomalies. Treatment options include orthodontic therapy, implants, adhesive techniques, and removable prosthesis. Therefore, to produce the most predictable esthetic results, it is important to choose the optimal treatment option. The aim of this report is to describe the management of a 15-year-old patient with oligodontia including six permanent teeth.

**Materials and methods:** A 15-year-old man with congenitally missing permanent maxillary lateral and mandibular central and lateral incisors was presented for treatment. For mandibular anterior region implant supported zirconium-oxide based all-ceramic FPD was selected as a treatment option. Owing to the limited bone width associated with the mandibular anterior edentulous region, an autogen bone grafting procedure was made to achieve enough bone volume for implantation. Two implants were placed into mandibular anterior region to support four mandibular incisors which were restored by 4-U zirconium-oxide based FPD. After osseointegration period of 6 months, 4-U zirconium-oxide based FPD was fabricated to replace four mandibular incisors. For maxiller anterior region, treatment plan was inclined to restore maxillary lateral incisors with two pieces of 3-U zirconium-oxide based FPD.

**Results:** The patient was followed for 2 years. Only minor loss of bone support at the fixture was observed (1.2 mm), while adjacent tooth surfaces showed some minimal bone loss.

**Conclusion:** Patients with congenitally missing incisors often raise difficult treatment planning issues. Implant placement and restoration is a preferred solution for the replacement of missing teeth in any age group but is particularly beneficial for younger patients with oligodontia. The use of zirconium-oxide based FPD that was supported by tooth or implant, is a treatment modality for replacing missing teeth, and provides patients with functional and esthetic restorations. With the advantages like esthetic and fracture strenght of zirconia, zirconium-oxide based FPD's become very popular when compared with metal-reinforced FPD's.

166 Poster – Topic Implant and Guided Surgery

Treatment of the edentulous maxilla with sinus pneumatization by using stereolithographic surgical templates and dental implants: a case report

**Presenter: Tuncer HY**

*Hacettepe University, Ankara, Turkey*

**Co-authors: Meral G<sup>1</sup>, Hersek N<sup>2</sup>, Tuncer HY<sup>1</sup>, Bacaksiz<sup>2</sup>**

<sup>1</sup>Department of Oral and Maxillofacial Surgery, Hacettepe University, Ankara, Turkey, <sup>2</sup>Department of Prosthodontics, Hacettepe University, Ankara, Turkey.

**Background and aim:** Presurgical planning is essential to obtain esthetic and functional implants, and a variety of techniques is available. In cases of compromised host bone or increased esthetic demand, more detailed information about patient is required for planning. Standard panoramic and periapical radiographs are essential for assessing bone anatomy at uncomplicated cases but more sophisticated radiographic analysis systems are required such as conventional computed tomography (CT) or cone beam computed tomography (CBCT) in

complicated ones. By obtaining CT images it is possible to fabricate surgical templates which transfers the preplanned implant positions to the patient and eliminates the incorrect positioning of the implants or injuring anatomical structures such as inferior alveolar nerve or maxillary sinus. The aim of this case report presentation is to demonstrate the successful results of implant placements with stereolithographic templates in a patient with bilateral pneumatized sinuses.

**Materials and methods:** A 45 years old male patient referred to our clinic, demanding implant supported fixed prosthesis. The radiographic evaluation of the patient revealed pneumatized maxillary sinuses which will not allow implant placement at the posterior maxilla. Because of these anatomic limitations a cone beam computed tomography was acquired with radio-opaque maxillary denture. The cone beam computed tomographic evaluation showed that maxillary anterior bone segment is inadequate horizontally and it is very difficult to place dental implants without stereolithographic surgical template. After this information a surgical stereolithographic template was fabricated and eight dental implants (Astratech Dental Implants, Mölnådal, Sweden) were placed. After a healing period of 3–5 months, implants were uncovered and implant supported fixed prosthesis were fabricated for maxilla and mandible.

**Results:** Implant supported fixed prosthetic rehabilitation of patients with bilaterally pneumatized maxillary sinuses represent a major challenge for prosthodontist and surgeon both. In this patient implants with favorable positions was placed by using SLT templates and this technique is very reliable in treating patients with pneumatized sinuses or bone inadequacies at any dimension.

**Conclusion:** The clinical results of this poster presentation suggested that SLT's are reliable in implant placement in complicated cases and could eliminate the need of additional surgical approaches.

167 Poster – Topic Implant and Guided Surgery

Clinical and radiographic evaluation of seven implants. Osseointegration rate and bone level stability: 1–3 years prospective study

**Presenter: Gisakis I**

*Private Practice, Larissa, Greece*

**Co-authors: Zabaras D, Gisakis I, Bouboulis S, Spanos A**

*Department of Dental Implants, Hygeia Hospital, Athens, Greece*

**Background and aim:** The aim of this paper is to present the results of a prospective, clinical and radiographic, study regarding osseointegration rate, peri-implant bone level changes and survival rate after loading of Seven<sup>®</sup> implants (Medical Implant System, Shlomi, Israel).

**Materials and methods:** One thousand four hundred and sixty-eight patients (664 males, 804 females), with no medical history, participated in the study. In total, 5540 implants were placed. The diameter of the implants was: (a) 3.75 mm, 1343 implants (24.24%), (b) 4.2 mm, 2319 implants (41.86%), (c) 5 mm, 1878 implants (33.89%). The length of the implants was: (a) 8 mm, 1063 implants (19.19%), (b) 10 mm, 1518 implants (27.4%), (c)

11.5 mm, 1505 implants (27.17%), (d) 13 mm, 1454 implants (26.25%). 2533 implants (45.72%) were placed in host bone and 3007 implants (54.28%) in augmented bone (with guided bone regeneration methods). 3012 implants (54.37%) were placed in the maxilla and 2528 implants (45.28%) in the mandible. The evaluation period was 12–36 months. All patients had a detailed clinical and radiographic examination every 3–6 months.

**Results:** Osseointegration was achieved in the great majority of the cases examined (5525 implants, 99.73%) ( $P < 0.001$ ). Fifteen implants failed to osseointegrate (0.27%). Out of them, nine implants were placed in augmented bone and six implants in host bone ( $P > 0.05$ ). Marginal bone loss around implants ranged from 0.07 mm ( $\pm 0.05$ ) in cases of host bone, to 0.13 mm ( $\pm 0.06$ ) in cases of augmented bone ( $P > 0.05$ ). Peri-implantitis was revealed in 83 implants (1.49%), mostly after the 24th month (71 implants, 85.54% in this group) ( $P < 0.05$ ). Out of them, 51 cases (61.45%) observed in male patients, while 32 cases in female patients (38.55%), mainly due to poor oral hygiene ( $P > 0.05$ ). Forty-nine cases (49.39%) of peri-implantitis were observed in the maxilla and 42 cases (50.6%) in the mandible. No implant was lost after loading during the observation period.

**Conclusion:** (a) the results of this study showed exceptional osseointegration rate (99.73%), (b) the application of bone regeneration methods, prior or in conjunction with implant placement, does not interfere with osseointegration, (c) marginal bone loss around implants was minimal, (d) the majority of failed osseointegration and peri-implantitis cases were observed in male patients, but no statistical significant differences were established regarding the sex of the patients, (e) implant survival rate after loading was 100%.

#### 168 Poster – Topic Implant and Guided Surgery

### Simultaneous implant installation with bone graft in cleft alveolus patients

**Presenter:** Seo MH

*Boramae Hospital, Seoul National University, Seoul, Korea*

**Co-authors:** Lee WD<sup>1</sup>, Choung PH<sup>2</sup>, Kang N<sup>3</sup>, Suh JD<sup>1</sup>

<sup>1</sup>Boramae Hospital, Seoul National University, Seoul, Korea, <sup>2</sup>Seoul National University, Seoul, Korea, <sup>3</sup>Grand Plastic Surgery Clinic, Seoul, Korea

**Background and aim:** The placement of endosseous implants in the maxilla or mandible is usually not allowed during growing of jaws. But we performed the simultaneous implant installation with iliac bone graft, resulting in the survival rate of 94.6%, which made us to do the procedure in cleft alveolus patients, preventing the bone loss between bone graft and delayed implant installation. In growing patients, the use of endosseous implants has been controversy. But, the effect of implant on the bone growing is discovered in 1991, 1992. The placement of endosseous implants in the maxillary or mandibular midline and posterior to the mandibular canines is not allowed during the growing of jaws. Canines are not allowed during the growing of jaws.

**Materials and methods:** Block bone graft and immediate implant installation was done in 22 patients (76 implants). All patients

were followed up for at least 12 months after fixture insertion. Perioperatively, at fixture insertion, at crown placement and at annual examinations, clinical radiographic resgistration were performed and the change of septal bone height were observed.

**Results:** Survival rates was 94.6% and only three implant was removed. On the base of these data, iliac bone graft and immediate installation was performed in nine cleft alveolus patient (11 implants).

**Conclusion:** We can take the advantage of bone graft and rehabilitation of loss of teeth. In case selection, the skeletal maturation of children and adolescent and the horizontal distance between the fixture before placing implant was carefully considered.

#### 169 Poster – Topic Implant and Guided Surgery

### Sparing sufficiency strategy with short endopore dental implants

**Presenter:** Nikolsky V

*Samara State Medical University, Samara, Russian Federation*

**Co-authors:** Nikolsky V<sup>1</sup>, Maksyutov A<sup>3</sup>, Nikolskaya G<sup>2</sup>, Nikolskaya L<sup>2</sup>

<sup>1</sup>Samara State Medical University, Samara, Russian Federation,

<sup>2</sup>Moscow Dental Business Implant Training Center, Moscow, Russian Federation, <sup>3</sup>Kirov (Vyatka) State Medical Academy, Kirov, Russian Federation

**Background and aim:** There are a lot of patients with small length of crestal bone and bad conditions for dental implantation in a maxilla posterior area because of anatomical particularities of maxilla sinus. There are a lot of patients with severe bone atrophy after teeth extractions. We and our patients prefer Sparing Sufficiency Strategy with short dental implants instead of pre-implantation augmentation in these cases. The objects of the study are to evaluate the survival rate, the clinical and radiographic outcomes of short (5 and 7 mm) Endopore dental implants.

**Materials and methods:** The research design included 1 to 2-years controlled, randomized and multicenter clinical study. Two hundred and ten short porous Endopore implants (Innova, Sybron) were used in 117 partially edentulous patients without any augment procedures: 148 implants (70.5%) 4.1 mm wide and 7 mm long with internal hex and 62 implants 5 mm wide and 5 mm long with external hex. All implants were submerged. Implantation sites located in a posterior area: 133 implants (63.3%) in maxilla and 77 in mandibula. Teeth at implant sites had been extracted at least 3 months before implantation. A types of bone were C and D (U. Lekholm and G. Zarb, 1985). The bone quality types were 3 (most often) and 4 in maxilla, 1 (more often) and 2 in mandibula. A radiographic evaluation was performed.

**Results:** Only one implant (0.5%) was lost before loading. After 3 months healing period all others implants were osseointegrated. Mean radiographic bone loss before loading measuring both interproximal surfaces was 0.15 mm (minimum 0, maximum 0.7 mm). Sixty-two implants were restored with single crowns, 69 implants were loaded with two or three splinted

crowns and 79 implants with 24 bridgework. Thirty-two implants were used in united crowns and bridgework with Pitt-Easy (Oraltronics, Sybron) dental implants. Mean CIR (crown or extrabone part/implant or intrabone part length ratio) were 1.44 for 7 mm long implants (min. 1, max. 2.2) and 1.59 for 5 mm long implants (min. 1, max. 2.7). There was not CIR more than 1.9 for implants with single crown. Mean bone loss after 1 to 2-years loading (mean 15.4 months) was 0.31 mm (min. 0, max. 0.9 mm). No one implant was lost during total loading period.

**Conclusion:** No significant differences were found in clinic and radiographic parameters between different CIR implants and also between 5 and 7 mm long implants. Differences in bone loss for two prosthetic types (single crowns – splinted crowns and bridgeworks) were statistically significant ( $P < 0.05$ ).

Short (5 and 7 mm) porous Endopore dental implants (Innova, Sybron) showed high overall survival rate (99.5%) and low crestal bone loss. Sparing Sufficiency Strategy with short Endopore implants instead of performing pre-implantation augment procedures and using longer implants may be considered as a good alternative treatment options.

#### 170 Poster – Topic Implant and Guided Surgery

### Clinical case: bimaxillar all-on-4 with NobelGuide™

**Presenter:** Bangola N

*MaloClinics, Lisbon, Portugal*

**Co-authors:** Bangola N<sup>1</sup>, Maló P<sup>2</sup>, Lopes A<sup>3</sup>

<sup>1</sup>*MaloClinics, Lisbon, Portugal*

**Background and aim:** The purpose of this patient's presentation is to demonstrate the simultaneous rehabilitation of both jaws with an immediate placed fixed prosthesis, connected after surgery, using the NobelGuide™ concept and following the All-on-4™ surgical technique.

**Materials and methods:** A male patient came to Maló Clinics concerned with poor retention and prosthetic stability due to the reabsorbed maxilla and mandible. Clinical and radiographic examination was performed to assess the inclusion criteria: sufficient bone volume and queratinized tissue, low smile line and mouth opening capability over 50mm. Upper and lower dentures that respected functional and aesthetic requirements were used as radiographic guides for CT scan. Surgical templates were made after computer planning using NobelGuide™ Procera® software. Four implants were placed, in each jaw, according to the All-on-four protocol (Maló et al. 2003, 2005) and an immediate, implant retained, all acrylic prosthesis was connected.

**Results:** All the implants were placed with an insertion torque > 50 N cm allowing immediate function. Immediate all acrylic prosthesis respecting functional and aesthetic requirements were placed. At 6 months evaluation implants fulfilled all success criteria.

**Conclusion:** The use of the NobelGuide™ concept with the All-on-four technique for oral rehabilitation of edentulous arches appears to be a predictable solution when inclusion criteria are respected. In addition, as it is a flapless procedure it provides a comfortable, cost and time saving treatment. Despite the promising

results, abusive inferences must not be taken regarding the nature of this single case study.

#### 171 Poster – Topic Implant and Guided Surgery

### Extraction socket closure by the double membrane technique after immediate implant placement

**Presenter:** Yun JH

*College of Medicine, Kwandong University, Myongji Hospital, Goyang, Korea*

**Co-authors:** Yun JH<sup>1</sup>, Choi SH<sup>2</sup>, Cho KS<sup>2</sup>

<sup>1</sup>*Department of Dentistry, College of Medicine, Kwandong University, Myongji Hospital, Goyang, Korea,* <sup>2</sup>*Department of Periodontology, Research Institute for Periodontal Regeneration, College of Dentistry, Yonsei University, Seoul, Korea*

**Background and aim:** To improve patient comfort and shorten the treatment period, the immediate placement of implants into extraction sockets has been proposed. Immediate implantation presents challenges for site healing and osseointegration. In addition, there is a difficulty in obtaining complete coverage of the extraction socket by soft tissue especially in posterior area. This subject will be illustrated with clinical cases of posterior immediate implant placement using double membrane technique (collagen membrane + dense PTFE membrane) in order to perform immediate guided bone regeneration around installed implants without primary flap closure, facilitating the preservation of keratinized mucosa.

**Materials and methods:** Atraumatic tooth extraction was performed and followed by meticulous curettage of the granulated tissue in socket. Wide diameter implant was immediately placed after extracting maxillary posterior tooth. Large gap between a coronal portion of fixture and adjacent bony walls was filled with allograft. In addition, a collagen membrane (lower) and dense PTFE membrane (upper) was placed layer-by-layer to make a closure of extraction socket without primary flap closure and prevent graft particle loss. Simple interrupted 4-0 sutures were applied across the membranes. Postoperatively, the patient was observed every week and instructed to rinse 0.12% chlorhexidine digluconate three times a day.

**Results:** Primary stability of implants was obtained. Wound healing was generally uneventful showing no sign of infection. Upper dense PTFE membrane was left exposed for 4 weeks. After then, the membrane was gently removed using forceps without flap elevation. Clinically, a lot of plaque deposition was shown on outer surface of dense PTFE membrane, but there was no plaque deposition on inner surface. Moreover, SEM (scanning electron microscope) view of removed membrane showed limited amount of bacteria on inner surface of membrane. Final restoration was delivered after conventional healing period of dental implants. It was shown that peri-implant tissue was favorable in clinical and radiographic finding.

**Conclusion:** The closure of extraction socket and immediate guided bone regeneration using the double membrane technique (collagen membrane + dense PTFE membrane) may have a good clinical outcome after immediate placement of a dental implant in posterior area.

## Immediate implant placement in infected sites: a prospective study

**Presenter: Marconcini S**

*Istituto Stomatologico Tirreno, Pisa, Italy*

**Co-authors: Marconcini S, Barone A, Cornelini R, Covani U**

*Istituto Stomatologico Tirreno, Lido di camaiore, (Lucca), Italy*

**Background and aim:** Immediate implant placement has several advantages, such as reduction of the number of surgical treatments and reduction of the time between the tooth extraction and the placement of the definitive prosthesis. However, there are still some situations which could jeopardize the success of the afore-said therapy, such as the presence of an infection caused by periodontal disease or periapical lesions. The objective of this study was to evaluate the clinical success of implants placed immediately after tooth extraction in periodontally affected sites.

**Materials and methods:** Twenty-six adult patients were scheduled in for tooth replacement. The selected teeth were carefully removed. Preparation of the alveoli was then performed for placement of the implants. The following clinical parameters were evaluated for each patient at the time of the first surgery and 6 months after implant placement: Implant bone level; bone crest position; defect width. Antibiotics (Amoxicillin 500 mg four times daily for 4 days), anti-inflammatory (1 g Nimusulide one time daily for 4 days) and Chlorhexidine mouthwash were prescribed during the post-operative period.

**Results:** The healing period was uneventful for all patients. All the implants had osseointegrated. At the end of the 6 months follow-up, patients were asymptomatic and showed no signs of infection or bleeding when probed.

**Conclusion:** On the basis of this study implants placed immediately after tooth extraction in periodontally affected sites may be a valid operative technique, if adequate pre- and postoperative care is taken.

## Value of navigation, prefabricated prosthetics and full ceramic final restoration in a demanding case of partial edentulism

**Presenter: Gorjanc J**

*Medicinski Center Gorjanc, Prevalje, Slovenia*

**Co-authors: Gorjanc J<sup>1</sup>, Gorjanc M<sup>2</sup>, Lokar B<sup>3</sup>**

*<sup>1</sup>Medicinski Center, Gorjanc, Prevalje, Slovenia, <sup>2</sup>Implant Institute Ljubljana Slovenia, <sup>3</sup>Dental Laboratory Lokar Ljubljana Slovenia*

**Background and aim:** In patients with extreme ridge resorption and high esthetic expectations the treatment team is sometimes confronted with large problems due to time-consuming and technically difficult steps. Clinical examination, plaster cast analysis and standard radiologic information are usually not enough to predict the outcome to a sufficient extent. Lack of sufficient predictability and weak demonstration possibilities may sometimes even discourage the patient from opting for the treatment. Available tool of 3D imaging available and planning can help overcome these problems. We wish to illustrate it by a case report.

**Materials and methods:** A Thirty-eight years old male patient presented in our office with a large postraumatic gap in the maxilla, ranging from 12 to 24. The missing teeth and supporting tissues were replaced by removable partial denture several years ago. He desired a fixed prosthetic solution. Besides the missing teeth we found a large vertical (4–12 mm) and transversal (2–6 mm) deficiency of the alveolar ridge. After the first CT-scan and diagnostic wax-up, we decided to correct the vertical gap by distraction osteogenesis that was followed by placement of bone grafts to correct the transversal dimension.

After the ridge reconstruction, placement of three implants for a delivery of implant-supported bridge was planned. The optimal position of the implants was determined by computer-assisted planning based on an additional CT scan with appropriate X-ray templates. Based on planning, surgical guidance was provided and used for a virtual operation, and making abutment work was completed on individual elements was completed.

**Results:** With the computer-aided planning we were able to reduce the long treatment period due to demanding surgical steps before implant placement was possible. From the standpoint of the patient, a better demonstration tool and therefore a higher acceptance of the treatment plan were attained. Some handling difficulties were encountered with the surgical guide but were overcome uneventfully.

**Conclusion:** 3D navigation and a prefabricated prosthetic based on it represent useful tool for successful treatment outcome in the most difficult implant cases. A shorter treatment time can be an additional beneficial effect. With more experience and further development of navigation, we might expect new horizons to emerge.

## Nobel Guide: flapless implant placement for immediately loaded prosthesis

**Presenter: Quiroz-Petersen G**

*Grupo Dental Bosques, Barcelona, Spain*

**Co-authors: Quiroz-Petersen G, Leyva Aguilar F, Mitrani Boyle R**

*Grupo Dental Bosques, México, Mexico*

**Background and aim:** The use of Nobel Guide® in some situations can be very advantageous for treatment planning cases where the amount of residual bone is severely decreased in size and quality and/or patients willing to have a less invasive surgery. A case is presented of an edentulous patient treated with Nobel Guide® software using a technique for an immediately loaded removable implant retained prosthesis.

**Materials and methods:** A completely edentulous patient is presented with an ill-fitting upper and lower denture. After fabrication of a functional and esthetic new set of complete dentures, a clear resin duplicate is fabricated for a cone beam scan. To prepare the denture several gutta-percha points are placed in the resin-based soft tissue of the denture at random positions according to the Nobel Guide® protocol for computer guided flapless surgery. The main point of using this software is to do all the treatment planning and place the implants at a

minimal invasive surgical appointment. It was planned that the future prosthesis would be a removable implant retained dental prosthesis with a maxillary complete denture. The Nobel Guide<sup>®</sup> software gives us the option of making a final fixed prosthesis, but due to the extensive distal cantilever and the amount of available bone for dental implants it is decided to only place the implants with the software and pick-up in the dental surgery.

**Results:** After having the patient wear the new dentures for a few days, a duplicate radiographic template was made to obtain a cone beam scan in DICOM format to be used with the Nobel Guide<sup>®</sup> software to plan and order a surgical template. Three implants were placed due to the lack of available bone to place more and healing abutments were left for 24-h. The day after surgery the complete denture was converted into an implant retained denture with locator attachments successfully without compromising the primary stability of the implants.

**Conclusion:** This innovative procedure gives the surgeon and restorative dentist a different use for computer-guided surgery that was mainly created for fixed dental prostheses. Taking advantage of the software to do the implant position, number and dimensions can give us an accurate predictable treatment option for the elderly patient with a hygienic removable prosthesis.

#### 175 Poster – Topic Implant and Guided Surgery

Is there a key to the successful osseointegration of zirconia implants? Summary of all currently published clinical studies of zirconia implants

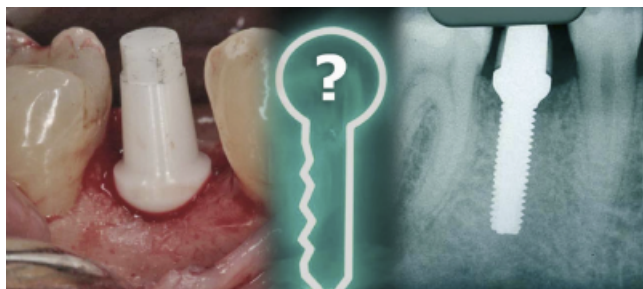**Presenter: Mellinghoff J**

*Dental Practice, Ulm, Germany*

**Co-authors: Mellinghoff J**

*Dental Practice, Ulm, Germany*

**Background and aim:** In recent times, zirconia implants have become increasingly popular. Since no long-term investigations exist as yet, the five currently published clinical studies hold particular importance. Various one-piece zirconia implant systems were investigated for post-operative periods of between 3 and 35 months. The aim of this work is to evaluate these existing studies, despite the diversity of study design, with regard to common parameters which play a key role in successful osseointegration.



**Materials and methods:** The clinical studies of Mellinghoff 2006, Oliva et al. 2007, Lambrich and Iglhaut 2008, Stoll 2008

and Wiltfang et al. 2008 have been comparatively evaluated with regard to the following parameters: implant design utilised, crestal implant surface roughness, spectrum of indications, anatomical status of the implant region, surgical procedure, measured primary stability, protective measures utilised in the healing period and success rates observed.

**Results:** The results of all the studies show that, with a few exceptions, failures occurred during the healing period. Neither implant design, surface roughness nor indications were crucial in achieving good osseointegration. The surgical method utilised was likewise not crucial. The main factor influencing the success rate of one-piece implants was to ensure atraumatic healing through appropriate protective measures. Similarly, primary stability had a positive effect on success rates.

**Conclusion:** Since all existing clinical studies describe a relatively short time period after the implantation of zirconia implants, caution is required when making general statements. However, these studies all show a consistent trend, which suggests a dependency between successful osseointegration and ensuring atraumatic healing after implantation, depending on the situation for 3–8 months, especially in cases with low primary stability. Based on these observations and precisely because so far no long-term data exists, the initial situation of a not easily anticipated good retention for the proposed protective measures is recommended as a contraindication for one-piece implant systems. Conversely, the existing results also indicate that by ensuring good protective measures in the healing period, the prognosis for zirconia implants is comparable to those of titanium.

#### 176 Poster – Topic Implant and Guided Surgery

Clinical result dental implants with fibula bone flap in mandible reconstruction

**Presenter: Chang YM**

*Chang-Gung Memorial Hospital, Taipei, Taiwan*

**Co-authors: Chang YM**

*Chang Gung Memorial Hospital, Taipei, Taiwan*

**Background and aim:** Evaluation the result not only esthetic but oral functional adequate in mandible reconstruction using fibula osteoseptocutaneous flap combine with primary or secondary dental implants.

**Materials and methods:** From 2001 to 2006 total 33 patients were divided into three groups for solve the alveolar ridge height insufficient problem by using fibula bone flap in mandible reconstruction, (1) place an reconstruction plate in mandible border and higher vertical position of the fibula–implant construct and use primary dental implantation (12 patients; total 37 fibula–bone implants), (2) use a double-barrel fibula method with primary osseointegration (12 patients total 35 fibula–bone implants), (3) use vertical distraction osteogenesis of fibula and secondary osseointegration (nine cases, 34 implants).

**Results:** All free tissue transfers were successful, method (1) and (2), all patients have good esthetic results and all implants

survival with completed prosthesis rehabilitation, one young female patient from method (1) group is mildly bothered by palpability of the second reconstruction plate; method (3) difficult controlling the distraction vector caused mild implant malposition notably in some area, no other complication. Under average 3 years functional loading the marginal bone loss < 1 mm around the implants.

**Conclusion:** Each of the presented methods can be useful for increasing the height of the reconstructed mandibular segment to provide an optimal mandibular reconstruction that restores mechanical functions, facial esthetics and complete dental competence with minimal complications.

177 | Poster – Topic Implant and Guided Surgery

## Immediate loading protocols for simplified treatment of partially edentulous patients

**Presenter: D'Avenia F**

*Studiavenia, Parma, Italy*

**Co-authors: D'Avenia F**

*Studiavenia, Parma, Italy*

**Background and aim:** The mechanism and the timing of osseointegration in implant therapy is nowadays so widely and deeply known, that accelerated loading protocols can be reasonably considered a reliable alternative to the standard ones. As a consequence, an updating of the clinical definition of success should include the concept of achieving osseointegration and optimal esthetic results with the least surgical trauma and the fastest loading timing.

**Materials and methods:** Partial edentulism offers a series of scientific and clinical questions in order to reach these aims, especially in cases where an immediate implant insertion is planned. The treatment of the extraction socket, the alveolar ridge preservation, the respect of adjacent teeth's periodontal support, the correct 3D implant positioning, represents, in such a clinical context, a serious challenge, especially if combined with the needs coming from high esthetic demands and reduced trauma and healing time.

**Results:** This lecture will focus on the scientific and clinical questions emerging in these specific situations, offering correlated solutions founded on the current literature review and the author's experience, the last being based on data coming from clinical studies on the way to be published.

**Conclusion:** This lecture will focus on the scientific and clinical questions emerging in these specific situations, offering correlated solutions founded on the current literature review and the author's experience, the last being based on data coming from clinical studies on the way to be published.

178 | Poster – Topic Implant and Guided Surgery

## Vertical ridge augmentation in mandible

**Presenter: Chung JE**

*Graduate School, College of Dentistry, Seoul National University, Seoul, Korea*

**Co-authors: Chung JE, Koo KT, Kim TI, Seol YJ, Lee YM, Koo Y, Rhyu IC, Chung JP**

*Department of Periodontology, Graduate School, College of Dentistry, Seoul National University, Seoul, Korea*

**Background and aim:** Severe ridge resorption after tooth extraction jeopardize the implant placement in esthetic area. To improve the prognosis and predictability of implant, the clinician often utilizes the ridge augmentation technique. Especially, in vertical defect area, guided bone regeneration, onlay block bone graft, distraction osteogenesis are considered. In this patient presentation, I will show you about vertical GBR.

**Materials and methods:** At June 19th, 2003, 45-year-old male came to Seoul National University of Dental Hospital, and his chief complaint was 'My lower front teeth are movable'. Left lower anterior teeth were apical involved state, so extraction was done. Six months after extraction (3.12.), vertical guided bone regeneration with autogenous bone and Bio-oss® and titanium reinforced ePTFE membrane. I used 8 mm long tenting pole and two fixation screws. Primary wound closure was achieved by buccal periosteal releasing incision. After 7 months of GBR procedures, membrane was removed and two Branemark Ti-u MK III system, narrow platform of 13 mm long fixture were installed at 31, 33 sites. After 3 months of fixture installation, healing abutment was connected (3 mm height) and prosthetic treatment was done. The patient functions well without any problem now that.

**Results:** I achieved about 4 mm vertical height of by GBR technique using autogenous bone and Bio-Oss®. And osseointegration between narrow platform fixture of Branemark Ti-U MK III system and newly formed bone was successfully achieved.

**Conclusion:** In severe alveolar ridge resorption after extraction, GBR technique using autogenous bone, Bio-Oss®, titanium reinforced ePTFE membrane is a predictable procedure, and osseointegration between narrow platform fixture of Bränemark Ti-U MK III system and newly formed bone was successfully achieved.

179 | Poster – Topic Implant and Guided Surgery

## Secured-fitted detachable surgical guide for edentulous jaw in maxilla

**Presenter: Satoshi S**

*Private Practice, Kanagawa, Japan*

**Co-authors: Shigehara S<sup>1</sup>, Nakashima K<sup>1</sup>, Takanashi Y<sup>1</sup>, Shiratori K<sup>2</sup>, Shintani S<sup>2</sup>, Imamura E<sup>3</sup>, Kawashima N<sup>3</sup>, Hongo T<sup>1</sup>**

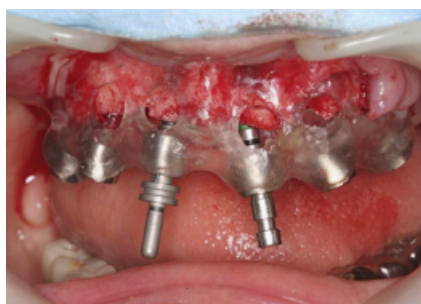*<sup>1</sup>Shonan Dental Care Implant Clinic, Kanagawa, Japan, <sup>2</sup>Showa University Oral, Maxillofacial Surgery, Tokyo Japan, <sup>3</sup>Faculty of Biomedical Engineering, Toin University of Yokohama, Kanagawa, Japan*

**Background and aim:** Guided surgery of implant placement has been utilized to acquire safety and reduce operation time of the



surgical procedure. However, some complications and failures have been reported with commercially available guide because of misplacement of the guide and/or complexity of the system. In addition, the commercial guides have not been suitable for the clinical situation of immediate implant placement following tooth extraction. We have developed a procedure of guided surgery for edentulous maxilla utilizing a bone-level surgical guide, which is an original, precise and stable, even a site of immediate placement following tooth extraction.

**Materials and methods:** Six maxillary edentulous cases (two males and four females) were selected for the newly developed guided surgery. Treatment outcome was retrospectively described in case series manner. Computed tomography was taken before the operation. Stereolithographic model was fabricated based on the CT data. Preoperative model surgery was performed and immediate interim prosthesis was prepared. Position, length and width of implants were decided using a computer software, Simplant (Materialize®). A surgical guide, which was made of self-curing acrylic resin and titanium was fabricated upon the stereolithographic model. In order to acquire a stability of the guide, we utilized two anatomical landmarks in maxilla; bottom edge of anterior nasal aperture (ANA) and incisive fossa (IF). Owing to this original feature, the guide was able to be secured on the bone surface and detachable during the operation.



**Results:** All of 39 implants were successfully placed as planned. Five implants were placed immediately following teeth extraction. Mean surgical operation time was 122.5 minutes. No complication was reported during the surgical procedure and the entire investigated period.

**Conclusion:** Although this pilot study had small number of cases and relatively short-term investigation period, our newly developed surgical guide seemed to be beneficial for accurate implant placement surgery in various clinical situations.

180	Poster – Topic Implant and Guided Surgery
-----	---

## Zygomatic implants combined to immediate loading procedures

**Presenter:** Verdino JB

*Private Practice, Hyères, France*

**Co-authors:** Verdino JB<sup>1</sup>, Louvet T<sup>2</sup>, Moal JM<sup>3</sup>

<sup>1</sup>Private Practice, Verdino, Hyères, France, <sup>2</sup>Private Practice, Louvet, Hyères, France, <sup>3</sup>Private Practice, Moal, Hyères, France

**Background and aim:** According to the classification of E Bedrossian, there are three areas on the upper maxillae: the anterior

zone, the bicuspid and the molar. When there is a lack of bone in the two posterior zones, the only solution to obtain initial stability is to use zygomatic implants, uni- or bilaterally, combined with the placement of two or more implants in the anterior zone. The aim of this presentation is to expose two clinical cases, with the description of the surgical procedure for the zygoma fixture, and also the immediate connection of a fixed screwed bridge.

**Materials and methods:** Two clinical cases: a 44-year-old female with two remaining cuspids and a lack of bone on the left upper maxillae. A zygomatic fixture is placed, the two cuspids are removed and three other implants are placed (two in the anterior area and one in the right bicuspid zone). The abutments are screwed and a prefabricated acrylic bridge is connected to the implants with titanium cylinders. The second case is a 55-year-old man with an old ceramic bridge on teeth that have to be removed. The first step consists of the extraction of remaining the teeth, immediate placement of five implants and a fixed screwed bridge. In order to reduce the cantilever on the left side, and due to a poor bone quantity, a zygomatic implant is placed 6 weeks later and connected to the pre-existing acrylic bridge. Both cases have been done under local anesthesia, without sedation.

**Results:** In both case, the use of zygomatic implants allows to obtain initial stability in areas with poor bone quantity and quality. The patients received an immediate fixed screwed bridge, immediately after surgery. A review of literature with statistical results, confirms the predictability of this technique.

**Conclusion:** The zygomatic fixtures are the only one alternative to grafting procedures (sinus lift or onlay grafts) in the posterior maxillae. It allows also to place fixed screwed acrylic bridge immediately after surgery, which is normally not possible with grafts, where an healing period of 4–8 months is usually required. Also, the statistical results shows the high predictability of the zygomatic implants.

181	Poster – Topic Implant and Guided Surgery
-----	---

## Computer-assisted implant placement: scan template, surgiuide, simplant and safe-system

**Presenter:** Tekin U

*Ege University, Faculty of Dentistry, Izmir, Turkey., Izmir, Turkey*

**Co-authors:** Tekin U<sup>1</sup>, Güngör MA<sup>2</sup>, Akay MC<sup>1</sup>, Parlar A<sup>2</sup>, Artunç C<sup>2</sup>

<sup>1</sup>Department of Oral and Maxillofacial Surgery, Ege University Faculty of Dentistry, Izmir, Turkey, <sup>2</sup>Department of Prosthodontics, Ege University Faculty of Dentistry, Izmir, Turkey

**Background and aim:** The need for an accurate diagnosis and treatment plan remains essential for predictable treatment outcomes with dental implants. Modern implantology uses techniques that can provide function, esthetics, and comfort with a minimally invasive surgical approach. Advances in computerized tomography (CT) technology now enable the execution of a surgical outcome based on presurgical planning. After computed tomography (CT)-based selection of the implant

site, transfer of planning and insertion of implants can be accomplished via template or computer-assisted navigation or a combination of both methods. Flapless implant surgery has been proposed to fulfill these requirements. The purpose of this paper is to discuss the use of scanning appliances to transfer clinically relevant prosthetic outcome information to a CT data set.

**Materials and methods:** Oral implants were planned on CT. A special surgical template was fabricated and the surgical bur tubes were directly positioned in this template. Bur tube positioning may represent a precise means for CT-guided template production. Also used SimPlant software, this information can be used to provide a pretreatment outcome analysis, which can be used for fabrication of stereolithographic models and surgical drilling guides used during osteotomy preparation.

**Results:** As a result, we were able to perform transmucosal drilling and implant placement in all patients without disruption of important anatomical structures; none of the patients had signs of post-operative sensory changes in the lip or chin region.

**Conclusion:** Although this modern approach may have many advantages, transferring virtual planning to the patient's mouth has only been developed recently. Further research is required to justify this novel approach for implant rehabilitation.

182	Poster – Topic Implant and Guided Surgery
-----	---

The use of autogenous mandibular block bone grafts for reconstruction of alveolar defects

**Presenter:** Yildirim G

*Selcuk University Faculty of Dentistry, Konya, Turkey*

**Co-authors:** Dolanmaz D, Yildirim G, Inan O, Alniacik G

*Selcuk University Faculty of Dentistry, KONYA, Turkey*

**Background and aim:** The repair of alveolar defects with bone grafts is one of the most common surgery techniques in oral and maxillofacial surgery. Although autogenous bone grafts need a second surgical intervention, they are accepted as a golden standard because of their high osteogenic potential. The grafts can be obtained from various extraoral or intraoral donor sites. Localized bone defects of alveolar ridge require only confined amount of bone and donor sites for these defects can be harvested from oral cavity. Common donor sites in the oral region are mandibular symphysis, retromolar area and maxillary tuberosity. In this retrospective study, the outcomes of autogenous block bone grafts obtained from mandible for different indications are reported.

**Materials and methods:** Twenty-three patients were included the study. Grafting was done in these patients for lateral crest augmentation, and sinus floor augmentation before the dental implantation. All operations were done under local anaesthesia. All grafts were stabilized on the recipient site by using a screw. No membrane was used for coverage of the graft. Implantation was done average 5 months later the grafting.

**Results:** Except one, all the grafts healed uneventfully. Graft exposition and donor site infection were seen in only one patient.

**Conclusion:** The results of this study show that the mandibular block grafts is a simple and effective treatment modality

for reconstruction of insufficient alveolar bone and also reduced the cost.

183	Poster – Topic Implant and Guided Surgery
-----	---

Implant placements with a computer guided surgery system based on stress analysis utilizing bone density: a clinical case report

**Presenter:** Maeda Y

*Osaka University, Suita, Japan*

**Co-authors:** Maeda Y, Gonda T, Wada M, Sogo M, Ikebe K

*Osaka University, Osaka, Japan*

**Background and aim:** With the help of 3D geometric data from CT as well as computer software for placement planning or providing surgical guided, safe and precise implant placement became possible based on the available bone volume. However, predictions of the initial stability and stress distribution through implant after integration are also important. The purpose of this study was to examine the possibility of utilizing CT bone density data for predicting initial implant stability and stress around integrated implant.

**Materials and methods:** Patient was the 62 years old totally edentulous male seeking mandibular implant prosthesis with better stability. After initial diagnosis and informed consent for the treatment, diagnostic complete dentures were fabricated and CT image was taken. 3DCT data with bone density of the mandible was analyzed with simulation software for implant placement (iCAT Diagnosis Software Ver3, Japan) site and direction with high initial stability for an overdenture. Initial stability of implants was measured at actual implant placement with the torque controller. Also 3D CT data was used to construct 3D finite element model using a special soft wear (Mechanical Finder, RCCM, Japan). Two titanium implants, the mandibular complete denture and soft tissue were also modeled. Analysis of stress in the bone around implant was performed with different implant length and diameter under 50 N of load at right first molar occlusal surface.

**Results:** With the implant placement simulation software, the area with highest initial stability was found around lateral incisor on both sides based on bone density. Actual fixation torque value was about 32 N. Stress analysis with the overdenture configuration indicated that the length and width of implant alter the range of stress distribution.

**Conclusion:** Within the limitation of this preliminary case report, it was suggested that CT bone density data can be the measure of clinical bone quality allowing prediction of the initial implant stability, while stress analysis using 3DCT data may provide the information of longitudinal implant stability.

## Clinical outcome and complication management of alveolar distraction osteogenesis in anterior maxilla

**Presenter:** Chen YY

*Chang-Gung Memorial Hospital, Taipei, Taiwan*

**Co-authors:** Chen YY, Chang YM

*Chang-Gung Memorial Hospital, Taipei, Taiwan*

**Background and aim:** Alveolar distraction osteogenesis is a relatively novel procedure by which alveolar bone and underlying mucosa are regenerated. It is now being widely used for treating severe alveolar ridge atrophy, especially before the placement of dental implants. The purpose of this retrospective study was to evaluate the clinical outcomes and complications of alveolar distraction osteogenesis in anterior maxilla.

**Materials and methods:** From 2000 to 2004, seven patients with alveolar ridge deficiency of anterior maxilla received alveolar distraction osteogenesis with distraction devices, including intraosseous or subperiosteal type, at the department of oral surgery, Chang-Gung memorial hospital, Taipei. A total of 21 implants were placed in the distracted bone.

**Results:** After distraction, the distracted height was increased from 6 to 12 mm, the average was 9.6 mm. However, a minor complication was found in all cases that the segment moved toward to palatal, which resulted in the necessity of secondary bone grafting procedure before dental implant placement. No complication of transport segment fracture was observed in any case.

**Conclusion:** Vertical distraction of the anterior segment of a severely resorbed alveolar ridge of the maxilla combined with secondary guided bone regeneration procedure can provide a proper basis for insertion and osseointegration of dental implants with few surgical complications and good patient satisfaction.

## Novel technique for crestal sinus floor elevation with atraumatic approach

**Presenter:** Di Alberti C

*Private Practitioner, Chieti, Italy*

**Co-authors:** Di Alberti C, Di Vera A, Camerino M, Donnini F, Rossi G, Dolci M, Di Alberti L

*Private Practitioner, Chieti, Italy*

**Background and aim:** The sinus floor elevation (sinus lift) is a procedure used for treating patients with very large pneumatization of the maxillary sinus and thereby with severe atrophic maxilla (height of the residual alveolar bone between 2 and 8 mm). The minimally invasive sinus floor elevation as first described by Summers is limited in the volume of augmentation that is possible. In contrast, the more invasive approach is the sinus lift of Tatum which is indicated for greater bone deficiencies. The classic lateral antrostomy pioneered by Tatum appears to be the most common sinus lift procedure. The more conservative crestal approach, advocated by Summers, provides an effective way of allowing implant fixture placement in the

atrophic maxilla with the not always well tolerated use of osteotomes by the patients. A novel approach for sinus lifting without the use of osteotomes and surgical hammer has been compared with classical techniques. The new compression and sinus elevation kit developed by MIS improved the treatment in sinus lifting and soft bone compression. A simple bone compression procedure had enable a better implantation and better implant primary stability.

**Materials and methods:** Sixteen patients treated for sinus lifting have been selected. Nine patients have been treated with classical sinus lifting following Summers technique. Five patients have been treated with new sinus lifting kit.

**Results:** The sinus elevation and compression kit has prevented traumatic osteotomy, increased bone density, increased implant primary stability and gave a perfect gradual control of sinus elevation and bone compression.

**Conclusion:** This paper report the results of a retrospective controlled case study of a comparative survey on clinical and psychological effects of the three different techniques of sinus lifting.

## Treatment of advanced periodontal destruction with immediately loaded implants and simultaneous bone augmentation: a case report

**Presenter:** Pardo Zamora G

*Universidad de Murcia, Murcia, Spain*

**Co-authors:** Guillermo P, Jose Luis C, Bruno N, Ma Rosario S

*Universidad Murcia, Murcia, Spain*

**Background and aim:** Advanced periodontal destruction is often associated with extraction of the teeth. Oral rehabilitation in these cases may include the traditional prosthetic restoration or an implant-supported reconstruction. Immediately loaded implants present an alternative treatment modality with the placement of higher numbers of implants, which are connected with a fixed prosthetic reconstruction.

**Materials and methods:** This clinical case report presents the surgical and prosthetic rehabilitation in a patient who had lost all teeth due to advanced periodontal bone destruction. Eight implants were placed in the upper and lower jaw each. Some implants required guided bone regeneration in conjunction with autologous bone grafting. All of the implants were connected with their abutments, and a temporary fixed restoration was placed immediately after surgery. The final metalloceramic-fixed reconstruction was cemented after 8 weeks of loading.

**Results:** All of the implants were osseointegrated and showed no clinical signs of mobility or infection. Mobility values were evaluated during healing and were found to be reduced. Radiological findings showed a stable peri-implant bone level during the total 24 month loading observation period.

**Conclusion:** This case report presents an alternative treatment concept for the oral rehabilitation in a patient with advanced periodontal destruction. The concept of immediate loading of implants might provide a better opportunity to meet patient needs than more traditional treatment modalities.

## Bilaterall elevation of the maxillary sinus using two different technique-case report

**Presenter:** Dragana Gabrić Pandurić

*University of Dentistry, Zagreb, Croatia*

**Co-authors:** Katanec D<sup>1</sup>, Komljenović D<sup>2</sup>, Gabrić D<sup>1</sup>, Kobler P<sup>1</sup>

<sup>1</sup>*School of Dentistry, Zagreb, Croatia,* <sup>2</sup>*Private Clinic, Rovinj, Croatia*

**Background and aim:** A 56-year-old female patient with bilateral free end, and two upper central incisors with two canines which are all compromised with irreversible progressive paradontopathy wish to have implant-prosthetic rehabilitation. In molar region, both maxillar sinuses are slouch too much so that there are no possibilities for sinus lifting intervention following with immediate implant placement.

**Materials and methods:** Left sinus is upraised with lateral ingress and augmented harvested autologous bone mixed with Bio Oss, and right sinus with closed ingress method, seizing balloon technique (Meisinger Balloon Control lift set from Hager&Meisinger GmbH, Germany) and gained space augmented with Easy Graft (Tri-Calciumphosphate, DS-Dental, Swiss). After 8 months following sinus lifting, were placed four implants from 'Nobel Replace Groovy' all 13 mm size in each augmented side of region 3, 5, 6, 7 and on the opposite side as well.

**Results:** Subsequently after 2 months following implant intervention was made suprastructure of fixed ceramical circular bridge from 16 to 26. Implant stability was measured with Osstell and was done by computerised densitometry in ten density points around each embedded implant before load of bridge construction and after. Afterwards was done statistical analysis of harvested measuring data, which was all documented with RTG shots and photos of surgical intervention and prosthetic making-of bridge.

**Conclusion:** Gained data results are showing us that sinus lifting method with enclosed balloon approach technique can result in gaining enough area for implant placement as well as with opened approach technique. Furthermore Balloon technique is more over less traumatised experience for patient with a much fewer side effects and postoperational problems. In addition if we have sufficient bone width for the purpose of sinus lifting in favour of placing of two up to three implants in that area we can equally sufficient use enclosed Balloon technique instead of opened lateral approach which is causing much more traumatised experience for patient and much more postoperational problems.

## Single tooth replacement in the aesthetic zone with Noble Perfect immediate placement and provisionalization

**Presenter:** Pinto M

*FMD UP, Porto, Portugal*

**Co-authors:** Pinto M, Fontes J

*FMD UP, Porto, Portugal*

**Background and aim:** It is well establish that the immediate placement and provisionalization of a scalloped implant in the

anterior maxillary area is a predictable and successful technique. However, it is difficult to determine the exact implant role in the treatment results, since the provisional restoration may influence them.

**Materials and methods:** In this communication, using the immediate placement and provisionalization of scalloped implants in the anterior maxillary area procedure, and by using an acrylic guide, the deceased tooth was placed as a provisional restoration, exactly at the some position as it was before the extraction. Soft tissues changes were taken using gingival mid-facial point, the papilla crest and the incisal border, before and after the extraction.

**Results:** It seems possible not only to increase the accuracy of the soft tissues changes quantification but also to achieve a maximum soft tissue anatomy preservation 12 months after treatment.

**Conclusion:** It seems possible not only to increase the accuracy of the soft tissues changes quantification but also to achieve a maximum soft tissue anatomy preservation 12 months after treatment.

## Immediate implant placement of super-wide implants to reconstruct missing molar teeth

**Presenter:** Yun SC

*Mir Dental Hospital, Daegu, Korea*

**Co-authors:** Yun SC, Park KB, Park JH, Jeon MH

*Mir Dental Hospital, Daegu, Korea*

**Background and aim:** Immediate implantation in the molar area has been very difficult with the existing implant system because of multiple roots and the wide width at the cemento-enamel junction. However, recent super-wide implants (6–8 mm. in diameter) development have enabled immediate implantation in molar area.

**Materials and methods:** Immediate implantation in the molar area has been very difficult with the existing implant system because of multiple roots and the wide width at the cemento-enamel junction. However recent super-wide implants (6 ~ 8 mm. in diameter) development have enabled immediate implantation in molar area.

**Results:** The cumulative implant success rate for the immediate placement and provisionalization procedure in this study was 96.64% (4/119) after at least 10 months of function with a follow-up period of up to 44 months.

**Conclusion:** For the rehabilitation of natural molar teeth, it is necessary that diameter of implant is similar to the width of teeth at CE junction. Super-wide implant is the result of this thought.

## Immediate implants after enucleation of an odontogenic keratocyst: an early return to function

**Presenter: Demircan S**

*Istanbul University Faculty of Dentistry, Istanbul, Turkey*

**Co-authors:** Isler SC<sup>1</sup>, Demircan S<sup>1</sup>, Can T<sup>1</sup>, Cebi Z<sup>1</sup>, Emrah B<sup>2</sup>

<sup>1</sup>Department of Oral Surgery, Istanbul University Faculty of Dentistry, Istanbul, Turkey, <sup>2</sup>Department of Prosthetic Dentistry, Istanbul University Faculty of Dentistry, Istanbul, Turkey

**Background and aim:** We present a case of a keratocyst accompanied by a history of inflammation, resorption of the roots of the mandibular teeth and devitalization of these teeth. Odontogenic keratocyst is an epithelial developmental odontogenic cyst most commonly occurring in the jaws. It comprises approximately 11% of all cysts of the jaws. It has an aggressive behavior including high rates of recurrence, rapid growth, and extension into adjacent tissues. Odontogenic keratocyst is commonly found in the mandible with a predilection for angle and ascending ramus of the mandible. The potential for recurrence of the keratocysts relates to the high proliferate activity of the keratocyst epithelium. Owing to the high recurrence rate and aggressive behavior of keratocysts, different treatment techniques can be chosen. Enucleation or curettage alone is the mostly preferred treatments in the management of keratocysts.

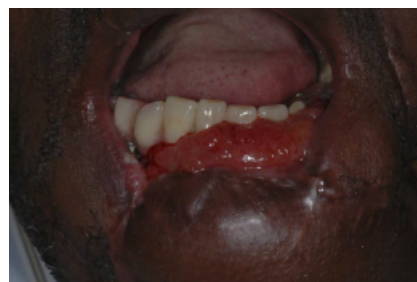**Materials and methods:** The treatment opinion chosen was enucleation of the cyst, extraction of the involved teeth and immediate four implants insertion.

**Results:** After 6 months of the cyst enucleation and implant placement the fixed ridge prosthesis finished and first year control uneventful.

A 45-year-old patient with significant bone loss of the anterior mandible and soft tissue loss of the lower lip, chin and neck resulting from gunshot injuries underwent immediate implant rehabilitation with simultaneous mandibular and lower face reconstruction. The aim was to apply a multidisciplinary approach comprising of an extended operation of multiple procedures, which might have otherwise been conducted sequentially over many months or years. This combination operation appears to be the first reported instance of immediate complete full arch restoration with dental implants simultaneously placed into a microvascular free bone flap.

**Materials and methods:** Preoperative planning included pre-bending of a mandibular fixation plate to the intended mandibular contour and prefabrication of a dental arch for adaptation to a provisional bridge.

A 12 cm graft derived from the patient's scapula was used to reconstruct the mandible and osteotomised to conform to the pre-formed fixation plate. Following anastomosis and re-vascularisation, five fixtures were placed in the neo-mandible and temporary lower bridge fitted. The latissimus dorsi and overlying skin was used for the soft tissue reconstruction. Definitive dental reconstruction with milled titanium, resin veneered implant-supported fixed denture took place 6 months later.



## Prosthetically driven mandibular reconstruction following a shotgun injury: immediate implant supported bridgework in a scapular free-flap

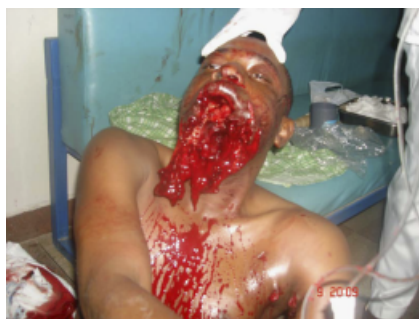**Presenter: Dawood A**

*Dawood and Tanner Dental Practice, London, UK*

**Co-authors:** Dawood A<sup>1</sup>, Hutchison I<sup>2</sup>, Tanner S<sup>1</sup>, Sauret-Jackson V<sup>3</sup>

<sup>1</sup>Dawood @ Tanner Dental Practice, London, UK, <sup>2</sup>Barts @ The London NHS Trust, London, UK, <sup>3</sup>Cavendish Imaging, London, UK

**Background and aim:**



**Results:** The patient was able to eat and speak relatively normally within 10 days of his first operation, made a good recovery and returned to work within 3 months. A cone beam CT scan taken 3 months postoperatively indicated good bony healing in the neo-mandible. Twelve months post-surgery, the patient rates his overall quality of life as 'very good' (based on the University of Washington Quality of Life Questionnaire) with few limitations. Improvement is to be made regarding chewing larger solids.

**Conclusion:** Pre-surgical planning facilitated complete rehabilitation in a single operating session and increased accuracy and predictability. Planning and implementing prosthodontic treatment in the immediate reconstructive phase 'guided' the adaptation, positioning and the extent of the graft, driving the surgical reconstruction towards a defined aesthetic objective. The emotional and psychological benefits of this one-stage approach, in addition to the obvious physical benefits were immediately evident as the patient suffered little post-traumatic stress. This work is an example of carefully orchestrated teamwork, with contributions from medical physics, dental technology, prosthodontic specialists, implant surgeons and oral and maxillofacial surgeons.

### Anatomic assessment of maxillary sinus vascularization: a cadaveric study

**Presenter:** Weinstein T

*University of Milan, Milan, Italy*

**Co-authors:** Rosano G<sup>1</sup>, Gaudy JF<sup>2</sup>, Weinstein T<sup>1</sup>, Del Fabbro M<sup>1</sup>, Taschieri S<sup>1</sup>

<sup>1</sup>*Department of Health Technologies, Section of Dentistry, IRCCS Galeazzi Orthopaedic Institute, University of Milan, Milan, Italy,*

<sup>2</sup>*Department of Cranial Cervicofacial Anatomy, Faculty of Medicine René Descartes, University of Paris 5, Paris, France*

**Background and aim:** The goal of this study was the investigation of the arterial blood supply to the maxillary sinus in order to give clinicians the basis for a better understanding of the origin of vascular complications that can derive from surgical procedures at this level.

**Materials and methods:** The study consisted of 30 sinuses from 15 human cadavers (age range at death 59–90 years). In order to define the complex vascularization of the maxillary sinus the afferent vascular network was injected with liquid latex mixed with red India ink through the external carotid arteries.

**Results:** An intra-osseous anastomosis between the dental branch of the posterior superior alveolar artery and the infra-orbital artery was found in 100% of cases. Such an anastomosis seems involved in the blood supply to the sinus membrane, to the periosteal tissues and to the anterior lateral wall of the sinus. The gingival branch of the posterior superior alveolar artery was found to anastomose an extraosseous branch of the infraorbital artery in 10 sinuses. A close anatomical relationship was also found among the sinus posterior wall, the descending palatine artery and the sphenopalatine artery in all cases. Small branches deriving from the posterior lateral nasal arteries perforated the nasal wall laterally and reached the mucosa of the maxillary sinus. The posterior lateral nasal artery is relatively close to the sphenopalatine artery and may anastomose with the facial or other nasal arteries; moreover, it has been found to course close to, or within, the medial wall of the sinus.

**Conclusion:** It is clinically important for all oral surgeons to know the localization of the anastomosis identified in the present study since its laceration during sinus floor elevation procedure is rather frequent and can cause hemorrhage. Even though the excision of this artery is not threatening because of its small size and its hemorrhage mostly resolves itself thanks to a reactive contraction of the vessel, it can cause impairment in visualization of the Schneiderian membrane, making its elevation more difficult and interfering with placement of graft material. A sound knowledge of the maxillary sinus vascularization is essential to prevent vascular complications during surgical operations involving this region.

### Fracture incidence in mandibular implant-overdentures over one and two implants

**Presenter:** Gonda T

*Osaka University, Graduate School of Dentistry, Suita, Japan*

**Co-authors:** Gonda T<sup>1</sup>, Maeda Y<sup>1</sup>, Walton J<sup>2</sup>, MacEntee M<sup>2</sup>

<sup>1</sup>*Osaka University, Suita, Japan,* <sup>2</sup>*University of British Columbia, Vancouver, Canada*

**Background and aim:** While two to four implants have been preferred to retain and stabilize an implant-overdenture, some reports suggest an overdenture retained by a single implant works well, however, there is no information on the incidence of fractures when dentures are retained by one implant. The objective of this study was to compare the fracture incidence of mandibular implant-overdentures retained by one and two implants.

**Materials and methods:** This study included data from the Vancouver Implant Prosthesis (VIP) clinical trial which ran from 2003 to 2008. The goal of the trial was to compare patient satisfaction, component costs, and treatment and maintenance times with mandibular overdentures retained by one or two implants. We examined the clinical records of the 85 patients (43 men and 42 women; mean age: 67 years) who completed at least 12 year wearing a mandibular implant-overdenture. From the clinical records, we identified subjects who had experienced a fractured overdenture. A fracture was identified as either a visible crack in the acrylic resin or as a total separation of the denture parts. The same clinical records listed three denture fracture sites: 'over the implant'; 'elsewhere' (meaning not over the implant); or 'unknown'. A chi-square test was used to compare the incidence of fracture.

**Results:** Forty-two subjects received a single implant, and 43 received two implants. In total, there were 17 fractures recorded for 13 subjects. Nine single-implant subjects experienced 11 denture fractures, while four double-implant subjects experienced 6 fractures. We found that there was no statistically significant difference in the incidence of denture fractures over one or two implants. Twelve (70%) of the fractures occurred over the implant, two (12%) occurred elsewhere, and the location of three (18%) fractures was not recorded. Where denture fractures did occur, they were found most frequently in areas adjacent to the implant(s).

**Conclusion:** The incidence of denture base fractures was not significantly different between overdentures retained by one or two implants. When fractures did occur, they tended to do so in areas adjacent to implants.

## Comparative in vitro study of the effects of laser irradiation for debridement of implant surfaces

**Presenter: Giannelli M**

*University of Florence, Florence, Italy*

**Co-authors: Marco G<sup>1</sup>, Paolo T<sup>1</sup>, Martina M<sup>2</sup>, Alessandro P<sup>2</sup>, Luca L<sup>1</sup>, Alessia T<sup>2</sup>**

<sup>1</sup>Department of Odontostomatology, University of Florence, Florence, Italy, <sup>2</sup>Department of Anatomy, Histology & Forensic Medicine, University of Florence, Florence, Italy

**Background and aim:** Bacterial lipopolysaccharide (LPS) has been identified as one the most potent pro-inflammatory agents and pathogenic factors of peri-implantitis, being implicated in soft and hard tissue resorption. Thus, elimination of contaminating bacteria as well as germ-derived LPS from the implant surface is the basis of peri-implant therapy. This study was designed to clarify whether implant irradiation with different low energy lasers known to be effective on bacterial decontamination, may also reduce LPS-induced inflammatory response.

**Materials and methods:** Human endothelial cells (HUVEC) and murine macrophages (RAW 264-7) were cultured on implant-derived titanium discs coated with *Porphyromonas gingivalis* LPS, subjected or not to previous irradiation with CO<sub>2</sub>, Erbium:YAG, or diode (810nm wavelength) laser and examined for the expression of morphological and molecular markers of inflammatory cell activation.

**Results:** We found that low energy laser irradiation significantly reduced LPS-induced NO production and cell activation by macrophages, as well as ICAM-1 and VCAM expression and IL-8 production by HUVEC. Of note diode laser was slightly albeit significantly more effective than CO<sub>2</sub>, and Erbium:YAG lasers to deactivate LPS coated to the titanium surfaces.

**Conclusion:** CO<sub>2</sub>, diode and Er:YAG laser irradiation at low energy parameters are all capable to blunt the inflammatory response of the noted cells to titanium-adherent LPS. These findings suggest that low energy laser treatment may be a promising therapeutic tool for peri-implant disease, as it is adequate to achieve an effective debridement of implant surfaces.

treatment may represent a promising therapeutic approach for the treatment of peri-implantitis, based on its ability to eradicate bacteria from dental titanium implant and peri-implant tissues. Despite this there are several concerns regarding the use of this therapy in the dental practice mostly due to the conflicting and few data regarding the effects of the laser irradiation on oral tissues. In the present study, we aimed at investigating the effects of low pulsed Neodymium: Yttrium Aluminum Garnet (Nd:YAG) laser irradiation, on the viability, proliferation and differentiation of different cells representative of the oral microenvironment and to elucidate mechanisms underlying its action.

**Materials and methods:** Saos-2 osteoblasts cells, H-end endothelial cells and NIH/3T3 fibroblasts were irradiated with appropriate laser parameters (20mJ/50–70 Hertz, previously shown to decontaminate titanium surface without changing the surface properties of the implant) and then analyzed for cell viability, cell proliferation and for the expression of specific differentiation markers by confocal immunofluorescence and Real Time PCR. Analysis of intracellular calcium mobilization was also performed in osteoblasts loaded with Fluo3-AM, a fluorescent Ca<sup>2+</sup> indicator.

**Results:** By MTS assay, it was found that Nd:YAG laser irradiation did not affect cell viability in all the tested cell types. With regards to cell proliferation, the laser treatment caused a significant increase of the cell number in osteoblastic Saos-2 cells whereas it did not influence the growth of endothelial and fibroblastic cells. Moreover, the laser irradiation increased the expression of several differentiation markers in all the three cell lines examined, including osteopontin, TRPC1, ALP and Runx2 in osteoblasts, collagen-type1 in fibroblasts and vinculin in endothelial cells. Notably, in the osteoblastic cells, the Nd:YAG irradiation induced a rapid intracellular calcium mobilization, suggesting an involvement of this ion in the regulation of the observed cellular responses.

**Conclusion:** Low-energy Nd:YAG laser therapy may represent a feasible and safety technique in the treatment of peri-implant diseases and its bio-stimulative effects may be crucial for the improvement of the healing process underlying these pathologies.

## Low pulse energy Nd:YAG laser therapy for the treatment of peri-implantitis: an in vitro study of the bio-stimulatory effects and mechanisms

**Presenter: Giannelli M**

*University of Florence, Florence, Italy*

**Co-authors: Marco G<sup>1</sup>, Flaminia C<sup>2</sup>, Paolo T<sup>1</sup>, Marco D<sup>1</sup>, Chiara S<sup>2</sup>**

<sup>1</sup>Department of Odontostomatology, University of Florence, Florence, Italy, <sup>2</sup>Department of Anatomy, Histology & Forensic Medicine, University of Florence, Florence, Italy

**Background and aim:** Prerequisite for clinical success of peri-implantitis is the removal of bacteria and by-products (LPS) from implant surfaces without damaging the cells that are involved in bone tissue formation (re-osseointegration). Low level laser

## Analysis of complications after sinus lifting with implant placement and correlation of complications with implant failure

**Presenter: Jin HM**

*Asan Medical Center, Seoul, Korea*

**Co-authors: Jin HM, Ahn KM**

*Asan Medical Center, University of Ulsan, Seoul, Korea*

**Background and aim:** Sinus lifting and implant installation has been performed for more than three decades and now accepted as safe procedures to treat severely resorbed maxilla. Complication rate after sinus lifting was reported from 0% to 30%. Most of the complications are minor and could be treated conservatively. However, severe complications such as chronic sinusitis and removal of implants could happen sometimes. In this study, we



examined complications after sinus lifting and implant installation and statistically evaluated the correlation of complications with implant failure.

**Materials and methods:** From 2000 to 2008, total 368 sinus lifting and implant installation was performed by one experienced surgeon. Male to female patient ratio was 225:143. Complications during and after sinus lifting such as membrane perforation, sinusitis, bleeding, severe swelling, ecchymosis, hematoma, severe pain, infection and implant removal were examined. Correlation of complication and implant failure were statistically evaluated with Cox proportional hazards model. Treatment protocol to treat failed implant after sinus lifting was suggested through clinical experiences.

**Results:** Minor complication such as pain, swelling and ecchymosis was reported in most cases (97%) but relieved after 1 week. Severe bleeding due to rupture of intraosseous artery was found in seven cases. Membrane perforation was found in 36 patients and repaired by collagen membrane. Total eight implants were removed and cumulative survival rate was 97.8%. According to Cox proportional hazard model, minor complications and membrane perforation was not related to implant failure, however, sinusitis was significantly related to implant failure.

**Conclusion:** Chronic sinusitis after sinus lifting and implant installation is most complicated and is related to implant failure. The early intervention of sinusitis is mandatory for reducing implant failure after sinus lifting procedure.

197	Poster – Topic Technical and Biological Complications
-----	---

The periodontium of adult sheep subjected to ovariectomy, malnutrition and glucocorticoid application – a histomorphometric analysis

**Presenter: Dvorak G**

*Medical University Vienna, Vienna, Austria*  
Co-authors: Dvorak G<sup>1</sup>, Reich K<sup>1</sup>, Watzek G<sup>1</sup>, Lill C<sup>2</sup>, Gruber R<sup>1</sup>, Haas R<sup>3</sup>

<sup>1</sup>Department of Oral Surgery, Vienna, Austria, <sup>2</sup>AO Research Institute, Davos, Switzerland, <sup>3</sup>Academy of Oral Implantology, Vienna, Austria

**Background and aim:** Aging, hypogonadism, malnutrition, and the application glucocorticoids have adverse effects on skeletal homeostasis. To which extend the periodontium undergoes catabolic changes under these conditions was determined in the present study.

**Materials and methods:** Six geriatric sheep with a mean age of  $7.5 \pm 1.0$  years were subjected to ovariectomy, calcium/vitamin D-restricted diet, and intramuscular administration of methylprednisolone for up to 32 weeks (test group). Six adult sheep with a mean age of  $3.8 \pm 0.9$  years remained untreated and served as controls. First and second premolars of both jaws were subjected to histological analysis. The distance from the gingival margin and the alveolar bone crest to the cemento-enamel junction was determined. Periodontal attachment was calculated based on the ratio between the height of the periodontal ligament and the alveolar bone. For clinical end points, we counted the number of teeth missing, teeth with gingival recession, and teeth with a probing depths  $> 4$  mm.

**Results:** Measures of gingival margin ( $2.2 \pm 1.6$  and  $7.2 \pm 2.3$  mm maxilla;  $-0.4 \pm 1.4$  mm and  $3.2 \pm 1.5$  mm mandible) and alveolar bone crest ( $-3.3 \pm 1.2$  and  $2.5 \pm 2.1$  mm maxilla;  $-3.5 \pm 1.1$  and  $-0.1 \pm 1.4$  mm mandible) are significantly lower in test than in controls animals. In line with these findings, periodontal attachment was only 62% in the maxilla and 83% in the mandible of the test group and almost completely preserved in the control group. For clinical end points, the number of recessions was significantly higher in test compared with control group ( $4.9 \pm 2.4$  and  $2.3 \pm 3.6$ ), but not the number of teeth missing and teeth with a probing depths  $> 4$  mm.

**Conclusion:** In sheep, the cumulating effects of aging, hypogonadism, malnutrition and glucocorticoid application can cause substantial catabolic changes of periodontal tissue. The underlying mechanisms that culminate in periodontal deterioration require further studies.

198	Poster – Topic Technical and Biological Complications
-----	---

Bacteraemia following dental implant surgery

**Presenter: Bolukbasi N**

*Istanbul University, Istanbul, Turkey*

Co-authors: Bolukbasi N<sup>1</sup>, Ozdemir T<sup>1</sup>, Gurler N<sup>2</sup>

<sup>1</sup>Department of Oral Implantology, Faculty of Dentistry, Istanbul University, Istanbul, Turkey, <sup>2</sup>Department of Microbiology and Clinical Microbiology, Istanbul University Medical Faculty, Istanbul, Turkey

**Background and aim:** Transient bacteraemias are frequently detected following invasive dental procedures. Several studies have investigated the type and frequency of bacteraemias induced following different dental treatment protocols. It is not well established that the incidence of bacteraemia after dental implant surgery. The aim of this pilot study was to investigate the occurrence of bacteraemia associated with dental implant installation.

**Materials and methods:** Twenty generally healthy patients; six men and 14 female were enrolled in this study. Patients were not given any systemic antibiotics either preoperatively or postoperatively. All operations were carried out under local anesthesia. Duration of surgery, the number and location of dental implants, subgingival or supragingival healing were noted. Blood samples were taken from antecubital vein for three times. The first sample was obtained before the surgery, the second and the third samples were obtained 30 min and 1 day after the surgery. Each sample, consisting 20 ml blood, was inoculated to two Bactec bottles (Becton, Dickinson and Company, Ireland) (10 ml for aerobic culture bottle and 10 ml for anaerobic culture bottle). The bottles were incubated 14 days for the presence of microorganism. The sensitivity to antibiotics was determined by disc diffusion method. The patients were evaluated for signs of infection for postoperative 10 days.

**Results:** No aerob and anaerob bacteria were isolated in the preoperative and third blood samples. Five patients had anaerobic bacteraemia. The bacterial species found in these patients were; Methicillin-resistant coagulase negative staphylococci (MRCNS) (sensitive to vancomycin, teicoplanin, clindamycin, gentamicin, ofloxacin, levofloxacin), Methicillin-susceptible coagulase negative staphylococci (MSCNS) (sensitive to vancomycin, erythromycin,



clindamycin, gentamicin, sulfamethoxazole, ofloxacin, levofloxacin, teicoplanin, rifampicin, fusidic acid), Bifidobacteria (penicillin, vancomycin, teicoplanin, gentamicin, ciprofloxacin, clindamycin, erythromycin, norfloxacin), MSCNS (sensitive to teicoplanin, vancomycin, gentamicin, ofloxacin, cefoxitin, levofloxacin, fusidic acid) and Corynebacteria (sensitive to penicillin, vancomycin, teicoplanin, erythromycin, clindamycin, gentamicin, trimetoprim, sulfamethoxazole, ofloxacin). There was no sign of infection for postoperative 10 days.

**Conclusion:** In this preliminary study, maximum three dental implants were placed in generally healthy patients. A larger patient group with variant conditions must be evaluated for verifying this outcome. Because all of the species detected in the present study were anaerobic, we should consider changing prophylactic antibiotic regimen.

#### 199 Poster – Topic Technical and Biological Complications

### Complications of sinus floor augmentation in our clinic

**Presenter:** Imamura E

*Yokohama General Hospital, Yokohama, Japan*

**Co-authors:** Imamura E<sup>1</sup>, Kamikura T<sup>1</sup>, Takamatsu T<sup>1</sup>, Akaike T<sup>1</sup>, Kaminaga A<sup>1</sup>, Shigehara S<sup>2</sup>, Kawashima N<sup>2</sup>

<sup>1</sup>Department of Oral and Maxillofacial Surgery, Yokohama General Hospital, Yokohama, Japan, <sup>2</sup>Department of Clinical Engineering, Faculty of Biomedical Engineering, Tooin University of Yokohama, Yokohama, Japan

**Background and aim:** The aim of this study was to investigate the intra- and postoperative complications of sinus floor augmentation in our clinic.

**Materials and methods:** This study consisted of 53 patients (20 males and 33 females) who underwent 63 sinus floor augmentation using the lateral wall approach from 2001 to 2008. Age is ranging from 36 to 68 years (average 54.5). In 17 cases, implants were installed at the time of sinus grafting. Sinus septa of elevated site was found in six sinuses. Autogenous bone was applied in 53 sites and composite of autogenous bone and be-ta tricalcium phosphate were applied in 10 sites. Autogenous bone was harvested from mandibular ramus, symphysis, iliac crest and tibia. The items of intra- and postoperative investigation were as follows: (1) abnormal bleeding of grafted site, (2) infection of grafted site postoperatively, (3) perforation of the Schneiderian membrane, (4) other complications related surgery.

**Results:** Abnormal bleeding required blood stanching was occurred in three sites (4.7%). Perforation of the Schneiderian membrane was occurred in four sites (6.3%), but infection was not occurred in these cases. Infection of grafted site was occurred in four sites (6.3%). One patient was occurred in cellulitis. Sensory disturbances of mandible with harvesting were occurred in three cases.

**Conclusion:** Although several complications may occur, sinus floor augmentation seems to be clinically useful modality prior to implant placement. But we need careful observation intra- and postoperatively.

#### 200 Poster – Topic Technical and Biological Complications

### Clinical evaluation of implant-tooth supported fixed partial prosthesis

**Presenter:** Ozgen M

*Istanbul University, Istanbul, Turkey*

**Co-authors:** Ozgen M, Gultekin BA, Bayraktar M, Shiraliyev S, Yalcin S

*Istanbul University, Istanbul, Turkey*

**Background and aim:** In clinical applications frequently implant-tooth-supported fixed partial prostheses(FPP) are not recommended because of the differences in the biomechanics of natural teeth vs. implants. The purpose of this prospective clinical study was to evaluate the assumption that a rigid connection of implants to teeth to support a three and two occlusal unit FPP causes more marginal bone loss around implants because of increased bending of a load under functional loading.

**Materials and methods:** In this study 25 Astra Tech dental implant applied to 23, systemically healthy, patients. In all of the FPP, the anterior premolar abutment tooth was rigidly connected to an implant (Ø 4.5 mm–11 mm Astra Tech Direct Abutment). Eleven implants have 8.25 mm distance between natural tooth and support three occlusal unit FPP, and 14 dental implants have 2.36 mm distance between a natural tooth and support two occlusal unit FPP. Marginal bone levels (MBLs) at the mesial and distal side of implant support were measured linearly on the periapical radiographs made by a paralleling device.

**Results:** Marginal bone level changes at mesial and distal sites of the implants supporting three occlusal unit FPP in 20 months of functional loading were 0.35 and 0.19 mm, respectively. Marginal bone level changes at mesial and distal sites of the implants supporting two occlusal unit FPP in 20 months of functional loading were 0.23 and 0.16 mm, respectively.

**Conclusion:** In our study, the distance between the dental implant and natural tooth did not effect the bone resorption around the dental implants.

#### 201 Poster – Topic Technical and Biological Complications

### Comparison of simultaneously cortical perforation of recipient bed and block bone, and only cortical perforation of recipient bed

**Presenter:** Jang IG

*Samsung Medical Center, Seoul, Korea*

**Co-authors:** Jang IG, Shin CH, Hong J

*Samsung Medical Center, Seoul, Korea*

**Background and aim:** The aim of this study is to analyze resorption rate and revascularization of autogenous block bone grafts in simultaneously cortical perforation of recipient beds and grafts, and only cortical perforation of recipient beds.

**Materials and methods:** Two block bone in 8 mm diameter was harvested in both skull using trephine bur on 20 New Zealand white rabbits. Harvested block bone was grafted on both inferior border of mandible. On the left side (experimental side), cortical bone of recipient beds and graft were perforated, and on the right side (control side), the only recipient bed was perforated. The

rabbits had been sacrificed and infused the India ink for the observation of revascularization at 20 day and 40 day after surgery. The specimens were proceeded for H-E staining and quantitative analysis (independent *t*-test,  $P < 0.01$ ) was made under an optical microscope. In additional, specimens were proceeded for the observation of revascularization.

**Results:** After 20 days, more bone volume was observed in experimental group, but no significant difference between two groups ( $P = 0.106$ ). There were significantly more bone volume in the experimental group at 40 days after surgery ( $P < 0.01$ ). After 20 days, more discrete vascular sprouts were observed in experimental side, but no difference at 40 days after surgery.

**Conclusion:** We conclude that the cortical perforation of both the recipient beds and grafts improve revascularization at early stage and overall graft persistence.

## 202 Poster – Topic Technical and Biological Complications

### Implant supporting maxillary full-arch prostheses: 3-year data

**Presenter:** Piombino M

*Clinic for Periodontal and Implant Surgery, Grumo Nevano, Italy*

**Co-authors:** Eccellente T<sup>1</sup>, Piombino M<sup>1</sup>, Festa P<sup>1</sup>, Piattelli A<sup>2</sup>

<sup>1</sup>*Clinic for Periodontal and Implant Surgery, Napoli Italy*, <sup>2</sup>*Chieti, Italy*

**Background and aim:** This multicenter study reports the clinical outcomes after 3 years of function of dental implants supporting maxillary full-arch bridges in maintenance therapy.

**Materials and methods:** Between March 1 to May 6 a total of 189 Ankylos implants were placed in 32 patients with edentulous maxilla. The mean age was 60 years (range 46–72). The implants/patient (Im/P) distributions was: 5Im/11P; 6Im/16P; 7Im/3P; 8Im/1P; 9Im/1P. 62 implants (32.8%) were placed consecutive to tooth extraction. The implants' length ranged from 8 to 14 mm. After 4–6 months of submerged healing the implants were loaded with cemented metal-ceramic full-arch prostheses. The total number of units replaced was 453. All patients were submitted to a quarterly control. In different time intervals PII, SBI, GI, standardized peri-apical radiographs, technical complications, patients satisfaction were recorded.

**Results:** After submerged healing time all implants became osseointegrated. During a total observation period of 3 years (range 2–7) 2 implant were lost. Biological complications (bone loss > 2 mm; GI+ and SBI+) occurred in 6.3% of the implants. All other implants presented healthy soft and hard tissues conditions. Eight patients presented a total of 15 ceramic fractures. Five patients were not satisfied with aesthetic of the rehabilitation. Two patients referred phonetic difficulty.

**Conclusion:** Favourable clinical conditions were found at implants after 3 years of function. The long-term success of implant therapy depends surely from osseointegration, but not less important is the soft tissues integration. The characteristic design of the implant-abutment connection produces a not relevant microgap and significantly influence the peri-implant

soft tissue and bone level stability. It is concluded that a correct oral hygiene, the presence of keratinized mucosa and microgap design, could influence the stability of peri-implant tissues and the longevity of implants. Bruxism as well as extensions were associated with more technical failures.

## 203 Poster – Topic Technical and Biological Complications

### Parafunctions and implant overloading: how to avoid implant prosthetic complications

**Presenter:** Garagiola U

*University of Milan, Inveruno, Italy*

**Co-authors:** Garagiola U<sup>1</sup>, Farronato D<sup>1</sup>, Mercatali L<sup>1</sup>, Szabo G<sup>2</sup>, Laskin D<sup>3</sup>

<sup>1</sup>*University of Milan, Milan, Italy*, <sup>2</sup>*Semmelweis University, Budapest, Hungary*, <sup>3</sup>*Virginia Commonwealth University, Richmond, VA, USA*

**Background and aim:** The aim of this study was to show the destructive effects of abnormal occlusal forces on implant supported prostheses in patients with bruxism, abnormal habits and other parafunctions, and to focus on concepts and the clinical procedures to reduce the potential risk factors for implant failure.

**Materials and methods:** Forty TMD patients were compared to 40 no-TMD patients in which were inserted 430 implants with the same features as number, size, position, design. Another experimental group of 50 TMD patients treated by prevention protocol was assessed. Besides, were considered type of restoration, cemented or screwed, malocclusion type, smoking, load timing. The heavy force of compression, clenching and grinding, as in bruxism, simultaneously applied strong pressures to the implants, crestal bone, restorations and temporomandibular joints. This was a potential risk factor for crestal bone loss, loss of integration before and after restoration, abutment screw loosening and fracture, implant fracture, decementation of restorations and fracture of the porcelain.

**Results:** The 5 years follow-up showed a 58% of soft tissues, bone and prosthetic complications in TMD patients vs. a 13% in non TMD patients. When TMD patients were undergone to occlusal overload prevention protocol, the complications were diminished to 15% ( $P < 0.001$ ). The results indicated that increasing the number of implants and reducing cantilevers decreased the stress on each one; using the longest and widest implant possible increases implant/bone surface area and reduces also strain on the restorations. Also implant design, occlusal table size, the direction, duration and magnification of the forces influenced the stress at the crestal bone/implant surface. Using an occlusal splint and performing occlusal adjustment, anterior guidance during excursive movements reduced forces and eliminate all lateral occlusal contact. Frequent occlusal follow-ups were mandatory to eliminate prematurities and interferences

**Conclusion:** Developing treatment plan that control the chronic bruxism through night-guards and an occlusal adjustment protocol to modify the occlusal forces on implants and their restorations, patients with temporomandibular disorders and bruxism can be candidates for implants.

## A case report of nasopalatine duct cyst caused by dental implant

**Presenter:** Takeshita K

*Takeshita Dental Clinic Success Implant Center, Tokyo, Japan*

**Co-authors:** Takeshita K<sup>1</sup>, Funaki K<sup>1</sup>, Mihashi K<sup>1</sup>, Takahashi T<sup>2</sup>

<sup>1</sup>*Takeshita Dental Clinic Success Implant Center, Tokyo, Japan,*

<sup>2</sup>*Division of Oral and Maxillofacial Reconstructive Surgery, Kyushu Dental College, Kitakyushu, Japan*

**Background and aim:** The dental implant in maxillary anterior region may place adjacent to an incisal canal. Some troubles caused by an incisal duct were bleeding or disintegration, but there were few reports of a nasopalatine duct caused by implant placement. This case report presents an analysis of the clinical, radiographic, and histological findings of a nasopalatine duct cyst around an implant after extraction of a tooth.

**Materials and methods:** A 45-year-old man visited our office because of root fracture of left central incisor of maxilla. Implant treatment was planned. Preoperative X-ray showed a normal morphology of the incisal canal. The implant was placed palatally to achieve good primary stability immediately after tooth extraction. 2.5 years after implant placement, the patient had not showed any clinical signs of symptoms, but radiographic examination showed radiolucency of crown size at the apical lesion of the implant. The Computed tomography (CT) revealed the radiolucency of 10 mm size containing incisal canal. As doubt of the nasopalatine duct cyst, we planned the cystectomy and the apicoectomy of the implant because of the good stability of the implant. After the buccal mucoperiosteal flap was reflected, there was the resorption of the apical buccal bone and the cyst wall. The cyst was removed, but the cyst wall adhered to the incisal canal. After cutting off, 3 mm of apical part of the implant was removed.

**Results:** The diagnosis of the histopathological analysis was a nasopalatine duct cyst. Pseudostratified ciliated columnar epithelium was found. After removing the cyst, maintenance program was carried out every four months. No complication is found by oral, examination, Dental X-rays and the CT. Healing is uneventful.

**Conclusion:** We concluded that the nasopalatine duct cyst developed because drill and implant were in contact with an incisal canal at implant placement. It was suggested that preoperative CT diagnosis and careful planning of operation could prevent complication such as the nasopalatine duct cyst caused by implant placement.

## Correction of infraocclusioned implant with segmental osteotomy: a case report

**Presenter:** Park KD

*More Dental Clinic, Suncheon, Korea*

**Co-authors:** Park KD<sup>1</sup>, Jeon HR<sup>2</sup>, Kook MS<sup>1</sup>

<sup>1</sup>*Chonnam National University, Gwang-Ju, Korea,* <sup>2</sup>*Jinsu Dental Clinic, Gwang-Ju, Korea*

**Background and aim:** Even in patients after the growth period, implants in the anterior portion of maxilla cause aesthetic

problems due to change in dentition in 5–10 years. The Implant behaves like ankylosed teeth and do not followed the changes of the alveolar processes due to continuous eruption of adjacent tooth. Therefore, this can lead to a vertical step between the implant and the neighboring natural teeth like a infraocclusioned tooth. This can usually be aesthetically repaired using new prosthetic crown or by surgical methods. The aim of this clinical example is to present a new flap design and complications in the segmental osteotomy technique during the correction of the malpositioned dental implant.

**Materials and methods:** A 29-year-old female patient with infra-occlusioned implant (central incisor) was treated with the segmental osteotomy technique. The implant was placed 10 years ago. Only two vertical incisions were done mesially and distally to the implant to maintain the blood supply. The vertical incisions were extended till the mucogingival junction to preserve the papillary tissue. Thin partial thickness dissection was made between the two vertical incisions like a tunnel technique. Then, conventional segmental osteotomy was performed. The segment was stabilized by resin provisional crown cap and wire-resin bonding. Subepithelial connective tissue graft was used to augmented the labial side after almost 4 months. Connective tissue was harvested from the palate and it was positioned labially under a split-thickness mucosal flap to increase the volume.

**Results:** The segment with the implant was repositioned coronally and lingually by using segmental osteotomy and connective tissue graft and showed better position for new aesthetic prosthetics. Segmented bone was fixed in the new position and satisfactory aesthetic results were obtained.

**Conclusion:** The segmental osteotomy with two vertical incisions and partial thickness flap technique could be an alternative method to correct the malpositioned or infraocclusioned implants. Therefore, we report our case with a view of literature.

## Immediate loading after immediate implant placement following tooth extraction upregulate the expression of bone related protein MRNA

**Presenter:** Sato R

*Tokyo Dental College, Chiba, Japan*

**Co-authors:** Sato R, Kokubu E, Morito T, Hara T, Yuasa K, Kenmotsu M, Miwa T, Sultan Zeb K, Kimura Y, Matsuoka K

*Department of Clinical Pathophysiology, Tokyo Dental College, Chiba, Japan*

**Background and aim:** Immediate loading after immediate implant placement following tooth extraction have gotten an attention, however, there are a few reports with regards to basic experiments. The purpose of this study was to investigate the expressions of bone-related protein mRNA of the tissues around the dental implant which was implanted following tooth extraction and immediate loaded in dog.

**Materials and methods:** Ten beagle dogs were used in this study. Forty-two sand-blasted titanium implants were immediately placed into the extraction socket of premolar teeth. Every implant sites were covered by e-PTFE membrane. The implants were divided into two groups; non-loading which was submerged and loading groups which received upper structure made from composite resin. The implant circumferential tissues were corrected at each of 1, 2 and 3 weeks after the operation. The tissue from extraction socket without implant was used as control. And then, expressions of alkaline phosphatase (ALP), osteopontin (OPN) and Osteocalcin (OCN) mRNA were analysed by quantitative RT-PCR. Two implants at each of the time periods were embedded in MMA-resin, and observed histologically.

**Results:** The tissues from loading group showed significantly increased the expression of ALP mRNA compared to control group at each of the time period ( $P < 0.05$ ). At 1 week, tissues were mainly composed of few fibroblasts, the expressions of OPN mRNA of the tissues from loading group were significantly upregulated than those of non-loading and control groups ( $P < 0.01$ ). However, there were no significantly difference between non-loading and loading groups at 2 weeks, tissues were composed of fibroblasts and capillaries and 3 weeks, tissues were composed of newly formed woven-bone which were surround by active osteoblasts. The expression of OCN mRNA of the tissues from loading groups was significantly upregulated compare to non-loading group at each of the time period ( $P < 0.05$ ).

**Conclusion:** These results suggest that the loading affect the expression of bone-related protein mRNA of the tissues around the dental implant which implanted immediately after the tooth extraction, in terms of creation of the osseointegration.

207 Poster – Topic Technical and Biological Complications

Which is better biomechanically? Connecting short with short or short with long implants

**Presenter:** Yang TC

Osaka University, Graduate School of Dentistry, Suita, Japan

**Co-authors:** Yang TC, Maeda Y, Gonda T, Wada M

Department of Prosthodontic and Oral Rehabilitation, Graduate School of Dentistry, Osaka University, Suita, Japan

**Background and aim:** In the posterior edentulous region with poor quantity and quality bone, connecting a short implant with a long one is considered as a treatment option to reduce the biomechanical complications and improve the survival rate (Ten Bruggenkate et al, 1998). However, it is also reported the connecting short ones may also be available (Renouard et al, 2008). The aim of this study was to examine the difference in biomechanical efficacy of stress distribution by connecting implants with different length and diameter using *in vitro* model.

**Materials and methods:** Titanium implants (3.8 × 7 mm:  $n = 2$ ; 4.4 × 7 mm:  $n = 2$ ; 5.0 × 7 mm:  $n = 2$ ; 4.4 × 12 mm:  $n = 1$ ; GC,

Japan) connected with abutments (height: 13 mm, GC, Japan) were embedded into PMMA resin block simulating low-density bone. Seven strain gauges were attached on implant external surfaces 1 mm below the abutment-implant connection. Fifty Newton of 30° angle lateral load was applied on to each abutment. The result from each implant was considered as non-splinted and the control groups for comparison. Then, abutments of two of 3.8, 4.4 and 5.0 mm diameter 7 mm length short implants were connected and applied with the same loading protocol. In addition, each of these 3.8, 4.4, 5.0 mm diameters short implant was connected to the 4.4 × 12 mm implant to evaluate the influence of different connecting conditions of splinted restorations on the maximum strain value (MSV).

**Results:** MSV became smaller progressively with significant differences ( $P < 0.01$ ) as the implant diameters were changed from 3.8 to 5.0 mm among non-splinted implant restorations. Splinted short implants pairs showed significantly smaller MSV ( $P < 0.01$ ) than non-splinted ones. MSV was almost identical when short implants were connected to the 4.4 × 12 mm implant compared to splinted short implant pairs.

**Conclusion:** Within the limitation of this *in vitro* model study, it is suggested that there is a 'primary supporting area' of bone around implant where the majority stress is supported. This is the reason for identical biomechanical efficacy between connecting short with short and short with long implants. Splinted restoration supported by short implants with wider diameter may use the primary supporting area more effectively which have the significant effect on stress reduction than supported by long implants with smaller diameter.

208 Poster – Topic Technical and Biological Complications

Morphological and structural properties of a DPSS ND:YAG Q-switching laser treated implant surface

**Presenter:** Codan B

Università degli Studi di Trieste, Trieste, Italy

**Co-authors:** Codan B<sup>1</sup>, Bellomo F<sup>1</sup>, Biasotto M<sup>1</sup>, Prosperi M<sup>2</sup>, Di Lenarda R<sup>1</sup>

<sup>1</sup>Università degli Studi di Trieste, Trieste, Italy, <sup>2</sup>GEASS srl, Udine, Italy

**Background and aim:** Titanium screws have been the most used dental implant for decades. Titanium surface composition, topography, roughness and surface energy play an essential role in the initial phases of bone regeneration and in the final clinical outcome of the implant. Recently it has been developed a novel surface treatment, designed to produce dental implant with a predictable micro-topography and lacking in polluting agents. This result is obtained exploiting a laser source which makes microfabrication industrially feasible. We developed a DPSS (Diode Pumped Solid System) laser Nd:YAG in Q-switching (GEASS, SyntheGra®), the laser source able to produce surfaces with biomimetic characteristics thanks to the perfect focus of the beam, the brief impulse and the wavelength. In this study, we

defined the morphology of the laser treated titanium surface at micrometric and nanometric level, analyzing in depth the entire hole and the related surrounding area.

**Materials and methods:** Titanium discs (2.5 mm thick and 6 mm in diameter) were used for all the experiments. The Ti discs were treated with the DPSS Nd:YAG Q-switching laser in order to obtain different patterns. To perform the topography analysis a profilometer (*Talysurf CLI 1000, Taylor Hobson USA*) and a AFM (Atomic Force Microscope – *Perception, Assing, Italy*) were used.

**Results:** Profilometer and AFM permit to have morphological information of different magnitude. The first one demonstrated the regular distribution of the holes and the average size and shape, suitable for the osteointegration. The second one was performed on a smaller area but with nanometric resolution. A study of the roughness of the fusion ring is here presented, with the demonstration for the biocompatibility of the surface morphology.

**Conclusion:** From the results obtained, we can conclude that the DPSS Nd:YAG Q-switching laser technology allows to produce predictable and predetermined surfaces, suitable to increase the implant osseointegration.

#### 209 Poster – Topic Technical and Biological Complications

### Radiographic characteristics of the incisive canal in the anterior mandible

**Presenter: Romanos G**

*Eastman Dental Center, Rochester, VA, USA*

**Co-authors: Romanos G<sup>1</sup>, Papadimitriou D<sup>1</sup>, Royer K<sup>2</sup>, Caton J<sup>1</sup>**

<sup>1</sup>*Eastman Dental Center, Division of Periodontology, Rochester, VA, USA*, <sup>2</sup>*Eastman Dental Center, Division of General Dentistry, Rochester, VA, USA*

**Background and aim:** The presence of the mandibular incisive canal (MIC) as an intraosseous anterior extension of the N. alveolaris inferior is of special interest in patients, who require surgical procedures in the chin region. The aim of this study was to investigate the presence of a MIC based on conventional panoramic radiographs.

**Materials and methods:** One thousand and forty-five radiographs randomly chosen from the patients of the Eastman Dental Center presented data including patient characteristics and presence/absence of MIC. The presence of a MIC was classified according to the patient dental condition, such as: Group 1: Edentulous; Group 2: Partially edentulous; Group 3: Patients with full dentition or restorations. Measurements (in mm) were performed considering the magnification scale of the Panorex evaluating the following parameters: (A) thickness of the canal; (B) length of the canal extending anterior to the mental foramen; (C) minimum distance from the alveolar ridge; (D) maximum distance from the alveolar ridge; (E) distance between the canals (in bilateral cases).

**Results:** The MIC was documented in 2.7% (7 males, 21 females). No cases (0%) were found within Group 1, 67.9%

were included within Group 2, while 32.1% were included in the Group 3. Six patients showed a bilateral MIC. The measurements in mm were: A: 1.48 ( $\pm 0.57$ ); B: 10.7 ( $\pm 4.95$ ); C: 16.06 ( $\pm 2.8$ ); D: 18.24 ( $\pm 2.73$ ); E: 27.07 ( $\pm 15.57$ ).

**Conclusion:** This radiological analysis presents the prevalence and morphological characteristics of the MIC in the mandible, in order to avoid surgical complications.

#### 210 Poster – Topic Technical and Biological Complications

### Survival rate and complications of implant-supported mandibular overdentures after 15 years

**Presenter: Orujov A**

*Azerbaijan State Institute for Medical Postgraduates, Baku, Azerbaijan*

**Co-authors: Orujov A<sup>1</sup>, Aliyeva L<sup>2</sup>, Lorenzoni M<sup>1</sup>, Wegscheider W<sup>1</sup>**

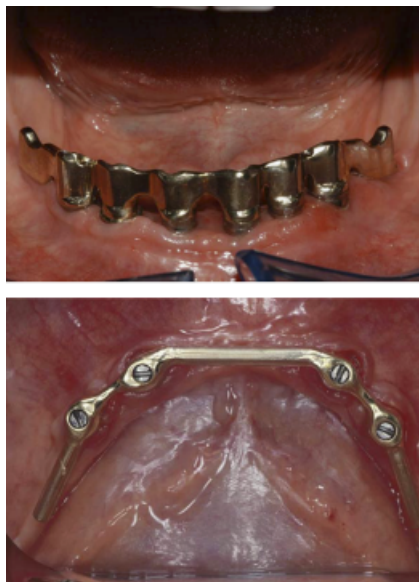
<sup>1</sup>*Azerbaijan State Institute for Medical Postgraduates, Baku, Azerbaijan*, <sup>2</sup>*New York University College of Dentistry, New York, NY, USA*, <sup>3</sup>*Graz Medical University, Graz, Austria*

**Background and aim:** Within this paper, we observed an implants treatment's outcome rate reported for patients with mandibular overdentures. Key features that included recording of results with prosthodontic treatment by mandibular overdentures, supported with IMZ, Frialit2 and XIVE implants were evaluated. The purpose of this retrospective clinical study is to evaluate and compare clinical success of the implant retained mandibular overdentures with a bar framework supported by various implant systems within a 15-year-period. The purpose of this retrospective clinical study is to evaluate and compare clinical success of an implant retained mandibular overdenture with a bar framework supported by various implant systems within a 15-year-period.

**Materials and methods:** A total of 123 patients with an edentulous mandible were treated in the Department of Prosthodontics and Implantology at the Graz Medical University. Between 1990 till 2005 a total of 546 implants were placed using the following implant systems: Frialit2 - 472 (76.8%), XIVE - 30 (4.8%) and IMZ - 112 (18.2%), accordingly. Overdentures and mesiostructures (gold cast gold-alloy base) with Dolder bars/individual milled-bars with distal extensions were provided for all patients. The research evaluation included clinical and X-ray data, follow-up evaluation and patient satisfaction survey according to the type of bar construction and the implant system used.

**Results:** All complications that became evident in this period were sorted according to the bar framework and the type of implant used. Further on, the problems were differentiated into following categories: complications with marginal soft tissue, complications with implant osseointegration (implant loosening and atrophy of surrounding alveolar bone), complications with bar construction and complications with prosthetic function.

## Conclusion:



On the basis of the clinical results, we concluded that the Frialitz and XIVE implant systems have a higher survival rate, more predictable results and better clinical function than IMZ implant system. Therefore, Frialitz and XIVE systems should be the method of choice for the edentulous mandible. It is also imperative to note that the frequency of complications with Dolder bar constructions were slightly more expressed than with individual milled-bar constructions. It is necessary also to note such point as necessity of regular follow-up. Further investigations of such problem as a material fatigue of the cast metal frame are recommended.

## 211 Poster – Topic Technical and Biological Complications

### Tooth-implant supported fixed partial dentures (FPDS): long-term results

#### Presenter: Rossi A

*Clinic for Periodontal and Implant Surgery, Grumo Nevano, Italy*

Co-authors: Eccellente T, Piombino M, Rossi A, Piombino S, Pezzella P

*Clinic for Periodontal and Implant Surgery, Grumo Nevano, Italy,*

**Background and aim:** To evaluate the biological and technical outcome of teeth and implants supporting FPDs.

**Materials and methods:** Sixty-nine partially edentulous patients (mean age 59 years) were rehabilitated with 75 metal-ceramic FPDs tooth-implant supported. Of the bridge abutments 119 were teeth and 108 were implant (11 Branemark, 35 Straumann and 62 Ankylos implants). The units replaced by the FPDs were 319. After prosthetic treatment, all patients were submitted to a quarterly control and followed at least 4 years (4–13 years). Clinical and radiographic parameters, patient' satisfaction, and technical complications were recorded.

**Results:** Four patients with a total of 12 abutments (five implants, seven teeth) were not present to recall. During a total observation period of 7.5 years, three implants were lost to development of a bone defect. Two teeth had a vertical fracture

and three teeth were lost due to periodontitis. Biological complications (PPD >5 mm and BOP+) occurred in 7.7% of the implants and in 9.8% of the abutments teeth (3.6% had secondary caries, 1.8% endodontic problems, 4.4% periodontitis). Eight bridges presented ceramic fractures. Five cases of abutments screws loosening occurred. Two patients were not satisfied with aesthetic of the rehabilitation.

**Conclusion:** Favourable clinical conditions were found at tooth and implants abutments after 4–13 years of function. Technical complications have been related to designs of different implant-abutment connections. The internal-tapered connection provides more mechanical stability.

## 212 Poster – Topic Technical and Biological Complications

### Assesment of prosthetic complications in full-arch implant supported zirconia bridges: a retrospective analysis of 59 consecutive cases with a 12–29 month follow-up

#### Presenter: Sousa S

*Instituto de Implantologia, Lisboa, Portugal*

Co-authors: Sousa S, Pragosa A, Crispim P, Moreira A, Dias M, Caramê J

*Instituto de Implantologia, Lisbon, Portugal*

**Background and aim:** Zirconia frameworks offer new perspectives in metal-free restorations because of its mechanical properties and also because of its aesthetically appealing clinical results. After its introduction as a framework material for tooth supported single crowns in the beginning of this decade, its encouraging results led the industry to widen zirconia's applications: first to tooth supported short span bridges, then to implant supported abutments and finally to full-arch implant supported screw-retained bridges. Currently the above-cited treatment modality is regarded as the state-of-the-art in full-arch rehabilitation. Despite that, the literature concerning prosthetic complications and survival rates of this kind of rehabilitation is scarce. The aim of this study was to assess consecutive cases restored with zirconia full-arch screw-retained implant bridges for complications and to determine a co-relation between them and occlusal factors such as the opposing arch.

**Materials and methods:** This study is based upon 59 consecutive full-arch screw-retained implant bridges with zirconia framework (ZirkonZahn) restoring 43 patients. All cases were checked for passive-fit of the framework and were occlusion adjusted in centric occlusion and in eccentric movements. After delivering of the final prostheses, all the patients followed regular check-up consultations with their restoring dentists (three) and the follow-up period ranges now between 12 and 29 month. In a merely prosthetic stand-point all cases were assessed for implant-related complications (implant fracture or screw-loosening), zirconia framework fracture and ceramic veneering fractures (minor chipping and major fractures).

**Results:** Of the 59 full-arch screw-retained zirconia implant bridges, 36 were placed in the maxilla and 23 in the mandible. There were 16 bi-maxillary cases (32 bridges), 15 bridges opposing

a natural dentition and 13 bridges opposing metal-acrylic screw retained implant bridges. No implant fractures were reported. Screw-loosening was reported in 5% of the cases. Zirconia framework fracture occurred in two cases (3.4%) both in the first week after delivering. Chipping of the veneering ceramic occurred in 25% of the cases. The overall prosthetic complications rate for the 59 cases was 28%. All prosthetic complications occurred in cases in which bi-maxillary implant supported rehabilitations with zirconia opposing zirconia frameworks were used.

**Conclusion:** Despite all the aesthetic advances inherent to zirconia bridges, the overall prosthetic complications rate of this kind of rehabilitation tends to be higher than the gold-standard treatment modality (metal-ceramic bridges) when no resilient elements are present (teeth or metal-acrylic bridges).

#### 213 Poster – Topic Technical and Biological Complications

### Bone level changes in single tooth implants

**Presenter: Eccellente T**

*Clinic for Periodontal and Implant Surgery, Grumo Nevano, Italy*

**Co-authors: Eccellente T, Piombino M, Rossi A, Capasso S**  
*Clinic for Periodontal and Implant Surgery, Napoli, Italy,*

**Background and aim:** The objective of this multicenter study was to retrospectively analyze the marginal bone loss in single tooth implants.

**Materials and methods:** Inclusion criteria were (1) missing single tooth with the presence of adjacent dentition, (2) minimal mesiodistal space on the top of the bone crest 6.0 mm (range 6–12 mm). Forty-nine patients received 64 Ankylos Plus implants (Dentsply, Friadent, Mannheim, Germany) in healed sites. Implant length ranged from 8 to 14 mm. The implant diameter distribution was: 62.5% of diameter 3.5 mm, 31.25% of diameter 4.5 mm and 6.25% of diameter 5.5 mm. All implants were inserted at least 1 mm below the vestibular plate. Marginal bone level using standardized periapical radiographs were evaluated at the implant loading, 6, 12 and 24 month later. Before II stage surgery, soft tissue thickness was clinically measured and all complications were noted.

**Results:** One implant was removed 3 weeks after implantation. After 3–4 months of submerged healing, all other implants were osseointegrated and were loaded with cemented crowns. After at least 36 months of function (36–45 months), no implant was lost and the cumulative survival rate was 98.5%. Radiographic mean bone loss evaluating both interproximal surfaces was 0.48 mm (range 0.35–1.43 mm). Only 12% of the sites showed a crestal bone loss > 1 mm. The majority of implants presented healthy peri-implant soft tissue conditions showing low values of clinical parameters (mPLI = 1, mSBI > 1). During the observation period no patient reported swelling or suppuration, three patients reported ceramic fractures. No complications related to implant components occurred.

**Conclusion:** The implant-prosthetic replacement of single tooth implant has proved to be a predictable treatment. The characteristic design of the implant-abutment connection pro-

duces a not relevant microgap and significantly influence the peri-implant soft tissue and bone level stability. In case of thin gingival tissue, we can expect crestal bone loss in the process of biologic width formation.

#### 214 Poster – Topic Technical and Biological Complications

### Diplopia complication after dental implant placement

**Presenter: Souza D**

*Los Gatos Dental Center, Los Gatos, CA, USA*

**Co-authors: Souza D, Moneim A**

**Background and aim:** Diplopia can be one of the symptoms of benign paroxysmal positional vertigo (BPPV). The ethiology of BPPV may be idiopathic, viral, ischemic or traumatic. Placement of maxillary implants has also been associated with BPPV. However, those cases are usually attributed to longer operation time, trauma of the maxilla and inner ear and head hyperextension. This study illustrates an unusual case where the same patient suffered diplopia and other symptoms of BPPV after undergoing two events of dental implant placement in the posterior maxilla within a 6-month period.

**Materials and methods:** 66 years old male, non-smoker, history of bypass surgery, had an implant placed after extraction of the upper second left molar under local anesthesia infiltration 2% Lidocaine w/1:100,000 epinephrine. The patient presented diplopia as the main complaint after the surgery together with imbalance, light-headedness, weakness, nausea, slight fever and anxiety. After 5 days, as the symptoms were still the same, the implant had to be removed. Twelve days after implant removal, the symptoms had subsided. Six months after this first diplopia episode, the patient was submitted to a second implant surgery at the same site using flapless technique. Eventhough the second surgery was quick, the patient had diplopia but this time with other mild symptoms. MRI scan of the brain has been done after the first diplopia episode and another MRI scan of the orbits has been done after the second diplopia episode in order to seek for any related abnormality after both implant placement.

**Results:** First MRI scan of the brain without a die suggested microvascular ischemia associated with diplopia and the second MRI of the orbits was normal with no area of signal abnormality or enhancement within the orbits; the optic nerves and extraocular muscles were symmetric and normal in appearance. There was no evidence of intracranial haemorrhage and no abnormal intra or extraaxial fluid collection. All symptoms disappeared after 2 weeks with no recurrences.

**Conclusion:** The diagnose of the patient according to his ophthalmologist and physician suggested no relation between diplopia and dental implant placement. However, since it happened twice with the same patient after placing an implant in the same site, it may be suggested a correlation between both episodes. One possibility is the administration of local anaesthesia with epinephrine in the posterior upper jaw or inner ear trauma induced by dental turbine noise working in maxilla. Also the supine position with hyperextension head movement may have caused some of the symptoms of BPPV.

## CAD/CAM fabrication of all-ceramic crown as a superstructure for posterior implant: a case report

**Presenter:** Terada T

*Toshi Dental Clinic, Chiyoda-ku, Japan*

**Co-authors:** Terada T<sup>1</sup>, Sasaki H<sup>2</sup>, Takahashi T<sup>3</sup>

<sup>1</sup>*Toshi Dental Clinic, Tokyo, Japan*, <sup>2</sup>*Japanese Society of Computer Aided Dentistry, Tokyo, Japan*, <sup>3</sup>*Kyusyu Dental College, Fukuoka, Japan*

**Background and aim:** CAD/CAM systems for dentistry have been attracting attention both in Japan and elsewhere. We fabricated implant superstructures using CEREC 3D (Sirona®) and achieved an excellent result. Although the follow-up period is not long enough, we summarized our experiences in this poster presentation.

**Treatment procedure:** The patient was a 51-year-old male who visited us in November 2007 with a chief complaint of pain in the left posterior area of the maxilla. Dental and panoramic X-ray examinations and periodontal probing revealed periapical cyst and bone loss in the maxillary left first molar region. The bone loss extended to the second molar area. The treatment plan included extraction of the hopeless maxillary molar teeth, implant placements and fabrication of crown using CEREC 3D.

**Materials and methods:** The left upper first and second molars were extracted in November 2007. Implants (SP 10.0 mm WN, Straumann) were placed, and, after healing, solid abutments (height: 4.0 mm) were connected at a torque of 35 N cm. Using a wax-up from the model, the crown was designed using CEREC 3D correlation mode and milled out of lithium disilicate glass-ceramic block, IPS.e.max CAD (Ivoclar Vivadent®). Fine adjustments of occlusion and contacts were made while the material was still in blue-color state (crystalline intermediate phase in which manual adaptations and cutbacks are possible). After staining and glazing, the crowns were finally connected.

**Results:** Postoperative course to date is good with no sign of mobility or fracture of implant fixtures and superstructures.

**Discussion and conclusion:** All-ceramic crowns fabricated by CAD/CAM systems have advantages such as less deterioration and higher biocompatibility. For this patient, we could fabricate restorations with excellent stability and esthetics from lithium disilicate glass-ceramic block with good opacity and strength. We will continue to follow the prognosis to assess the long-term outcome. Also, we would like to proactively use the chair side CAD/CAM solutions for the benefit of patients.

## Peri-implant pathogens: a problem of the local pocket or the whole oral cavity?

**Presenter:** Kwon YD

*Kyung Hee University Dental School, Seoul, Korea*

**Co-authors:** Kwon YD<sup>1</sup>, Yoo JY<sup>1</sup>, Song HW<sup>1</sup>, Karbach J<sup>2</sup>, Wagner W<sup>3</sup>, Al Nawas B<sup>3</sup>, Lee B<sup>1</sup>, Leesungbok R<sup>4</sup>

<sup>1</sup>*Department of Oral & Maxillofacial Surgery, Kyung Hee University Dental School, Seoul, Korea*, <sup>2</sup>*Department of Oral Surgery, University Clinic of Mainz, Mainz, Germany*, <sup>3</sup>*Department of Oral & Maxillofacial Surgery, University Clinic of Mainz, Mainz, Germany*, <sup>4</sup>*Department of Prosthodontics, Kyung Hee University East-West Neo Medical Center, Seoul, Korea*

**Background and aim:** The presence of yeast species such as *Candida* sp. in peri-implant pockets has been suggested but rarely investigated. The aim of this study was to evaluate the distribution status of peri-implant pathogens (periodontopathogens and yeasts) in peri-implant pockets in patients with implant-supported overdentures.

**Materials and methods:** Twenty-one edentulous patients who were seen regularly during oncologic recall were included using the following criteria: implant-supported prosthetics, implants which had been *in situ* for a minimum of 6 months from uncovering. Two implants per patient were selected for the detection of periodontal pathogenic microbiota and yeast on a split mouth basis. Clinical parameters (modified Plaque Index, probing depth, bleeding on probing) were recorded. Microbiological identification of periodontal pathogens was done by using the DNA probe (HAIN-lifescience GmbH, 72147 Nehren, Germany) test. To identify yeast species, classical microbiological methods using SAB agar plates and API-20C AUX (Biomérieux, Marcy-l'Etoile, France) were used.

**Results:** Concordance of microbiologic results in the two separated implants was evaluated with Kappa value. In 12 patients (57%), yeast sp. was found and periodontal pathogenic bacteria were identified in seven patients (33%). In the peri-implantitis group, the prevalence of yeast was 50% (9/18) and that of periodontal pathogens was 33% (5/15). In the healthy group, 33% (9/27) showed a positive result for yeast and 22% (6/27) showed a positive result to periodontal pathogens. However, none of these results were statistically significant ( $\chi^2$ ,  $P > 0.05$ ). Intraindividually, the occurrence of periodontal pathogenic bacteria showed high concordance ( $P = 0.004$ ), but for yeast a discordance was found ( $P > 0.05$ ).

**Conclusion:** Because of the strict criteria on the subjects, the number of the patients is more or less small to run a Kappa value but the result is still worth mentioning. To reveal more information on yeast distribution in peri-implant pockets, further investigation including longitudinal study would be needed and larger study would be required to detect such correlation. In contrast to the yeast colonization, which seems to be a local phenomenon, the distribution of periodontal pathogens might be an overall problem of the oral cavity.



### Implantation after traumatic injury of upper incisor, follow-up by cone beam CT: case report

**Presenter:** Kalmár G

*Semmelweis University, Budapest, Hungary*

**Co-authors:** Kalmár G, Joób Á

*Department of Oro-Maxillofacial Surgery and Stomatology,*

*Semmelweis University, Budapest, Hungary*

**Background and aim:** The aim of the poster is to present one possible complication of early implant placement and its solution. A case report of a traumatised maxillary incisor is presented. The left central incisor was fractured in the apical third of the root. The left lateral incisor and canine were luxated as well, but there was no fracture noticeable on the root, only at the coronal part. Because of the trauma the thin and porous maxillary facial cortical plate over the roots in this area was also injured, and the patient had bilateral mandibular fracture without dislocation.

**Materials and methods:** After removing the left central incisor root with flapless technique an implant therapy was planned. While placing the implant in the socket the injured cortical plate broke out, so without primary stability the implant had to be removed. Bone augmentation, GBR was necessary to do. The luxated teeth, after endodontic treatment were fixed with an orthodontic splint to the neighbouring teeth. The provisional acrylic crown was fixed in this splint with a brace.

**Results:** Nine months later implant placement could be done, and the immediate rehabilitation of the incisor was made with a cemented acrylic resin crown in non-occlusal loading. The final rehabilitation was made 2 months after the last surgery together with placing crowns on the lateral incisor and canine.

**Conclusion:** Even though early implant placement is an advantageous method in preserving bone mass, but if tooth loss was due to trauma special care is needed and the X-ray and CT images and the clinical picture are to be evaluated together. In such cases a wider surgical approach instead of minimal invasive methods is preferable.

### Clinical advices to use NobelGuide® with a cone beam CT scanner (E-Woo Picasso Trio)

**Presenter:** Avontroodt P

*Parodontologie Breda, Breda, the Netherlands Antilles*

**Co-authors:** Avontroodt P, Kranendonk A

*Parodontologie Breda, Breda, the Netherlands Antilles*

**Background and aim:** CBCT scans are becoming more popular in the dental world. Not only are they better for diagnosis and has less radiological radiation, but also it is possible to use them in a private practice. Because NobelGuide® is built for CT scan and works with Hounsfield Units it is not completely compatible for CBCT scans. At this moment there are many different cone beams on the market and it is difficult to use the standard protocol for them.

**Aim:** The main purpose of our poster is to evaluate the NobelGuide® protocol with the Picasso trio CBCT scanner. We will evaluate the different steps in the process. Tips and tricks will be given. The use of glass balls instead of gutta percha markers will be evaluated by a study.

**Materials and methods:** Twenty-seven patients were scanned. Nine patients have glass balls. The others have gutta percha markers.

**Results:** In the group of the glass balls the computer found in 100% of the patients automatically the markers. The mean and maximum error was 0.0895 and 0.1322. In the gutta percha group only in 19% of the patients the markers were found automatically. Sixty-eight percent of the markers were found after changing the settings to the maximum. In 13% of the cases the markers has to be search manually. The mean and maximum error was 0.1334 and 0.2165.

**Conclusion:** The use of a CBCT scan is compatible with the nobelguide® protocol but little changes are necessary during the converting process. The use of glass balls is better than gutta percha markers because of the computer friendly use.

### Evaluation of implant-supported bar designs with two and four implants (clinical study)

**Presenter:** Bayraktar M

*Istanbul University, Istanbul, Turkey*

**Co-authors:** Bayraktar M, Ozgen M, Shiraliyev S, Gultekin BA, Yalcin S

*Istanbul University, Istanbul, Turkey*

**Background and aim:** Clinicians recommended that the prosthesis with an implant-supported bar is practical and effective way in total edentulous patients. For long-term success the passive fit of bar attachment, the balance of occlusion and the patient cooperation is needed. The complications with bar attachment implant prosthesis may be classified biologically and mechanically. All problems may be solved earlier by frequent recalls.

**Materials and methods:** Rigid bar designs with two and four dental implants among different dental implant systems. The prosthetic maintenance service carried out during the 6-month period was recorded for both bar types in both groups. Patient satisfaction and mechanical complications recorded.

**Results:** Screw loosening was much higher in four implant-supported bar structures than two implant-supported bar structures. In one case four implant-supported bar fractured after 8 months loading because of bruxism. The patient satisfaction was higher in four implant-supported bar structures.

**Conclusion:** Both bar designs provide acceptable functional comfort. The patient satisfaction respective with retention was higher in four implant-supported bar structures. High retention and stability appear to be an important factor for the patients' satisfaction and oral comfort. Rigid retention results in a higher force impact and appears to evoke the need for the retightening of occlusal screws, resulting in more maintenance service.

## Surgical repair of sinus membrane perforations

**Presenter: Sezen C**

*Istanbul University, Istanbul, Turkey*

**Co-authors: Sezen C, Ersanli S, Bolukbasi N**

*Department of Oral Implantology, Faculty of Dentistry, Istanbul University, Istanbul, Turkey*

**Background and aim:** The most frequent intraoperative complication with sinus elevation is perforation of sinus membrane. New techniques are improved for the management of large perforations of the Schneiderian membrane. Choukroun's Platelet Rich Fibrin (PRF) is one of the new developed techniques. PRF is second generation platelet concentrate and contains many growth factors which are obtained in a simple manner from patient's own blood. The treatment of sinus perforations with PRF is a simple, economical procedure.

**Materials and methods:** Forty-six year old female patient received bimaxillary sinus lifting surgery. The sinus augmentation procedure followed the technique described by Tatum. Prophylactic oral antibiotics (Amoxicilin 1000mg) and anti-inflammatory drugs (Meloxicam 15 mg) were used half an hour before the procedure and continued for 7 days. Although care was taken not to perforate sinus membrane perforation occurred in both sides. One perforation side was sealed with only PRF. The other side was sealed with PRF and also bone graft (Bio-Oss, Geistlich, Germany) was applied. After 8 months, only PRF applied side is treated with PRF and bone graft (Bio-Oss, Geistlich, Germany) with second surgery.

**Results:** Both sites were rehabilitated successfully with implant-supported prosthesis.

**Conclusion:** Sinus perforations treated with Bio-Oss and PRF at the same time allows for shorter waiting time. Growth factors inherited by PRF may be a supporting factor for complication free healing. Further investigation may prove the clinical effectiveness of these techniques.

## Implant fracture management: a 14 years clinical observation

**Presenter: Bischof M**

*Ardentis Clinique Dentaire, Lausanne, Switzerland*

**Co-authors: Bischof M<sup>1</sup>, Szmukler-Moncler S<sup>2</sup>, Nedir R<sup>3</sup>**

<sup>1</sup>*Ardentis Clinique Dentaire, Lausanne, Switzerland,* <sup>2</sup>*Department of Odontology, Galeazzi Orthopaedic Institute, Milano, Italy,*

<sup>3</sup>*Department of Stomatology and Oral Surgery, University of Geneva, Geneva, Switzerland*

**Background and aim:** Implant fracture is a relatively rare occurrence; however, it is (1) potentially difficult to resolve, (2) time consuming for patients and clinicians alike. This report documents the outcome of poor diagnosis and underestimation of risk factors and the consequences on implant and prosthesis prognosis.

**Materials and methods:** In 1991, a male 54-year-old patient partially edentulous (remaining teeth = 11, 21 and 27) received

two implants in site 13 and 24 to retain a removable partial denture (RPD). Both were Ø 4.1 × 12 mm hollow screw ITI Bonefit Straumann implants and supported a ball anchored RPD. In 1995, both implants fractured at the first row of hollows and the osseointegrated embedded portions were left *in situ*. Subsequently, two implants were added mesially and distally to each fractured implant. To retain the RPD, all four implants were equipped with magnets. From 1996 till 2006, all magnets have been replaced five times because of wear and fracture; the RPD was also relined. Owing to the high frequency of complications and because of the subsequent failure of the remaining teeth, additional implants were placed after a bone grafting procedure. Relying on 10 implants, a fixed complete prosthesis was cemented in 2008.

**Results:** Before implant treatment the patient presented a history of parafunctional habits materialized by multiple relinings and fractures of the existing RPD. Hypertrophic masticatory muscles were also, and still are, patent. After 4 and 4.5 years of function, both implants fractured. The radiographs showed a limited bone loss on the implants attaining the first row of holes of the implant. This bone loss may have been secondary to occlusal overloading because no signs of periodontitis could be identified. On radiographic controls, the implants' fractured portions were progressively surrounded by bone. After 14 years, they remain encapsulated and asymptomatic.

**Conclusion:** On retrospect, this patient presented many risk factors that are now recognized as potentially leading to implant fracture. Considerable time and cost were wasted and would have been avoided, if all the risk factors had been identified and taken into account. Nonetheless, this case shows that fractured implants do not need to be explanted if they do not jeopardize an ensuing treatment. A timely more complex treatment may have avoided all these complication and would have led to increased satisfaction of the patient and less risk to the implants and the prosthesis.

## Implant supported prosthetic rehabilitation of the patient following osteomyelitis treatment. A case report

**Presenter: Bacaksiz II**

*Hacettepe University, Faculty of Dentistry, Ankara, Turkey*

**Co-authors: Tasar F<sup>1</sup>, Hersek N<sup>2</sup>, Yildirim B<sup>1</sup>, Sezgin O<sup>1</sup>, Bacaksiz II<sup>2</sup>**

<sup>1</sup>*Department of Oral And Maxillofacial Surgery, Hacettepe University Faculty of Dentistry, Ankara, Turkey,* <sup>2</sup>*Department of Prosthetic Dentistry, Hacettepe University Faculty of Dentistry, Ankara, Turkey*

**Background and aim:** Osteomyelitis of the mandible is usually odontogenic or traumatic in origin and is a mixed infection of oral bacteria that involves all layers of bone in which widespread necrosis occurs. Patients with osteomyelitis often have a systematic disease like osteopetrosis, pyknodysostosis, osteoporosis or the use of medicines like bisphosphonates. Rarely, osteomyelitis occurs after a tooth extraction, resulting from a virulent, bacterial and resistant infection. Extraction socket no

longer provides adequate drainage and Infection spreads along the marrow cavity causing osteomyelitis to be widespread.

**Materials and methods:** In the presented case, a 29-year-old female patient referred to Oral and Maxillofacial Surgery clinic with a complaint of pain. She was in good health. In clinical examination pus drainage between teeth 41 and 42 were observed. There was a swelling at posterior edentulous molar area. As a consequence of clinical and microbiological findings pointing out osteomyelitis, surgery was performed under general anesthesia. The patient was hospitalized and received antibiotic treatment intravenously for 2 weeks in the Department of Infectious Diseases. Histopathological examination was reported as 'osteomyelitis'. After 2 year follow-up, three Implants (Astra Tech AB, Molndal, Sweden) were placed to the effected side and were loaded after 3 months with a metal-supported porcelain restoration.

**Results:** Twelve months after loading, there was no clinical and radiological bone loss around the implants.

**Conclusion:** With the proper surgical and medical treatments, implants can be placed to the formerly infected mandible after the treatment of osteomyelitis just as in healthy bone.

#### 223 Poster – Topic Technical and Biological Complications

### Universal locator® vs. classical ball attachment

**Presenter:** Altuna P

*Universitat Internacional de Catalunya, Barcelona, Spain*

**Co-authors:** Altuna P, Cabratosa J, Barroso A

*Universitat Internacional de Catalunya, Barcelona, Spain*

**Background and aim:** The first choice of treatment in mandibular total edentulism is an overdenture supported by two implants and a retaining system. A splinting bar-clip or a ball attachment were used traditionally with a high success rate. These solutions sometimes have a time consuming maintenance. Technically, these systems have several disadvantages that can be easily solved when using the Locator® system. The aim of our presentation is to illustrate with a case series why this system is becoming so popular.

**Materials and methods:** With a series of case presentations we analyze the advantages and disadvantages of traditionally used bar-clip or ball attachments compared with a very versatile unsplinted-implant attachment widely used nowadays. All patients were treated with an overdenture retained with two implants. We include clinical cases with several types of retention systems.

**Results:** Our results showed a very low rate of technical complications and were easily solved compared with the older type of attachment.

**Conclusion:** The Locator® system provides with a good alternative to the bar or ball attachment. There is a Locator® abutment available for almost all dental implant systems and it is probably one of the most universal connection systems after de Brånemark external hexagon. It seems that the Locator® abutment performs in a very predictable way and with an easy maintenance, but further clinical trials are needed to evaluate its long-term complication and success rates.

#### 224 Poster – Topic Technical and Biological Complications

### Oral implant survival in penicillin allergic patients

**Presenter:** Fortes V

*Clinica Aparicio, Barcelona, Spain*

**Co-authors:** Fortes V, Codesal M, Gorostegui M, Surette M, Muela R, Pascual A, Manresa C, Barluenga N, Franch M, Aparicio C

*Clinica Aparicio, Barcelona, Spain*

**Background and aim:** No reference about antibiotic allergies as a risk factor on implant success was found. The aim of this retrospective study was to evaluate the success of implants placed in patients allergic to antibiotics compared to non-allergic patients.

**Materials and methods:** Three thousand two hundred and ninety-eight consecutive patients that underwent implant surgery from 1987 to 2007 were included. Out of them 102 (38 males and 64 females) were considered as allergic to antibiotic (91 to penicillin). As potential risk factors we considered tobacco, gender, moment of loading, age and the surgical technique. A total of 590 implants were placed in the allergic patients. Out of them 16 were smokers. 268 implants were immediately loaded and 322 received delayed load. The survival time was used for statistical analysis.

**Results:** Twenty-six patients showed implant failure (seven smokers). A total of 55 implants failed on these 26 patients (17 immediately loaded and 38 delayed loaded). The implant survival rate 6 months after placement was 90% on the allergic patients and 98% on non allergic patients ( $P$ -value < 0.05).

**Conclusion:** For the short-term implants success, the penicillin allergy must be considered as a risk factor. Tobacco and moment of loading are the most influence risk factors in allergic patients.

#### 225 Poster – Topic Technical and Biological Complications

### Early oral implant failures: etiologic factors (a retrospective study)

**Presenter:** Kessaris P

*Athens Medical Center, Kifissia, Greece*

**Co-authors:** Kessaris P, Kostas H, Nikos L

*Athens Medical Center, Athens, Greece*

**Background and aim:** To evaluate, from personal experience, the association between the failure rate of dental implants and the several different major etiologic factors for their loss.

**Materials and methods:** Failures were chronologically divided into those occurring before, at and after abutment connection. The clinical conditions varied from osteomyelitis to totally asymptomatic but mobile implants. Three hundred and twenty-eight oral titanium implants were placed in the jaws of 101 patients (45 males and 56 females) of which 173 were Ossfit – Anthogyr (BCP surface) and 155 were Straumann (SLA surface). Their length was between 8 and 14 mm and the diameter between 3.3 and 4.2 mm. Of those 126 implants were maxillary and 202 implants were mandibular. The postoperative healing period was 3–6 months before loading. Beta-lactams were given mainly for antibiotic prophylaxis. Hard and soft tissue handling was performed in an atraumatic manner and the appropriate

initial stability was achieved. The following 3 week postop period was univentful. Non-smoking protocol was followed.

**Results:** Three maxillary fixtures (3%) and 12 mandibular fixtures (6%) failed to osseointegrate. Seven of them in males and eight of them in females. The overall success rate was 95.5%. All implants with mobility (with or without pain symptoms during percussion) were removed. Also those that performed advanced bone resorption secondary to infection (even with Ostel measurement > 60 and without mobility).

**Conclusion:** Clinical and radiographic findings indicated that four major etiologies might have implicated in the failure processes: infection, impaired healing ability of the host bone site, overload and anatomic conditions. We think that patient compliance is another major factor regarding smoking habits and oral hygiene. The treatment of the failed implants will be described and their conditions will be discussed as some of them were replaced with new ones and finally loaded successfully, but the rest were 'placed to sleep' or replaced by conventional prostheses.

226	Poster – Topic Technical and Biological Complications
-----	---

### Regeneration of the periodontium on aceller matrix using detergent method at biodental allo-implant

**Presenter:** Inoue M

*Inoue Masatoshi Dental Office /Institute for Frontier Medical Sciences, Kyoto University, Kyoto, Japan*

**Co-authors:** Inoue M, Nakamura T, Segawa A, Hatayama T

*Institute for Frontier Medical Sciences, Kyoto University, Kyoto, Japan*

**Background and aim:** A variety of implants are now clinically and widely used at teeth defects. There remain, however, a lot of unsolved problems on the implants and most of them are caused by the lack of the periodontium on the implants.

**Aim:** We tried to regenerate periodontium from the allograft of tooth.

**Materials and methods:** We pull out the tooth of white New Zealand rabbits and beagle dogs and treated them in the two ways: freeze method and detergent method. Cell components were intended to be removed from the periodontium. Histopathologically, light microscopic analysis was employed to evaluate degree of cell extraction. As the *in vivo* test, we implanted the extracted allo-tooth treated with the detergent method and evaluate them clinically effectiveness using rabbits and dogs model. Light microscopic analysis was employed to evaluate allo-tooth treated with the method histopathologically.

**Results:** In freeze method, most cell of the periodontium could be removed. In detergent method, all the cells were perfectly removed in our protocol. The degree of the damage of periodontium matrix by freeze method was stronger than that by detergent method. Consequently, the detergent method appears to be useful for preparing acellular matrix from the periodontium. In the rabbit model, the periodontium regenerated perfectly on acellular matrix. In the dogs' model, the implanted tooth roots were almost resorped, however, the gingival connective tissue fibers attached to the implants were generally oriented perpendicular to the root surface and the regeneration of cementum was observed there.

**Conclusion:** Detergent method was useful was promising for the regeneration of the periodontium on teeth allograft.

227	Poster – Topic Technical and Biological Complications
-----	---

### Immediate loading implant-supported rehabilitation after adenoid cystic carcinoma treatment: the challenge of a particular clinical case

**Presenter:** Dias R

*Faculty of Medicine of University of Coimbra, Coimbra, Portugal*

**Co-authors:** Dias R, Tondela J, Rocha S, Nicolau P, Guerra F

*Department of Dentistry, Faculty of Medicine of University of Coimbra, Coimbra, Portugal*

**Background and aim:** The adenoid cystic carcinoma represents 10% of the malignant neoplasm of the head and neck, with incidence in any salivary gland, age and sex gender. Oral rehabilitation of patients after primary treatment is a challenge in order to transpose the biologic, morphologic, functional and prosthetic limitations identified. With this work we used an implant-supported option for rehabilitating a patient after left-sublingual adenoid cystic carcinoma treatment.

**Materials and methods:** Surgery recession and radiotherapy produced anatomic, morphologic and functional bone and soft tissues modifications that explained the difficulty in adaptation to removable prosthesis and in the patient quality of life. A partial edentulous patient of the female gender was initially treated in the Faculty Clinic of our University. She was rehabilitated with a maxillar and mandibular partial removable prosthesis. However, she demonstrated incapacity to adaptation to the mandibular prosthesis because of mechanical trauma. To transpose these limitations and increase the predictability of our prosthetic rehabilitation we made a mandibular diagnostic wax-up, a surgical-guide and a provisional prosthesis after determination of the 'neutral-zone'. The final prosthetic option was an immediate loading implant-supported fixed prosthesis screwed over four AstraTech® Osseospeed implants localized in the positions 46,44,42 and 34. In position 42 installed a immediate post-extraction implant.

**Results:** Because of previous bone osteotomy the platform of implant 34 occupied a lower level comparatively to the others. To compensate vertically this mechanical limitation we adapted a prosthetic abutment of 8 mm of height keeping the rest of the prosthetic structure (bridge) at the same level. This prosthetic option allowed reestablishing the function immediately after surgery. The bioactive surface of AstraTech® Osseospeed implants contributed for the successful osteointegration in the bone irradiated 19 months before implant surgery. The fixed prosthetic solution contributed to a steady occlusal and functional result transposing the initial difficulties and problems related by the patient, principally the vertical/horizontal instability and mechanical trauma.

**Conclusion:** In this particular case our goal was transpose the limitations of the primary treatment. The fixed implant-supported rehabilitation permitted an acceptable/integrated

biological and functional result and as a consequence a satisfied and more self-confidence patient.

228 | Poster – Topic Technical and Biological Complications

### Alveolar distraction reconstruction of an extensive alveolar bone defect as a consequence of a car accident: case report

**Presenter: Rásonyi-Kovács O**

*Semmelweis University, Budapest, Hungary*

**Co-authors: Rásonyi-Kovács O, Joób-Fancsaly Á, Bogdán S**

*Semmelweis University, Budapest, Hungary*

**Background and aim:** A 15-year-old female patient suffered a pan facial fracture in a car accident. The trauma caused a large bone defect of the alveolar process in the upper front and premolar region. The prosthetic rehabilitation with fixed restoration in the case of this bone defect indicated bone grafting and implant placement.

**Materials and methods:** One year after the trauma the reconstruction of the traumatised area was done with distraction osteogenesis (after 1 week latency period, 0.5 mm distraction rate per day). The height of the osteotomy was determined to result in a minimal extension of 8 mm of the bone in the oro-vestibular dimension. After the end of distraction, the patient did not return to the Department for 2 years. On control a CBCT scan was made, and it was seen that the reconstructed alveolar process lost a large amount of bone in the oro-vestibular dimension, but remained sufficient in the vertical dimension.

**Results:** Because of the atrophy implant placement could not be performed, and a lateral augmentation with a calvaria graft had to be done. After this, having achieved a sufficient bone quantity, implants were placed the Nobel Guide technique.

**Conclusion:** It can be concluded that a large amount of bone can be generated by distraction osteogenesis in the area of alveolar process as well. However, the atrophy of this bone without loading goes faster, because of the immaturity of the bone, than the atrophy of a physiologically edentulous alveolar process.

229 | Poster – Topic Technical and Biological Complications

### Patients with dental implants poorly adapt the jaw muscle activity to food hardness during chewing

**Presenter: Grigoriadis A**

*Karolinska Institutet, Huddinge, Sweden*

**Co-authors: Grigoriadis A, Trulsson M**

*Karolinska Institutet, Huddinge, Sweden*

**Background and aim:** During mastication sensory signals from the oral cavity adapt the motor output to the mechanical properties of food. Since the periodontal mechanoreceptors encode detailed information about tooth loads, it is likely that their inputs contribute to this regulation. The aim of this work was to study if subjects that lack periodontal receptors, i.e., subjects with implant-supported bridges, can adapt their jaw muscle activity to food hardness during chewing.

**Materials and methods:** Fourteen subjects with implant-supported bridges in both jaws and 13 age and gender-matched subjects with natural dentition were included in this study. The muscular activity of right and left masseter and temporal muscles was recorded by electromyography (EMG) using surface electrodes. Each subject was instructed to chew and swallow four soft and four hard gelatine-based visco-elastic model foods in a semi-random order.

**Results:** No difference could be seen between the groups regarding number of chewing cycles or duration of mastication. The subjects in both groups used more muscle activity in the beginning of the chewing sequence when chewing hard food compared to soft food. However, only subjects with a natural dentition showed a significant decrease in muscle activity between the beginning and the end of the chewing sequence.

**Conclusion:** Subjects with implants supported bridges cannot regulate to food hardness to the same extent as those with natural teeth. The present results suggest that periodontal receptors are of importance for the adaptation of muscle activity during chewing and the loss of these sensors degrade the control of the force development.

**Acknowledgement:** This study was supported by the Swedish Research Council and Swedish Dental Society.

230 | Poster – Topic Technical and Biological Complications

### The microbiological RT-PCR analysis around the integrated and periimplantitis-not integrated zirconia and titanium implants

**Presenter: Wojtowicz A**

*WUM-OSIS, Warsaw, Poland*

**Co-authors: Wojtowicz A, Wandzel-Sobczak B, Struzycka I, Krzywicki D**

*Warsaw Medical University, Warsaw, Poland*

**Background and aim:** The characteristics of zirconia – ‘white’ implants are different than titanium. Both has a strength and weakness. The survival rates are higher in titanium implants, when compare with zirconia implants, but long-term esthetic effect specially in esthetic zone are better in zirconia. It is known fact, that “oral” bacteria ‘doesn’t like’ zircon surface. The aim of this study was evaluate and compare the clinical analysis of osseointegration and quality and quantity of nine species of most frequently bacteria pathogenic in periodontitis, using Real Time PCR methodology for nine species: *Actinobacillus actinomycetemcomitans*, *Tannerella forsythensis*, *Campylobacter rectus* and others.

**Materials and methods:** Evaluated materials (smears) were taken from the surface of the implants in 4 groups:

- integrated titanium implants 3 months after surgery,
- integrated zirconia implants 3 months after surgery,
- non- integrated titanium implants,
- non-integrated zirconia implants.

Thirty Ziterion one-piece titanium (10) and zirconia (20) implants were used for this study in seven patients (two to three titanium on one side of jaw and two to three zirconia on the other side in the same patient). Zirconia implants were ‘covered’ using

temporary, acrylic templates, according the procedure (no immediate loading), similar to titanium implants.

**Results:** RT-PCR analysis showed lower quality and quantity of bacteria around the zirconia in comparison with titanium. The survival rate in titanium implants was higher than zirconia: one titanium implant lost, four zirconia implant lost. The periosteal rate was also different in osseointegrated as well non-integrated titanium and zirconia implants.

**Conclusion:** It seems that the Branemark- osseointegration process is different for titanium and zirconia. No clinical and microbiological symptoms of periimplantitis were found in non-integrated zirconia in comparison with titanium. Zirconia one piece implants need special, critical procedure, after installation when compared with titanium implants, anti-periimplantitis pharmacotherapy it seems not necessary when no zirconia implants osseointegration.

231	Poster – Topic Technical and Biological Complications
-----	---

**Retreatment of maxillary atrophy with four zygomatic implants associated to the immediate loading after lack of stability and displacement of the implant in the maxillary sinus**

**Presenter: Kuabara M**

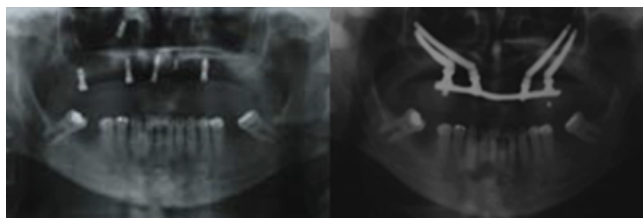
*Imppar Odontology, Londrina, Brazil*

**Co-authors:** Kuabara M<sup>1</sup>, Ferreira E<sup>2</sup>, Paz L<sup>2</sup>

<sup>1</sup>Universidade Sagrado Coração USC, Bauru, Brazil, <sup>2</sup>Imppar Odontology, Londrina, Brazil

**Background and aim:** The zygomatic implant placement is an alternative to solve the complications when there is lack of bone tissue and implants in the rehabilitation of atrophic maxilla. The purpose of this study is to report a solution of the retreatment of maxilla atrophic using four zygomatic fixtures with a system of immediate loading through planning prosthetic reverse after failure the rehabilitation with bone grafting and installation of conventional implants.

**Materials and methods:**



In the clinical examination, the patient showed a total conventional up prosthesis that was installed in substitution of the upper protocol lost. After removal of the prosthesis was noted the bad positioning of some implants. At the radiographic examination, six in maxilla implants were viewed, including one found itself inside of the right maxillary sinus and the implant the region of 21 there was fractured. The other bone implants had resorptions around their third cervical portion justifying the mobility reported by the patient. There has been removal of implants in conventional maxilla and permanence of the use of conventional prosthesis total during the period of

tissue repair. Two months after by the using of reverse planning the patient had a fixed maxillary prosthesis with immediate loading supported by four zygomatic implants.

**Results:** One year after rehabilitation were not highlighted painful symptomatology, instability of implants and processes of bone resorption.

**Conclusion:** The technique proposed the use of zygoma as a place of anchoring of two implants bilaterally, coupled with bone quality, primary stability and polygon set up to ensure effective treatment, benefiting the patient, by the least cost, agility and rehabilitation.

232	Poster – Topic Technical and Biological Complications
-----	---

**Neuromuscular approach for implant-supported fixed prosthesis: a retrospective clinical study**

**Presenter: Fukuoka Y**

*Nankai University, College of Medicine, Heiping, China*  
**Co-authors:** Fukuoka Y<sup>1</sup>, Chang WG<sup>2</sup>, Cho SC<sup>2</sup>

<sup>1</sup>Nankai University, Heiping, China, <sup>2</sup>New York University, New York, NY, USA

**Background and aim:** Attention to occlusion is the critical element for successful and long-term implant treatment. A lot of literatures have reported that the clinical success and longevity of dental implants can be achieved by biomechanically controlled occlusion. The difference between natural tooth and Implant is with or without periodontal ligament. Inoue and colleagues measured oral tactile sensibility by loading gradient axially force, the detection threshold was 1.5–5 g on natural teeth and under anesthesia it become worse. But on implant the detection threshold of minimal pressure was 50–500 g but no difference under anesthesia. There is remarkable study documented the fact that in the bone anchored implant the sensory receptor is not bone but neuromuscular systems including masticatory muscle. The aim of study is that the neuromuscular concept is effective for the implant-supported restoration.

**Materials and methods:** In this study, 46 patients were consecutively treated with implant-supported fixed prostheses. In total, 221 implants were placed. And patients have defect more than Eichner's classification B2. Among the patients of test group 13 patients have parafunction and among the patients of control group 7 patients have parafunction. The mean loading period was 63.9 months after superstructures were placed. The neuromuscular evaluation was performed by using K7 Evaluation unit. The K7 Evaluation Unit is composed with CMS (computerized mandibular scanning), EMG (surface electromyography) and TENS (ultra low frequency transcutaneous electroneural stimulation myomonitor). The treatment was performed according to the neuromuscular treatment protocol. The mean observation period was 63.9 months after loading. Inclusion criteria is more than B2 Eichner's classification. The survival rate is evaluated statistically by Modified Fisher's analysis.

**Results:** The distribution of defect pattern in this study was showed 50% patients are collapse of occlusion when implants are placed. Few complications of superstructure and implants were observed in time of examination. The survival rate was

99.39% in test group while that of the control group was 90.70%. The survival rate showed significant difference by Fisher's analysis between test and control groups. The survival rate of group with parafunction is higher different between test and control group.

**Conclusion:** The implant restoration utilized with NM concept showed higher implant survival rate than other technique in this retrospective study. Especially in the patients with parafunction the survival rate shows a higher difference. It suggested that NM concept is effective for the patient who lost posterior support.

#### 233 Poster – Topic Tissue Augmentation and Tissue Engineering

##### Evaluation of peri-implant crevicular fluid prostaglandin E<sub>2</sub> levels in augmented extraction sockets

**Presenter: Ayhan E**

*Primadent Dental Clinic, Ankara, Turkey*

**Co-authors: Ayhan E<sup>1</sup>, Tüter G<sup>2</sup>, Parlar A<sup>2</sup>, Kurtiş B<sup>2</sup>**

<sup>1</sup>Primadent Dental Clinic, Ankara, Turkey, <sup>2</sup>University of Gazi, Ankara, Turkey

**Background and aim:** The purpose of this study was to evaluate the healing, stability and peri-implant Prostaglandin E<sub>2</sub> levels in extraction sockets filled with Emdogain<sup>®</sup> and Bio-Oss<sup>®</sup> Collagen.

**Materials and methods:** Ten patients having symmetrical teeth in contralateral quadrants of the same jaw condemned for extraction were participated in our study. There were two extraction sockets in each patient/jaw. After the initial periodontal therapy, following tooth extraction, a total of 20 sockets in 10 patients were randomly divided into two treatment groups as 10 extraction sockets were filled with Bio-Oss. Ten extraction sockets were filled with Emdogain. Primary soft tissue closure of the grafted site were achieved by using free mucosal graft harvested by a punch technique. After 3 months of healing the sites were reentered and implant placements were performed. The numeric stability values of implants were evaluated by resonance frequency analysis (RFA) at the first and the third months. Clinical parameters were recorded. Peri-implant crevicular fluid (PICF) was collected after the first and the third months of implant surgery. Assays for PICF were carried out by ELISA.

**Results:** All experimental sites healed uneventfully. In all cases, the grafted sites were able to support implant placement in second surgery. While there were no statistically differences between the first and the third months peri-implant GI scores in Bio-Oss<sup>®</sup> Collagen groups, there was statistically significant decrease in GI scores at the third month in Emdogain<sup>®</sup> groups. When we compare PGE<sub>2</sub> levels between Emdogain<sup>®</sup> and Bio-Oss<sup>®</sup> Collagen groups at first and third months, statistically decreased PICF PGE<sub>2</sub> levels were detected in Emdogain<sup>®</sup> group ( $P=0.011$ ). RFA values were statistically higher for implants placed in Emdogain<sup>®</sup> sites at the third month than the first month while no significant differences were seen in RFA values

for implants placed in Bio-Oss<sup>®</sup> Collagen sites at the first and third month.

**Conclusion:** Our results suggested that Emdogain<sup>®</sup> may provide additional benefits during the early wound healing by reducing the GI scores and PICF PGE<sub>2</sub> levels in osseointegration process. Further studies with greater numbers of patients are needed to evaluate the effect of these materials on osseointegration process.

#### 234 Poster – Topic Tissue Augmentation and Tissue Engineering

##### Characterization and possibility of bone regeneration for dental implant using dental pulp stem cells (DPSCs) and stem cells from human exfoliated deciduous teeth (SHED) as novel stem cell origin

**Presenter: Nakamura S**

*Nagoya University Graduate School of Medicine, Nagoya, Japan*

**Co-authors: Nakamura S<sup>1</sup>, Yamada Y<sup>2</sup>, Katagiri W<sup>1</sup>, Sugito T<sup>1</sup>, Ito K<sup>1</sup>, Ueda M<sup>1</sup>**

<sup>1</sup>Department of Oral and Maxillofacial Surgery, Nagoya University Graduate School of Medicine, Nagoya, Japan, <sup>2</sup>Center for Genetic and Regenerative Medicine, Nagoya University School of Medicine, Nagoya, Japan

**Background and aim:** Mesenchymal stem cells (MSCs) have been used for clinical application, including bone augmentation, in tissue engineering and regenerative medicine. To date, the most common source of MSCs has been bone marrow. However, the bone marrow aspirate is an invasive and painful procedure for the donor. Thus, identification and characterization of alternative sources of MSCs are of great importance. Recently, dental pulp stem cells (DPSCs) were isolated from pulp and expected to be useful for bone and dentin/pulp formation. In this study, we focused on the characterization and possibility of bone regeneration for dental implant using DPSCs and stem cells from human exfoliated deciduous teeth (SHED) compared to MSCs.

**Materials and methods:** At first we have compared 'stemness' such as multipotentiality, proliferation rate, and surface epitope of stem cell markers of DPSCs, SHED and MSCs. And osteogenic differentiation capacity was evaluated by analyzing the expression of mineralization-related genes using real-time PCR. In addition, gene expression profiles of DPSCs and SHED were analyzed using DNA microarray (total 41,078 genes) and expression patterns of selected genes were validated by real-time PCR.

**Results:** DPSCs as well as SHED possessed multipotentiality and expressed mesenchymal lineage markers (CD13, CD29, CD44, CD73, and CD105) that resembled those of MSCs. The proliferation rate of SHED showed significantly higher than that of DPSCs and MSCs ( $P<0.05$ ). In osteogenic differentiation assay, expression of mineralization-related genes was higher in SHED than that in DPSCs suggesting potential of effective bone formation. Comparison of gene expression profiles indicated that there were 4386 genes with changed expression between DPSCs and SHED by 2.0-fold or more. Higher expression in SHED was observed for genes that participate in pathways related to extracellular matrix and cell proliferation.

**Conclusion:** These results suggested that SHED possesses 'stemness' and is able to provide enough number of cells for clinical application easily because of high proliferation capacity. Moreover, SHED that is generally discarded as medical waste and can be obtained without any invasion could be possibilities alternative cell source for bone formation for dental implant.

235 | Poster – Topic Tissue Augmentation and Tissue Engineering

The significance of keratinized mucosa on the maintenance of dental implants before and after the delivery of autogenous gingival grafts

**Presenter:** Basegmez C

*Istanbul University Faculty of Dentistry, Istanbul, Turkey*

**Co-authors:** Basegmez C, Ersanli S, Yalcin S, Ozdemir T

*Istanbul University Oral Implantology, Istanbul, Turkey*

**Background and aim:** Despite strong opinions and beliefs about the benefits of keratinized mucosa, debate continues about the necessity for an attached keratinized tissue zone around implants.

**Materials and methods:** Forty-four individuals who were treated previously with two or more dental implants and overdentures were taken into consideration. The patients were diagnosed with inadequate keratinized tissue around their implants ( $< 2$  mm) at the maintenance visit and 67. Plaque and gingival indices (PI, GI), probing depth (PD) and the width of keratinized mucosa (KM) were recorded initially, at the first, third and sixth months following the delivery of autogenous gingival grafts (AGG).

**Results:** At the first, third and sixth months following the delivery of AGGs, PI and GI scores were significantly lower ( $P < 0.01$ ). PD values were lower at the third and sixth months according to baseline ( $P < 0.05$ ). The width of KM were significantly greater following the delivery of FGGs at the first, third and sixth months ( $P < 0.05$ ). Furthermore, the width of KM correlated significantly with all clinical parameters ( $P < 0.05$ ). A significant correlation revealed that the absence of an adequate zone of keratinized mucosa is associated with higher plaque accumulation and gingival inflammation also causing pocket deepening.

**Conclusion:** Within the limitations of this study it may be suggested that an adequate keratinized soft tissue zone around implants, which is enhanced by AGGs, facilitates cleaning procedures for the individual, reduces plaque accumulation and prevents gingival inflammation in return.

236 | Poster – Topic Tissue Augmentation and Tissue Engineering

Osteotome sinus floor elevation without grafting material: a 5-year follow-up

**Presenter:** Nedir R

*Swiss Dental Clinics Group, Vevey, Switzerland*

**Co-authors:** Nedir R<sup>1</sup>, Vazquez L<sup>1</sup>, Nurdin N<sup>2</sup>, Szmukler-Moncler S<sup>3</sup>, Bernard JP<sup>1</sup>, Bischof M<sup>2</sup>

<sup>1</sup>*Department of Stomatology and Oral Surgery, School of Dental Medicine, University of Geneva, Geneva, Switzerland,* <sup>2</sup>*Swiss Dental Clinics Group, Ardentis Clinique Dentaire, Vevey, Switzerland,*

<sup>3</sup>*Department of Odontology, Galeazzi Orthopaedic Institute, University of Milano, Milan, Italy*

**Background and aim:** The long-term outcome of implants placed in the atrophic maxilla without grafting material has not been documented yet. In a previous study (Nedir et al. COIR 2006), the 1-year predictability of an osteotome sinus floor elevation (OSFE) procedure without grafting material was evaluated in maxillae with a limited mean residual bone height (RBH) of  $5.4 \pm 2.3$  mm. Mean endo-sinus bone gain was  $2.5 \pm 1.2$  mm and crestal bone loss (CBL) was  $1.2 \pm 0.7$  mm. On the 3-year mid-term (Nedir et al. COIR 2009, in press), the endo-sinus bone gain increased slightly to  $3.1 \pm 1.5$  mm and CBL was limited to  $0.9 \pm 0.7$  mm. The present paper reports the 5-year long-term results.

**Materials and methods:** Twenty-five ITI-SLA implants (length  $\leq 10$  mm) were placed in 17 patients to rehabilitate 16 molar and nine premolar maxillary sites with four single crowns and 13 fixed partial dentures. At the 5-year control, endo-sinus bone gain, CBL and protrusion length were measured on apical radiographs.

**Results:** One patient with one implant was lost during follow-up and was dropped-out of the study. Compared to the post-operative situation, the mean CBL was  $0.8 \pm 0.8$  mm. All implants gained endo-sinus bone; the mean gained bone was  $3.2 \pm 1.3$  mm (range 1.1–5.8 mm). Six implants have gained  $> 4$  mm of apical bone. The protrusion length into the sinus decreased from  $4.9 \pm 1.9$  mm at surgery to  $1.5 \pm 0.9$  mm after 5 years. Since the 1-year control, an additional bone gain was measured for 20 implants; bone gain was stable for 3 implants while one showed a decrease of 0.3 mm.

**Conclusion:** This is the first long-term report that addresses the capacity of forming bone beneath the Schneiderian membrane when it is lifted beyond the limits of the sinus floor without addition of any grafting material. During this 5-year survey with controls at 1, 3 and 5 years, implants fulfilled the clinical and radiographic criteria of success proposed by Albrektsson et al. (1986). The limited CBL measured at the 1-year control has stabilized over the 5 years. The augmented area did not shrink following the 1-year control; rather, bone gain tended to increase with time. With a success rate of 100%, this study confirms the long-term predictability of the OSFE technique. In addition, it corroborates that bone grafts or grafting materials are not a prerequisite for bone formation when the initial RBH of the maxilla is on average 5 mm.



## Bone induction by block or particulated type calcium phosphate carrier system coated by *E. coli* - expressed rhBMP-2 in a rat calvarial defect

**Presenter:** Kim JW

College of Dentistry, Yonsei University, Seoul, Korea

Co-authors: Kim JW<sup>1</sup>, Choi KH<sup>2</sup>, Yun JH<sup>3</sup>, Jung UW<sup>1</sup>, Kim CS<sup>1</sup>, Choi SH<sup>1</sup>, Cho KS<sup>1</sup>

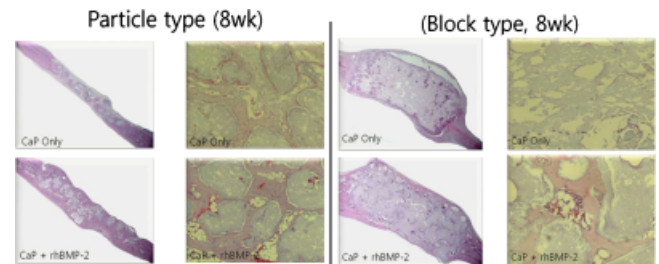
<sup>1</sup>College of Dentistry, Yonsei University, Seoul, Korea, <sup>2</sup>Cowellmedi co., Ltd. Busan, Korea, <sup>3</sup>College of Medicine, Kwandong University, Seoul, Korea

**Background and aim:** High cost of recombinant human bone morphogenetic protein-2 (rhBMP-2) and lack of proper carrier system still remain as limitations for clinical use, although many studies have reported that rhBMP-2 could induce significant bone regeneration. In order to overcome these limitations, through many previous studies, it has been demonstrated that rhBMP-2 expressed in prokaryotic system has been a good alternative to rhBMP-2 expressed in eukaryotic mammalian cells economically. The aim of present study was to investigate bone formation of *Escherichia coli*-expressed rhBMP-2 (ErhBMP-2) coated calcium phosphate carrier system in a rat calvarial defect.

**Materials and methods:** ErhBMP-2-coated calcium phosphate blocks and particles were prepared by freeze-dried coating method. Circular, transosseous defect, 8-mm in diameter critical-size calvarial defects were prepared using a trephine bur in 80 male Sprague-Dawley rats. The animals were divided into five groups of 16 animals each and allowed to heal for 2 weeks (eight rats) or 8 weeks (eight rats). Each group received one of the following: (1) sham surgery, (2) calcium phosphate particle (CPP) alone, (3) calcium phosphate block (CPB) alone, (4) 1 mg/g ErhBMP-2-coated CPP, 5) 1 mg/g ErhBMP-2-coated CPB. Following 2- or 8-weeks healing interval, the specimens were obtained. Histologic and histometric analysis were performed regarding the new bone area and defect closure.

**Results:** Wound healing was generally uneventful, and material exposure or other complications of the surgical site were not observed. The new bone area/augmented area at 2 weeks after surgery in CPP alone, CPB alone, ErhBMP-2 coated CPP and ErhBMP-2-coated CPB group was 33%, 12%, 71%, 61%. At 8 weeks after surgery, the corresponding value was 24%, 15%, 65%, 39%. CPP group with or without ErhBMP-2 showed significantly greater bone density at 2 and 8 weeks when compared with the sham surgery and CPB group with or without ErhBMP-2 ( $P < 0.01$ ). In CPB group with or without ErhBMP-2 histologically, bone regeneration was not induced inside of the block. The augmented, new bone area, defect closure of the experimental group was significantly larger than that of the carrier alone and negative control group ( $P < 0.01$ ). New bone area/augmented area

CPP		CPB	
CPP alone	ErhBMP-2 + CPP	CPB alone	ErhBMP-2 + CPB
2wk 33%	71%	12%	61%
8wk 24%	65%	15%	39%



**Conclusion:** Within in the limitations of the present study, calcium phosphate carrier system coated by *E. coli*-expressed rhBMP-2 can be concluded to be effective in bone regeneration, and even distribution of new bone was observed in particulated type. Further development about macro- and micro-porosity of block type carrier system is needed.

## Bone regeneration and interparticle spacing with new formulations

**Presenter:** Palma P

Dental Medicine Department, Faculty Medicine, University of Coimbra, Coimbra, Portugal

Co-authors: Palma P<sup>1</sup>, Matos S<sup>1</sup>, Ramos J<sup>1</sup>, Figueiredo H<sup>2</sup>, Kausar J<sup>3</sup>, Guerra F<sup>1</sup>

<sup>1</sup>Dental Medicine Department, Faculty Medicine, University of Coimbra, Coimbra, Portugal, <sup>2</sup>Histologic Department, Faculty Medicine, University of Coimbra, Coimbra, Portugal, <sup>3</sup>Implant Center of the Palm Beaches, Boca Raton, FL, USA

**Background and aim:** There is a trend in developing biologic modalities that may enhance wound healing of specific sites. In this regard, the cell-binding domain activity of type I collagen is provided by a synthetic peptide (P-15) incorporated in a scaffold (anorganic bovine matrix [ABM]) to facilitate the attachment, migration, and differentiation of cells. Recently, a new presentation of this material has been developed with the purpose of improving its handling, controlling particle migration and optimizing its clinical efficacy. It was suggested that creating a more homogenous interparticle spacing, which is a sine qua non condition for a proper cellular and vascular colonization, could promote a faster bone regeneration with expectable quantitative and qualitative clinical benefits. The aim of this study authorized was to evaluate different bone grafts in bone regeneration: ABM/P-15 formulations and a demineralized rabbit allograft.

**Materials and methods:** Thrity-two adult, male, rabbits were divided in four test groups and one positive control group (ABM/P-15 particulate) and one negative control group (empty-no filling). Critical size defects in the distal femur were filled with ABM/P-15 part. (Group I) and with ABM/P-15 carriers: carboxymethylcellulose and glycerol (Group II); sodium hyaluronate (Hy) hydrogel (Group III), and lyophilized plugs (Group IV). Additionally, demineralized bone allograft suspended in sodium Hy was used in Group V. Block sections were harvested at 2 and 4 weeks for histological processing.

**Results:** Group II presented a significant reduction in bone formation compared with other groups, in both evaluation periods. At 2 weeks, Group V presented a significant increase in new bone formation compared with Group I ( $P < 0.05$ ). Group IV presented more new bone formation than Groups I and III, nevertheless there was no statistical difference ( $P > 0.05$ ). At 4 weeks, Group IV presented a significant increase in new bone formation compared with Group I ( $P < 0.05$ ) and there were no significant differences between Groups III and V and the Group I ( $P < 0.05$ ). There was statistical difference in intragroups comparison only for Groups I and V.

**Conclusion:** These results show the influence of different formulations of bone grafts in providing an adequate scaffold for the support of the regenerative process and emphasize the importance of three-dimensional distribution of particles and space provision in new bone formation, especially in early periods.

239 Poster – Topic Tissue Augmentation and Tissue Engineering

Ridge augmentation of the atrophic posterior mandible with inlay and onlay iliac bone grafting: a prospective controlled clinical trial for the comparison of two techniques

**Presenter:** Felice P

*University of Bologna, Bologna, Italy*

**Co-authors:** Felice P<sup>1</sup>, Pistilli R<sup>2</sup>, Lizio G<sup>1</sup>, Pellegrino G<sup>1</sup>, Checchi L<sup>1</sup>, Marchetti C<sup>1</sup>

<sup>1</sup>University of Bologna, Bologna, Italy, <sup>2</sup>San Filippo Neri Hospital, Rome, Italy

**Background and aim:** To compare the efficacy of two techniques in terms of bone gain, bone-resorption, vertical augmentation, cumulative peri-implant bone resorption, implant survival, implant success and complication rate, in two groups of patients who underwent inlay and onlay bone grafting for preprosthetic issues in the atrophic posterior mandible. The time needed to fully recover mental nerve sensitivity was also investigated.

**Materials and methods:** Twenty surgical sites on 20 patients were randomly assigned to two treatment groups: group A: Inlay and group B: Onlay. All grafts were taken from iliac crest. After 3–4 months, 20 fixtures in the Inlay group and 23 in the Onlay group were placed for fixed prosthetic rehabilitation. Provisional and definitive prostheses were delivered 4 and 8 months later respectively. The median follow-up after loading was 18 months.

**Results:** The median bone gain was 4.9 vs. 6.5 mm (Inlay vs. Onlay,  $P$ -value 0.019); the median bone resorption was 0.5 vs.

2.75 mm (Inlay vs. Onlay,  $P$ -value  $< 0.001$ ); the median final vertical augmentation was 4.1 vs. 4 mm (Inlay vs. Onlay). The implant survival rate was 100% in both groups, while the implant success rate was 90% vs. 86.9% (Inlay vs. Onlay,  $P$ -value 0.190ns). A minor and major complication rate of 20% and 10%, respectively, for both groups was encountered.

**Conclusion:** Inlay technique obtains lower bone resorption and more predictable outcomes but requires an experienced surgeon; Onlay technique obtains higher bone resorption, needs a bone block graft over-sized in height respect to the final vertical augmentation what clinicians are looking for, but requires a shorter learning curve. Once implant placement has been carried out, the outcomes are similar for both groups procedures, both techniques may be considered effective in correcting vertical deficits in posterior mandible, with implant outcomes comparable to those in native alveolar bone.

240 Poster – Topic Tissue Augmentation and Tissue Engineering

The effects of platelet-rich plasma (PRP) on the proliferation and the release of growth factors of periodontal ligament cells

**Presenter:** Pang EK

*Ewha Womans University Graduate School of Medicine, Goyang-Si, Korea*

**Co-authors:** Lee SK<sup>1</sup>, Ji S<sup>2</sup>, Pang EK<sup>1</sup>

<sup>1</sup>Department of Periodontology, Ewha Womans University Graduate School of Medicine, Seoul, Korea, <sup>2</sup>Department of Periodontology, Korea University Anam Hospital, Seoul, Korea

**Background and aim:** Periodontal ligament cells (PDLs) plays an important role in the regeneration of periodontium. One of the ways promoting healing potentials of PDLs is *via* the use of platelet-rich plasma (PRP). PRPs contain high concentrations of growth factors and stimulate the repair and regeneration of tissues. In this study, the effects of PRP on the proliferation and the activation of PDLs and on the release of growth factors from PDLs were investigated.

**Materials and methods:** PDLs were isolated from third molars or premolars of healthy young patients, 16–25 years old. Whole blood were obtained from four healthy volunteers, 25–39 years old. And PRPs were prepared using centrifugal separator (PLA-CON<sup>TM</sup>, Oscotec Inc., Seoul, Korea) and activated. The platelet concentration of PRP was measured and the amount of PDGF-AB, PDGF-BB, TGF- $\beta$ 1, VEGF were determined by ELISA. Activated PRPs were added to media and the effect of different concentrations of PRPs on the proliferation and the alkaline phosphatase (ALP) activity of PDLs were investigated. The effect of PRPs on the attachment of PDLs and on the release of growth factors from PDLs according to time were evaluated using ELISA. As statistical analyses, Student's *t*-test, one-way analysis of variance (ANOVA), two-way ANOVA and Bonferroni's multiple comparison test were performed ( $P < 0.05$ ).

**Results:** Platelet concentration was 5.14-fold increased in PRP compared to whole blood. Growth factor levels in PRP were measured and mean 273.38 ng/ml of PDGF-AB, 47.0 ng/ml of

PDGF-BB, 168.42 ng/ml of TGF- $\beta$ 1 and 510.56 pg/ml of VEGF were detected. PDLs cultured in the media containing 10% or more concentrations of PRPs showed significantly increased cell proliferation and ALP activity compared with control ( $P < 0.05$ ). PDLs cultured in the media containing 10% PRP also presented higher cell attachment and increased release of TGF- $\beta$ 1 and VEGF compared with control ( $P < 0.05$ ).

**Conclusion:** PRPs could deliver high concentrations of growth factors to defect site directly and indirectly and increased the proliferation, the attachment and the ALP activity of PDLs. From these results we suggested that PRP could be a useful tool to facilitate periodontal regeneration.

#### 241 Poster – Topic Tissue Augmentation and Tissue Engineering

### Socket preservation in the aesthetic zone using autogenous hard and soft tissue grafts

**Presenter:** Hanser T

*Privatzahnklinik Schloss Schellenstein, Olsberg, Germany*

**Co-authors:** Hanser T, Khoury F

*Privatzahnklinik Schloss Schellenstein, Olsberg, Germany*

**Background and aim:** Socket preservation using bone substitutes rather aims at a graft-enhanced soft tissue healing than leading to a bony healing in the extraction socket. This presentation reports the results of a study evaluating the clinical performance of extraction site management using autogenous hard and soft tissue grafts preventing not only soft tissue volume collapse but also achieving real bone formation, even in cases of partial alveolar bone defects.

**Materials and methods:** After antibiotic prophylaxis and gentle tooth extraction in 17 patients 22 single or neighbouring sockets in the aesthetic zone (incisors and canines) were completely filled with autogenous bone chips. Partial or entire loss of the buccal alveolar bone after tooth extraction was present in all cases. A free gingival graft of about 3 mm thickness from the palate corresponding to the socket's orifice was sutured to seal the grafted extraction site. Sockets were filled with autogenous bone chips harvested from edentulous sections with the MicroSaw (Dentsply Friadent, Mannheim, Germany) or trephine bur. Clinical outcome was examined after 1, 2, 4, 6 and 8 weeks to verify soft tissue graft integration, alveolar volume and bony healing. Implant placement was performed 8 weeks after socket preservation.

**Results:** After 8 weeks all soft tissue grafts were integrated and extraction sockets fully epithelialized. No clinical relevant alveolar collapse was found and soft tissue contours could be preserved in all cases. Bone grafts were clinically mature and well revascularized. Bony contours were preserved and buccal alveolar bone defects rebuilt. Ideal prosthetic driven implant placement could be performed. All implants were surrounded by at least 2 mm bone after placement without additional grafting procedures. Aesthetic outcome after prosthetic treatment was pleasing in all cases.

**Conclusion:** Compared with the exclusive osteoconductive potential of bone substitutes the osteogenetic, osteoinductive and osteoconductive potentials of autogenous bone grafts enable not only graft-enhanced soft tissue healing but also a real bone

formation in the extraction socket, a reduction of treatment time and avoid additional costs for biomaterial. Moreover extraction site management using autogenous grafts can be seen not only as a tissue preserving but also reconstructive technique in cases of partial alveolar bone defects.

#### 242 Poster – Topic Tissue Augmentation and Tissue Engineering

### Clinical results of vertical bone augmentation with autogenous bone block and tunnel technique

**Presenter:** De Stavola L

*Private Practice, Rubano PD, Italy*

**Co-authors:** De Stavola L<sup>1</sup>, Tunkel J<sup>2</sup>

*<sup>1</sup>Private Practices, Padova and Treviso, Italy, <sup>2</sup>Private Practice, Bad Oeynhausen, Germany*

**Background and aim:** Since implant dentistry has begun to play an important role in the rehabilitation of patients, techniques for vertical bone reconstruction to optimize the aesthetics and function have been advanced. The autogenous bone is unequivocally accepted as gold standard for reconstruction. However, the volume instability of the regenerated bone after block graft augmentation seems to jeopardize the effective end result. The aim of this study is to report the outcome of the treatment of vertical defects with autogenous bone graft in terms of vertical bone gain and bone resorption at the time of the augmentation surgery (TPo), the implant placement (TP1) and the abutment connection (TP2).

**Materials and methods:** Ten vertical mandible or maxilla defects were treated by tunnel technique with autogenous mandible bone block in ten consecutive partially dentated patients. Implants were inserted 4 months after TPo, and abutment connections were placed 4 months after TP1. Four linear measurements were taken (a) the maximal extension of the vertical defect (VD) measured from the residual alveolar crest to the level of the mesial/distal bone; (b) the vertical amount of the bone graft (VBG) measured from the residual alveolar crest level to the more coronal part of the graft, at TPo; (c) the bone resorption (BR1) at TP1 measured from the regenerated alveolar crest level to the head of the vertical screw fixing the bone block during the healing; (d) the bone resorption during the implant-healing (BR2) as the distance between the implant shoulder and the bone level at the TP2. The complete amounts of bone resorption (BRtot) and of bone gain (VBGtot) from TPo to TP2 were calculated.

**Results:** No major complications as exposure of the bone graft were recorded, all implants were osseointegrated. Both the VD and the VBG mean were 6.5 mm. The BR1 and BR2 mean were both 0.3 mm, with a BRtot mean of 0.6 mm (9.3%) and a VBGtot mean of 5.9 mm.

**Conclusion:** Limited bone resorption (9.3%), a great amount of vertical bone gain (5.9 mm) and no graft exposure seem to demonstrate that vertical bone augmentation with autogenous bone graft combined with a tunnel-technique-approach is a reliable and predictable method to treat vertical defects of the alveolar crest.

### Effect of combinatorial BMPS(BMP-2, BMP-7) gene delivery on osteoblastic differentiation

**Presenter:** Park YS

*Seoul National University Dental Hospital, Seoul, Korea*

**Co-authors:** Yark YS, Lee YM

*Seoul National University Dental Hospital, Seoul, Korea*

**Background and aim:** Bone morphogenetic proteins (BMPs) play a role in induce undifferentiated cells to be differentiated into osteoblastic cells. Therefore, can contribute to regeneration of destructed tissue. However, human trials with BMPs have generally been less successful than earlier animal studies. Gene therapy (*ex vivo*) has recently been used as a means of delivering BMPs to sites of tissue regeneration. In the present study, we investigated the effect of co-transduction of adenoviruses expressing BMP-2 and BMP-7 on osteoblastic differentiation of C2C12 cells *in vitro*.

**Materials and methods:** A replication-defective human Ad5 containing a cDNA for BMPs in the E1 region of the virus (Ad5BMP-2 and Ad5BMP-7) was constructed by *in vivo* homologous recombination. W20-17 cells were used for evaluation of functional activity of adenoviral vector, Ad5BMPs. After, Ad5BMP-2 and Ad5BMP-7, those have functional activity, transduced C2C12 cells with various MOI (multiplicity of infection) to assess most effective and stable titer. Based on this result, C2C12 cells were transduced with Ad5BMP-2 and Ad5BMP-7 alone or by combination. And then we assessed BMPs expression, ALP activity, cell proliferation.

**Results:** Ad5BMP-2 and Ad5BMP-7 successfully transduced to W20-17 cells, and secreted BMPs stimulated cell differentiation. Also, C2C12 cells transduced with Ad5BMPs showed expression of BMPs and increased ALP activity. When MTT test was performed to assess of toxicity of Ad5BMPs and secreted BMPs, in all groups, cell proliferation was observed over times. However, at 7 days, cells cotransduced with Ad5BMP-2 and Ad5BMP-7 showed lower proliferation than the others. C2C12 cells co-transduced with Ad5BMP-2 and Ad5BMP-7 had greater ALP activity than would be predicted if effect of individual Ad5BMPs were additive.

**Conclusion:** Present study demonstrated that adenoviruses expressing BMPs gene successfully produce BMPs protein and these BMPs stimulate cells to be differentiated into osteoblastic cells. Also the osteogenic activity of Ad5BMPs can be synergistically increased by co-transduction of cells with Ad5BMP-2 and Ad5BMP-7.

### The evaluation of vertical bone formation ability of various graft materials using titanium cap in the rabbit calvarium

**Presenter:** Kook M

*Chonnam National University, Korea, Gwang-Ju, Korea*

**Co-authors:** Kook M, Choi G, Park H, Oh H, Ryu S

*Chonnam National University, Korea Gwang-Ju, Korea*

**Background and aim:** This study was performed to evaluate of new vertical bone formation ability of various graft materials used with titanium cap in the rabbit calvarium.

**Materials and methods:** Total 32 sites of artificial bony defects were prepared by using trephine bur with a diameter of 8 mm on calvaria of sixteen rabbits. Grooves with the depth of 0.2 mm were prepared by using trephine bur with a diameter of 8 mm on the calvaria of 16 rabbits for the fixation of titanium cap. Treatment was performed respectively as induced only bleeding for control group ( $n=8$ ), autogenous bone graft with iliac bone for experimental group 1 ( $n=8$ ), alloplastic bone graft (Syntho-Graft<sup>®</sup>, USA) for experimental group 2 ( $n=8$ ) and xenogenic bone graft (NuOss<sup>®</sup>, USA) for experimental group 3 ( $n=8$ ). After the treatment, titanium cap (diameter 8 mm, height 4 mm, thickness 0.2 mm) was fixed into the groove. At the third and sixth week post-operatively, each groups of rabbits were sacrificed to evaluate in the aspect of radiographic and histological analysis.

**Results:** (1) According to micro CT analysis, the comparison of the remodeled bone below the titanium cap showed no statistically significant difference among experimental groups ( $P>0.05$ ). And the lowest bone volume was observed in the control group.

(2) In histological analysis, the control group in the third week showed bone remodeling along the inner surface of the cap and at the contact region of calvarium without any specific infiltration of inflammation tissue. Bone remodeling was observed around the grafted bone and along the inner surface of the titanium in all experimental groups. And all groups in the sixth week showed more increased area of bone remodeling and maturation than those in the third week.

(3) Histomorphologically, comparing of newly formed bone showed on sequence of autogenous, alloplastic, and heterogenous bone graft in decreasing order. But, there was no statistically significant difference among autogenous, alloplastic, and heterogenous bone ( $P>0.05$ ).

**Conclusion:** This result suggests that autogenous bone is best choice for vertical bone formation, but when autogenous bone graft has a limited availability, alloplastic and xenogenic bone graft also may be an alternatively good bone graft material used with suitable guided membrane.

### Experiences with nanostructured bone substitutes in particular and block form: prospective histological and clinical trial with 3 years follow-up

**Presenter:** Meier J

*Private Practice, Bremerhaven, Germany*

**Co-authors:** Meier J, Wolf E, Heine M

*EAO, Brussels, Belgium*

**Background and aim:** This study deals with a bone substitute (BS) produced at relatively low temperatures consisting of nano crystalline hydroxyapatite (HA) embedded in silica-gel matrix [NanoBone (TM)]. The structural changes after implantation were analysed histologically and the cellular ingrowth with special regard to the formation of blood vessels and the de novo bone formation was demonstrated. The organisation of the augmentation material was compared with other BS with

special regard to time and the amount of newly formed bone. While granular BS of different composition have reached kind of standard in implantology their varying biological potential seems worth being reviewed. The introduction of this BS in form of blocks opens a path to augmentation procedures that previously could be performed only by autogenous, allogenic or xenogenic bone transplants without the second site operation to harvest bone or other risks. Histological and clinical outcome after 3-year follow-ups will be presented.

**Materials and methods:** The BS NanoBone (TM) was applied for lateral, vertical or combined augmentations of the alveolar process (LA:  $n=75$ ) and external sinus floor elevations (SFE:  $n=68$ ) in particular form. Lateral augmentations and socket preservation was also performed using the NanoBone-Block (TM). The advantage of the latter was the fact that the often difficult stabilising of the augmentation material was not necessary due to the solid consistence. The timetable based on an average healing period of 3 months after augmentation when bone specimen were collected during implant placement. The functional loading of the implants was started another 3 months later. In eight cases bilateral SFE was performed and to judge the individual reaction to different BS NanoBone (TM) was applied on one side and compared with bovine bone mineral on the other. The ratio of new bone vs. bone marrow and remaining BS was measured.

**Results:** Six of the total of 149 patients in the LA and SFE groups were lost to follow-up. In the remaining collective all of the 358 implants inserted in the augmented areas were still in function and unobtrusive. Radiological examinations to estimate changes in bone contour showed no regression above the variation of measurement faults. In the LA group the thin or thick biotype of the gingival tissues seem to influence the stability of the buccal onlay when granular NanoBone (TM) is used, but due to difficulties in the clinical assessment no hard data could be gained. The impression is that in thin biotype cases the loss of volume seem to be more relevant. A histologic evaluation of the resorption process and the bone formation after LA is not as easy as in SFE cases where bone specimen were obtained routinely. Block augmentation was started in October 2008. The results and bone penetration in humans show that this is a valuable and reliable alternative to bone transplants of other origin

**Conclusion:** Augmentation of bone deficiencies in maxillofacial and oral surgery can be performed nicely using nanostructured HA in silica-gel matrix [NanoBone (TM) = NB] in granular as well as in block form. The latter can be applied in places where mechanical stabilisation is more difficult or important and yields a promising implant layer. That fact that cellular ingrowth and the invasion of blood vessels even in the inner spaces of the BS can be observed in early stages of the regeneration promotes the osseous integration and substitution by a large amount of vital bone. Compared with other BS the augmentation with NB yields more vital bone in only half or one third of the time recommended for e.g. BBM. The considerable shortening of the underlying therapy protocol with 3 months incorporation period for the BS and another 3 months

for the integration of the implants can be regarded a reliable modification for the benefit of our patients.

Evaluation of the fate of anorganic bovine bone fragments (Bio-Oss<sup>®</sup>) applied for sinus augmentation by histochemical and cytological methods with special references to the interaction with osteoclasts

**Presenter: Tamaki H**

*Tokyo Medical and Dental University Graduate School, Bunkyo-ku, Tokyo, Japan*

**Co-authors: Tamaki H, Nakayama H, Takano Y**

*Tokyo Medical and Dental University Graduate School, Bunkyo-ku, Tokyo, Japan*

**Background and aim:** Currently, sinus augmentation utilizing bone substitutes instead of autologous bone is accepted as predictable method. However, actual process of tissue reactions and fate of bone substitutes after sinus augmentation have not been fully elucidated. The aim of this study was therefore to evaluate bone conductivity and fate of a commonly used bone substitute (Bio-Oss<sup>®</sup>) grafted for sinus augmentation in the dental clinic, by histochemical and cytological methods.

**Materials and methods:** Five patients aged 38–63 without systemic complications were selected and five sinus augmentation were performed using a 100% anorganic bovine bone matrix (ABBM: Bio-Oss<sup>®</sup>) as bone substitute. Six months following the procedure, a bone core at installation of implant was removed and processed for radiographic, histological and histochemical analyses by light and electron microscopy under a written informed consent. Osteoconductive capacity of ABBM, remodeling of induced bones and fate of ABBM were evaluated by histomorphometrical methods. Thirteen Straumann implants were placed and remained for three months before restorative treatment.

**Results:** At postoperative sixth month, densely packed fragments of ABBM were remaining throughout the isolated bone core. Most ABBM fragments were encapsulated by the induced bone and formed a solid framework of ABBM-bone composite. Surface layers of the ABBM fragments encapsulated in the induced bone showed distinct immunoreactions for osteopontin. Most induced bone over the ABBM fragments was covered with bone lining cells and active sites of bone formation or resorption were seldom encountered. In contrast, most of the exposed surfaces of ABBM particles were covered with multinuclear osteoclasts showing intense histochemical reactions of tartrate-resistant acid phosphatase (TRAP). Average resorption surface rate of the induced bone at 6 M after operation was only 2.1%, whereas that of the exposed ABBM particles was as high as 48.3%. Interestingly, however, large proportion of multinuclear TRAP positive cells attached to the ABBM surfaces were devoid of typical ruffled border.

**Conclusion:** ABBM rapidly induces bone deposition on its surface, whereby allowing accumulation of osteopontin into the matrix, which may later promote osteoclast attachment and its resorption once exposed to the surrounding milieu. ABBM (Bio-Oss<sup>®</sup>) particles thus appear to form solid and stable 3D composite with newly induced bone, which are only slowly remodeled

because of hypofunctional osteoclasts, and hence provide stable support for the implant body for substantial periods.

247 Poster – Topic Tissue Augmentation and Tissue Engineering

### Porous titanium granules and emd in rabbit tibia critical size peri-implant osseous defects

**Presenter:** Wohlfahrt JC

*University of Oslo, Oslo, Norway*

**Co-authors:** Wohlfahrt JC, Rønold HJ, Ellingsen JE, Lyngstadaas SP

*University of Oslo, Oslo, Norway*

**Background and aim:** Porous Titanium Granules (PTG) have been used to a limited extent as osseous regenerative materials within the field of orthopaedic surgery for 15 years. The aim of this study was to investigate the osteoconductive properties of porous titanium granules (PTG) or PTG mixed EMD (EPTG) or EMD alone (EMD).

**Materials and methods:** In this animal experimental study critical size defects were prepared in the tibias of 24 New Zealand rabbits. The defects were randomized into three tests and one control group. The test defects were treated with either PTG, EPTG or EMD whereas control defects were left empty (sham). The defects were closed with a submerged coin shaped titanium implant and left healing for four weeks. Osseous regeneration was analyzed by micro-CT and histology using indexes for (A) Regenerated peri-implant cortical bone, (B) New bone in the marrow space compartment and (C) Vertical amount of regenerated cortical bone.

**Results:** Significantly more regenerated bone were seen in the defects grafted with either PTG or EPTG when compared to Sham or EMD for all indexes ( $P < 0.05$ ). No difference was seen between defects grafted with PTG and EPTG. The sham defects did not close completely and did not show any bone formation in the marrow compartment, confirming that these defects are true critical size defects at least within the time frame of this experiment.

**Conclusion:** The results suggest that PTG is osteoconductive and can be used to promote bone formation in critical size osseous defects adjacent to titanium implants without hampering implant osseointegration. No beneficial effects from the adjunctive use of EMD to PTG were seen.

248 Poster – Topic Tissue Augmentation and Tissue Engineering

### Osteogenic potential of bone-marrow derived osteoblast on titanium and zirconium oxide surface

**Presenter:** Pae A

*School of Dentistry, Kyung Hee University, Seoul, Korea*

**Co-authors:** Pae A<sup>1</sup>, Bae K<sup>1</sup>, Lee H<sup>2</sup>, Kim HS<sup>1</sup>, Woo YH<sup>1</sup>

<sup>1</sup>Department of Prosthodontics, School of Dentistry, Kyung Hee University, Seoul, Korea, <sup>2</sup>Department of Oral Anatomy, School of Dentistry, Kangnung National University, Kangnung, Korea

**Background and aim:** The ivory color of zirconium oxide, similar to the color of natural tooth, makes it useful in esthetically

important areas of the oral cavity, and its ability to transmit light provides advantages in esthetic restorations. High biocompatibility with reduced bacterial adhesion and flexural strength render it an excellent material for implant abutments. The purpose of this study is to evaluate the proliferation and osteogenic potential of bone-marrow derived osteoblasts on zirconia oxide surfaces using the cDNA-microarray.

**Materials and methods:** Discs measuring 10 mm in diameter and 2 mm in thickness were made of zirconium oxide and grade 4 titanium alloy. Rat bone-marrow derived osteoblasts were harvested and cultured on (1) grade 4 titanium disc (control group) and (2) yttrium-stabilized tetragonal zirconia polycrystal (experimental group). By using cDNA microarray, expression of 21,575 genes was monitored in the control and experimental group. Cell proliferation activity was evaluated through MTT assay at 4 and 24 h. SEM (scanning electron microscopy) was used to visualize the progression of osteoblast culture at 4 and 24 h. ALP activity was measured at 4 days to evaluate the cell differentiation rate.

**Results:** cDNA microarray showed that the expression profiles of the cells on the titanium discs exhibited striking overlaps with those of the cells on zirconia discs. However, in the expression of genes involved in cell adhesion were upregulated on the zirconia surface. The genes regulating apoptosis and ubiquitin mediated proteolysis were also upregulated on the zirconia surface. Several genes involved in regulating proteasome and ribosome were downregulated on the zirconia surface. From the MTT assay, the optical density of blue formazan produced by the osteoblast on titanium surface and zirconia surface showed no significant difference. SEM examination revealed that osteoblasts were well spread and attached on both surfaces. The cells cultured on titanium and zirconia showed similar ALP activities.

**Conclusion:** In this study, we evaluated the proliferation and osteogenic potential of bone-marrow derived osteoblasts on zirconia oxide. Zirconia showed comparable biological response of osteoblasts with titanium. Zirconia is able to up/downregulate some functional activities of osteoblasts.

249 Poster – Topic Tissue Augmentation and Tissue Engineering

### Intraoperative factors affecting onlay block graft resorption

**Presenter:** Stacevicius M

*Vilnius Implantology Center Clinics, Vilnius, Lithuania*

**Co-authors:** Grybauskas S, Stacevicius M, Puisys A, Linkevicius T

*Vilnius Implantology Center Clinics, Vilnius, Lithuania*

**Background and aim:** To determine intraoperative factors that have most influence on bone graft resorption.

**Materials and methods:** Prospective clinical study started Aug 2005 and is still ongoing. Intraoperative data from over 100 autogenous onlay block grafting procedures are used to evaluate onlay autogenous bone graft resorption with respect to residual ridge width, recipient site, storage in saline vs. blood, block size, block adjustment time, 1 vs. 2 screw fixation, normal vs. reverse

block orientation, perforations, biomaterial coverage and total operation time. Data were analyzed and contrasted at both timepoints (during operation and at the time of implant placement).

**Results:** Mean graft resorption reached up to 1 mm. Mandibular anterior recipient sites are significantly correlated with increased graft resorption ( $P < 0.05$ ), while biomaterial coverage significantly decreases bone loss during post operative healing period ( $P < 0.05$ ). Neither residual ridge width, saline vs. blood storage, block size, block adjustment time, 1 vs. 2 screw fixation nor cortical-to-bed relationship or perforations affected bone grafts significantly.

**Conclusion:** The least resorption of onlay block graft can be achieved by harvesting grafts of sufficient thickness, rigidly fixating them with at least two screws in a close-fit position, filling residual gaps, covering grafts with xenograft and a resorbable barrier membrane.

250	Poster – Topic Tissue Augmentation and Tissue Engineering
-----	---

Is periosteum prevention helpful during guided bone defect regeneration? Experimental studies of cranial bone osseous differentiation using local BMP-2/4 gene transfer and peg-membranes

**Presenter:** Wehrhan F

University of Erlangen-Nuremberg, Erlangen, Germany  
Co-authors: Falk W<sup>1</sup>, Schlegel KA<sup>1</sup>, Amann K<sup>2</sup>, Molenberg A<sup>3</sup>, Lutz R<sup>1</sup>, Wieland M<sup>3</sup>

<sup>1</sup>Department of Oral and Maxillofacial Surgery, University of Erlangen-Nuremberg, Erlangen, Germany, <sup>2</sup>Institute of Pathology, University of Erlangen-Nuremberg, Erlangen, Germany, <sup>3</sup>Straumann Research Institute, Straumann AG, Basel, Switzerland

**Background and aim:** Bone substitute materials (BSM) and membranes, preventing fibroproliferation during guided bone regeneration (GBR) are widely used. Local BMP-2/4 gene delivery could promote bone progenitor cell recruitment, osseous differentiation and proliferation without stimulation of periosteum derived overwhelming fibroproliferation. Respecting the unique feature of cranial bone precursor cell biology of high proliferation due to their cranial neural crest (CNC) origin, the contribution of the periosteum could accelerate bone regeneration. The aim of the experimental study was to evaluate the influence of local BMP-2/4 gene transfer on domestic pig's calvarian bone CSD regeneration in presence and absence of periosteum and compared to cellular proliferation stimulation by recombinant PDGF. Prevention of periosteum was realised using PEG membranes. Defect regeneration was quantitatively assessed by histology and osseous differentiation by immunohistochemistry.

**Materials and methods:** 20 adult domestic pigs received 9 cylindric CSD (1 × 1 cm) in the calvarial bone. Defects were allowed to regenerate by either filling with: autologous bone; BSM (HA/TCP) + BMP-2/4 transfected osteoblasts + PEG membrane; BSM (HA/TCP) + rhPDGF + PEG-membrane. PEG membranes were used with either 10- or 120-day degradation kinetics. BMP-2/4 gene transfer was realised by a fusion protein

(liposomal *in vitro* transfection with the artificial tag V5. Quantitative histomorphometry was performed (Toluidin-blue staining) after 1, 2, 4 and 12 weeks. Immunohistochemistry assessed the degree of osseous/chondrogenic differentiation (Sox-9, BMP-2/4) and the duration of BMP-2/4-expression (V5-tag).

**Results:** Induced BMP-2/4-expression was traced until 2 weeks following cell transfer. 4 weeks after surgery in BMP-2/4 transfected defects a significantly reduced bone formation was detected in the periosteum prevented defect compared to the periosteum covered defects ( $P < 0.05$ ). Expression of Sox-9 was significantly reduced in the periosteum prevented, and in the periosteum covered and BMP-2/4 transfected defects compared with the periosteum covered defects only ( $P < 0.05$ ). 12 weeks after surgery no significant difference was detected targeting the Sox-9 expression in the periosteum prevented and the periosteum covered defects, whereas Sox-9 was significantly reduced in all BMP-2/4 transfected defects ( $P < 0.05$ ).

**Conclusion:** Prevention of periosteum is dispensable in conditions of exogenous bone morphogenic differentiation, using local BMP-2/4-gene delivery. During early bone repair guided bone regeneration can be accelerated in CSD of maxillofacial bone if sufficient bone progenitor cell differentiation is provided. The regenerative capacity of periosteal bone progenitor cells should be involved in the regenerative approach.

251	Poster – Topic Tissue Augmentation and Tissue Engineering
-----	---

Histological evaluation of osseous neoformation promoted by an injectable calcium phosphate cement in atrophic areas

**Presenter:** Gehrke SA

Bioface Institut and University of Santa Maria, Santa Maria RS, Brazil

Co-authors: Gehrke SA<sup>1</sup>, König Jr. B<sup>2</sup>, Martins NB<sup>3</sup>

<sup>1</sup>Bioface Institut, Santa Maria, Brazil, <sup>2</sup>University of São Paulo, São Paulo, Brazil, <sup>3</sup>University of Santa Maria, Santa Maria, Brazil

**Background and aim:** Many commercial bone substitutes are available on the market today. All claim to be osteoconductive, most of them have been studied in animal models, but few have been investigated histologically to evaluate their performance in human beings. The aim of the study was to assess the ability of a calcium phosphate cement (PD VitalOs Cement<sup>®</sup>, Produits Dentaires SA, Switzerland) to stimulate bone neoformation using two augmentation techniques: sinus floor augmentation and horizontal ridge augmentation.

**Materials and methods:** Six patients were included in the study, three requiring sinus floor elevation (Group 1, G1), the other three requiring horizontal ridge augmentation (Group 2, G2). The selected patients all needed implants in the augmented sites, as well as at least one implant in a neighboring site with enough bone to allow installation of the implant. They all signed an informed consent before being enrolled. All the surgeries were performed in two steps, with implant installation 4 and 6 months after augmentation in the Groups 2 and 1, respectively. Cores were collected with a trephine bur upon

implant placement. The obtained sections were stained with the Hematoxylin/Eosin and the Masson's trichrome methods. In each patient, a core of native bone was collected close to the augmented site to place the additional implant. The number of osteocytes was measured with an image analysis software.

**Results:** No complication occurred and all the treated sites healed uneventfully. All implants could be installed as planned. The mean quantity of osteocytes found in the two augmented groups is significantly higher than in the cores collected from the neighboring sites (native bone): 15 per mm<sup>2</sup> in G1, 19 per mm<sup>2</sup> in G2, 6 per mm<sup>2</sup> in native bone. The trabecular density is higher in augmented cases than in native bone. In the trabeculae, numerous osteocytes can be seen in the sections, as well as many incremental growth lines. In the non-calcified spaces between trabeculae, an intensive cellular activity can be deduced from the presence of collagen fibers. Intensive vascularization is also evidenced by the presence of numerous dilated blood vessels. No cement remnant is to be seen on any of the histological sections of the augmented sites.

**Conclusion:** The study shows the ability of the cement to stimulate osteogenesis. No remnant of the cement can be seen on any of the histological sections collected upon implant installation. This indicates that PD VitalOs Cement is completely resorbable.

#### 252 Poster – Topic Tissue Augmentation and Tissue Engineering

Experimental study of immediate distraction osteogenesis with bone grafting: comparison with the bone grafting method

**Presenter: Funaki K**

*Takeshita Dental Clinic Success Implant Center, Tokyo, Japan*

**Co-authors: Funaki K<sup>1</sup>, Yamashita Y<sup>2</sup>, Yamauchi K<sup>2</sup>, Takeshita K<sup>1</sup>, Takahashi T<sup>2</sup>**

<sup>1</sup>*Takeshita Dental Clinic Success Implant Center, Tokyo, Japan,*

<sup>2</sup>*Kyushu Dental College, Kitakyushu, Japan*

**Background and aim:** After causing the defect of the jawbone continuously to the operation of the tumor or the injury, the bone grafting (BG) method or the distraction osteogenesis (DO) has been selected. On the BG method, there is a problem of bone resorption. On the DO, there is a difficulty of making the transport segment. Simultaneous approach of both methods has not been reported, therefore those problems might be able to be solved. The purpose of this research is to do the immediate distraction osteogenesis with bone grafting for the mandible in dogs.

**Materials and methods:** All animal experiments were conducted according to the Guidelines for Animal Experimentation at Kyushu Dental College, Japan. Ten beagle dogs were used in this experiment. The right side was the immediate distraction osteogenesis side (IDO). The left side was augmented by the BG method. Mandibular premolars were extracted and buccal corticotomy in each dog. The cortical bone block of 2 mm in thickness was made from the mandible. The block bone was transplanted to the alveolar defect region, and a horizontal

alveolar distraction device was installed. After a 10-day latency period, distraction commenced at a rate of 0.2 mm per day for 10 consecutive days to allow for horizontal elongation of 2 mm at the top of crest. After the distraction osteogenesis, the left mandibular premolars were extracted and the cortical bone block was transplanted to the region. The animals were sacrificed 1 month (1 m group; *n* = 5) or 3 months (3 m group; *n* = 5) after the bone augmentation.

**Results:** Bone augmentation: In 1 m group, the average of the amount of bone gain was 3.6 mm on the IDO side and that was 1.6 mm on the BG side. In 3 m group, the average of the amount of bone gain was 2.6 mm on the IDO side and that was 1.4 mm on the BG side. In the both groups, the average amount of the bone gain on the IDO side was significantly greater than that on the BG side. Histologic findings: newly bone formation could be seen in the distraction gap 1 month after the bone augmentation. Three months after bone augmentation, a mature bone tissue was admitted in the distraction gap.

**Conclusion:** The amount of the bone gain on the IDO was greater than that on the BG. IDO reported on this experiment seemed one of the useful bone augmentation methods.

#### 253 Poster – Topic Tissue Augmentation and Tissue Engineering

Impact of hydrophilic implant surfaces to support hard tissue formation at chronic-type alveolar ridge defects

**Presenter: Schwarz F**

*Heinrich Heine University, Düsseldorf, Germany*

**Co-authors: Schwarz F<sup>1</sup>, Rothamel D<sup>2</sup>, Ferrari D<sup>1</sup>, Jung R<sup>3</sup>, Becker J<sup>1</sup>**

<sup>1</sup>*Department of Oral Surgery, Heinrich Heine University, Düsseldorf,*

*Germany, <sup>2</sup>Department of Maxillofacial and Plastic Surgery,*

*University of Cologne, Cologne, Germany, <sup>3</sup>Department of Fixed and Removable Prosthodontics and Dental Material Science, University of Zurich, Zürich, Switzerland*

**Background and aim:** The aim of the present study was to radiologically evaluate the impact of chemically modified hydrophilic titanium implants (modSLA) to support hard tissue formation at chronic-type lateral ridge defects of varying extensions without guided bone regeneration (GBR).

**Materials and methods:** A total of eight standardized lateral ridge defects (depth: 6 mm, width: 9 mm) exhibiting different heights (T1: 2 mm; T2: 4 mm; T3: 6 mm; T4: 8 mm) were prepared bilaterally in the lower jaw of 12 beagle dogs each. After 4 weeks of chronification, modSLA implants were inserted at the respective sites, and randomly allocated in a split-mouth design to either (a) GBR (polyethylene glycol membrane + biphasic calcium phosphate), or (b) untreated control. After 2 and 8 weeks of submerged healing, the residual defect height (RDL) was determined at each site using cone beam computed-tomography.

**Results:** At 2 weeks, control sites revealed significantly higher RDL values at T1 (*P* < 0.01), T2, T3 and T4 (*P* < 0.01; respectively) defects when compared to the GBR sites. At 8 weeks, between group comparisons revealed comparable mean RDL values at T1



and T2 sites ( $P > 0.05$ ; respectively). Even though all control sites exhibited a hard tissue formation at T3 and T4 defects, mean RDL values were significantly lower at GBR treated sites ( $P < 0.01$ ; respectively).

**Conclusion:** Within its limitation, the present study has indicated that modSLA titanium implants might have the potential to support hard tissue formation at T1 and T2 defects without GBR procedures.

254	Poster – Topic Tissue Augmentation and Tissue Engineering
-----	---

## Bone augmentation in rabbit calvariae: a comparative histopathologic animal study

**Presenter:** Ghanavati F

*Shaheed Beheshti University School of Dentistry, Tehran, Iran*

**Co-authors:** Ghanavati F<sup>1</sup>, Gholami G<sup>1</sup>, Asgari S<sup>2</sup>, Eghbal J<sup>2</sup>, Ghanavati F<sup>3</sup>, Rahimi H<sup>4</sup>, Sadr P<sup>5</sup>, Karamlou M<sup>6</sup>, Sculean A<sup>7</sup>

<sup>1</sup>Department of Periodontology, Iran Center for Dental Research, University of Shahid Beheshti, School of Dental Medicine, Tehran, Iran, <sup>2</sup>Department of Endodontics, University of Shahid Beheshti, School of Dental Medicine, Tehran, Iran, <sup>3</sup>Newcastle Hospital, Newcastle, UK, <sup>4</sup>Harvard School of Dental Medicine, Boston, MA, USA, <sup>5</sup>Farzan Institute of Science, Research and Technology, Tehran, Iran, <sup>6</sup>Shaheed Beheshti University, School of Dentistry, Tehran, Iran, <sup>7</sup>Department of Periodontology, Radboud University Medical Center, the Netherlands Antilles

**Background and aim:** The rabbit calvaria was challenged with Tri Calcium phosphate (TCP), Bovine-Derived Hydroxyapatite (BioOss), Calcium Sulphate (CaS), Demineralised Freeze-dried Bone Allograft (DFDBA) and an oily calcium hydroxide suspension (Osteoinductal), to evaluate and compare the bone histopathologic response to these materials.

**Materials and methods:** Thirty-four holes in the calvaria of 12 male Australian rabbits were randomly filled with TCP, BioOss, CaS, DFDBA and Osteoinductal and two holes were kept as control and one month later histological evaluation were performed on the samples using an optical microscope. The regenerated bone type and extension, the extent of the material which was absorbed, the amount of inflammation and the presence of inflammatory cells i.e., foreign body giant macrophages, lymphocytes, monocytes, foreign body giant cells and plasmacells were recorded by the pathologist. Statistical analysis was carried out with Kruskal-wallis, Fisher's exact test and ANOVA when appropriate.

**Results:** The type of regenerated bone in the defect area did not show a significant difference between the groups ( $P = 0.3895$ ); while the amount of inflammation was significantly different ( $P = 0.029$ ) BioOss had the least amount of inflammation and while the DFDBA group was associated with the highest amount of inflammation. The presence of foreign body giant cells was also significantly different ( $P = 0.0009$ ) and there was no any considerable difference for the presence of other inflammatory cells ( $P$  concerning bone formation extension, no significant difference was detected between the groups ( $P = 0.475$ ).

also DFDBA had the highest material resorption and TCP group had the lowest amount ( $P = 0.002$ ).

**Conclusion:** DFDBA granules were the most resorbable material and it shows more inflammation than other substitutes in the rabbit calvaria. BioOss exhibit the least inflammation and TCP had the least capability for resorption. Giant cells have been detected mostly in Ostin samples while in TCP samples these were the least. BioOss showed the most amount of bone regeneration and DFDBA exhibited the least amount of bone formation.

255	Poster – Topic Tissue Augmentation and Tissue Engineering
-----	---

## Implant survival following vertical and horizontal bone augmentation with a synthetic biphasic calcium phosphate: long-term follow-up datas

**Presenter:** Stricker A

*University of Freiburg, Freiburg, Germany*

**Co-authors:** Stricker A, Gutwald R, Metzger M, Schmelzeisen R, Sauerbier S

*Department of OMS University Hospital of Freiburg, Freiburg, Germany*

**Background and aim:** Bone augmentation is frequently necessary to support dental implant placement procedures. Autogenous bone is considered to be the current gold standard for bone augmentation; however, only limited amounts of autogenous bone can be harvested at the implantation site. Furthermore this procedure may lead to morbidity problems. As an alternative, commercially available bone substitutes may be used to limit some of the drawbacks associated with autogenous bone. Straumann® BoneCeramic is a commercially available synthetic bone graft substitute comprising porous biphasic calcium phosphate, in the form of granules, which has been on the market since 2004. In this study we report long-term implant survival rate.

**Materials and methods:** In all indications, with exception of bone splitting, Straumann® BoneCeramic was used in combination with autogenous bone. For vertical augmentation procedures bone particles were first fixed to the alveolar ridge and subsequently covered by the synthetic graft particles. A resorbable collagen membrane was always used to protect and stabilize the augmentation site. Implants were mostly inserted simultaneously into the augmented bone. Functional loading occurred between 3 and 5 months post-surgery, depending on the indication.

**Results:** Between January 2005 and December 2008 we performed 332 sinus floor elevations, 153 bone splitting procedures, 148 vertical augmentations and 37 lateral augmentations using this new material. A total of 1025 dental implants, from various different manufacturers, were inserted. We disposed of 3 years follow data for 73 implants placed, at least 2 years follow-up data for 403 implants and at least 1 year follow-up data for 751 implants. Four implants were lost, three after sinus lifts and one following vertical augmentation. The overall success rate was 99.6%.

**Conclusion:** The result is encouraging, also in comparison to previous data obtained with the use of autogenous bone alone.

The positive influence of the material on the healing process can be related to its osteoconductive and resorption characteristics.

256 Poster – Topic Tissue Augmentation and Tissue Engineering

### Immunophenotype and ultrastructural characterization of cell culture from grafted maxillary sinus

**Presenter:** Padial-Molina M

*University of Granada, Granada, Spain*

**Co-authors:** Padial-Molina M<sup>1</sup>, Galindo-Moreno P<sup>1</sup>, Avila G<sup>2</sup>, Moreno-Riestra I<sup>2</sup>, Fernandez-Barbero JE<sup>1</sup>, O'Valle F<sup>1</sup>

<sup>1</sup>University of Granada, Granada, Spain, <sup>2</sup>University of Michigan, Ann Arbor, MI, USA

**Background and aim:** The presence of non-mineralized tissue is important for graft remodeling. The expression by mesenchymal cells of different growth factors favor its differentiation toward bone formation. The aim of this study was to determine the immunophenotype and ultrastructural characteristics of cells cultured from maxillary sinus grafted with a composite bone graft.

**Materials and methods:** A composite bone graft consisting of autologous cortical bone and anorganic bovine bone, in a 1:1 ratio, was used for sinus elevation with 6 months delayed implant placement. Primary osteogenic cells obtained from core biopsies were cultured. Immunohistochemistry analysis to certify histogenetic origin was performed. Ultrastructural characteristics were analyzed by transmission electron microscopy.

**Results:** Cultured adherent cells showed intense immunostaining for vimentin, CD68, lysozyme, fascin, caldesmon and CD10. Negative stain for CD34, CD31, CD56, osteopontin, podoplanin (D2-40), desmin, E-cadherin and S-100 protein was observed. Some isolated cellular elements were positive for  $\beta$ -catenin, calponin, actin and COX-2 stain. Ki-67 indicated a proliferative index of 30–35%. Ultrastructural study showed large cell nuclei and great number of intracytoplasmatic vesicles with different densities.

**Conclusion:** Our data reveal the presence in cultured tissue of mesenchymal cells with a non-clearly defined complex immunophenotype. They may be adults stem cells capable to differentiate toward different cells types by paracrine signaling.

257 Poster – Topic Tissue Augmentation and Tissue Engineering

### Small intestinal submucosa (SIS) and titanium frame membranes: a new alternative for guided bone regeneration (GBR). A subclinical study in dogs

**Presenter:** Briceno F

*Universidad Javeriana, Bogota, Colombia*

**Co-authors:** Briceno F, Vivas J, Landaeta C, Rincon J, Ordonez A

*Universidad Javeriana, Bogota, Colombia*

**Background and aim:** A new alternative intended for GBR was created, developed and tested. SIS is a well-known Biomaterial

for replacement or repair of damaged tissues that contains a tridimensional matrix that is ideal for surgical regeneration processes. SIS Collagen membranes were reinforced with titanium prefabricated mesh, combining two different biomaterials to create a new compound. These new membranes' tridimensional structure and the biologically rich composition of the purified collagen provide an option for regenerating tissues. The objective of this study is to evaluate the efficacy of this invention and compare it to traditional alternatives.

**Materials and methods:** A new compound made through the invention method and generally suitable for regenerative surgery was created and tested. Thirty-five mutt dogs were used, classified in four groups as follows: Group A consisted of 10 dogs who received the SIS-titanium compound; Group B of 10 dogs who received SIS collagen membranes; Group C of 10 dogs who received Titanium mesh; and Group D of five dogs constituted the control group, none of whom were grafted. In all the animals an authentic four-wall bony defect was created in the posterior mandible during the first surgical stage; subsequently in the second surgical stage all the bony defects were grafted with autologous bone and GBR was performed with three different materials. After 90 days the animals were sacrificed and a dental CT scan taken.

**Results:** CT scan image analysis showed a significant difference in terms of the quantity and density of regenerated bone in group A (SIS titanium membranes) compared to the other groups (SIS collagen, Titanium mesh and control group).

**Conclusion:** The present study subclinically demonstrated that the invented SIS-titanium membrane compound is a highly reliable material for use as an implantable material in regenerative bone surgery. A high degree of effectiveness was observed in terms of volume and bone density.

258 Poster – Topic Tissue Augmentation and Tissue Engineering

### Relapse and overcorrection in alveolar distraction osteogenesis for dental implant of mandible

**Presenter:** Iwata M

*Kishiwada Tokushukai Hospital, Kishiwada, Japan*

**Co-authors:** Iwata M

*Kishiwada Tokushukai Hospital, Kishiwada, Japan*

**Background and aim:** Vertical alveolar distraction osteogenesis is an efficient method for augmentation prior to inserting dental implants. But a relapse of the transport segment and decrease in bone height before implant placement is common. In this study, we evaluated this alveolar distraction osteogenesis before implant placement, investigated the relapse in bone height. And we determined the overcorrection in alveolar distraction osteogenesis, period of implant placement.

**Materials and methods:** The subjects were 25 patients, ranged in age from 21 to 52 years with the defect of the mandible (19 males and 6 females). In all cases we treated by vertical alveolar distraction osteogenesis. Active distraction was started after a latency period of 3 days with a rate of 0.5 mm twice daily. After

the end of alveolar distraction osteogenesis, length of consolidation was 3 months, and distractors were removed. Bone height was measured on digital orthopantomographic radiographs, after distraction and before implant placement.

**Results:** Mean alveolar distraction was 11.5 mm. The mean relapse was 21% (13% to 27%) after the end of consolidation. 1 month after distractor removal, 10 patients were performed implant placement (Group A). The mean relapse was 5% (1–7%) at implant placement. On the other hand, 15 patients were performed distractor removal and implant placement at the same time (Group B).

**Conclusion:** The vertical alveolar distraction osteogenesis before dental implant placement is very useful but a considerable relapse must be confronted. This study indicated that implant placement performed at the same time of distractor removal if possible, and the need for overcorrection was more than 27%. In Group A, the need for overcorrection was more than Group B, more than 34%.

#### 259 Poster – Topic Tissue Augmentation and Tissue Engineering

### Preclinical animal model for de novo bone formation in human maxillary sinus

**Presenter:** Lutz R

*Oral and Maxillofacial Surgery, Erlangen, Germany*

**Co-authors:** Lutz R<sup>1</sup>, Rupprecht S<sup>2</sup>, Petrovic L<sup>2</sup>, Honert C<sup>3</sup>, Srour S<sup>1</sup>, Felszegy E<sup>4</sup>, Nkenke E<sup>1</sup>, Schlegel KA<sup>1</sup>

<sup>1</sup>Oral and Maxillofacial Surgery, University of Erlangen, Erlangen, Germany, <sup>2</sup>Private Practice, Erlangen, Germany, <sup>3</sup>Private Practice, Asbach, Germany, <sup>4</sup>Institute for Forensic Medicine, Semmelweis University, Budapest, Hungary

**Background and aim:** Up to now the effect of bone substitute materials on *de novo* bone formation has been tested in a variety of preclinical animal models to demonstrate their regenerative capacity before clinical use. In order to define the comparability of the experimental pig model, the following study compared the outcome of bone regeneration after application of autogenous bone and bone substitutes in a porcine model with the clinical outcome in humans.

**Materials and methods:** In the animal experiment  $\beta$ -tricalcium phosphate ( $\beta$ TCP), hydroxyapatite (HA) and autogenous bone (AB) were each placed in three monocortical bone defects (10 mm diameter) on the forehead of six adult pigs ( $N=54$ ). In a randomized prospective clinical trial, 44 sinus floor elevations were performed with  $\beta$ TCP, HA and AB in 41 patients. The bone regeneration rate was quantified microradiographically, after a defined observation period of 24 weeks in both experimental models.

**Results:** No statistically significant differences in bone regeneration after application of autogenous bone (AB) and bone substitute materials (HA and  $\beta$ TCP) in a porcine calvarial monocortical defect model and in human maxillary sinus augmentation could be found after 24 weeks of observation. [AB ( $P=.98$ ),  $\beta$ TCP ( $P=.31$ ) and HA ( $P=.68$ )]. Wilcoxon rank-sum test was used for statistical analysis.

**Conclusion:** The chosen porcine model ensures an important evidence of biocompatibility before clinical use of bone substitute materials. Showing no statistically significant differences in bone regeneration compared to human maxillary sinus it has to be considered as a valuable model for preclinical testing of bone substitute materials in maxillofacial surgery.

#### 260 Poster – Topic Tissue Augmentation and Tissue Engineering

### Dimensional study of the bone reparation achieved after the sinus lift procedure with a composite graft of autogenous bone and deproteinized mineral bovine bone, assessed by cone-beam tomography

**Presenter:** Vargas A

*University of Oviedo Spain, Oviedo, Spain*

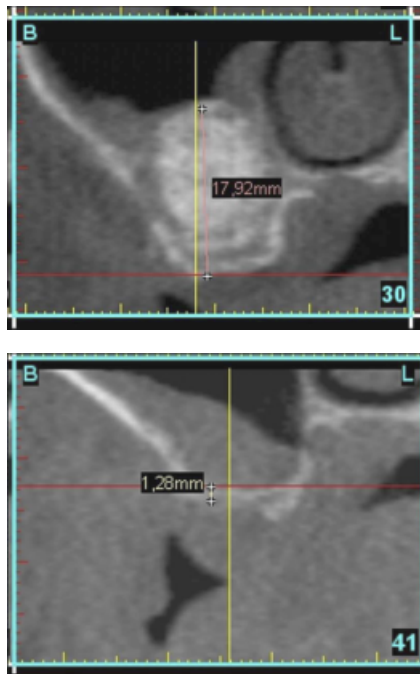
**Co-authors:** Vargas A<sup>1</sup>, Sicilia A<sup>2</sup>

<sup>1</sup>University of Oviedo, Oviedo, Spain, <sup>2</sup>Clinica Sicilia, Oviedo, Spain

**Background and aim:** The sinus floor elevation is a well-documented technique for the grafting of atrophic posterior maxillas with reduced crestal bone height. Several grafting materials have been described for this proposal. In type III and IV sinuses this procedure becomes especially necessary and often a delayed implant approach is required, making it vital to analyze patients' characteristics and to minimize complications which could threaten the graft viability. The aim of this study was to calculate the bone gain after maxillary sinus grafting in potential maxillary sites receiving dental implants evaluated by means of cone-beam tomography. Secondly, prevalence of complications and its influence on bone reparation was evaluated.

**Materials and methods:** Twenty-four consecutive patients from January 2007 to December 2007 receiving 29 sinus floor elevations (type III and IV sinuses) were evaluated retrospectively. An initial cone-beam tomography assessed insufficient residual crestal bone height. Subsequently, the sinus lift procedure was performed (lateral window approach) and any perforation of the schneiderian membrane was covered (collagen membrane), if noted. A composite graft was then placed. When it was possible, implants were placed simultaneously. Patients were monitored and any adverse event was recorded. After a maturation period of 6–8 months, a second cone-beam tomography was carried out, leading to the placement of 65 rough-surface implants. An immediate provisional prosthesis was developed when primary stability requirements were achieved. Short-term (average 9.82 months) implant survival rate was calculated. The average bone height gain and the influence of complications were analyzed statistically.

**Results:** Six perforations of the sinus membrane were observed during the healing period. Ninety-seven percent of the implants were placed in a delayed approach, after a healing period of 6–8 months; whereas 3% were placed simultaneously. An overall survival rate of 100% was observed after a follow-up of 10 months. To consider an implant successful, the criteria of Albrektsson et al were evaluated. No complications were observed in the immediate provisional restorations. An average 12.7 mm of bone height gain was observed after the maturation of the maxillary sinus graft.



**Conclusion:** Within the limitations of this study, delayed implant placement after sinus grafting seems to be a reliable alternative for severely atrophic maxillary sites receiving implant rehabilitations. Complications, such as membrane perforations, seem to decrease significantly the amount of bone reparation, without preventing programmed implant placement or compromising graft viability.

carefully elevated and its integrity was assessed visually and with a blunt instrument. The site randomly assigned to test group was treated with the application of a resorbable barrier (Inion<sup>®</sup>) with no grafting material. The Inion barrier stiffens in contact with water holding up the sinus membrane and maintaining the space beneath. Contra-laterally 100% particulated inorganic bovine bone (Bio-Oss<sup>®</sup>) was applied beneath the sinus membrane (control procedure). After 6 months, a total number of 60 Way<sup>®</sup> (Geass, Italy) implants were placed and a bone specimen has been taken for histological evaluation on both sides. Implants were loaded after 4 months.

**Results:** Test procedure: Atrabecular bone with large medullary space were observed. Many osteoblasts were observed in the process of apposing bone. No acute inflammatory cell infiltrate was present around the particles or at the interface with bone. Histomorphometry showed that the mean amount of new bone was  $37.0 \pm 3.28$ , of marrow spaces was  $62.2\% \pm 4.4$ , of osteoblast activity was 25%.

**Control procedure:** A new woven bone and a remarkable percentage of residual Bio-Oss biomaterial was found. Residual ABB particles, in most cases, were surrounded by marrow spaces. In other areas, lamellar bone was found in tight contact with the particles surface. Histomorphometry showed that the mean amount of new bone was  $39.0 \pm 2.28$ , of ABB was  $47.1 \pm 3.18\%$ , of marrow spaces was  $22.2 \pm 5.4\%$ , of osteoblast activity was 5%.

**Conclusion:** Histological outcomes demonstrated that the use of a stiff barrier is able (a) to maintain lifted up the Schneiderian membrane, (b) to preserve the space underneath, (c) to obtain the formation of a good quality bone just from the bone clot, with no necessity of grafting materials.

261 | Poster – Topic Tissue Augmentation and Tissue Engineering

A comparison of two techniques to augment maxillary sinuses with the lateral approach: no grafting procedure vs. anorganic bone placement. Preliminary histological and clinical outcomes of a randomized controlled clinical trial

**Presenter:** Felice P

*University of Bologna, Bologna, Italy*

**Co-authors:** Felice P<sup>1</sup>, Esposito M<sup>2</sup>, Scarano A<sup>3</sup>, Pistilli R<sup>4</sup>, Lizio G<sup>1</sup>, Checchi L<sup>1</sup>

<sup>1</sup>University of Bologna, Bologna, Italy, <sup>2</sup>University of Manchester, Manchester, UK, <sup>3</sup>University of Chieti-Pescara, Chieti, Italy, <sup>4</sup>San Filippo Neri Hospital, Rome, Italy

**Background and aim:** To compare the histological/histomorphometric and implant results up to 4 months follow-up of two different maxillary sinus lift techniques via a lateral approach: the use of synthetic resorbable barriers (Inion) (test group) without grafting material in one side vs. anorganic bovine bone (Bio-Oss) placement in the contra-lateral site (control group).

**Materials and methods:** Ten patients with a residual bone height of 1–4 mm in posterior edentulous maxillas underwent sinus lift procedures performed bilaterally with lateral approach: after the elevation of a mucoperiosteal flap, a lateral bony window was performed and internally displaced; the maxillary membrane was

262 | Poster – Topic Tissue Augmentation and Tissue Engineering

Evaluation of a new three-dimensional measurement technique to define bone volume after sinus augmentation

**Presenter:** Hein P

*University Dental Clinic, Medical University Graz, Graz, Austria*

**Co-authors:** Hein P<sup>1</sup>, Kirmeier R<sup>1</sup>, Platzer S<sup>2</sup>, Grbic S<sup>3</sup>, Robl T<sup>4</sup>, Lorenzoni M<sup>2</sup>, Jakse N<sup>1</sup>

<sup>1</sup>Department of Oral Surgery and Radiology, University Dental Clinic, Medical University Graz, Graz, Austria, <sup>2</sup>Department of Prosthodontics Prosthetics, Periodontology, Restorative Dentistry and Implantology University Dental Clinic, Medical University Graz, Graz, Austria, <sup>3</sup>Institute for Computer Graphics and Vision, University of Technology Graz, Graz, Austria, <sup>4</sup>Department of Radiology, Medical University Graz, Graz, Austria

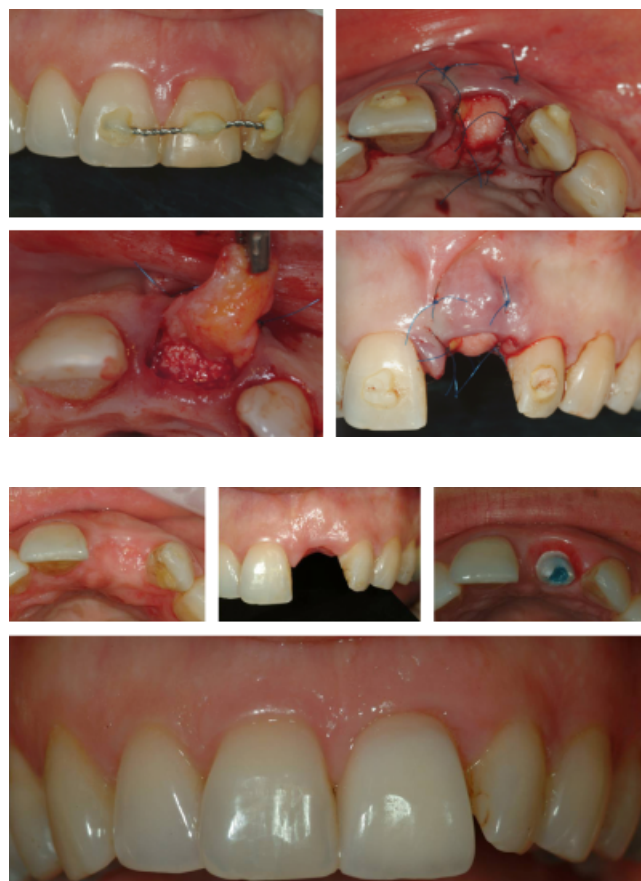**Background and aim:** Volume determination of internal maxillary sinus augmentations and evaluation of time dependend dimensional changes are very time-consuming. The intention of this investigation was to assess a newly developed software to calculate the grafted volumes automatically using computed tomography (CT) data sets.

**Materials and methods:** In this study augmentations and dimensional changes were simulated with radiation impermeable

impression material on three skulls to validate this new 3D measurement technique. We scanned the skulls before and after each augmentation procedure in three positions each using a CT scanner. The newly developed software application generated the datasets to evaluate the simulated volume by calculating the difference between the datasets with and without augmentation. The actual grafted volume was finally validated with support of Leonardo 3D Workstation, Version VD10B syngo VX49B, (Siemens, AG, Bensheim, Germany). All measurements were performed three times by three examiners.

**Results:** Three augmentations were simulated in the maxillary sinus of three skulls. The average of the volume of the first simulated augmentation was 2.785 ml, of the second 4.43 and 5.495 ml were augmented in the third simulation. We compared both methods and calculated the coefficient of correlation (ICC). The ICC of 0.999 illustrates that the methods correlate high reliable. It could be shown that the process is also reliable, if the skulls are in three different directions located on the CT-scanner.

**Conclusion:** This *in vitro* study shows that the new software tool is a time saving and accurate application to calculate the volume of maxillary sinus augmentations automatically.



#### 263 Poster – Topic Tissue Augmentation and Tissue Engineering

Evaluation of a technique for ridge volume preservation after tooth extraction 'saddle connective tissue graft and bovine HA for ridge preservation after extraction'?

**Presenter: Lecloux G**

*University of Liège, Chaudfontaine, Belgium*

**Co-authors: Lecloux G, Raepsaet N, Lambert F, Rompen E**

*University of Liège, Liège, Belgium*

**Background and aim:** The aim of this prospective study was to evaluate a technique for tissue volume preservation after tooth extraction.

**Materials and methods:** Twelve patients in need of tooth extraction in the aesthetic area (upper incisors, canines) were treated. After gentle tooth avulsion, the socket was filled with BioOss (Geistlich). A free connective tissue graft, inserted in semi-thickness pockets buccally and palatally, was then used to cover the socket like a 'saddle'. Photographs, impressions and clinical observations were performed every 2 weeks till 12 weeks after surgery. Dimensional changes of the alveolar ridge were calculated on models: measurements were performed at 3 points at the mid-zone of the buccal aspect, as well as at 3 points (mesial papilla, centre and distal papilla) on the occlusal side. A resin key supported by adjacent teeth and spaced from soft tissues was used for measurements and to check concordance between models. Reproducibility of the measures was statistically analysed by ANOVA-2, and time-associated changes with a linear model (GLMM).

**Results:** At 12 weeks, vertical dimension at papilla level were not significantly different from baseline as well as the central

value. For horizontal dimension, the most coronal value showed a decrease of 0.87 mm ( $P=0.006$ ) while the central and apical values were not changed.

**Conclusion:** In conclusion, this 'saddle' technique led to a successful preservation of alveolar ridge volume although with a minimal loss of 0.87 mm which is better than other reports from different techniques.

#### 264 Poster – Topic Tissue Augmentation and Tissue Engineering

Sinus augmentation using pre-hydrated cortico cancellous porcine granules bone: hystomorphometric evaluation after 6 months

**Presenter: Ricci M**

*University of Genova, Camaiore, Italy*

**Co-authors: Ricci M<sup>1</sup>, Calvo-Guirado JL<sup>2</sup>, Rispoli L<sup>3</sup>, Covani U<sup>4</sup>, Barone A<sup>5</sup>**

<sup>1</sup>Department of Biomedical and Dental Sciences and Technologies, Camaiore, Italy, <sup>2</sup>Department of Implant Dentistry, University of Murcia, Murcia, Spain, <sup>3</sup>Department of Dentistry, University of Rome, Rome, Italy

**Background and aim:** The aim of this investigation was to evaluate the efficacy of a xenograft (pre-hydrated cortico-cancellous porcine bone) in sinus augmentation surgery after a period of 6 months of healing.

**Materials and methods:** This prospective human study was performed in 26 maxillary sinuses. Eighteen patients between



the age of 38 and 70 years who required sinus floor elevation were enrolled in this study. All the maxillary sinuses were grafted using 100% cortico-cancellous porcine bone particles (MP3<sup>®</sup>, TecnoSS, Coazze, Italy). The osteotomy windows were covered with a reabsorbable collagen membrane. Biopsy specimens were taken from the lateral window after 6 months and an histomorphometric evaluation was performed.

**Results:** In all 26 samples, the area fraction of the new formed bone ranged from 7.5% to 100% with an average of  $43.95 \pm 18.6\%$ . The ratio between new bone and residual graft material in the augmented sinuses was 3.1.

**Conclusion:** Sinus augmentation with the above reported xenograft was considered a well-accepted procedure. Moreover, it should be taken into consideration the high resorption rate of this bio-material 6 months after grafting. We were unable to investigate the biological reasons for the high resorption rate. However, a possible role of the hydrating porcine collagen should be evaluated.

265 Poster – Topic Tissue Augmentation and Tissue Engineering

### Quantitative assessment of bone graft quality following sinus lift using intra-oral radiography

**Presenter: Kim H**

*UC Medical Corporation, Tokyo, Japan*

**Co-authors: Kim H<sup>1</sup>, Son M<sup>2</sup>**

<sup>1</sup>Private Practice, Tokyo, Japan, <sup>2</sup>Nagoya University, Nagoya, Japan

**Background and aim:** In previous studies it was shown that the image analysis of the bony structure on dental radiographs was valid to assess bone quality. The imaging parameters of the trabecular pattern on intra-oral radiographs show correlations with the bone mineral density (BMD) as measured by quantitative computerized tomography (QCT). The aim of this prospective study was to quantitate bone quality following sinus lift using the image analysis of intra-oral radiographs. The reliability of the imaging parameters was assessed to determine whether the tested analysis could be used to quantitate graft incorporation.

**Materials and methods:** Ten patients were treated with implants placed into sinuses grafted with autogenous bone and beta tricalcium phosphate. A total of eleven sinuses were treated. Implant installation was performed four months after bone grafting. Intra-oral radiographs of grafted site were obtained postoperatively and at predetermined periods thereafter. The regions of interest (ROI) were selected for each radiograph stored on hard disk and binarized. A total of 32 parameters were measured using binary images to assess bone graft quality morphometrically. The reliability of the parameters at each phase was examined by means of Cronbach's  $\alpha$ .

**Results:** More than 50% of the values of Cronbach's  $\alpha$  for the parameters was less than 0.6 during the first 2 months. A significant increase in the values of  $\alpha$  was measured 2 months postoperatively. Eighty-four percent of the values was at least 0.85 thereafter and 99% was at least 0.85 at 4 months and thereafter. The increases in the values of  $\alpha$  leveled 4 months

postoperatively and little further changes were measured. The internal consistency of the imaging parameters was highly established at least 4 months postoperatively.

**Conclusion:** The overall changes in the measurements of the imaging parameters were attributed to a increase in bone remodeling activity in the grafted sites especially at 2 months postoperatively and thereafter. This study indicates that a healing period of 4 months after bone grafting has already been sufficient for graft incorporation. The image analysis of intra-oral radiographs potentially offers an alternative diagnostic tool to identify the optimal graft healing period and the timing of implant placement after grafting. Further studies are needed to quantitate bone quality of different grafting materials placed in sinuses.

266 Poster – Topic Tissue Augmentation and Tissue Engineering

### New method to control a gingival flap in implant second surgery or one stage implant surgery

**Presenter: Jo JW**

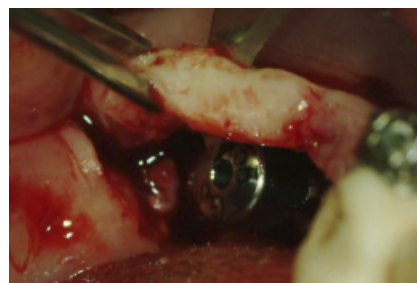*Chung-Ang University Hospital, Seoul, Korea*

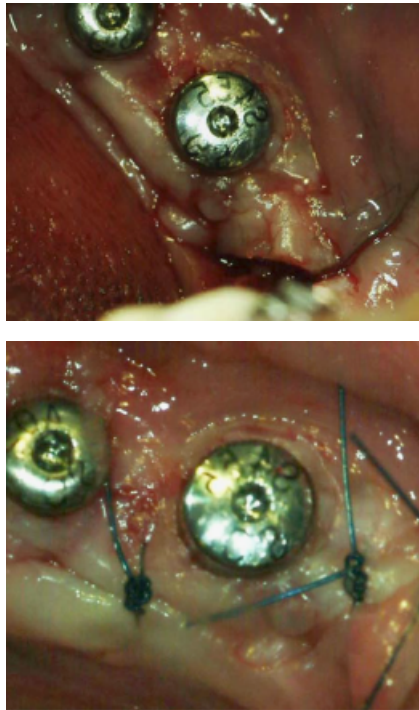
**Co-authors: Jo JW<sup>1</sup>, Choi YJ<sup>2</sup>**

<sup>1</sup>Chung-Ang University Hospital, Seoul, Korea

**Background and aim:** The suture after implant second surgery or one-stage implant installation is performed buccal and lingual side around healing abutments. Usually the impression for prothodontics is performed after suture off. If there are no suture materials or incision lines around healing abutments, there are less changes of gingiva around the healing abutments and it is possible to take an impression for prothodontics earlier. The purpose of this study is to introduce a new flap control method which is used in one-stage implant surgery or second implant surgery. In this method, there is no suture material or incision line around the healing abutment, therefore faster soft tissue healing and less changes of gingiva around the healing abutment is expected.

**Materials and methods:** After lingually positioned incision and flap elevation, cover screw is removed and healing abutment is placed. A small hole is punched on elevated flap in proper position with #12 blade. If the small hole is positioned in attached gingiva, better healing is expected. Punched flap is putted on healing abutment like 'T-shirt wearing' action. The healing abutment is exposed to oral cavity. Sutures are performed just around incision line not around the healing abutments.





**Results:** After the flap is putted on healing abutments like 'T-shirt wearing' action, the small hole in the flap is expanded during passing healing abutments and shrink again around the neck of healing abutment. So, the flap can be fitted completely around the healing abutments. After suture, the fitted gingival tissue does not have much changes its shape or volume. And the gingival healing around the healing abutment is faster than usual method of second implant surgery or one stage implant surgery.

**Conclusion:** The new method like 'T-shirt wearing' action of this study makes soft tissue around the abutments healing faster and less changes after second surgery or one stage implant surgery. So it is possible to take an impression for prothodontics earlier and to remain more attached gingiva around the healing abutment. If a dentist planed the implant installation with submerged method, but the bone density is better than it seemed in X-ray, this method can be used. And if an incision is positioned too linually in second surgery, this method can be used, too.

267 Poster – Topic Tissue Augmentation and Tissue Engineering

A comparative study with or without ha graft materials of bone augmentation beyond the skeletal envelope in the rat calvarium: the micro CT and histological analysis

**Presenter:** Kochi G

*Nihon University Grauduate of Dentistry, Chiyoda-ku, Japan*  
Co-authors: Kochi G<sup>1</sup>, Sato S<sup>2</sup>, Orii H<sup>2</sup>, Moriya Y<sup>2</sup>, Arai Y<sup>3</sup>, Ito K<sup>2</sup>

<sup>1</sup>Division of Applied Oral Science, Nihon University Graduate School of Dentistry, Tokyo, Japan, <sup>2</sup>Department of Periodontology, Nihon University School of Dentistry, Tokyo, Japan, <sup>3</sup>Nihon University School of Dentistry, Tokyo, Japan

**Background and aim:** A new microfocus computerized tomography (R\_mCT) system is now available that can quickly and

continuously produce clear images of bones in small living animals. The goal of this study was to evaluate whether micro-CT analysis matches histomorphometry and whether it can be used to assess bone augmentation beyond the skeletal envelope in the rat calvarium.

**Materials and methods:** The calvarium was exposed, and circular grooves were prepared bilaterally to a penetration of 26%. Two resin caps were placed in the absence (control) or presence (experiment) of hydroxyapatite (HA), and images of bone augmentation within the resin cap were obtained via R\_mCT. The rats underwent repeated R\_mCT scans 1–12 weeks after surgery, followed by preparation of histological sections. For each central section, we calculated and compared the percentages of newly generated bone and marrow space relative to the bounded area of the resin cap.

**Results:** R\_mCT images and histological analyses demonstrated higher bone volumes in the experimental sites compared to the control sites. The total volumes measured histologically and by R\_mCT correlated with one another.

**Conclusion:** R\_mCT is useful for the measurement of bone regeneration beyond the skeletal envelope.

268 Poster – Topic Tissue Augmentation and Tissue Engineering

The effects of bmps on osteoblast cells: VEGF, CA, PI, and no levels and cell morphology

**Presenter:** Aybar B

*Istanbul University Faculty of Dentistry, Istanbul, Turkey*  
Co-authors: Aybar B<sup>1</sup>, Emes Y<sup>1</sup>, Vural P<sup>2</sup>, Degirmencioglu S<sup>2</sup>, Atalay B<sup>1</sup>, Kaya AS<sup>1</sup>, Aktas I<sup>1</sup>, Issever H<sup>2</sup>, Yalcin S<sup>1</sup>, Bilir A<sup>2</sup>

<sup>1</sup>Faculty of Dentistry, Istanbul University, Istanbul Turkey, <sup>2</sup>Istanbul Faculty of Medicine, Istanbul University, Istanbul Turkey

**Background and aim:** Bone morphogenetic proteins (BMPs) play an important role in the initiation of bone formation by affecting cell growth and differentiation in a variety of cell types including osteoblasts. Vascular Endothelial Growth Factor (VEGF), is an important regulator of angiogenesis and vasculogenesis, and also VEGF signaling is important for skeletal development. Nitric Oxide (NO), Calcium (Ca) and Inorganic Phosphate (Pi) are important molecules for cell functions. The aim of this study was to evaluate effects of BMPs on VEGF, Ca, Pi, NO and osteoblast cell morphology in an osteoblast cell culture model.

**Materials and methods:** 50,000 cells/ml were seeded and cultured on graft materials for 24 and 48 h (h). Different concentrations of BMP's (combination of BMP's numbered from 1 to 14) were supplemented to the medium.

**Results:** BMP was found to increase VEGF ( $P=0.00$ ), Ca ( $P=0.02$ ) and Pi ( $P=0.00$ ) especially in the first 24h. The increase in the NO in the experimental groups were found to be statistically insignificant ( $P=0.12$ ).

**Conclusion:** Our data state that further investigation should be performed on the effects of BMPs on osteoblast cell membranes and membrane receptors and cell signaling, together with its known effects on early phase of bone and vascular epithelial tissue formation.

Reconstruction of the alveolar ridge by means of a titanium mesh and particulate autogenous bone grafts at the point of bone defect with radiographic evaluation

**Presenter:** Miyamoto I

*Kyushu Dental College, Kitakyushu City, Japan*

**Co-authors:** Miyamoto I, Tomoyose T, Yamauchi K, Kodama T, Yamashita Y, Takahashi T

*Kyushu Dental College, Kitakyushu, Japan*

**Background and aim:** Several bone augmentation procedures have been introduced; autogenous bone graft with titanium mesh is one of the useful techniques. However, there are a few clinical studies with titanium mesh and autogenous bone grafts. The purpose of this study is to evaluate titanium mesh for the alveolar ridge reconstruction clinically and radiographically with computed tomography for the implant placement at the point of the type of bone defect.

**Materials and methods:** Forty patients at 50 sites rehabilitated between September 2000 and February 2009 with autogenous particulate mandibular ramus bone or iliac particulate cancellous bone marrow graft and micro titanium mesh for the implant placement without block bone graft were evaluated. The shape of bone defects were distributed three patterns. Horizontal and vertical bone defects, horizontal bone defect, and socket type bone defect group were evaluated, respectively. The complications encountered in this study were classified and assessed during healing period and after implant installation.

**Results:** The bone defects were successfully augmented with titanium mesh and autogeneous bone graft without block bone generally. The horizontal and vertical bone defect type was the most difficult augmentation bone defect. Mean horizontal bone height was 3.6 (range 2.0–7.7) mm and vertical height were 4.6 (2.1–6.5) mm. The horizontal bone defect type was 4.2 (1.6–7.3) mm. On the contrary, the socket type of the bone defect has achieved the most efficient bone augmentation. Mean horizontal bone height was 5.6 (range 4.0–7.3) mm and vertical height were 10.7 (7.8–13.7) mm. The major complications were infection, mesh exposure, bone resorption and neurological disturbances. Implant failure also observed. The HV type of bone defect showed significantly higher percentage of mesh exposure.

**Conclusion:** The results demonstrate that autogenous bone graft with titanium mesh has shown enough alveolar bone reconstruction quantitatively and qualitatively for the implant placement. However, the type of bone defect showed the differences. The socket type bone defect shows good results. Several complications will occur, but almost of the trouble are not influence the implant treatment results. Mesh exposure after few weeks of operation could tolerate severe bone resorption; in contrast, early phase of infection or mesh exposure might provoke severe clinical results.

Post operative swelling of the maxillary sinus membrane after the sinus floor augmentation

**Presenter:** Nosaka Y

*Nosaka Oral Surgery Clinic, Ashiya-City, Japan*

**Co-authors:** Nosaka Y<sup>1</sup>, Hamamoto K<sup>1</sup>, Nosaka H<sup>1</sup>, Arai Y<sup>2</sup>

<sup>1</sup>Nosaka Oral Surgery Clinic, Ashiya-City, Japan, <sup>2</sup>Nihon University School of Dentistry, Tokyo, Japan

**Background and aim:** Recently, the cone beam computed tomography (CBCT) has been developed and it has an advantage not only in clear picture quality, but low dose of exposure to radiation by the patients. The aim of present clinical study was designed to evaluate the complication of the post-operative swelling of the maxillary sinus membrane which occurs within 1 week after the maxillary sinus floor augmentation.

**Materials and methods:** Maxillary sinus floor augmentations were performed using  $\beta$ -tricalcium phosphate ( $\beta$ -TCP) alone in 49 sites of 43 cases. The CBCT was taken before the surgery, immediately after, 1 week after and every 3 months after the surgery. The degrees of the post-operative swelling of the maxillary sinus were classified into three categories.

Class 1: the swelling  $< 1/3$  of the remaining sinus cavity

Class 2: the swelling between  $1/3$  and  $2/3$  of the remaining sinus cavity

Class 3: the swelling  $> 2/3$  of the remaining sinus cavity

**Results:** One week after the surgery, swelling of the sinus membrane was observed in 49 sites (100%) of 43 cases (100%). In 47 sites (95.9%) of 41 cases (95.3%), the swelling had disappeared within 3 months after the surgery. The results of the post-operative swelling of the maxillary sinus were Class 1: 9 sites (18.4%), Class 2: 22 sites (44.9%) and Class 3: 18 sites (36.7%). In 18 sites (36.7%) of 15 cases (34.9%), the lateral window was covered with only the mucoperiosteal flap. In these cases, the granules of  $\beta$ -TCP flowed out through the lateral window toward the buccal side of the alveolar bone in 11 sites (61.1%) of 10 cases (66.7%) and the loss of volume was observed in the augmented area. In 31 sites (63.3%) of 28 cases (65.1%), the lateral window was covered completely with the barrier membrane or the titanium mesh. In these cases, the outflow of the granules of  $\beta$ -TCP was observed in only two sites (6.5%) of two cases (7.1%).

**Conclusion:** The most important complication of the post-operative swelling of the sinus membrane was the outflow of the granules of  $\beta$ -TCP which caused the loss of volume in the augmented area. It was suggested that the lateral window must be covered completely to avoid the outflow of the bone materials.



## Flapless transalveolar osteotome sinus floor elevation with simultaneous implantation without graft material: secondary implant stability

**Presenter:** Atamni F

*Clinic of Oral Surgery and Implantology, Chisinau, Moldova*

**Co-authors:** Topalo V<sup>1</sup>, Atamni F<sup>2</sup>, Palarie V<sup>1</sup>, Atamna M<sup>2</sup>

<sup>1</sup>State University of Medicine and Pharmacy, Chisinau, Moldova,

<sup>2</sup>Clinic Oral Surgery and Implantology, Tel-Aviv, Israel

**Background and aim:** Implant placement in the posterior atrophied maxilla is a challenging procedure. The sinus floor (SF) augmentation with a lateral access is the most commonly used technique. In contrast to the more invasive lateral approach, Summers proposed elevation of SF through transalveolar approach with graft materials using flap surgery. Our goal is to evaluate secondary stability (SS) of the implants inserted through flapless transalveolar SF elevation without grafting materials.

**Materials and methods:** Fifty patients had been treated between September 2005 and August 2008 with 70 screw type SLA implants with a torque of 40–45 Ncm (study group). The residual bone height was 5–10 mm. The implants length was 8–13 mm and diameter was 3.75–6 mm. The transalveolar elevation of the SF was performed by flapless technique and without bone grafting. Bone quality was evaluated during surgery and implant sites were underprepared to achieve maximum primary stability. Elevation was performed with only one osteotome. The diameter of the osteotome was similar with the implant apex part. The second stage was performed no < 6 months of implant insertion. Reference group includes 30 patients with simultaneous insertion of 88 screw type SLA implants through lateral access. The torque was similar to the study group. The implants length was 11.5–16 mm and diameter was 3.75–6 mm. The residual bone height was similar to the study group. SS of the implants in both groups was measured with the Periotest.

**Results:** In the reference group 2 implants were loosened during healing period. Periotest mean value for the SS of the implants from the study group was – 4.6. In the reference group the medium secondary stability was – 4.7. There is no significant statistical difference of the SS in both groups (Student's *t*-test = 0.3584; *P* > 0.05). The survival rate for the implants from the study group was 98.5% and 97.7% for the reference group.

**Conclusion:** The flapless transalveolar sinus floor elevation with osteotomy technique and simultaneous implant insertion without graft materials allows high implant SS similar to the simultaneous implant insertion through lateral sinus window approach and bone augmentation with xenografts.

## Histological analysis of anorganic bovine bone in augmentation procedures: a systematic review of prospective studies

**Presenter:** Clementini M

*Università Tor Vergata-Roma-, Rome, Italy*

**Co-authors:** Clementini M, Pegna F, Agrestini C, Barlattani A

*Università Tor Vergata, Rome, Italy*

**Background and aim:** Anorganic bovine bone (ABB) has been shown to have osteoconductive properties and no inflammatory or adverse responses as grafting materials used in sinus augmentation or alveolar ridge augmentation procedures. The purpose of the present study was to analyze the histologic and histomorphometric features of ABB to assess the degree of resorption of the graft material and replacement by new vital bone.

**Materials and methods:** All prospective studies in which guided bone regeneration as well as sinus floor elevation was performed by means of ABB, were analyzed. A systematic review included studies in which histologic and histomorphometric analysis of the new vital bone and the residual ABB particles was conducted. Biopsy had to be performed at least 6 months after grafting. Results of separated data of ABB alone and ABB with autogenous bone were included.

**Results:** From 1372 articles reviewed, 42 titles were screened and only 14 full-text publications were identified as fulfilling the inclusion criteria. In all studies the investigation was carried out analyzing a 30 µm specimen for histologic and histomorphometric analysis through the optical or electron microscopy. The percentages reported on the biopsy performed between 6 and 20 months (mean: 13 months) after grafting show that the volume occupied by newly formed bone varied from 12.44% to 38% (mean: 24.4%) and the volume occupied by the residual ABB particles varied from 70.2% to 11% (mean: 32.77%).

**Conclusion:** Within the limits of this study there was evidence that the ABB takes part in the remodelling process. The long-lasting presence of the ABB particles could be explained by a bonding mechanism that maintains the biomechanical integrity of the bone-biomaterial interface during the remodelling processes. The ABB appeared to be osteoconductive and to support new bone formation in augmentation procedures to facilitate the placement of implants in areas with insufficient bone quantity.

## Multidisciplinary treatment solutions by the help of dental implants in a maxillofacial traumatized patient with an excessive bone loss: case report

**Presenter:** Sezer B

*Oral Surgery, Izmir, Turkey*

**Co-authors:** Sezer B<sup>1</sup>, Gunbay T<sup>1</sup>, Saracoglu A<sup>2</sup>

<sup>1</sup>Department of Oral and Maxillofacial Surgery, Faculty of Dentistry, Ege University, Izmir, Turkey, <sup>2</sup>Department of Prosthetic Dentistry, Faculty of Dentistry, Ege University, Izmir, Turkey

**Background and aim:** The aim of this report is to describe a significantly deficient case of alveolar bones that were managed

by alveolar bone augmentation using a technique of distraction osteogenesis and onlay bone grafting before dental implant placement.

**Materials and methods:** A 26-year-old female presented with a complaint of poor esthetics resulting from oral injuries incurred in an accident 13 years previously. In addition to a mandibular parasymphiseal fracture, seven mandibular, five maxillary anterior teeth and the most of the alveolar ridge were lost. Clinical examination revealed severe loss of bone in the mandibular anterior region, an absence of a labial sulcus, loss of lower lip support, and a slight over eruption of the mandibular anterior teeth. In preparation for dental implants a distraction osteogenesis surgical procedure and augmentation was done to lengthen the height of the alveolar ridges. After a 4-month healing period, the width of the residual ridge was found to be insufficient for implant placement. To correct this deficiency, a bone graft used to the labial aspect of the ridges. The patient was then appropriately medicated and healing was uneventful.

**Results:** After 3 months, the width of the residual ridge was assessed to be adequate for endosseous implants. The prosthetic treatment achieved created the overjet and overbite with a significant improvement in esthetics acceptable to the patient.

**Conclusion:** Injury to the teeth and alveolar ridge of the anterior region can cause a severe alveolar ridge deficiency resulting in ridge atrophy and maxillary retrognathism. The loss of these teeth and alveolar bone together with fibrotic scar formation can result in adverse changes of the interarch space, occlusal plane, arch relationship, and arch form which complicates rehabilitation and can compromise the esthetic outcome. While implant dentistry has become a new paradigm in oral reconstruction and replacement of missing teeth, ideal implant positioning can be compromised by inadequate alveolar bone. In terms of bone, height, width, and quality of the bone itself. Correction of osseous deficiencies with ridge augmentation allows ideal implant placement and creates a more natural soft tissue profile which influences crown anatomy and esthetics.

274 | Poster – Topic Tissue Augmentation and Tissue Engineering

## The osteoinductive effects of rhBMP-2 coated pure titanium implant surfaces

**Presenter:** Kung S

*Chang Gung Memorial Hospital, Kweisan, Taoyuan, Taiwan*

**Co-authors:** Kung S<sup>1</sup>, Hsieh Y<sup>2</sup>

<sup>1</sup>*Chang Gung Memorial Hospital, Taoyuan, Taiwan,* <sup>2</sup>*Kaohsiung Veterans General Hospital, Kaohsiung, Taiwan*

**Background and aim:** Recombinant human bone morphogenic protein type 2 (rhBMP-2) is proved to have the capability to induce new bone formation. The purpose of this study was to evaluate the effects of rhBMP-2 on ectopic bone formation when coating on pure titanium implant surfaces.

**Materials and methods:** Preparation with different concentration of rhBMP-2 (0.5, 1.5 and 5 µg) were absorbed onto collagen type I membranes; these were used to wrap onto pure titanium implants, and then embedded into the subperiosteum area on

the back of Sprague–Dawley rats. The negative control group consisted of implants coated with plain collagen type I membranes. Three weeks after implantation, titanium implants and surrounding tissues were retrieved and processed by whole mount staining with alizarin red and alcian blue to examine the evidence of osseous tissue or chondrous tissue formation respectively. The newly formed structures in the BMP groups were further identified by Toluidine blue staining, and immunohistochemical staining with osteopontin and alkaline phosphatase. The bone formation parameters (trabecular bone surface, trabecular bone volume and mean trabecular thickness) of the new bone were measured and compared between the test groups.

**Results:** Bone formation on pure titanium implant surfaces in BMP groups was identified and a positive dose-dependent relationship appeared in this osteoinduction process. Meanwhile, endochondrous bone formation process, identified by alcian blue stain, was also observed on titanium implant surfaces.

**Conclusion:** A dose-dependent osteoinductive potential of BMP-2-coated titanium implants was evident in ectopic sites of experimental rats. However, chondrogenesis in the process cannot be overlooked.

275 | Poster – Topic Tissue Augmentation and Tissue Engineering

## Bone quality of the particulate cancellous bone and marrow reconstructed mandible

**Presenter:** Matsuo A

*Tokyo Medical University, Tokyo, Japan*

**Co-authors:** Matsuo A<sup>1</sup>, Chiba H<sup>1</sup>, Takahashi H<sup>1</sup>, Toyoda J<sup>1</sup>, Hasegawa O<sup>1</sup>, Arisaka R<sup>1</sup>, Hojo S<sup>2</sup>

<sup>1</sup>*Tokyo Medical University, Tokyo, Japan,* <sup>2</sup>*Kanagawa Dental College, Kanagawa, Japan*

**Background and aim:** Particulate cancellous bone and marrow (PCBM) combined with mesh tray can be highly effective for mandibular reconstruction, because it is easily achieve a suitable contour to perform the osseointegrated implant. However, our previous report suggested that X-ray opacity and CT value of this method were lower than that of native bone even after 1 year of surgery. Although, many studies have reported the quality of various type of grafted bone of the small defects for implant, quality of PCBM reconstructed bone of the large defect have not precisely evaluated yet. For this purpose, we performed standardized bone biopsy of the alveolar bone with a trephine bur from the implant insertion area of the PCBM reconstructed and native mandible. CT value using clinical CT, bone microstructures and bone mineral density (BMD) using micro-CT were compared between these two groups.

**Materials and methods:** Fourteen samples (seven cases) of PCBM, Platelet rich plasma and mesh tray reconstructed mandible (PCBM group), and 16 samples (10 cases) of native mandibular bone (native group) were served for this study.

**Methods:** All specimens were harvested by inner diameter 2.8 mm trephine bur, subsequently osseointegrated implants were inserted at the site. Hounsfield unit (HU) of clinical CT data before surgery were measured (SIM/PLANT: Materialize

Dental). Bone samples were scanned using micro-CT, and microstructures of the cancellous bone were measured (TRI-3D BON Latoc. Co. Ltd., Japan), BMD were also calculated in 13 samples (six cases), six samples (six cases). Osseointegration of implant were evaluated at the second operation.

**Results:** Although, compact bone was thinner and H.U. was lower in PCBM group than that of native group on clinical CT, almost microstructural parameters and BMD were as equivalent degree in PCBM group as native group. Osseointegration rate was 100% in both groups.

**Conclusion:** Well bone quality of the cancellous bone may be contributed to the osseointegration of the implant in the PCBM reconstructed bone.

276 | Poster – Topic Tissue Augmentation and Tissue Engineering

### The use of recombinant human bone morphogenic proteins in maxillary sinus augmentation: a case report

**Presenter:** Patel R

*School of Dentistry, Loma Linda University, Loma Linda, CA, USA*

**Co-authors:** Patel R, Lozada J, Kan J, Kleinman A

*School of Dentistry, Loma Linda University, Loma Linda, CA, US*

**Background and aim:** The purpose of this poster presentation is to provide a thorough review of the literature on the indication and applications of recombinant human bone morphogenic protein (rh-BMP2) in the augmentation of the maxillary sinuses prior to implant placement. The background will review the evolution of BMP's in implant dentistry and outline their use in modern surgical bone augmentation techniques. Further, the importance of the different carrier materials will be emphasized.

**Materials and methods:** There will be case presentation of a patient that underwent maxillary sinus augmentation presented. The patient was treated with the use of rh-BMP2 (INFUSE<sup>®</sup>, Medtronic, Minneapolis, MN). The patient was treated with a split-mouth design to compare new bone formation compared with conventional grafting techniques using a combination of allograft (Puros<sup>®</sup>, Zimmer dental, Warsaw, IN, USA) and xenograft (Bio-Oss<sup>®</sup>, Osteohealth, Shirley, NY, USA). Core samples were taken following 6 months of healing concurrent with implant placement. The core samples were analyzed histomorphometrically and radiographically using cone beam computerized tomography (i-CAT<sup>®</sup>, Imaging Sciences International, Hatfield, PA, USA).

**Results:** The samples are presently being evaluated histomorphometrically and the data will be available for presentation.

**Conclusion:** Following an evaluation of the histomorphometry, the new bone formation with the use of rh-BMP2 will be compared with the conventional grafting materials and conclusions will be drawn on the efficacy of rh-BMP2 and potential advantages and limitations of tissue growth factors.

277 | Poster – Topic Tissue Augmentation and Tissue Engineering

### Complication management of early barrier exposure associated with implant placement in esthetic zone

**Presenter:** Mohseni Salehimonfared SH

*Tehran University of Medical Science, Tehran, Iran*

**Co-authors:** Mohseni Salehimonfared SH<sup>1</sup>, Dibaji H<sup>2</sup>

*<sup>1</sup>Tehran University of Medical Science, Tehran, Iran, <sup>2</sup>Private Practice, Tehran, Iran*

**Background and aim:** Early membrane exposure is a common problem in GBR. The purpose of this report is to present a technique to deal with barrier exposure complications associated with implant placement.

**Materials and methods:** An 18-year-old girl presented with localized advanced periodontal disease on tooth # 9. GBR technique was performed following extraction utilizing non-absorbable membrane with titanium screw under membrane (tent formation) to create space for bone generation. After 10 days membrane became exposed. The membrane was kept for 4 weeks by three weekly office visit in addition to home care of cleaning the site with 0.2% CHX. After 4 weeks partial thickness flap utilized to remove the membrane carefully and placed a connective tissue graft to cover and protect the newly formed tissue under the membrane. An implant was placed 7 months after membrane removal. Then prosthetic implant completed.

**Results:** Complications associated with an early barrier can be managed with CHX in home and office to clean the membrane and site for 5 weeks until newly formed tissue mature, then a connective tissue graft restored soft tissue demand of the esthetic zone before implant placement.

**Conclusion:** Barrier exposure does not mean treatment failure. This report shows that ridge augmentation in the presence of early barrier exposure possible by frequent office visit to de plaque the site, by employing timely GBR and CTG technique and by allowing sufficient healing period we can achieved a satisfactory soft and hard tissue result.

278 | Poster – Topic Tissue Augmentation and Tissue Engineering

### Genes expression during osseointegration after various surface-treated dental implant installation

**Presenter:** Lee DW

*Dental Hospital, East-West Neo Medical Center, Kyung-Hee University, Seoul, Korea*

**Co-authors:** Lee DW, Jee YJ, Ryu DM, Kim JH

*Dental Hospital, East-West Neo Medical Center, Kyung-Hee University, Seoul, Korea*

**Background and aim:** The present study was performed to examine the genes expression during osseointegration of dental implant. Machined, resorbable blast media (RBM), oxidized surface-treated implants were used in this study. This three different surface-treated implants (5 mm in length, 3 mm in diameter, Osstem, Korea) were placed in the tibia of the rabbit. In the control group, the only bone defect was made.

**Materials and methods:** The rabbits were sacrificed for histomorphometric evaluation and GeneFishing analysis at 1, 2, 6 weeks after placement.

**Results:** In histomorphometric evaluation with the measurement of BIC (bone-implant contact ratio) and BA (bone area ratio), RBM surface implant was highest value in both BIC and BA, and machined surface implant was lowest score. In GeneFishing<sup>TM</sup> screening analysis, 52 DEGs (differentially expressed genes) was expressed in 1 week group and 50 DEGs in 2 weeks group. This result suggest that implant surface treatment modulate the gene expression of bone tissue around dental implant. And then, direct sequencing and BLAST of eight DEGs had performed. One DEGs, expressed in oxidized surface only, was identified the Rabbit hsp90-binding protein (p59). Six DEGs was the unknown genes, one DEGs was EST (expressed sequence tag).

**Conclusion:** These results suggest that p59 protein is concerned in osseointegration of oxidized surfaced implant, and many unknown genes are related osseointegration of dental implant.

279	Poster – Topic Tissue Augmentation and Tissue Engineering
-----	---

### Micro-CT based quantification of bone-regeneration achieved with beta-TCP/collagen composite

**Presenter:** Ata F

*Showa University, Tokyo, Japan*

**Co-authors:** Ata F<sup>1</sup>, Yamaki K<sup>1</sup>, Kataoka Y<sup>1</sup>, Miyazaki T<sup>1</sup>, Miyazaki T<sup>1</sup>

<sup>1</sup>Department of Oral Biomaterials and Technology, Showa University School of Dentistry, Tokyo, Japan, <sup>2</sup>Department of Oral and Maxillofacial Surgery, Machida Municipal Hospital, Kanagawa, Japan

**Background and aim:** Nano  $\beta$ -TCP reinforced collagen scaffold that is naturally synthesized and needs no additional treatments has been developed for bone regeneration in our latest study. Of particular importance is the spatial distribution and accurately quantification of bone-regeneration achieved with the implanted scaffold as this provides a direct mean for assessing of this clinical advantage. Micro-computed tomography (micro-CT) is a non-destructive X-ray imaging strategy that has been used to characterize natural bone quality. The authors expected that the three-dimensional data sets obtained using micro-CT provide more accurate information on the regenerated bone structure compared with typical two-dimensional methods, such as histology and scanning electron microscopy. This study aimed to evaluate an *in vivo* scaffold property of  $\beta$ -TCP/collagen by means of the micro-CT analysis.

**Materials and methods:** The authors previously reported that colloidal alkaline nano calcium phosphates can be prepared by discharge in physiological buffered solutions. Briefly, a platinum foil was used as the power supply cathode and a platinum foil as the counter electrode. Each foil was immersed in 100ml of modified simulated body fluid. Subsequently, discharging was maintained at 2.5 A and 100 V for 270 s. Alkaline colloidal  $\beta$ -TCP were prepared by removal of supernatants. Twelve-week-old male Wistar rats were used. Under anesthesia, the periosteum of the calvarium was ablated and a full-thickness standardized trephine defect, 9 mm in diameter, was made in the

calvarium. Those rats in each of the  $\beta$ -TCP/collagen and untreated groups were scanned the defect by micro-CT at 4 weeks after implantation.

**Results:** After 4 weeks implantations, the micro-CT image of  $\beta$ -TCP/collagen group was amalgamated radiopacity condensed. In control group the image was not radiopacity, the same as that before implantation.

**Conclusion:**  $\beta$ -TCP/collagen showed considerable scaffold property as bone regeneration materials.

280	Poster – Topic Tissue Augmentation and Tissue Engineering
-----	---

### Histologic study of absorbable atelocollagen sponge on healing of a fresh extraction socket in the mongrel dog

**Presenter:** Lee JW

*College of Dentistry, Chosun University, Kwang-ju, Korea*

**Co-authors:** Lee JW, Moon SS, Jang Hs, Kim Bo

*Chosun University, Kwang-ju, Korea*

**Background and aim:** Extraction socket is absorbed with time. These days, techniques to preserve the socket at the same time of extraction before restoring the edentulous region with implants are reported. The purpose of this study was to evaluate the influence on healing of fresh extraction socket of Mongrel dog.

**Materials and methods:** In this experiment, eight dogs were used. After sectioning two mandibular premolars then we carefully extracted them. Experimental parts were randomly selected and divided into two groups. Group 1: atelocollagen sponge was used with buccal bone defect, Group 2: without using atelocollagen sponge with buccal bone defect. Buccal bone of extraction socket was prepared by 2/3 of the length of the socket. Dogs were sacrificed in 1, 4, 6 and 10 weeks and they were histologically evaluated.

**Results:** Newly formed bone was detected in both Groups 1 and 2 in 4 weeks. In this period of time, newly formed bone was more mature on apical part in Group 1. The amount of newly formed bone was relatively much more in Group 1 than in Group 2. The extraction socket of Group 2 was distinct while it was difficult to distinguish extraction socket from surrounding bone in Group 1. New bone formation was proceeded in 6 weeks of the surgery and more amount of the formation was detected in Group 1 than that of in Group 2. Bone remodeling process was observed in 10 weeks of the surgery and this phenomenon appeared in both Group 1 and 2. There were Morphologic differences of extraction socket in this period time; Group 1 was healed as 'dome-shaped ceiling' and Group 2 was occupied with newly formed bone.

**Conclusion:** In this limited study, placing absorbable atelocollagen sponge in fresh extraction socket facilitates new bone formation and it especially reconstructs the peripheral bone so that it would be an adequate material for healing on extraction socket. In the future, it will be considered to require histometrical study to evaluate the promotion on the amount of newly formed bone.

Bone formation after sinus floor elevation using Straumann® boneceramic with or without autogenous bone in humans

**Presenter:** Kirmeier R

*Medical University of Graz, Graz, Austria*

**Co-authors:** Kirmeier R<sup>1</sup>, Payer M<sup>1</sup>, Clar V<sup>2</sup>, Bosshardt D<sup>3</sup>, Wegscheider W<sup>2</sup>, Jakse N<sup>1</sup>

<sup>1</sup>Department of Oral Surgery and Radiology, School of Dentistry, Medical University of Graz, Graz, Austria, <sup>2</sup>Department of Prosthodontics, Graz, Austria, <sup>3</sup>Department of Periodontology, Department of Oral Surgery & Stomatology, School of Dental Medicine Switzerland, University of Bern, Bern, Switzerland

**Background and aim:** Sinus floor augmentation using bone substitutes is a highly successful and predictable procedure to increase bone volume for implant placement in the posterior region of the severely atrophic maxilla. The aim of this preliminary randomised controlled clinical trial was to obtain histological and morphometrical information on the amount of newly formed bone in the grafted areas augmented either with a blend of HA and TCP (Straumann® BoneCeramic, Straumann AG, Basel) exclusively or to a compound of Straumann® BoneCeramic and autogenous bone.

**Materials and methods:** Eight patients, seven females and one male, with a mean age of 52 years (range 39–72 years) requiring bilateral sinus floor elevations were included in this study. In a two-stage technique each patient was randomly grafted on one side with the bone substitute alone and on the contra-lateral side with a combination (60:40 ratio) of the bone substitute and autogenous bone chips harvested from the external oblique line. At 4 and 6 months a cylindrical bone sample of the augmented tissue was harvested from each augmentation site by a trephine bur (2.2 mm internal diameter) exactly in the region of the intended implant positions. All 16 biopsies were fixed in 4% formalin and undecalcified ground sections were used for histologic and morphometric analyses. Parameters assessed were (1) percentages of new bone, graft materials, and soft tissue; and (2) the percentage of surface contact between the graft substitute and new bone.

**Results:** On both sides expedient newly formed bone could be generated in the posterior atrophic maxilla after 6 months of healing. Histomorphometrically, the amount of new bone decreased from the residual ridge toward deeper grafting regions for all treatment modalities. For the whole grafted area after 4 months bone substitute alone revealed the lowest amount of new bone and the lowest surface contact between graft substitute and new bone. The addition of autogenous bone increased the amount of new bone and surface contact after an interval of 4 months. For all treatment modalities, most new bone and highest surface contact was found close to the residual ridge. The percentage of new bone in this area reached 40%.

**Conclusion:** Each of the sinuses in this study showed an adequate amount of bone to accommodate implants for fixed prosthetic reconstruction. Straumann® BoneCeramic benefits from mixtures with autogenous bone, which might function as an inductive vehicle and lowers thereby the healing time.

Long-term stability of dental implants in grafted bone with torus mandibularis

**Presenter:** Sato T

*School of Medicine Keio University, Shinjyuku-ku, Japan*

**Co-authors:** Sato T<sup>1</sup>, Kawana H<sup>1</sup>, Nakagawa T<sup>1</sup>, Asanami S<sup>2</sup>

<sup>1</sup>School of Medicine, Keio University, Tokyo Japan, <sup>2</sup>International University of Health and Welfare, Mita Hospital, Tokyo, Japan

**Background and aim:** Thinking about the autogenous bone materials for reconstruction of the alveolar ridge before dental implant placement, there are many reports using the mandibular symphysis or the ramus or the iliac bone. But, using the torus mandibularis is very rare. We performed alveolar ridge reconstruction using the torus mandibularis before dental implant placement or simultaneously. And we evaluate the long-term stability of these dental implants.

**Materials and methods:** Three patients were received alveolar ridge reconstruction using harvested bone from torus mandibularis. The detail were one patient had onlay graft, second patient had veneer graft and last patient had inlay graft (sinus-lift).

**Results:** All alveolar ridge reconstruction were success and also all implants were successfully osseointegration. The complications like bleeding, uncontrollable pain and nerve disturbance were not seen in all patients at both the donor site and the recipient site after early post-operation. The radiographic evaluation of bone level of around implants are stable for 24 to 96 months follow-up.

**Conclusion:** Torus mandibularis is good bone-grafting material for patients who required alveolar ridge reconstruction. And, it can lead to long-term stability.

Implantation of irradiated and distracted microvascular bone graft after resection of osteosarcoma

**Presenter:** Vähätalo K

*Private Practice/KirPartner Oy, Turku, Finland*

**Co-authors:** Kimmo V<sup>1</sup>, Juhani L<sup>2</sup>, Kalle A<sup>2</sup>

<sup>1</sup>Private Practice, Turku, Finland, <sup>2</sup>Turku University Central Hospital, Turku, Finland

**Background and aim:** Distraction osteogenesis (DO) is one of the alternatives in vertical bone augmentation. We describe an application of DO in a complicated case where microvascular iliac crest bone graft was distracted after high dose irradiation and implants were inserted in the irradiated, distracted bone graft.

**Materials and methods:** A 40-year old man with minor symptoms was referred for further examination because of hard labial bone expansion (size 25 × 30 mm) in anterior mandible. Biopsy indicated chondroblastic osteosarcoma, grade II. Tumour was resected and continuity defect was reconstructed with microvascular iliac crest bone and muscle graft. Tumour-free margins were inadequate and additional radiotherapy (64 Gy) was given. One year after uneventful healing, the irradiated bone graft was

distracted to increase bone height and to optimize bone position. Hyperbaric oxygen treatment (20 + 10 sessions) was used during distraction. The distractor was removed after 6 months consolidation. Additional 3 months healing was allowed before implantation with four Straumann 4.1 screw implants using a one-stage procedure. Two of the fixtures were inserted in the area of irradiated, distracted graft.

**Results:** All implants osseointegrated. Prosthetic loading was started 5 months after implant insertion with fixed bridge. After 3-years follow-up, the functional and aesthetic outcome is acceptable and marginal bone level has remained stable.

**Conclusion:** Distraction osteogenesis and vertical bone augmentation seems to be possible also in irradiated bone. Before this can be recommended further clinical studies are needed.

#### 284 Poster – Topic Tissue Augmentation and Tissue Engineering

### Middle term outcome of bone allograft as an alternative therapy in maxillary augmentation procedures

**Presenter:** Josep N

*Instituto Mediterraneo de Odontologia e Implantologia, IMOI, Barcelona, Spain*

**Co-authors:** Novell J, Novell-Costa F, Ivorra C, Martinez C, Munilla A, Jimenez MJ, Pascual N, Novell F

*Instituto Mediterraneo De Odontologia E Implantologia, IMOI, Barcelona, Spain*

**Background and aim:** Successful bone grafting requires that the clinician select the optimal bone grafting material and surgical technique from among a number of alternatives. In cases of severe resorbed ridge autologous bone graft from cranium or iliac crest are the gold standard. Those procedures have an important morbidity and uncomfortable postop for patients. We introduce the same surgical approach and method of bone grafting reducing the morbidity using bone allograft (bone bank).

**Materials and methods:** From July 2006 to January 2009 a total of 14 augmentation procedures have accomplished in 14 patients. Age range were 56 years old. Eight cases in women, the rest in men. Nine cases in maxilla and five cases in mandibular bone. All the surgeries were performed under local anesthesia and conscious sedation by two trained surgeons. Skull calotte allograft was performed in all the patients. After cutting the bone, titanium screws (1.2 mm, diametre) were used to fix the graft. Dental implants were inserted after 4–6 months of osseointegration of the graft.

**Results:** From those 14 surgical procedures only one of them, in upper maxillary, had a problem of bone exposition. The rest of the cases had a normal postop. No importan reabsortion were found in the grafts. Implants were performed at 4 months in 10 patients and 6 months in the other four cases. A total of 82 implants were inserted in bone allografts. Patients posoperative conditions were comfortable, similar to implant procedures. Two years follow-up is achieved in three patients without abnormalities. Mean time of follow-up of the other patients were from 3 months to 19 months.

**Conclusion:** Bone allograft (bone bank) is a less traumatic surgical procedure in augmentation cases. Avoid the donor area morbidity and reduces surgical time. No general anesthesia is required. Longer follow-up is needed to become an elective surgical technique.

#### 285 Poster – Topic Tissue Augmentation and Tissue Engineering

### Preservation of the post-extraction alveolar ridge in the molar maxillary areas in humans: histological and histomorphometrical evaluations

**Presenter:** Canullo L

*Private Practice, Rome, Italy*

**Co-authors:** Dellavia C<sup>1</sup>, Canullo L<sup>2</sup>, Pellegrini G<sup>3</sup>, Rasperini G<sup>3</sup>

<sup>1</sup>Department of Human Morphology and Biomedical Sciences, Città Studi, Milan, Italy, <sup>2</sup>Private Practice, Roma, Italy, <sup>3</sup>Unit of Periodontology, Dental Clinic, Department of Surgical Sciences, Reconstructive and Diagnostic, University of Milan, Fondazione IRCCS Ospedale Maggiore Policlinico, Mangiagalli e Regina, Milan, Italy

**Background and aim:** After tooth extraction, the alveolar ridge preservation is important for implant placement, aesthetic and functional reconstruction. Placement bone substitute in post extractive alveolar socket serves the purpose to stabilize the wound healing, avoid the bucco-lingual shrinkage and overlying soft tissue collapse, provide a scaffold for new bone formation and carry osteoinductive proteins. The aim of this study is to evaluate at 3, 6 and 9 month (i) the healing of Bio-Oss Collagen augmented maxillary posterior extraction sockets, covered with Bio-Gide membrane, (ii) the amount of newly formed bone.

**Materials and methods:** Three patients that needed the extraction of a maxillary molar, were included in the study. After surgery, the alveolar defects were augmented with Bio-Oss Collagen and covered with collagen membrane. Osteotomy for implant insertion was performed at 3, 6 and 9 months. A bone core, 2 × 1 mm, was retrieved from the center of each grafted socket by means of a trephine bur, and processed for undecalcified histology. Staining was performed with toluidine blue/pyronine G (Sigma-Aldrich, St Louis, MO, USA). The sections were view, photographed in a Nikon light microscope (Eclipse E600) equipped with a calibrated digital camera (DXM1200, Nikon, Tokyo, Japan). Histomorphometric analyses were performed by stereologic method.

**Results:** By 3 months Bio-Oss particles were surrounded by cellular connective tissue. Implanted material displayed resorption areas with osteoclast-like cells. Minimal amount of newly formed bone was detectable. Mean bone density was 2.77%, residual Bio-Oss Collagen amounted to 43.75%, and connective tissue was 53.48%. At 6 months a reduced amount of Bio-Oss particles remained surrounded by newly formed bone and connective tissue, no ongoing resorptive activity was observed. The harvested cylinder was comprised of 44.42% new bone, 12.5% grafted Bio-oss Collagen and 43.08% connective tissue/marrow spaces. At 9 month newly formed bone tissue was mainly organized in lamellar shape. Small amount of woven bone was detectable. Bio-Oss Collagen remnants overall the sample were surrounded by new bone and provisional matrix; no resorption areas were evident. Regenerated bone occupied 47.17% of the total area, Bio-Oss Collagen remnants 17.4% and connective tissue/marrow 35.43%.

**Conclusion:** At the observation, the augmented alveolar healing process appeared delayed. Bio-Oss Collagen is a biocompatible

material, adapted for bone augmentation procedures. However after 9 month of healing, remnants particles are still detectable, partially immersed in newly formed lamellar bone and connective tissue, confirming the extended remodeling time. In agreement with previous studies, Bio-Oss does not show bone promoting capacity. As confirmed by previous studies, the clinical advantage of Bio-Oss collagen grafting is mainly the space maintaining activity.

**286 | Poster – Topic Tissue Augmentation and Tissue Engineering**

### Experimentally induced osteogenic differentiation of human fibroblasts

**Presenter: Lorincz A**

*Semmelweis University, Budapest, Hungary*

**Co-authors: Lorincz A<sup>1</sup>, Bogdán S<sup>1</sup>, Király M<sup>2</sup>, Varga G<sup>2</sup>**

*<sup>1</sup>Department of Oral and Maxillofacial Surgery, Semmelweis University, Budapest, Hungary, <sup>2</sup>Department of Oral Biology, Semmelweis University, Budapest, Hungary*

**Background and aim:** The aim of the poster is to present the effects of certain substances on the osteogenic differentiation of human fibroblasts.

**Materials and methods:** Human fibroblasts derived from a primary human culture of cells obtained from surgically excised submandibular glands were cultured in various media and their osteogenic differentiation was compared. Media were supplemented with vitamin D<sub>3</sub>, PTH and various growth factors. Differentiation in an osteoblast-like direction was assessed using alizarine red staining, immunocytochemistry and the study of the expression of certain OCN, BSP, Runx2, etc.

**Results:** Significant differences were found between the various groups and the negative control as to the speed and effectiveness of osteogenic differentiation.

**Conclusion:** Based on the present research the development of more effective, osteoinductive bone grating materials becomes possible.

**287 | Poster – Topic Tissue Augmentation and Tissue Engineering**

### Capacity of bone differentiation of dental pulps stem cells: comparison of three differentiation media

**Presenter: Rodriguez FJ**

*University of Murcia, Molina de Segura Murcia, Spain*

**Co-authors: Rodriguez FJ<sup>1</sup>, Blanquer M<sup>1</sup>, Meseguer L<sup>1</sup>, García de Insausti C<sup>1</sup>, Bleda P<sup>1</sup>, Iniesta F<sup>1</sup>, Majado MJ<sup>1</sup>, Oñate RE<sup>1</sup>, Martínez S<sup>2</sup>, Moraleda JM<sup>1</sup>**

*<sup>1</sup>University of Murcia, Murcia, Spain, <sup>2</sup>Institute of Neuroscience/University Miguel, Hernandez, Alicante, Spain*

**Background and aim:** The literature affirms that human post-natal dental pulp stem cells have the ability to differentiate to osteoblasts. We propose is differentiate the human postnatal dental pulp stem cells with three different medium and compare their capacity.

**Materials and methods:** Human dental pulp was extracted from teeth of healthy adult subjects aged 21–45 years. The pulp was

gently removed and immersed in a digestive solution for 1 h at 37°C. After digestion, cells were placed in three flasks with different mediums. Medium 1: Medium Osteodiff (miltényi); Medium 2: Eagle's alpha minimal essential medium, 15% fetal bovine serum, Lenexa, KS, USA), and antibiotics (100 U/ml penicillin, 0.1 mg/ml streptomycin, and 0.25 lg/ml. Amphotericin B; Sigma Chemical Co., St. Louis, MO, USA). Medium 3: a-MEM medium, added with 20% FBS, 100 mM 2P-ascorbic acid, 2 mM L-glutamine, 100 U/ml penicillin, 100 mg/ml streptomycin. Flasks were incubated at 37°C in a 5% CO<sub>2</sub> and the medium changed twice a week. At 30 day, the mineralization matrix mineralisation was determined with the Alizarin red S dye.

**Results:** After 35 days, DPSCs formed and developed mineralization nodules (clusters), as revealed by Alizarin red staining. This staining was bigger in Medium 1 than Medium 2 and Medium 3.

**Conclusion:** This study demonstrates the ability of stem cells to differentiate into osteoblasts specially with Osteodiff (miltényi).

**288 | Poster – Topic Tissue Augmentation and Tissue Engineering**

### Lateral augmentation using BCP and collagen membranes: morphometric and histomorphometric results

**Presenter: Friedmann A**

*Universitätsmedizin Charité Berlin, Berlin, Germany*

**Co-authors: Friedmann A<sup>1</sup>, Gissel K<sup>1</sup>, Dard M<sup>2</sup>, Dietrich T<sup>3</sup>, Bosshardt D<sup>3</sup>**

*<sup>1</sup>Universitätsmedizin Charité, Berlin, Germany, <sup>2</sup>Institut Straumann AG, Basel, Switzerland, <sup>3</sup>Department of Oral Surgery, Birmingham, UK*

**Background and aim:** Biphasic Calcium Phosphate (BCP) was used for lateral augmentation either combined with cross-linked (CLC) or native collagen (NC) membrane in bone dehiscences at implant placement. Outcome parameters were: morphometric gain in newly mineralized tissue crestal to the defect margins confirming mineralization by histomorphometry.

**Materials and methods:** Impressions using individual plastic trays and sterile A-silicone were taken initially and repeated at every surgery. Complete soft tissue closure was achieved; healing lasted for 6 months. At re-entry flap design was repeated for impression taking. Biopsies were taken from the lateral aspect of augmented areas by a trephine. Non-decalcified sections stained with fuchsin red were quantified by point counting method. Silicone templates were adjusted on alveolar crest on casts, which showed implants in place. Trimming templates parallel to basis of casts determined reference points; casts + templates were sectioned bucco-lingually. Sectioned template was mounted on cast obtained at first surgery. Vertical dimension was measured drawing perpendicular from edge of silicon template to crest middle of cross-sectioned implant. At crossing point with alveolar crest most buccal extension horizontally was reference 0. Reference 1 was 'subcrestally' at level of most pronounced buccal aspect.

**Results:** Histomorphometric evaluation confirmed  $40.35 \pm 8.44\%$  for bone area;  $40.54 \pm 9.34\%$  for soft tissue and  $19.11 \pm 6.76$  for BCP area fraction, respectively. Morphometric alterations under NC membrane resulted in 0.2 mm (IQ: -0.2-1.8) in height and 0.7 mm in width (IQ: -0.0-2.3) at reference 0 and in 2.7 mm (IQ: 0.2-3.0) and in 2.1 mm (IQ: 0.8-3.0), respectively at reference 1. In defects protected by CLC membrane median for reference 0 was 1.1 mm (IQ: 0.8 to 1.9) in height and 1.8 mm in width (IQ 1.0-3.0); reference 1 resulted in medians of 2.5 mm (IQ: 1.4-3.7) and 3.0 mm (IQ: 2.2-3.3), respectively. Statistically significant greater gain in height ( $P=0.463$ ) and width ( $P=0.0359$ ) was revealed by T-Test at reference 0 for combination of BCP and CNC membrane.

**Conclusion:** Histomorphometric scores demonstrated reasonable relationship among area fractions regarding new bone formation, soft tissue compartment and residual grafting material in defects filled with BCP. Grafted defect areas protected by cross-linked collagen membranes resulted in significantly greater gain of mineralized tissue in vertical and horizontal dimension at most coronal point of initially exposed implant surface if compared to outcome in defects protected by membranes out of native collagen.

289 Poster – Topic Tissue Augmentation and Tissue Engineering

Mandibular bone defect regeneration, *in situ* tissue engineering,  $\beta$ -tricalcium phosphate, scaffold

**Presenter:** Hatayama T

*Institute for Frontier Medical Sciences, Kyoto University, Japan*

**Co-authors:** Hatayama T, Nakamura T, Umeda H, Inoue M, Segawa A

*Institute for Frontier Medical Sciences, Kyoto University, Kyoto, Japan*

**Background and aim:** The aim of our study was to evaluate the tissue response and new bone formation induced by  $\beta$ -tricalcium phosphate ( $\beta$ -TCP), collagen, and autologous bone fragments with fibrin glue implanted into a mandibular bone defect.

**Materials and methods:** Granulated  $\beta$ -TCP and collagen from porcine skin were mixed and freeze-dried. The weight ratio of both materials was 98:2. The composite scaffold for bone regeneration was composed of this artificial material and autologous bone fragments. Two adult rabbits were used. A mandibular bone defect ( $2 \times 1$  cm) was created in each rabbit. The animals were divided into two groups. In group 1, the mandibular bone defect was closed by replacing the original free bone flap, and the residual fissure and burr holes were filled with the composite scaffold with fibrin glue. In group 2, the bone defect was closed only by replacing the original free bone flap. Three months after the treatment, computed tomography and histologic examinations were done in two animals.

**Results:** In two rabbits in group 1, the defects were almost closed by new bone; whereas in group 2, the defects were filled with fibrous tissues instead of bone.

**Conclusion:** This study showed that the composite scaffold made of  $\beta$ -TCP, collagen, and autologous bone fragments with

fibrin glue enabled reconstruction of mandible bone defect without the usual fixation materials.

290 Poster – Topic Tissue Augmentation and Tissue Engineering

Effect of emdogain on periodontal tissues in a novel root chamber model: a histomorphometric study in dogs

**Presenter:** Ayhan E

*Primadent, Ankara, Turkey*

**Co-authors:** Ayhan E<sup>1</sup>, Parlar A<sup>2</sup>, Gültekin SE<sup>2</sup>, Sengüven B<sup>2</sup>, Giray B<sup>3</sup>

<sup>1</sup>Primadent Dental Clinic, Ankara, Turkey, <sup>2</sup>University of Gazi,

Ankara, Turkey, <sup>3</sup>University of Hacettepe, Ankara, Turkey

**Background and aim:** The aim of this study is to evaluate the effect of emdogain and emdogain-GTR combination, on the formation of periodontal tissues in a novel root chamber model.

**Materials and methods:** Five female beagle dogs with clinically healthy oral conditions were used in this study. The maxillary canines on both sites of the jaw were experimental area for the preparation of the chambers. The crowns of the canines were cut at the level of gingival margin. The root canal treatments were done. Then mucoperiosteal flaps from buccal and palatal aspects were elevated. A cavity in the root were prepared with a cylindrical bur under saline rinse. The depth of the cavity were approximately 5 mm. There were 10 experimental area totally. Three experimental sites were filled with Emdogain. Three experimental sites were filled with Emdogain and covered with inion GTR membrane. Three experimental sites were covered with inion GTR membrane without using emdogain. The last one experimental site was left empty. After a healing period of 3 months the dogs were sacrificed. The jaw sections of the experimental areas were removed and evaluated under light microscopy.

**Results:** All experimental sites healed uneventfully. In this pilot study, histologically new acellular cementum, periodontal ligament and new alveolar bone formation were observed in emdogain group. In Inion GTR membrane sites there were cellular cementum, periodontal ligament and new alveolar bone formation. Combination of Emdogain-Inion GTR membrane sites healed in the absence of new bone.

**Conclusion:** The goal of the present study was to evaluate the healing response of Emdogain, used to promote the periodontal regeneration. Our histological observations indicated that Emdogain may improve new bone formation. Further studies with greater numbers of experimental sites are needed to evaluate the effect of these materials on periodontal regeneration process.



## Clinical application using injectable tissue-engineered bone for minimally invasive and aesthetic dental implant treatment

**Presenter:** Yamada Y

*Nagoya University, Nagoya, Japan*

**Co-authors:** Yamada Y<sup>1</sup>, Ito K<sup>2</sup>, Nakamura S<sup>2</sup>, Yoshimi R<sup>2</sup>, Hibi H<sup>2</sup>, Baba S<sup>3</sup>, Ueda M<sup>2</sup>

<sup>1</sup>Center for Genetic and Regenerative Medicine, Nagoya University School of Medicine, Nagoya, Japan, <sup>2</sup>Department of Oral and Maxillofacial Surgery, Nagoya University Graduate School of Medicine, Nagoya, Japan, <sup>3</sup>Foundation for Biomedical Research and Innovation, Kobe, Japan

**Background and aim:** Many patients wish more aesthetic treatment of minimal invasiveness (MI) and earlier by immediate function and loading. So we would apply injectable tissue-engineered bone (TEB) and papilla (TEP) by tissue engineering and regenerative medicine (TERM) with earlier bone and papilla regeneration for achievement of them. And we would evaluate about the clinical prognosis on a long-term basis.

**Materials and methods:** It applied in conjunction with the injectable TEB and/or TEP, along with mesenchymal stem cells (MSCs) and platelet-rich plasma (PRP) or extracellular matrix. We applied injectable TEB for periodontal treatments and sinus floor augmentation, vertical and horizontal alveolar ridge augmentation of severe bone resorption with simultaneous implant placement, and TEP for interdental papilla regeneration, and investigated the regenerative bone volume and the stability of regenerated bone.

**Results:** The height of regenerated mineralized tissue for dental implants showed the mean increases of  $8.1 \pm 2.3$  mm compared with preoperative values and the prognosis was stable for 6.5 years follow-up time. And the computed tomography (CT) scans demonstrated that the regenerated bone quality at 6-month after operation was near to nature bone. In addition, black triangle improved by injection of TEP.

**Conclusion:** Injectable TEB and TEP would provide a further option as a graft material with MI and earlier regeneration for dental implant treatment. In addition, TEP would be useful for aesthetic treatment of black triangle and gingival improvement. Furthermore, these technologies would potentially provide a great benefit to patients in dental implant, periodontal treatment, cranio-maxillofacial surgery.

## Bone decoding: proposal for a new fractal analysis

**Presenter:** Sartori M

*S. Apollonia Dental Center, Lazzate, Milan, Italy*

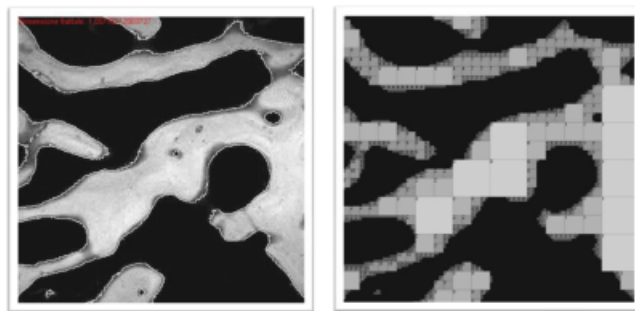
**Co-authors:** Longoni S, Sartori M

*S. Apollonia Dental Center, Lazzate, Milan, Italy*

**Background and aim:** Nowadays many studies show the great role of three-dimensional structure of biomaterials and dental implants in order to promote new bone formation and osseointegration. Companies do not give products that exactly repro-

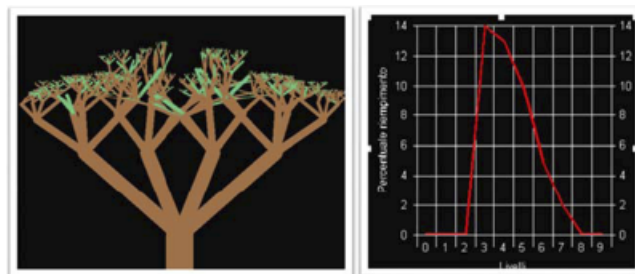
duce bone architecture in order to enhance matching between bone and implants. Usually implants design is based on clinicians experience and engineering rules. The goal should be implants that really mimic bone geometry. This study focused on the natural geometry of human bone. The aim is to present a new method (patent pending) to analyze digital images of tissues and in particular of jaw bones.

**Materials and methods:** Thirty human bone specimens were collected during standard implant placement using a trephine bur. The cylindrical specimens (diameter 2.5 mm and length 8 mm) were sent to the histologist: longitudinal cuts and micro-X-ray were done. The digital images obtained were processed with a specific software compiled by Authors. The algorithm was named Recursive Quadrants Analysis (RQA). The software analyzed the trabecular structure of bone evaluating both the white areas (bone trabeculae) and the black areas (empty spaces). The analysis was based on a recursive scale independent subdivision of the white and black areas using square quadrants. For each level of recursion the dimension of the quadrants was a submultiple of the previous level.



**Results:** For each image processed with the RQA algorithm, a graph was automatically plotted: it showed distribution and dimensions of quadrants for each level of recursion. The analysis was done for white areas and for black spaces. In the same time information about bone density, spatial distribution of the trabeculae (dimension and level of ramification) and spatial distribution of empty spaces was obtained. In this way the digital images of bone specimens were ranked in relation to their geometric fractal properties. Moreover, clusters of different quadrants in white and black areas were automatically identified by the software. These clusters were used with a reverse engineering process to design medical devices.

**Conclusion:** This method allowed to analyze the micro-architecture of human bone. The results obtained suggested to plan



further projects: new digital bone classification, new implants design in order to match the new bone classification, new scaffold geometries, a software for daily clinical use starting from X-rays images. This research introduces a new philosophy: obtaining medical devices designed by tissues.

293 | Poster – Topic Tissue Augmentation and Tissue Engineering

**Success rate of dental implants inserted in autologous bone graft regenerated areas: a systematic review**

**Presenter: Clementini M**

*Università Tor Vergata, Roma, Rome, Italy*

**Co-authors: Clementini M, Morlupi A, Agrestini C, Barlattani A**

*Università Tor Vergata, Rome, Italy*

**Background and aim:** Autologous bone graft is an effective procedures for augmenting atrophic maxillary sinus. The purpose of the present study was to assess the success rate of implants placed in atrophic ridges, regenerated by means of autologous block bone grafts harvested from extra or intraoral donor sites.

**Materials and methods:** A systematic review of all prospective and retrospective studies analyzing the success rate of implants placed simultaneously or as a second surgery following ridge augmentation by means of onlay graft technique, compared with implants placed in pristine bone, was performed. To be included, studies had to involve at least five consecutively treated patients and to report clearly specified success criteria. It was also necessary a minimum follow-up period of 6 months, to allow the observation of potential biological complications during function, rather than early implant failures. In order to assess the success rate of implants in terms of clinical stability, osteointegration and bone resorption, studies reporting only the survival rate of implants were excluded.

**Results:** From 287 potentially relevant studies, 51 full-text publications were screened and six were identified as fulfilling the inclusion criteria. The success rate of implants placed in onlay graft regenerated ridges ranged from 72.8% to 95.7% after a follow-up period ranging from 6 months to 10 years, and all the studies but two reported a success rate higher than 84% (range 84–95.7%).

**Conclusion:** The obtained data demonstrated that the success rate of implants placed in regenerated areas are very similar to those obtained in case of implants placed in pristine bone, and suggested that autologous onlay bone graft augmentation is a quite predictable technique to allow the placement of implants in atrophic areas. Despite that, the current review revealed that there are not many studies providing data on the success rate of dental implants placed in onlay bone graft augmented ridges and demonstrated, on average, a poor methodological quality. So randomized controlled studies adopting standardized criteria to define success and failure of implants are required and data from this review must be considered indicative.

294 | Poster – Topic Tissue Augmentation and Tissue Engineering

**Ridge augmentation with osteogenesis distraction and peridental plastic surgery before implant-supported restauration: a case report**

**Presenter: Olivera J**

*ZAHNARTZ European Institute of Implantology, Lima, Peru*

**Co-authors: Olivera J**

*ZAHNARTZ European Institute of Implantology, Lima, Peru*

**Background and aim:** It is known that guided bone regeneration to vertical increase of residual alveolar ridges is not so predictable with conventional procedures, and even worse when we have more than 3 mm-deep defects. In the other hand, the postextraction bone resorption in the maxilla creates a defect on a vestibular wall. This case reports not only an osteogenesis distraction made in the sextant II with the aim of increasing the residual alveolar ridge vertically, before dental implants placement, but also a periodontal plastic surgery before the final restauration for horizontal increasing, in order to improve the biomechanics and achieve a much more acceptable esthetic for the patient, respectively.

**Materials and methods:** A KLS Martin distractor was placed on a partially edentulous 48-year-old patient to return her appropriate height alveolar bone. First, we exposed the affected area. Using burs and chisels the bone incisions were done, after verifying the correct displacement of the bone segment set to distractor, the flap was closed. Then we waited for, the latency period which was about 7 days, the activating period that was a rate of 1 mm per day, and the consolidation period that took 10 weeks. After this time, the distractor was removed and two titanium implants were placed immediately at 1.1 and 2.1 sites. We wait for an osteointegration period, besides the osteogenesis distraction consolidation becomes completed. The next phase consist in making connective tissue grafts in 1.2 and 2.2 sites to correct the horizontal defects. Finally, the ceramic restorations were done and installed.

**Results:** It was found a significant gain in height of the residual alveolar ridge, approximately 5 mm. The two implants oseointegrated without any complication in the distracted bone segment. The connective tissue grafts allowed a filling of 3 mm horizontally.

**Conclusion:** The alveolar osteogenesis distraction and a connective tissue grafts are predictable surgical techniques that can correct vertical and horizontal alveolar defects (Seibert 2 and 3) in a fast way, where esthetic and biomechanic aspects are before concern before implant-supported restorations. The quality of generated bone at the osteogenesis distraction site was good for the implants oseointegration.

# Sinus floor elevation with nanoporous bone graft material: an 18 months follow-up

**Presenter:** Mertens C

*University of Heidelberg, Heidelberg, Germany*

**Co-authors:** Mertens C, Steveling H

*Department for Oral and Maxillofacial Surgery, University of Heidelberg, Heidelberg, Germany*

**Background and aim:** The aim of this study was to evaluate clinical and radiographic results of maxillary sinus floor elevations using biphasic nanoporous HA/TCP alloplast. After implant surgery and prosthodontic rehabilitation, patients were followed-up for a mean observation period of 18 months.

**Materials and methods:** On a total of 53 patients an external sinus floor elevation to compensate for insufficient bone height in the posterior maxilla had to be conducted as precondition for implant surgery. In these patients 74 individual grafting procedures were executed. As grafting material a synthetic nanoporous bone graft material consisting of a mixture of HA/TCP-crystals (BONITmatrix, DOT, Rostock, Germany) combined with autologous blood – taken from the defect side – was placed between the bony floor and the elevated mucosa. After a four months healing period, patients received 114 Astra Tech implants altogether. After 3 months of implant healing, patients received either a fixed or a removable reconstruction.

Patients were followed-up clinically and radiographically. The augmented areas were surveyed by means of panoramic X-ray to assess bone formation and bone stability and evaluated statistically. The average observation period was 18 months.

**Results:** In this study, an average bone increase of 9.97 mm could be achieved (SD 1.59 mm) after sinus floor elevation. The augmented areas showed good primary stability during implant placement. Throughout the total observation period, good radiographic bone stability could be measured. All of the 114 implants are functionally loaded and no loss is to be expected.

**Conclusion:** After a mean observation of 18 months, the used biomaterial radiographically shows good osseointegration and high bone stability. No implant lost had to be documented so far. Adding to this the positive histological and immunohistochemical findings of a prior study with the same patients, it can be summarized that after a relatively short 4-months healing-period the biomaterial shows predictable good results.

# Platelet-rich-plasma (PRP) and freeze dried bone allograft (FDBA) as an adjunct to maxillofacial rehabilitation by means of zygomatic fixtures and bone autografts

**Presenter:** Evrard L

*ULB-Hôpital Erasme, Bruxelles, Belgium*

**Co-authors:** Evrard L<sup>1</sup>, Baeyens W<sup>2</sup>, Glineur R<sup>1</sup>

<sup>1</sup>ULB-Hopital Erasme, Brussels, Belgium, <sup>2</sup>ULB-Hopital Erasme, Brussels, Belgium

**Background and aim:** For the maxilla, in case of a post-traumatic loss or of a major post-edentation resorption, functional and esthetic rehabilitation can be achieved by means of two or four zygomatic fixtures plus two to four conventional implants in the anterior region. In these cases, reconstruction of the anterior part of the maxilla can be performed, using a bone autograft completed by an allograft and PRP. PRP has been shown to enhance the maturation rate of bone grafts, bone density, as well as to accelerate resorption of some biomaterial particules. The large number of platelet it contains release significant quantities of growth factors (PDGF-aa, PDGF-ab, PDGF-bb, TGF-β<sub>1</sub>, TGF-β<sub>2</sub>, VEGF, EGF), which promote neo-vascularization and osseous regeneration, by the way of mitogenic and chemotactic effects on mesenchymal stem cells, pre-osteoblastic and osteoblastic cells. The cell adhesion molecules contained in PRP (fibrin, fibronectin, vitronectin) act as a matrix for role in osteoconduction.

**Materials and methods:** Clinical cases are presented, involving placement of two to four zygomatic fixtures, in conjunction with a cranial or mandibular symphysis autografts, completed by use of Freeze Dried Bone Allograft (FDBA) and Platelet-Rich Plasma (PRP) in the form of gel and membranes. Biopsies were taken 4–6 months after bone grafting, at the time of implant placement in the region of the anterior maxilla. Histological analysis was performed, in order to evaluate the effects of PRP on bone maturation and bone density, in the case of the use of a bone autograft in conjunction with an allograft. The four years clinical results are presented.

**Results:** Histological sections show the very good degree of maturation of the reconstructed bone (lamellar bone, poor cellularity, absence of inflammatory infiltrate).

X-rays show the level of bone around implants.

**Conclusion:** The results presented here show that PRP used in conjunction with allografts and autografts allows a very good bone quality and density for implants to be placed. After 4 years of functional load, all implants are successful.

## GBR with titanium micromesh

**Presenter:** Conti G*Università degli Studi di Milano, Brescia, Italy*

Co-authors: Rasia Dal Polo MT, Conti G, Borgonovo A, Dolci M, Vettorello F, Reo P

*Clinica Odontoiatrica Università degli Studi di Milano, Milano, Italy*

**Background and aim:** Different techniques for atrophic alveolar bone ridges reconstruction are described in literature, such as resorbable and non-resorbable membranes and titanium micromeshes. During the last years titanium meshes, in association with autologous and heterologous bone, have been used and tested in oral surgery for partial or total alveolar ridges augmentation. Aim of this work was to present cases describing the use of titanium micromesh combined with autologous and heterologous bone grafts in patients affected by alveolar bone resorption.

**Materials and methods:** Before surgery, a radiologic investigation based on panoramic radiography and computed tomography (CT DENTALSCAN) was performed. During surgery, after opening a full thickness flap, a titanium mesh was prepared according to the effective size of the bone defect (measured with a periodontal probe). The mesh was fixed to the bone using titanium mini-screws and/or pins. Before mesh positioning, heterologous (Bio-Oss, Geistlich Biomaterials, Wolhusen, Switzerland) and autologous bone chips were applied under the grid to fill the bone defect. Before closing the flap and suturing, a resorbable membrane (Bio-Gide, Geistlich Biomaterials, Wolhusen, Switzerland) was used to cover the mesh. Approximately 5 months after first surgery, the mesh was removed, and at the same time dental implants were positioned in order to reduce postoperative discomfort and avoid a third surgery.

**Results:** In all the cases, a good increase of the alveolar bone ridge to insert implant fixtures with good primary stability and without necessity for further regeneration was obtained. In one of the cases, an early exposure of the mesh was observed after 2 weeks. However, this event did not compromise the outcome of the procedure.

**Conclusion:** Titanium mesh is a reliable containment system used for reconstruction of the maxilla and the mandible. This material tolerates exposure very well and gives predictable results.

Clinical, histological, radiological comparison of two materials used for sinus augmentation before implant placement, and after short time of loading: a pilot study

**Presenter:** Staneikaite R*Vilnius Implantology Center, Vilnius, Lithuania*Co-authors: Staneikaite R<sup>1</sup>, Maslova N<sup>1</sup>, Puisys A<sup>1</sup>, Grybauskas S<sup>1</sup>, Linkevicius T<sup>2</sup><sup>1</sup>*Vilnius Implantology Center, Vilnius, Lithuania,* <sup>2</sup>*Faculty of Medicine, Institute of Odontology, Vilnius University, Vilnius, Lithuania*

**Background and aim:** Maxillary sinus augmentation allows improvement of vertical bone height and facilitates implant placement. Many materials have been utilized for this procedure with similar success rates, however, studies, that combine different substances from the same patient are very rare.

Study aimed for clinical and histological comparison of two grafting materials for sinus augmentation: natural 100% bovine hydroxyapatite (Bio-oss) and synthetic 60% synthetic hydroxyapatite 40% and  $\beta$ -tricalcium phosphate mixture (Bone Ceramic).

**Materials and methods:** Bilateral sinus augmentations were performed for 10 patients using Bio-oss on the right sides (mean residual bone height – 3.4 mm) and Bone Ceramic on the left side (mean residual bone height – 2.4 mm). After 6 months of healing 46 two-piece implants were inserted into grafted areas. At the time of implantation bone biopsies were taken. Before loading, implants were evaluated according to osseointegration success criteria. All 46 implants were loaded 6 months postoperatively. Control cone beam computed tomography was made to compare grafting material density after prosthesis loading.

**Results:** Sinus augmentations with both materials were successful. All 46 implants were osseointegrated and stable before restoration. The histological static morphologic observations showed differences in tissue structure, consistency and amount of bone-fibrous tissue between materials. Bone density of CT scans measured in relative Hounsfield unit (HU) scale were different, but not clinically significant.

**Conclusion:** Within limits of the study both biomaterials allowed for good, stable clinical results with sinus augmentation and implant integration before loading and after short time of loading in spite of diverse histological picture, and different bone density measurements.

## Implants survival rate in microvascular transplants

**Presenter:** Virnik S*Hospital Klagenfurt, Klagenfurt, Austria*

Co-authors: Virnik S, Gaggl A, Justich X, Chiari F

*Department of Oral and Maxillofacial Surgery, Klagenfurt, Austria*

**Background and aim:** For the reconstruction in the MKG surgery the microvascular transplants represent an important aspect to social, working and aesthetic functions for patients

after a tumour or trauma. This study compares three different microvascular transplants.

**Materials and methods:** Between 2001 and 2008 patients received a microvascular transplants from pelvis (seven), fibula (four) or femur (seven) and treated with implants. All of them were compared and evaluated. Out of 16 patients with 75 implants only one had an implant loss of 4%. We achieved a healing rate of 96%.

**Results:** Out of 16 patients with 75 implants only one had an implant loss of 4%. We achieved a healing rate of 96%.

**Conclusion:** Microvascular transplants can be used successfully to reconstruct the alveolar ridge. The transplant can be adjusted individually in order to carry out an implant with a strong supply.

300 | Poster – Topic Tissue Augmentation and Tissue Engineering

### Reconstruction of the severely resorbed alveolar crest with autografts and platelet rich fibrin

**Presenter: Yildirim E**

*Istanbul University, Istanbul, Turkey*

**Co-authors: Yildirim E, Ersanlı S, Bedelov E, Bolukbasi N**

*Department of Oral Implantology, Istanbul University Faculty of Dentistry, Istanbul, Turkey*

**Background and aim:** Ideal implant positioning can be compromised by inadequate alveolar bone dimensions and bone quality. Bone augmentation procedures are frequently required before dental implant placement in these cases. Several techniques for correction of deficiencies may be considered, such as bone block grafting. Autogenous block bone graft and second-generation platelet rich fibrin (PRF) combination can be used for hard tissue augmentation and to prevent soft tissue dehiscence.

**Materials and methods:** In this presentation this treatment protocol will be explained with case presentation. A 21-year-old female patient with missing maxillary incisor tooth because of explantation of unerupted canine tooth represented to Istanbul University Faculty of Dentistry Department of Oral Implantology for dental implant treatment. Clinical examination revealed severe horizontally and vertically bone loss and an absence of a labial sulcus. In preparation for dental implant surgery orthodontic treatment was done. Cortico-cancellous block was harvested from the symphysis to correct these deficiencies. Autogenous particulate bone graft mixed with platelet poor plasma was placed at the periphery of the block. Platelet rich fibrin membrane was placed above the graft material.

**Results:** After 4 months, the width and height of the residual ridge was assessed by radiography and clinical evaluation was performed. 3.4 mm in diameter and 13 mm in length implant was placed in grafted bone. Five months later, the implants were uncovered followed by impression and temporary restoration for papil forming. The prosthetic treatment was finished with implant-supported full-ceramic crown.

**Conclusion:** This case report suggest that block autografts harvested from the symphysis and platelet-rich fibrin combination may have the potential to maintain soft and hard tissue contour.

301 | Poster – Topic Tissue Augmentation and Tissue Engineering

### Biological container stabilized with a new allograft material

**Presenter: Fuchs E**

*Private Clinic, Thalwil, Switzerland*

**Co-authors: Fuchs E**

*Privat Clinic CH-8800, Thalwil/ZH, Switzerland*

**Background and aim:** The Biological Container. Prepared and stabilized by a new stuffy material. Fixation for the predictable alveolar distraction and predefined three-dimensional direction with vital bone as a base for oral implantation.

**Materials and methods:** The aim of the development of a surgical technique combined by a new stabilization with this stuffy allogeneic material for alveolar distraction was to guarantee the vector of the distraction and also a simpler and faster application. The smaller design of the device and the proper stuffy fixation is an advantage. The stabilization is guaranteed through this stuffy, but resorbable material.

**Results:** The stabilization is guaranteed through this stuffy, but resorbable material. In the period 2007 till 2009 16 cases of alveolar distraction combined with Easygraft in the so-called biological container were carried out. Fourteen implants were incorporated; one implant were lost during healing phase. The survival rate was 92.6%.

**Conclusion:** With this small device in combination with this new stuffy material (Easygraft and Crystalgraft) an augmentation of the anterior segment of the maxilla and the distal segment of the mandible in severely vertical and horizontal resorbed alveolar ridge cases can be achieved and a proper bed for incorporation of dental implants can be installed. This material can although used to stabilize a minimal-invasive spreading of the alveolar ridge. <http://www.bonemanagement.com>

302 | Poster – Topic Long-Term Studies

### Cost, maintenance and patient satisfaction with three different retention systems for implant supported mandibular overdenture

**Presenter: Cristache CM**

*Concordia Dent SRL, Bucharest, Romania*

**Co-authors: Cristache CM<sup>1</sup>, Cristache G<sup>1</sup>, Burlibasa M<sup>2</sup>, Ionescu C<sup>2</sup>**

*<sup>1</sup>Concordia Dent Clinic, Bucharest, Romania, <sup>2</sup>University of Medicine and Pharmacy 'Carol Davila', Bucharest, Romania*

**Background and aim:** Few prospective clinical studies of implant-retained mandibular overdenture have evaluated the impact of different methods of attaching overdentures to implants on aspects of everyday life or person values. The aim of our study is to compare costs, maintenance requirements, patient satisfaction and oral health-related impact on the quality of life of patients restored with three different retention systems for implant supported mandibular overdenture.

**Materials and methods:** Sixty-nine patients (between 42 and 84), fully mandibular edentulous with severe alveolar ridge atrophy

and instability of the existing lower denture were enrolled in the study. Each patient received two Straumann,  $\text{AE } 4.1 \text{ mm}$ ,  $10 \text{ mm}$  ( $n = 35$ ) and  $12 \text{ mm}$  ( $n = 34$ ), screw-type implants in the interforaminal region of the mandible. After 6 weeks healing period a new denture was made and the patients randomly assigned to one of the following equal groups: retentive anchors (B) – with two subgroups: B.1 patrice with variable retentivity ( $n = 12$ ) and B.2 patrice with fixed retentivity ( $n = 11$ ), magnets (M) and Locator (L). Total costs of the procedures were calculated for the three retention systems used. All patients rated with the aid of questionnaires adapted from the indexes oral health-related quality of life in its short form OHIP-EDENT their general satisfaction as well as other features of their dentures (comfort, stability, ability of chewing, speech, esthetic and cleaning ability).

**Results:** Four implants failed (97.1% success rate). After 24 month: Surgical and prosthetic costs were similar, but components costs were highest at M group and lowest at B2 group. For B1 group – additional costs for unscheduled procedures (activation/replacement) were needed. Statistically significant improvement in the OHIP-EDENT domains of functional limitation and physical and psychological disability was seen in all groups. Patient satisfaction improved significantly in the three groups across all variables including esthetics, except ease of cleaning – the B and L group had higher maintenance necessities. M group scored lower stability but also lower maintenance requirements.

**Conclusion:** Implant-supported overdenture improves retention and stability, despite of the system used. The choice of the retention system used is determined by the special needs of each patient. Acknowledgments: Supported by Grant no. 316/2003 and no. 507/207 from the ITI Foundation for the Promotion of Oral Implantology, Switzerland.

#### 303 Poster – Topic Long-Term Studies

### CNC-milled titanium frameworks supported by implants in the edentulous jaw: a 10-year comparative clinical study

**Presenter: Örtorp A**

*Institute of Odontology, The Sahlgrenska Academy, Göteborg, Sweden*

**Co-authors: Örtorp A<sup>1</sup>, Jemt T<sup>2</sup>**

<sup>1</sup>*Institute of Odontology, The Sahlgrenska Academy, Gothenburg, Sweden,* <sup>2</sup>*The Brånemark Clinic, Gothenburg, Sweden*

**Background and aim:** No long-term clinical studies for more than 5 years are available on Computer Numeric Controlled (CNC) milled titanium frameworks. The objective was to evaluate and compare the clinical and radiographic performance of implant-supported prostheses provided with CNC titanium frameworks in the edentulous jaw with prostheses with cast gold-alloy frameworks during the first 10 years of function.

**Materials and methods:** A consecutive group of 126 edentulous patients were randomly provided with 67 prostheses with titanium frameworks (test) in 23 maxillas and 44 mandibles, and with 62 prostheses with gold-alloy castings (control) in 31

maxillas and 31 mandibles. Clinical and radiographic 10-year data were collected for the groups.

**Results:** The 10-year Cumulative survival rate (CSR) was 95.6% and 98.3% for titanium and gold-alloy prostheses, respectively ( $P > .05$ ), and the 10-year CSR implants was 95.0 and 97.9, respectively ( $P < .05$ ). One prosthesis was lost in each group due to loss of implants, and one prosthesis was a failure due to framework fracture in the test group. Two metal fractures were registered in each group. Loss of screw site fillings were more frequent in the gold-alloy group in the maxilla after 5 ( $P < .05$ ) but not after 10-years of follow-up ( $P > 0.05$ ). More appointments were needed for the maxilla when compared with the mandible ( $P < 0.001$ ). No implants were lost after 5 years follow-up. Smokers lost more implants than nonsmokers ( $P < 0.01$ ) after 10 years of follow-up. The mean marginal bone loss in the test group was  $0.70 \text{ mm}$  (SD  $0.61$ ) and  $0.67 \text{ mm}$  (SD  $0.85$ ) in the maxilla and mandible, respectively, with similar pattern in the control group ( $P > 0.05$ ).

**Conclusion:** The frequency of complications was low with mainly similar clinical and radiological performance for both groups. CNC-milled titanium frameworks are a viable alternative to gold-alloy castings in the edentulous jaw with similar clinical and radiological performance as gold-alloy frameworks during the first 10 years of function.

#### 304 Poster – Topic Long-Term Studies

### Changes in nitric oxide and arginase levels in saliva, gingival crevicular fluid and peri-implant crevicular fluid after loading of dental implants: a prospective cohort study

**Presenter: Ozmeric Kurtulus N**

*Gazi University Faculty of Dentistry, Ankara, Turkey*

**Co-authors: Ozmeric N<sup>1</sup>, Elgun S<sup>2</sup>, Sahin R<sup>1</sup>, Sungur C<sup>1</sup>, Mollaoglu N<sup>3</sup>**

<sup>1</sup>*Department of Periodontology, Faculty of Dentistry, Gazi University, Ankara, Turkey,* <sup>2</sup>*Department of Biochemistry, School of Medicine, Ankara University, Ankara Turkey,* <sup>3</sup>*Department of Oral and Maxillofacial Surgery, Faculty of Dentistry, Gazi University, Ankara Turkey*

**Background and aim:** Nitric oxide (NO) is a highly reactive free radical that initiates host defense, homeostatic and developmental functions by either direct effect or intercellular signaling. NO synthesis is controlled by arginase reaction through depletion of the common substrate L-arginine. We have previously reported that the arginine–NO pathway in periodontal tissues may have a role in inflammation via excessive NO production due to a decrement of arginase expression. In the present study, it has been hypothesized that alteration in NO level or arginase activity might have a role in survival of dental implants after loading. In addition, we also aimed to investigate whether NO-arginase pathway differs in gingival crevicular fluid (GCF), peri-implant crevicular fluid (PICF) and saliva.

**Materials and methods:** Eighteen subjects with 31 implants were included in the study. Periodontal status was determined by clinical periodontal assessments, including plaque index,

bleeding on probing, gingival index, probing pocket depth, clinical attachment level and radiographic examination. After periodontal examination, all patients were subjected to basic periodontal therapy. Before any treatment, GCF from the contralateral site of missing tooth, unstimulated saliva samples and PICF obtained at baseline and repeated after loading at 1, 3 and 6 months. Quantitative determination of nitrite and nitrate was done using NO Assay Kit and ELISA was employed to determine the amount of arginase in GCF, saliva and PICF.

**Results:** NO was measured higher in GCF of patients compared to that in saliva. Similar amounts of arginase were observed in both GCF and saliva. Implant therapy did not have an impact on salivary NO and arginase levels, however, PICF NO levels upregulated significantly after loading at 1, 3 and 6 months whereas arginase levels downregulated.

**Conclusion:** Analysis of GCF and PICF might be beneficial in the determination of current periodontal or peri-implant status in terms of NO-arginase involvement. Since GCF and PICF have the chance of being closely approximated to the periodontal or peri-implant tissues where inflammatory diseases begin, they seem to provide more information than markers in saliva. The results have indicated that the determination of NO-arginase levels in biologic fluids might be a good indicator of inflammatory activity.

305	Poster – Topic Long-Term Studies
-----	----------------------------------

### Crestal bone loss around astra tech implants: 3 years clinical study

**Presenter:** Turkoglu P

*Istanbul University, Istanbul, Turkey*

**Co-authors:** Turkoglu P, Atalay S, Gultekin BA

*Istanbul University, Istanbul, Turkey*

**Background and aim:** The resulting crestal bone levels around dental implants following restoration has been a topic of discussion and used as a reference for evaluating implant success for many years. The concept of platform switching may limit the bone change that occurs around the coronal aspect of the implant. The Astra Tech implant system exhibits several important features like platform switched design, surface structure and abutment connection.

**Materials and methods:** A total of 132 Astra Tech dental implants were inserted in 48 partially and totally edentulous patients. Before placement medically compromised, alcoholics and heavy smokers ( $\geq 20$  per day), non-treated periodontally infected and parafunctional habit patients were eliminated. Patients were followed as a part of a prospective longitudinal study focusing on implant survival, peri-implant bone resorption, peri-implant gingival health and complications. Radiographic parameters were evaluated on panoramic radiographs right after implant insertion, permanent prosthesis delivery and 1, 2 and 3 years after implant insertion. The distance from both the mesial and distal margins of the implant collar to the most coronal point where the bone appeared to be in contact with the implant were measured by on radiographs. Plaque and gingival index scores were analyzed 1 week after permanent prosthesis delivery and 1, 2, 3 years after implant insertion.

**Results:** The cumulative survival rates were consequently, 98.5%, 98.2% and 97.9% after first, second and third years. Only two implants (4.0/9 mm) placed in posterior maxilla were lost. One two-implant-supported three unit zirconium bridge was replaced by reason of breakage. The mean crestal bone loss was  $0.6 \pm 0.075$  mm at the end of the study. No differences were found between implants that were placed in maxilla and mandible respective with bone resorption. Satisfactory peri-implant health index scores were achieved (gingival index and plaque index scores were found  $< 1$ ).

**Conclusion:** The typical pattern of crestal bone resorption was not observed in our study. Platform switching seemed to reduce peri-implant crestal bone resorption and increase the long-term predictability of implant therapy so that the design may play importance in short implants and aesthetic cases. However, histologic evaluation and longer follow-up periods are needed to confirm the results reported in this study.

306	Poster – Topic Long-Term Studies
-----	----------------------------------

### Sinus floor elevation: a retrospective analysis of 213 consecutive cases (456 implants) with up to 9-year follow-up

**Presenter:** Pragosa A

*Instituto de Implantologia, Lisboa, Portugal*

**Co-authors:** Carames J<sup>1</sup>, Pragosa, A<sup>1</sup>, Sousa S<sup>1</sup>, Crispim P<sup>1</sup>, Marques H<sup>1</sup>

<sup>1</sup>*Instituto de Implantologia, Lisboa, Portugal*, <sup>2</sup>*Faculty of Dental Medicine, University of Lisbon, Lisboa, Portugal*

**Background and aim:** Grafting the floor of the maxillary sinus has become the most common surgical intervention for increasing alveolar bone height prior to the placement of endosseous dental implants in the posterior maxilla. In an era where alternative techniques for rehabilitation of the severely atrophic posterior maxilla are proposed without the support of long-term clinical studies, we present a retrospective analysis of 213 cases of sinus floor elevation (456 implants) with up to 9-year follow-up.

**Materials and methods:** One hundred and forty-four consecutive patients previously treated with at least one implant in the grafted maxillary sinus region of the maxilla were included in this retrospective analysis. A total of 456 root-form fixtures had been surgically placed to support fixed dental bridges. All implants were placed at the Instituto de Implantologia, Lisbon, by the same surgeon. The patients were followed in a standardized clinical and radiographic method for up to 9 years.

**Results:** An overall survival rate of 94.1% was verified. Of the implants that failed, only four did not survive after loading. The survival rates lowered in cases in which patients were heavy smokers (92%). A tendency for a lower survival rate was established, the greater the smoking habit. And similarly a correlation was also established between the existence of periodontal disease and implant failure. After applying correlations tests (Pearson's and SIG(two-tailed)) we also observed a tendency for greater failure rates in cases in which implants were placed simultaneously with the sinus lift technique.

**Conclusion:** Sinus floor elevation is well documented and presents high implant survival rates, which make it a predictable technique for implant rehabilitation of the severely atrophic posterior maxilla. However, special care must be taken when using this technique in the presence of smoking habits and periodontal disease.

307	Poster – Topic Long-Term Studies
-----	----------------------------------

Rationale and clinical outcome of prefabricated anatomical shaped prosthetic components of ZRO<sub>2</sub> for the posterior region – primarily results of a prospective randomized clinical trial

**Presenter:** Trimpou G

J.-W. Goethe University, Frankfurt am Main, Germany  
Co-authors: Trimpou G<sup>1</sup>, Weigl P<sup>2</sup>, Grizas E<sup>2</sup>, Lauer HC<sup>2</sup>

<sup>1</sup>Department of Oral Surgery and Implantology, J.-W. Goethe University, Frankfurt am Main, Germany, <sup>2</sup>Department of Prosthodontics, J.-W. Goethe University, Frankfurt am Main, Germany

**Background and aim:** The initial formation of the peri-implant soft-tissue mostly starts from the circular shape of the implant neck or healing abutment. Customized, anatomical-shaped healing abutments enable a natural looking formation in a timely but costly manner. Although nowadays the esthetical demands are expanded to the posterior region, patients are noticed to show less willingness to invest the same money amount for posterior aesthetics as they do in the anterior region. This increased esthetical demand on natural emergence-profile should be achieved in an easily, predictable and with reduced effort way even in the posterior region. The aim of a long-term, prospective clinical trial (Ethical commission University of Frankfurt: No.133/05) was to prove a facilitation of nature like soft-tissue formation by using prefabricated anatomical shaped Zirconia-components. Furthermore the long-term performance of prefabricated anatomical shaped all ceramic abutments in the posterior region is evaluated.

**Materials and methods:** Twenty-one patients serve as a control group. After second stage surgery healing abutments (Ankylos<sup>®</sup>, Dentsply Friadent, Germany) were mounted and replaced 2 weeks later by titanium abutments ( $n_{tit} = 23$ ) retaining 19 single crowns and two bridges (PFM). Twenty-one patients of the test group were restored with 19 crowns and two bridges borne on innovative all-ceramic abutments ( $n_{zirc} = 23$ ) which simulate a posterior tooth after a crown preparation with a margin at the scalloped soft tissue level. At this level the elliptical cross section imitates the emergence profile. An index-free implant-abutment joint is needed to ideal align this asymmetrical abutment. All-ceramic healing abutments with same design as the abutments were placed at the day of second surgery. Technical and biological maintenance, plaque index (PI), papilla bleeding index (PBI), sulcus fluid flow rate (SFFR) and Periotest values (PTVs) were assessed to evaluate the long-term performance in both groups.

**Results:** The innovative posterior all-ceramic components support an excellent development of a clinically intact soft-tissue.

Additionally, the replacement of the healing abutment does not cause any compression contrary to the control group. A posterior crown with a tooth-identical emergence profile is easier to produce in the test than in control group. Only minor technical complications (ceramic chipping, decementations) were reported for both groups.

**Conclusion:** The new method is more efficient and predictable in terms of time and costs according to the soft tissue shaping, since the components are prefabricated. The reduced compression simplifies the procedure of component-insertion and was proven as more patient-oriented.

308	Poster – Topic Long-Term Studies
-----	----------------------------------

IL-1BETA, IL-10, RANKL AND OPG levels in peri-implant sulcular fluid

**Presenter:** Yamalik N

Hacettepe University Faculty of Dentistry, Ankara, Turkey

Co-authors: Akman AC, Guncu GN, Gunday S, Yamalik N, Berker E

Department of Periodontology, Hacettepe University Faculty of Dentistry, Ankara, Turkey

**Background and aim:** Plaque accumulation around dental implants can result in the development of an inflammatory reaction in the peri-implant mucosa. Cytokines can activate degradative pathways. It is supported that analysis of and PISF volume and ingredients may serve for detection of inflammation. In the present study, PISF interleukin-1 beta (IL-1 $\beta$ ), IL-10, OPG, RANKL levels were analysed to determine whether the diagnostic value of PISF can be used to evaluate early changes around implants.

**Materials and methods:** A total of 40 dental implants either healthy/non-inflamed ( $n = 20$ ), or gingivitis/inflamed ( $n = 20$ ), were classified. Peri-implant status has been evaluated by clinical evaluation [plaque index (PI), gingival index (GI), probing depth (PD) and gingival bleeding index (GBI)] were recorded and PISF samples were also obtained. PISF IL-1  $\beta$ , IL-10, receptor activator of nuclear factor-kappa B ligand (RANKL), and osteoprotegerin (OPG) levels were measured by enzyme-linked immunosorbent assay (ELISA). Potential volumetric changes in PISF were also evaluated. For a longitudinal design repeated measurements were performed whenever possible.

**Results:** Data analyzes demonstrated that, the volume of the PISF was significantly higher in gingivitis/inflamed group when compared with healthy/non-inflamed group. The IL-10:IL-1  $\beta$  and OPG:RANKL ratios were higher in healthy/non-inflamed implants when compared with the gingivitis/inflamed implants.

**Conclusion:** These data suggest that ingredients and volume of PISF could be useful markers of inflammation in peri-implant tissues. IL-1  $\beta$ , IL-10, RANKL and OPG levels in PISF may become a novel biomarker to evaluate the health status of surrounding tissues of dental implants.



XIVE<sup>®</sup> implants in the posterior maxilla after a maximum observation time of 5 years

**Presenter:** Clar V

*University Dental Clinic, Medical Clinic Graz, Graz, Austria*

**Co-authors:** Clar V<sup>1</sup>, Heschl A<sup>1</sup>, Platzer S<sup>1</sup>, Wegscheider WA<sup>1</sup>, Lorenzoni M<sup>1</sup>, Jakse N<sup>2</sup>

<sup>1</sup>*Department of Prosthodontics Implantology, Periodontologie, Restorative Dentistry, Graz, Austria,* <sup>2</sup>*Department of Oral Surgery and Radiologie, Graz, Austria*

**Background and aim:** In the posterior maxilla, the process of ridge reduction is multidirectional. The result of resorption is insufficient bone volume for implant placement before prosthetic treatment. The purpose of this retrospective evaluation was to analyse the survival rate of Xive<sup>®</sup> implants in different indications in the posterior maxilla.

**Materials and methods:** Xive<sup>®</sup> implants of the implant data base, University Dental Clinic Graz, were analyzed. Implants were inserted using the placement instructions provided in the Xive<sup>®</sup> Surgical Manual. Data management and check-ups of patients were achieved by an independent surgically and prosthetically non-involved researcher. All patients were in an at least once-a year recall routine.

**Results:** Between 2001 to 2008 205 patients were treated with 630 Xive<sup>®</sup> implants in the posterior maxilla – 5.9% replacing single teeth, 13.8% intermediate gaps, 27.9% edentulous maxilla and 52.4 uni- or bilateral free-end situations. Using the lateral-window-technique sinus elevation procedure was performed in 75.7% of all cases. In this group a mean residual bone height of 6.28 mm was calculated. In 47% of these patients a one-stage procedure was performed. In 53% of the grafted sites a mean healing period of 9.1 months and an average bone augmentation of 8.95 mm were evaluated. Four implants of 630 implants failed. These failures occurred during the first 7 months of the healing period. All other implants were successful restored. Seventy-eight implants were followed for 5 years with a survival rate of 96.2%, 137 for 4 years with a survival rate of 97.8%. After a 3-year period of observation for 237 implants 98.7% of the implants were successfully loaded. The survival rates of Xive<sup>®</sup> implants placed in different indications did not show significant statistical difference.

**Conclusion:** After a 5-year observation period it can be stated, that 96.2% of maxillary posterior Xive<sup>®</sup> implants are successfully supporting implant prostheses. Further data are needed to evaluate the long-term prognosis of implant-supported restoration of the posterior maxilla.

**Acknowledgement:** Supported by Dentsply-Friadent Volker.clar@medunigraz.at

Long-term evaluation of implant placed in the augmented maxillary sinus area using lateral window approach: 1- to 10-year retrospective study

**Presenter:** Yon JY

*Dental Hospital of Yonsei University, Seoul, Korea*

**Co-authors:** Yon Jy, Jung UW, Kim CS, Choi SH, Cho KS

*Department of Periodontology, Dental Hospital of Yonsei University, Seoul, Korea*

**Background and aim:** Reduced height of residual alveolar bone can limit the placement of endosseous dental implants. Maxillary sinus floor augmentation with lateral window approach (LWA) has become a routine treatment procedure for the atrophied edentulous maxillae. The purpose of this study was to evaluate the cumulative success rate (CSR) of the implants placed in the augmented maxillary sinus by LWA, the correlation between crown-to-implant (CI) ratio and marginal bone loss (MBL) around implants, and the distribution of complication.

**Materials and methods:** One hundred nine cases of the maxillary sinus augmentation with LWA were performed in the posterior area which a residual bone height (RBH) of < 5 mm on 96 patients from September 1996 to May 2007 in the Department of Periodontology, Dental hospital of Yonsei University. The mean follow-up period of implants was  $45.3 \pm 23.4$  months with range from 17 to 135 months. A total of 217 implants were placed in the augmented area [86 Straumann implants (39%), 131 Brånemark implants (61%)]. The CSR was calculated according to Kaplan-Meier's method. RBH and augmented bone height (ABH) were measured. The CI ratio at the baseline was recorded. The association between the CI ratio and MBL were calculated by correlation analysis ( $P < .05$ ). The distribution of biological and technical complications was investigated.

**Results:** Six implants were failed during the follow-up period (five Brånemark, one Straumann). A total CSR, Brånemark and Straumann were 97.1%, 96.9%, and 98.8%, respectively. The mean RBH, ABH, and CI ratio were  $3.72 \pm 1.04$ ,  $9.75 \pm 3.21$  mm, and 1.42:1, respectively. The correlation between CI ratio and MBL was not statistically significant ( $P = 0.72$ ). The incidence of complication was 42.2%. The most prevalent biological complication was Schneiderian membrane tearing (14.3%) and technical complication was screw loosening (14.7%).

**Conclusion:** Within the limitation in this study, there is no association between the CI ratio and MBL. Despite relatively high incidence of complication, the CSR was showed to be high as a routine implant CSRs. Therefore, the maxillary sinus augmentation procedure with LWA could be concluded to be a predictable surgical modality for placement of the implant at atrophied maxillary posterior area for long-term period.

## Immediate loading with overdenture in the edentulous jaws: long-term results

**Presenter:** Eccellente T

*Clinic for Periodontal and Implant Surgery, Grumo Nevano, Italy*

**Co-authors:** Eccellente T, Piombino M, Rossi A, Capasso S

*Clinic for Periodontal and Implant Surgery, Grumo Nevano, Italy*

**Background and aim:** To evaluate clinical efficacy of immediate loading with overdenture retained by prefabricated conical copings in the edentulous jaws.

**Materials and methods:** Between January 2 and May 7 a total of 636 Ankylos implants (Dentsply, Friadent, Mannheim, Germany) were placed in 77 edentulous mandibles and in 82 edentulous maxilla (four implants in each jaw) and immediately loaded. Implant length ranged from 9.5 to 17 mm. One hundred forty-five patients were monitored in this study. Fourteen patients received the same treatment in both jaws. Patient's age at implants placement ranged between 42 and 82 years, the mean age was 62,3 years. Twenty-eight patients were smokers. All participants gave informed consent. Following surgery all implants were connected with prefabricated conical abutments, that are manufactured with a precise fit to secondary conical copings. These prefabricated copings are polymerised into denture base directly in the mouth of the patients. Panoramic X-ray were taken at implants placement after 6 months and yearly. mSBI and mPLI, patient' satisfaction, technical complications were recorded in different time intervals.

**Results:** Four implants in the mandible and seven implants in the maxilla were removed during observation period and could be successful replaced but are not included in our statistics that lead to an implants cumulative survival rate of 98.3% (mandible 98.7%, maxilla 97.9%), the prosthesis survival rate was 100%. After a total observation period of 32.4 months (range 18–70 months) all other implants presented healthy peri-implant hard and soft tissue conditions (mSBI > 1; mPLI = 1). Radiographic examination showed an excellent bone healing and stable bone level. During the observation period 11 cases of abutments screws loosening occurred. Fourteen partial break denture base occurred and were quickly repaired. The majority part of the patients were satisfied about time and modality of treatment. Six patients were not satisfied with aesthetic; all other appreciated function, aesthetic and retention of the restoration.

**Conclusion:** Basing on the present long-term data it was concluded that four implants with high primary stability, may support immediate loading in edentulous mandible as well as in edentulous maxilla.

## Survival rates of super – wide implants (6–8 mm in diameter)

**Presenter:** Park JP

*West-Mir Hospital, Daegu, Lao People's Democratic Republic*

**Co-authors:** Park Jp<sup>1</sup>, Park Kb<sup>2</sup>, Park Sj<sup>3</sup>

<sup>1</sup>Jong-pil PARK, Daegu, Korea, <sup>2</sup>Kwang-bum Park, Daegu, Korea,

<sup>3</sup>Sang-jun Park, Daegu, Korea

**Background and aim:** The purpose of this retrospective clinical study was to evaluate the outcome of survival rates of super wide implants in molar areas.

**Materials and methods:** In this retrospective clinical study, 1135 super wide Rescue implants (Megagen Co, Korea/super RBM surfaced/595 maxilla, 540 mandibular) were placed in 649 patients (402 male, 247 female/age mean: 51 years old, range 20–83 years old). Of the total, 68.3% were used to treat fully or partially edentulous situations, including single-tooth loose, and 31.7% were placed immediately after teeth extraction or removal of failed implants, of which all 100% were in the molar regions. Implant diameter and length ranged from 6.0 to 8.0 mm and 5.0 to 10.0 mm, respectively. The implants were followed for up to 42 months.

**Results:** Of 1135 placed implants, 58 were lost. Among them, 53 implants were lost within 12 months after implants placement. The survival rates were 93.6% for the implants in the maxilla and 96.3% for the implants in the mandible, yielding and overall survival rate of 94.9% for up to 42 months.

**Conclusion:** The survival rate of 94.9% compares favorably with that of standard diameter implants. The outcome of the present study show that the use of super-wide implants may result in a predictable treatment outcome in molar areas.

## Prefabricated taper crowns as retainer for implant suprastructures: prosthetic treatment protocol, cost effectiveness, general satisfaction, marginal soft-tissue response and hygiene ability. Three-years results of a prospective clinical trial

**Presenter:** Weigl P

*J.-W. Goethe University/Frankfurt am Main, Frankfurt am Main, Germany*

**Co-authors:** Weigl P<sup>1</sup>, Trimpou G<sup>2</sup>, Lauer HC<sup>1</sup>

<sup>1</sup>Department of Prosthodontics, J.-W. Goethe University, Frankfurt am Main, Germany, <sup>2</sup>Department of Oral Surgery and Implantology, J.-W. Goethe University, Frankfurt am Main, Germany

**Background and aim:** Bar shaped retainer offer a difficult hygiene of peri-implant mucosa, non-splinted retainer like ball or magnets cause high prosthetic aftercare. A promising solution is a retainer avoiding the mentioned negative side effects to meet especially the soaring immobility of geriatric patients. The objective of the prospective clinical trial was to evaluate the hygiene ability and the periimplant mucosa of removable suprastructures retained with a prefabricated tapered crown

system, assessed on patients which are not participate in a special and intensive hygiene recall program. Additionally several parameters such as retentive strength, frequency of pressure points, need of a relining, time and costs of this treatment are of special interest.

**Materials and methods:** Twenty-three patients (15 ♀, 8 ♂, Ø age 61.6 years  $\pm$  12.9 SD) were included in this study. After three drop-outs 20 patients with 21 overdentures (9 mandibles, 12 maxillae, retained by 91 Ankylos<sup>®</sup>-Implants and 6 teeth) were evaluated for 36 months. The removable dentures were retained by a prefabricated telescopic retainer system named SynCone<sup>®</sup> (Dentsply, Friadent, Germany). A novel treatment modality was used based on intraoral bonding of the copings to the framework in order to achieve a passive and precise fit. Plaque index (PI), papilla bleeding index (PBI), sulcus fluid flow rate (SFFR) and Periotest values (PTVs) were assessed. Patient's hygiene ability was evaluated by using questionnaires.

**Results:** One implant in the lower jaw was lost after 25 months (survival rate 98.91%). The PTVs of implants improved significantly between the first denture insertion ( $\text{mean}_{\text{initial}} = -0.9 \pm 1.73$  SD) and 6 months ( $\text{mean}_{6-\text{months}} = -2.01 \pm 1.46$  SD) (Tukey's test,  $P < 0.05$ ) and remain stable ( $\text{mean}_{36-\text{months}} = -2.52 \pm 1.76$  SD). The SFFR between baseline ( $\text{mean}_{\text{initial}} = 28.74 \pm 18.93$  SD) and after 36 months ( $\text{mean}_{36-\text{months}} = 15.13 \pm 13.14$  SD) differ significant (Tukey's test,  $P < 0.05$ ). The plaque accumulation (PI) at the abutments was low ( $\text{mean}_{36-\text{months}} = 0.38 \pm 0.61$  SD). The periimplant soft tissue was free of inflammation (PBI  $\text{mean}_{36-\text{months}} = 0.37 \pm 0.64$  SD). Hygiene ability was scored as easy by the majority of patients (94.8%). The average lab-side manufacture time and costs for dentures made with a casted telescopic retainer is 2.16-fold  $\pm$  0.82 SD and 1.78-fold  $\pm$  0.36 SD perceptively higher than for dentures with the prefabricated retainer.

**Conclusion:** Removable suprastructures made with prefabricated double crown components allow an easy hygiene and handling comfort. The usage of the SynCone<sup>®</sup>-retainer enables an easy manufacturing of removable dentures with equal clinical behaviour and biomechanics of a fixed suprastructure.

#### 314 Poster – Topic Long-Term Studies

Perceptual changes in the peri-implant soft tissues assessed by directional cutaneous kinaesthesia and graphaesthesia: a prospective study

**Presenter:** Habre-Hallage P

Saint-Joseph University, Baabda, Lebanon

Co-authors: Habre-Hallage P<sup>1</sup>, Bou-Abboud Naaman N<sup>1</sup>, Reyhler H<sup>2</sup>, van Steenberghe D<sup>3</sup>, Jacobs R<sup>3</sup>

<sup>1</sup>Saint-Joseph University, Beirut, Lebanon, <sup>2</sup>Universite Catholique de Louvain, Bruxelles, Belgium, <sup>3</sup>Katholieke Universiteit Leuven Leuven Belgium

**Background and aim:** The innervation of skin and oral mucosa plays a major physiological role in exteroception. This innervation is also of clinical interest since it is manifested by sensory changes after neurosurgical procedures. The aim of this study was to assess the perception of mechanical stimuli applied to

the buccal mucosa in subjects rehabilitated with a single osseointegrated implant compared with the contralateral dentate side. Such information might contribute to a better understanding of the role of the reported increased innervation in the peri-implant soft tissues, in the oral sensorimotor function.

**Materials and methods:** Seventeen subjects with 20 implants were selected and tested. Directional cutaneous kinaesthesia (DCK) and graphesthesia (G) were performed on the buccal side of the alveolar mucosa before implant placement and at planned intervals until 6 months after the prosthetic rehabilitation. In each subject, one implant was stimulated while the tissues surrounding the contralateral natural tooth served as a control. Average percentages of correct responses in a four-choice task for DCK and three-choice task for G were calculated.

**Results:** Despite an intersubject variation in both the DCK and G, significantly high intra-individual correlations were found ( $P < 0.005$ ). The implant sites showed a significant difference at the four interval test for both tests. For DCK and G the average of correct responses decreased at the abutment connection (after the second surgery) then it started to increase to reach a level near but lower than the control site at 3–6 months of function.

**Conclusion:** Postsurgical sensory changes may be bothersome to patients, even though the main goal of the surgery has been completely successful. To assess this observation, one cannot simply rely on the patient's subjective report. The directional cutaneous kinaesthesia and the graphaesthesia are simple but reliable sensory tests that could be easily applied in the oral region. They correlate the physiologic function of the receptors to the subjective response of the patient. The present study reveals that tooth loss gives lower tactile function compared to implant-supported prostheses. This finding confirms the existence of the osseoperception phenomenon intraorally. It may find its origin in the peri-implant environment. However, the peri-implant soft tissues are partially involved in this function. Since this study confirmed that open flap procedures reduce the directional sensitivity, further investigation may demonstrate the merit of the flapless/flap techniques.

#### 315 Poster – Topic Long-Term Studies

Immediate occlusal loading of the mandible: Brånemark novum system<sup>®</sup> a retrospective 8 year follow-up study on 70 consecutive patients

**Presenter:** Navarro JM

Branemark Osseointegration Center, Spain, Las Palmas G.C., Spain

Co-authors: Navarro JM<sup>1</sup>, Navarro Jr. JM<sup>2</sup>, Brånemark Pi<sup>3</sup>

<sup>1</sup>Brånemark Osseointegration Center Las Palmas, Las Palmas, Spain,

<sup>2</sup>Brånemark Osseointegration Center Las Palmas and New York

University College of Dentistry Department of Biomaterials and

Biomimetics New York United States, <sup>3</sup>Brånemark Osseointegration

Center, Göteborg, Sweden

**Background and aim:** In 1995, Skalak and Brånemark, developed an immediate loading technique for the edentulous mandible with the use of prefabricated components. The initial success of this procedure, using only three fixtures, indicated that with

good quality bone, careful placement of the implants, and a well-adjusted prosthesis, results were similar to those reported with the two-stage surgical approach. The purpose of this study was to evaluate our experience at the Brånemark Osseointegration Center (BOC) in Spain, utilizing the Brånemark Novum<sup>®</sup> protocol. To evaluate Implant survival rate, prosthesis survival rate and to determine risk factors of this technique.

**Materials and methods:** Seventy consecutive patients seeking rehabilitation of the mandible that was either completely edentulous or had remaining hopeless teeth that required extraction were included in this study. Each received three implants between the mental foramina placed utilizing the system's surgical guidelines. Permanent fixed prostheses fabricated over pre-manufactured components were attached to the implants on the day of implant placement. The patients were followed for 43–95 months (4–8 years) (mean 69 months). Peri-implant hard and soft tissues were periodically evaluated. Satisfaction was assessed by means of a questionnaire.

**Results:** The overall implant and prostheses survival rate was 92.7% and 95.71%, respectively. 2.8% of the patients reported some discomfort during treatment, and all patients would recommend the procedure to others. Radiographic bone levels have been maintained in the majority of the cases, and soft tissue health has been seen to be generally very good.

**Conclusion:** The long-term results obtained demonstrate that the Brånemark Novum<sup>®</sup> method is a predictable technique with a high percentage of clinical success that represents a therapeutic alternative for the rehabilitation of patients with edentulous mandibles.

316	Poster – Topic Long-Term Studies
-----	----------------------------------

## Regional odontodysplasia and dental implant rehabilitation

**Presenter: Casey D**

*Roswell Park Cancer Institute, Buffalo, NY, USA*

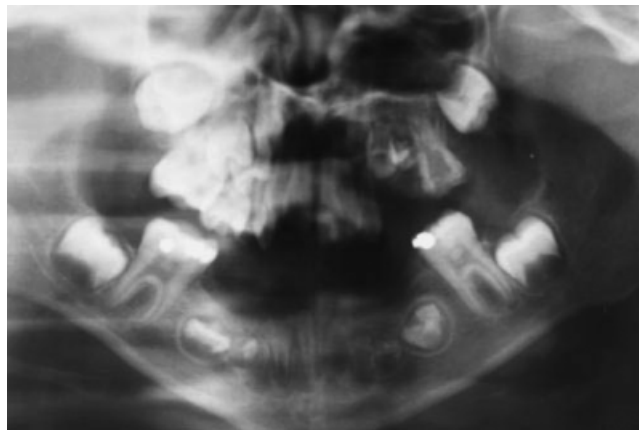
**Co-authors: Sullivan M, Rossitto R, Casey D, Goodloe S III**

*Roswell Park Cancer Institute, Buffalo, NY, USA*

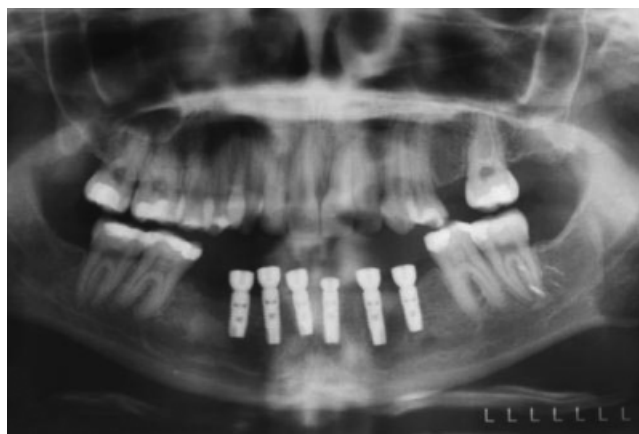**Background and aim:** Regional odontodysplasia (RO) is a rare developmental disorder of the enamel and dentin that results in atypically shaped teeth that often exhibit delayed or failed eruption. The condition usually affects both deciduous and permanent teeth, with only specific areas of the dentition being involved. Treatment is controversial, with no apparent consensus in the literature. Historically, most permanent unerupted teeth affected by RO have been extracted at an early age, thus long-term follow-up of patients and description of implant treatment have rarely been reported. Hemangiomas of the skin overlying areas of involved teeth have been reported in <10 cases, and this case adds additionally to that group. The aim of this paper is to report on a patient with RO who was followed for a period of 16 years, from ages 3 to 19, and resulted in definitive rehabilitation using dental implants and fixed partial prostheses. The definitive treatment procedure will be described.

**Materials and methods:** A 2 1/2 year old girl with diagnosed RO was treated over a period of 16 years in our clinic with

removable prostheses and orthodontics. After skeletal growth was complete, extractions of impacted and unerupted teeth were performed, along with autogenous bone grafting, followed by restoration with dental implants and fixed prostheses.



Age 8



Age 19

**Results:** The successful rehabilitation of a patient with RO using dental implants and fixed prostheses is described. The case is noteworthy due to the fact that the patient was followed over a longer period or time than others in the literature. Treatment culminated in a definitive restoration with dental implants and fixed prostheses, which has been rarely described in the literature. At birth the patient had a capillary hemangioma of the skin in the approximate area overlying the involved teeth, which has only been reported in approximately 10% of case reports. The patient had teeth involved in three quadrants, including the mandibular anterior crossing the midline, again, rarely reported.

**Conclusion:** Regional odontodysplasia can be treated by a multidisciplinary approach, with orthodontics, oral and maxillofacial surgery, and implant prosthodontics all playing a role in the definitive treatment. The final treatment goal after all alveolar growth is completed, is treatment using dental implants and fixed implant prostheses.

## Immediate restoration of small diameter implants in cases of partial posterior edentulism: a four-year cases series

**Presenter:** Nardi D

*Private Practice, Bologna, Italy*

**Co-authors:** Degidi M<sup>1</sup>, Nardi D<sup>1</sup>, Piattelli A<sup>2</sup>

<sup>1</sup>Private Practice, Bologna, Italy, <sup>2</sup>Dental School, Chieti, Italy

**Background and aim:** The aim of this prospective study was to evaluate the use of immediate restorations supported by 3.0 mm diameter implants as a suitable technique for the rehabilitation of partial posterior edentulism.

**Materials and methods:** Forty patients, 18 males and 22 females, with a mean age of 54.7 years (SD = 17.2), with partial edentulism in the posterior region, were consecutively treated with 93 immediately restored 3.0 mm diameter implants. In total 48 and 45 implants were placed in the maxilla and mandible respectively. All implants were placed in healed sites and splinted by the temporary restoration, which was placed in such a way as to avoid occlusal contact. The final restoration was delivered approximately 6 months after implant insertion. Mean marginal bone loss was assessed using standard periapical radiographs immediately after surgery, and at 6, 12, 24, 36 and 48 months follow-up examinations.

**Results:** All implants osseointegrated and were clinically stable at the 6-month follow-up. The accumulated mean marginal bone loss was 1.16 mm (SD = 0.90;  $n = 89$ ) at the 48-month follow-up. No implant fractures occurred.

**Conclusion:** The use of immediately loaded small diameter implants supporting fixed partial restorations is a predictable procedure for the rehabilitation of partial posterior edentulism.

## Immediate and early loading of replace select tapered tiunite implants placed in post-extractive sockets and healed sites. Retrospective analysis of the 5-year clinical outcome

**Presenter:** Mura P

*Private Office, Rome, Italy*

**Co-authors:** Mura P

*Private Practice, Rome, Italy*

**Background and aim:** The use of the Replace Select Tapered TiUnite implant has been retrospectively evaluated in a private practice in Italy.

**Materials and methods:** In routine practice, 61 consecutive patients have been treated with 89 implants. The patients, 24 males and 37 females, had a mean age of 50 years, range 21–76 years, at implant placement. Fifty-one implants were placed in the maxilla and 38 implants were placed in the mandible. Seventy-nine of the implants were placed in extraction sites. Provisional restorations were in occlusion. Seventy-nine implants were loaded immediately and two, five and three implants were loaded in 1, 2 and 3 weeks following placement,

respectively. Fifty-five implants supported single crowns and 34 were splinted for support of restorations. Definitive prosthetic restoration was delivered within 1–4 months following implant placement. Evaluations of soft tissue health and marginal bone remodelling were conducted. An independent radiologist performed the radiographic evaluation using the top of the implant as the reference point with negative values indicating a level below the reference point.

**Results:** Seventy-one implants in 51 patients passed the 5-year follow-up. No implants have failed resulting in a cumulative implant survival rate of 100% (5 years). Three patients, with six implants, withdrew during the course of the follow-up; one patient passed away and two patients moved. At the 5-year follow-up, a majority of the implants demonstrated normal periimplant mucosa and no visible plaque. The mean bone level at 5-year follow-up was  $-2.42$  mm (SD 1.28,  $n = 69$ ) demonstrating a level in line with the first thread. Mean marginal bone loss from implant inserting to 5 years was 0.63 mm (SD 1.96,  $n = 69$ ). Mean marginal bone loss from 3 to 5 years was possible to calculate for 32 implants: 0.13 mm (SD 0.90,  $n = 32$ ).

**Conclusion:** This retrospective 5-year follow-up of Replace Select Tapered TiUnite implants from routine clinical use demonstrates good treatment outcome with regard to implant survival, soft tissue condition and marginal bone response.

## Immediate occlusal loading of single lower molars using Brånemark system® wide platform tiunite® implants: a 5-year follow-up report of a prospective clinical multi-center study

**Presenter:** Calandriello R

*Private Practice, Bologna, Italy*

**Co-authors:** Calandriello R, Tomatis M

*Private Practice, Bologna, Italy*

**Background and aim:** In the posterior mandible, the conventional two stage surgical approach to implant therapy was reported to cause higher bone loss and/or higher implant failures with machined implants due to the peculiar anatomic and physiologic conditions of this area. As the TiUnite® surface favors bone healing, it was hypothesized this surface would also improve the performance of wide implants in posterior mandibles. Based on these assumptions, a protocol for immediately loaded implants for single molar replacement was developed.

**Materials and methods:** The study includes 33 consecutive patients treated in two private dental offices between March 2001 and September 2003 and monitored until September 2008. Main inclusion criteria were: surgical sites healed at least 4 months; vertical bone height allowing for placement of implants at least 8.5 mm long; implant to crown length ratio minimum 1:1; minimum insertion torque of 35 N cm before final seating of the implant neck in the bone.

Patients with uncontrolled diabetes, immune diseases or severe bruxism were excluded. A total of 40 Brånemark System® TiUnite® Wide Platform MK III implants were placed. All implants were provided with provisional crowns in full centric occlusion at the

time of surgery. Patients were clinically and radiologically followed for up to 5 years. An independent radiologist performed the radiographic evaluation using the top of the implant as the reference point with negative values indicating a level below the reference point.

**Results:** Two implant failed so that the cumulative success rate at 5 years was 95.0%. The mean bone level at 5-year follow up expressed as mesial plus distal value averages was  $-1.43$  mm (SD 0.86,  $n=38$ ). The mean marginal bone remodelling expressed as mesial plus distal value averages from implant insertion to 5 years was  $-1.17$  mm (SD 0.90,  $n=38$ ). No adverse events occurred during the follow-up period.

**Conclusion:** Although limited by the number of patients treated in accordance with the protocol adopted, 5-year results encourage the use of immediately loaded single lower molars supported by Brånemark System® Wide Platform TiUnite® implants and further document the clinical advantages of immediate loading protocol and titanium oxidized surfaces.

320	Poster – Topic Long-Term Studies
-----	----------------------------------

### Clinical and microbiological findings around implants: a 1-year prospective study

**Presenter:** Tenenbaum H

*Dental Faculty, Strasbourg, France*

**Co-authors:** Tenenbaum H

*Dental Faculty, Strasbourg, France*

**Background and aim:** Number of studies has pointed to the detrimental effect of pathogenic bacteria on peri-implant tissue health. Early colonization around implants has been characterized in partially edentulous patients, but there is still a lack of data regarding the evolution of the subgingival biofilm over time in correlation with clinical parameters. The purpose of this prospective study was to characterize clinical and microbiological parameters of soft tissues surrounding dental implants placed in partially edentulous patients following a one-stage procedure.

**Materials and methods:** One hundred and ten patients (77 females and 33 males, aged 20–72 years; 14 smokers) and 232 implants were included. Clinical parameters including plaque index, gingival index, sulcular bleeding index, probing depth, recession and clinical attachment level were evaluated at six aspects of each implant by a sole calibrated examiner. Subgingival plaque samples were obtained with paper points and analyzed using a Checkerboard DNA–DNA technique. All parameters were checked at baseline, 3, 6, 9 and 12 months.

**Results:** The mean plaque index ( $0.51 \pm 0.37$  at baseline), gingival index ( $1.14 \pm 0.26$  at baseline) and sulcular bleeding index ( $0.21 \pm 0.23$  at baseline) did not vary significantly during the 1-year follow-up. The main clinical finding was an increase in pocket depth from  $2.65 \pm 0.56$  at baseline to  $2.91 \pm 0.56$  after 1 year. The microbiological analysis demonstrated a slight increase in the percentage of patients in which the presence of the most pathogenic bacteria (*P. gingivalis*, *T. forsythia* and *T. denticola*) could be detected.

**Conclusion:** The results of this prospective study suggest that some clinical and microbiological conditions around implants in partially edentulous patients are susceptible to change over time.

321	Poster – Topic Long-Term Studies
-----	----------------------------------

### A retrospective, clinical evaluation of implant-supported bridges in the edentulous maxilla after up to 5 years in function

**Presenter:** Jönsson G

*County of Västernorrland, Sundsvall, Sweden*

**Co-authors:** Jönsson G, Weiland A, Sandahl L

*County of Västernorrland, Sundsvall, Sweden*

**Background and aim:** The aim of this retrospective clinical study was to evaluate the outcome of complete maxillary bridges, fully or partially supported by Brånemark System Zygoma implants after up to 5 years in function. In addition, patient satisfaction of the function, aesthetics and overall outcome of the treatment were assessed.

**Materials and methods:** A total of 23 non-consecutive patients were included in the study receiving 121 dental implants (69 Brånemark System Zygoma implants, 52 standard implants) between 2001 and 2006. All implants were placed according to a two-stage surgical procedure. The bridges were connected after a mean healing period of 6 months (range: 1 week–15 months). All patients attended a follow-up visit during the fall of 2007 where the clinical stability of the bridges was assessed. In addition, bleeding on superficial probing and the occurrence of plaque were evaluated at each implant site. Any sinus related symptoms or other adverse events were carefully monitored and recorded during the study period. Finally, the patients were asked to fill out a form evaluating the overall outcome of their treatment.

**Results:** The patients were followed for a mean period of 48 months (range: 6–65 months) from the time of bridge connection. At the follow-up visit all implants remained *in situ*. Although all patients had functional bridges at the follow-up visit, the cumulative success rate for the bridges was 73.2% after 5 years. Two bridges were replaced due to fractures and another bridge was temporarily removed due to suspected loss of osseointegration of one of the supporting implants. Healthy mucosa with no signs of bleeding on probing and no visible plaque were registered for 80 and 71% of the implant sites, respectively. The most commonly reported adverse event was loose prosthetic screws. Two patients reported reoccurring colds and sinusitis. Another patient experienced pain caused by overgrowth of mucosa onto the bridge. All patients were satisfied with the functional outcome of their treatment, i.e. chewing ability and speech. All but one patient was satisfied with the aesthetic results.

**Conclusion:** This retrospective study presents encouraging results for complete maxillary bridges fully or partially supported by Brånemark System Zygoma implants after up to 5 years in function.

A five-year prospective, multicenter, randomized-controlled study of the incidence of peri-implantitis for hybrid-dae and fully-dae implants

**Presenter:** Kenealy J

*BIOMET 3i, Palm Beach Gardens, FL, USA*

**Co-authors:** Zetterqvist L<sup>1</sup>, Feldman S<sup>2</sup>, Rotter B<sup>3</sup>, Vincenzi G<sup>4</sup>, Wennström J<sup>5</sup>, Chierico A<sup>4</sup>, Stach R<sup>6</sup>, Kenealy J<sup>6</sup>

<sup>1</sup>Private Practice, Gefle, Sweden, <sup>2</sup>Private Practice, Towson, MD,

USA, <sup>3</sup>Southern Illinois University, Edwardsville, IL, USA, <sup>4</sup>Private Practice, Verona, Italy, <sup>5</sup>Goteborg University, Goteborg, Sweden,

<sup>6</sup>BIOMET 3i Palm Beach Gardens, FL, USA

**Background and aim:** The incidence of peri-implantitis has been reported to be as high as 14% and because peri-implantitis can cause progressive bone loss and is difficult to treat, it often leads to implant failure. Implants with a roughened collar surface are perceived to be at a higher risk for peri-implantitis and other mucosal complications. In 1996 the Osseotite<sup>®</sup> implant (Biomet 3i) was commercially introduced with a 'hybrid' design having a dual acid-etched surface (DAE, Osseotite) extending the length of the implant from the apex to approximately the third thread where a machined surface is present up to the seating surface. Considerations for potential benefits of extending the DAE surface to the seating surface led to this prospective randomized-controlled study designed to assess the risk and incidence of peri-implantitis for fully-DAE-surfaced implants.

**Materials and methods:** Study implants, fully-DAE-surfaced 'test' implants and hybrid-DAE 'control' implants, were placed in a single-stage approach with the seating surface level with the crestal margin of alveolar bone. Transmucosal abutments were placed and after 2 months of healing implants were provisionalized with one of each implant type supporting each prosthesis to ensure that all conditions were consistent between groups. Final restorations were placed at 6 months and patients followed for 5 years at annual intervals. Follow-up evaluations included Sulcus Bleeding Index scores (SBI), probing for suppuration, assessments for mobility, and periapical radiographs to identify radiolucencies and crestal bone levels.

**Results:** One hundred and twelve patients were enrolled and 165 test and 139 control implants were placed supporting 127 prostheses. No substantial differences in mucosal health outcomes between test and control groups were observed throughout the 5-year follow-up. For both groups, 83% of all SBI-scores were '0' – absence of bleeding and 13% of scores were '1' – an isolated bleeding spot. Only one observation of suppuration was recorded and this for a control implant at the baseline evaluation. There was one diagnosis of peri-implantitis for a control implant 3.5 years after implant placement and the condition was subsequently resolved following surgical intervention. Radiographic analyses of crestal bone regression demonstrate that the mean change from baseline (provisionalization) is less for test implants in comparison to control implants ( $P < 0.0001$ ).

**Conclusion:** The results of this 5-year, prospective, multicenter study show no increased risk in soft tissue complications or peri-implantitis for fully-DAE-surfaced implants.

Immediate provisional restoration of screw-type implants in the posterior mandible: 60 months results

**Presenter:** Payer M

*Dental School, Medical University of Graz, Graz, Austria*

**Co-authors:** Payer M<sup>1</sup>, Heschl A<sup>2</sup>, Stopper M<sup>2</sup>, Platzer S<sup>2</sup>, Clar V<sup>2</sup>, Kirmeier R<sup>1</sup>, Jakse N<sup>1</sup>, Pertl C<sup>1</sup>, Wegscheider W<sup>2</sup>, Lorenzoni M<sup>2</sup>

<sup>1</sup>Department of Oral Surgery and Radiology, Dental School, Medical University of Graz, Graz, Austria, <sup>2</sup>Department of Prosthodontics, Dental School, Medical University of Graz, Graz, Austria

**Background and aim:** Aim of this prospective study was to evaluate the clinical outcome of immediately provisionally restored screw-type implants 60 months after implantation in the posterior mandible.

**Materials and methods:** Twenty-three patients (12 females, 11 males) were treated with 40 Xive<sup>®</sup> screw-type implants (Dentsply Friadent, Mannheim, Germany) for the replacement of mandibular molars and premolars. Provisional restoration was performed immediately after implant placement. Radiographic bone levels and implant survival were evaluated 12, 24, 36, 48 and 60 months after surgery by a blinded investigator.

**Results:** At the time of implant insertion the mean coronal bone level was 0.33 mm (SD 0.32). The mean marginal bone level after 12 months was 0.73 mm (SD 0.79), resulting in a significant bone loss ( $P < 0.05$ ). Three of the implants had a bone loss exceeding 2 mm. The mean marginal bone level after 24, 36, 48 and 60 months was 0.67 mm (SD 0.82), 0.64 mm (SD 0.87), 0.69 mm (SD 0.89) and 0.88 mm (SD 1.12) respectively. No implants were lost over the entire period of observation resulting in an implant survival rate of 100%.

**Conclusion:** The present data of immediately loaded implants in the posterior mandible seem to be comparable those of conventionally loaded implants. Yet additional long-term data will be necessary to include this protocol as a standard procedure in treatment concepts for the edentulous posterior mandible.

Osseointegration of dental implants in patients with osteoporosis. A prospective, 3 years follow up study

**Presenter:** Luchetti C

*National University of La Plata, La Plata, Argentina*

**Co-authors:** Luchetti C, Kitrilakis A

*Department of Implant Dentistry, National University of La Plata, La Plata, Argentina*

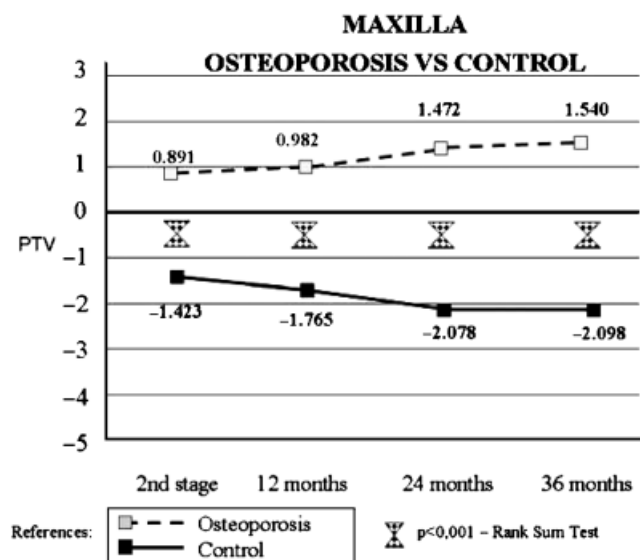
**Background and aim:** Although there is not a contraindication for implant placement in osteoporotic patients, the prognosis in the long term is not clear yet. The aim of this study was to evaluate the outcomes of dental implants in patients with osteoporosis.

**Materials and methods:** Forty-eight female, osteoporotic patients, without medications for osteoporosis treatment, who

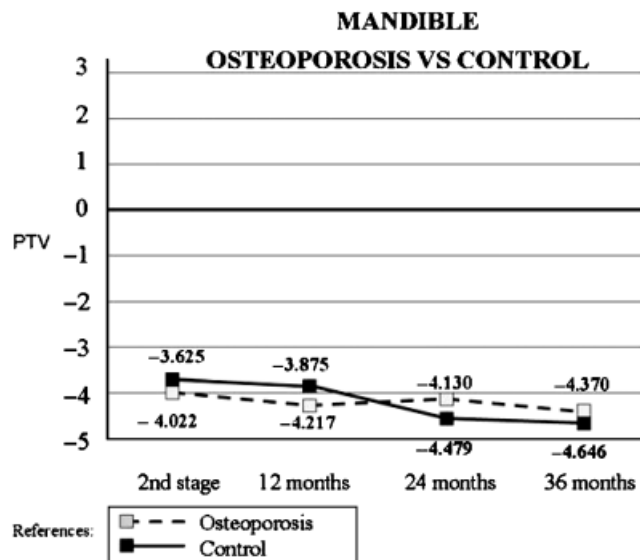
received 101 implants, 55 in the maxilla and 46 in the mandible (Group Os) were selected. Osteoporosis was defined based on bone mineral density (BMD) score utilizing World Health Organization criteria. Forty-eight premenopausal, healthy female patients, under the age of 50, who received 100 implants, 52 in the maxilla and 48 in the mandible, served as controls (Group C). Periotest values (PTV) were recorded at second stage surgery, 12, 24 and 36 months. Dual-energy X-ray absorptiometry (DEXA) was obtained previous to implants placement. Also, osteocalcin and deoxypyridinoline, bone turnover biochemical markers, were obtained preoperatively and at 6 and 12 months, in order to search for correlations with PTV.

**Results:** Success rates in the maxilla were 96.36% (Os) and 98.07% (C). In the mandible, was 100% in both groups. PTV at 2nd stage, 12, 24 and 36 months in the maxilla were for Group Os, 0.891 (3.089); 0.982 (3.618); 1.472 (2.913) and 1.540 (2.092) and for Group C, -1.423 (2.270); -1.765 (2.132); -2.078 (1.820) and -2.098 (1.628). PTV at the same intervals in the mandible were for Group Os, -4.022 (0.856); -4.217 (0.892); -4.130 (1.002) and -4.370 (0.878) and for Group C, -3.625 (1.579); -3.875 (1.606); -4.479 (1.321) and -4.646 (1.229).

VPT differences between both groups in the maxilla were observed at every interval ( $P < 0.001$ ). Nevertheless, the differences between both groups in the mandible were not statistically significant. A correlation was found between BMD at spine and PTV at 12 months for group Os in the maxilla ( $P < 0.001$ ). No correlations were found between biochemical markers and PTV at any interval.



**Conclusion:** In the mandible, local bony quality has shown to be more important, and it was not influenced by the osteoporosis being the PTV similar in both groups. However, in the maxilla, osteoporosis seems to aggravate the local bony condition, compared to the controls. Osteoporosis can be considered a relative risk factor in the maxilla, and of less importance in the mandible. BMD at spine measured by DEXA could be a predictor of outcome in the maxilla. Biochemical markers could be useful to determine the prognosis; however this study has failed to



show correlations. A larger study is needed to draw more detailed conclusions.

325 Poster – Topic Long-Term Studies

## Long-term follow-up study on Astra Tech dental implants

**Presenter:** Dilling M

*University of Heidelberg, Heidelberg, Germany*

**Co-authors:** Mertens C, Dilling M, Steveling H, Mühling J

*Department for Oral and Maxillofacial Surgery, University of Heidelberg, Heidelberg, Germany*

**Background and aim:** The aim of this retrospective study was to evaluate the long-term success of Astra Tech dental implants inserted in the department of oral- and maxillofacial surgery of the University of Heidelberg throughout an average observation period of 10 years. Not only the overall survival rate was analysed but also the crestal bone stability.

**Materials and methods:** This study is based on 86 patients (54 women and 32 men) who received a total of 339 implants (Astra Tech, Mölndal, Sweden). Patients were observed between 7 and 15 years with an average observation period of 9.56 years. All implants have been placed in accordance with the manufacturers' protocol. Implants were functionally loaded with fixed or removable restorations after a healing period of 3–6 months. The patients' annual follow-ups included clinical and radiographic examinations. Intraoral radiographs in right angle technique were performed to determine marginal bone changes. Changes were calculated based upon the measured differences between reference point and the first contact of the crestal bone. Distal and mesial measurements were evaluated statistically.

**Results:** After a mean observation period of 9.56 years, an average marginal bone loss of 1.45 mm (SD 1.36 mm) could be measured. Five implants were lost during the observation period. The cumulative survival rate was 98.53%.



**Conclusion:** The long-term results of this study indicate that Astra Tech implants provide for a high long-term survival rate and low marginal bone loss.

326 | Poster – Topic Long-Term Studies

### Clinical and radiographical evaluation of a platform switched dental implants

**Presenter:** Gultekin BA

*Istanbul University, Istanbul, Turkey*

**Co-authors:** Gultekin BA, Bayraktar M, Ozgen M, Yalcin S  
*Istanbul University, Istanbul, Turkey*

**Background and aim:** Dental implant rehabilitation is one of the most reliable and also predictable treatment methods in edentulous cases. Implant designs and surface structures have been vastly improved for greater success on almost all bone qualities. A platform switching concept consists of using prosthetic components that are undersized in relation to the diameter of the implant collar in order to limit peri-implant bone resorption. The purpose of this study was to evaluate the clinical and radiographical success of a platform switched Ankylos implants.

**Materials and methods:** Totally, 184 dental implants were inserted in 43 patients. Grafted sites, medically compromised patients and smokers were excluded from the study. Twenty-two implants in lower, 29 implants in upper jaw were immediately loaded. One hundred thirty-three implants were loaded in conventional manner (2 and 4 months healing for lower and upper jaw, respectively). Panoramic radiographs were taken right after the operation, at prosthesis delivery and 6, 18, 30 months after prosthesis delivery. The distance from both the mesial and distal margin of the implant collar to the most coronal point where the bone appeared to be in contact with the implant were measured. Peri-implant index scores (Modified Plaque Index, Gingival Index) were also recorded at 6, 18, 30 months after prosthesis delivery.

**Results:** The cumulative survival rate was 99.5%. One implant inserted in posterior upper jaw (4.5/11 mm – conventionally loaded) was lost before loading. Total mean bone loss was  $0.5 \pm 0.03$  mm for all implants. No significant differences were found between immediate and conventional loading respective with peri-implant bone resorption. Implants placed in maxilla were slightly showed more bone loss than mandibular implants. Satisfactory peri-implant index scores were gained ( $\leq 1$ ) in this study. In two patients loosening of the abutment screw was observed.

**Conclusion:** The treatment of edentulous cases using Platform Switched Ankylos implants is suitable for both conventional and immediate loading. The use of prosthetic abutments with a reduced diameter in relation to the implant diameter seems to limit the crestal resorption usually observed during the year following loading. More clinical studies are required to confirm the long-term performance.

327 | Poster – Topic Long-Term Studies

### Evaluation of hard and soft tissue changes after corticotomy-facilitated orthodontics using cephalometric analysis

**Presenter:** Choi B

*UiJeongbu St. Mary's Hospital, UiJeong bu, Korea*

**Co-authors:** Heo HA<sup>1</sup>, Lee W<sup>1</sup>, Choi B<sup>2</sup>, Kim SH<sup>3</sup>, Yun HJ<sup>4</sup>

**Background and aim:** The purpose of this study was to determine the relationship between corticotomy and movement pattern of anterior segment through analyzing changes of soft and hard tissue following perisegmental corticotomy and orthopedic retraction and to find out the factors which cause the decrease of lip protrusion.

**Materials and methods:** Twenty-four adult female patients (average 27.3 years old) who were diagnosed with bimaxillary or maxillary protrusion underwent maxillary corticotomy and anterior segment retraction. Lateral cephalograms taken at pretreatment, postoperative and posttreatment were analyzed.

**Results:** Maxillary central incisor and A point showed statistically significant backward and downward movement following corticotomy. Upper alveolar ridge angle and  $\angle$ SNA also significantly decreased. The most anterior point of upper lip, LS point had a significant backward and downward movement and Nasolabial angle showed a significant increase.

**Conclusion:** Corticotomy-facilitated orthodontic treatment is an effective and appropriate alternative in patients who are diagnosed with maxillary protrusion and are scared of orthognathic surgery.

328 | Poster – Topic Long-Term Studies

### Immediate fluoride modified implant placement in fresh extraction sockets: assessment of the factors of success 24-month follow-up

**Presenter:** Nedelec O

*Paris, France*

**Co-authors:** Nedelec O

*Paris, France*

**Background and aim:** The aim of this retrospective study was to review the esthetic outcomes of single-tooth immediate fluoride modified implant placements and determine the criteria that may influence these results.

**Materials and methods:** This review analyzed after 24 months in function the esthetic outcomes of 50 non-adjacent implant restorations using an immediate surgical placement protocol.

**Results:** A significant change in crown height due to the marginal bone recession of 0.7 (0.30 mm) was recorded for all sites. Thin tissue biotype showed greater recession than thick tissue biotype ( $1.0 \pm 0.83$  vs.  $0.5 \pm 0.31$  mm, respectively). Implants with a buccal shoulder position showed less more three times more recession than implants with a lingual shoulder position ( $1.1 \pm 0.51$  mm vs.  $0.4 \pm 0.29$  mm respectively). The Pink Esthetic Score was 12.62 (1.39) and the

Papillary index according to Jemt was 68% for class 2 and 30% for class 3.

**Conclusion:** Immediate implant placement requires very careful case selection. Long-term prospective studies on bone and tissue stability are, however, necessary to confirm the results of this retrospective review.

329	Poster – Topic Long-Term Studies
-----	----------------------------------

Comparison of ITI and a Xive dental implant systems by using resonance frequency analysis during osseointegration period: a clinical study

**Presenter:** Karabuda ZC

*Istanbul University, Istanbul, Turkey*

**Co-authors:** Karabuda ZC, Abdel-Hak J, Ahemd S, Akilli E, Arici V

*Istanbul University, Istanbul, Turkey*

**Background and aim:** Currently, there is no available clinical tool to evaluate the amount of osseointegration and primary stability around dental implants. It has been recently suggested that changes in the stiffness of an implant in bone during healing may be monitored by using resonance frequency analysis (RFA). The aim of this study was to determine whether RFA can be integrated into the routine clinical evaluation of initial healing of dental implants.

**Materials and methods:** Twenty-four patients (15 females and 9 males; with a mean age of 51.7 years) were included into this study. Total of 94 implants and two different implant systems (Xive-Dentsply Friadent Germany)[64] and ITI (Straumann, Switzerland) [30] were evaluated by using Ostell<sup>®</sup>. A specific transducer for each implant system was used for RFA. ISQ (implant stability quotient) levels were obtained for each implant at the time of surgery, 3 weeks, 6 weeks post-operatively and at the time of loading (3 or 6 months following surgery). Data were analyzed for different healing times, various anatomical locations, implant length and type. Average time in function was 8 months.

**Results:** One implants were failed during healing. Implant stability was higher on mandible compared with maxilla (ANOVA, followed by *Post-hoc* testing  $P < 0.001$ ). The difference seen between posterior and anterior regions were not statistically significant. ISQ levels decreased significantly at 3 and 6 weeks post-surgery compared with readings obtained at the time of surgery ( $P < 0.001$ ). A recovery to the initial ISQ levels was noted at the time of implant loading. The possible effects of different types and lengths of implants to ISQ readings were discussed.

**Conclusion:** Results of this study support the need for a clinical tool to evaluate dental implant stability before loading especially for implants placed on maxilla. Immediate loading with well-controlled occlusal forces may help to manipulate early bone healing/remodeling around dental implants. However, it appears that early loading is riskier than immediate loading. Further studies are needed to compare the early changes seen in immediately loaded dental implants and to determine whether there is any time point in which the total recovery may occur.

330	Poster – Topic Long-Term Studies
-----	----------------------------------

Immediate loading with overdenture in edentulous maxilla

**Presenter:** Piombino M

*Clinic for Periodontal and Implant Surgery, Grumo Nevano, Italy*

**Co-authors:** Eccellente T, Piombino M, Rossi A, Piombino S

*Clinic for Periodontal and Implant Surgery, Grumo Nevano, Italy*

**Background and aim:** This multicenter study report the clinical results of immediate loading in edentulous maxilla with overdenture.

**Materials and methods:** In 82 patients (38 F, 27 M) with edentulous maxilla a total of 328 Ankylos implants were placed (four implants in each maxilla). At the implant placement, patient age ranged 43–78 years. One hundred and thirteen implants were placed consecutive to tooth extraction, 47 within 3 months. Implant length ranged from 9.5 to 17 mm. Following surgery all implants were connected with prefabricated conical abutments, that are manufactured with a precise fit to secondary conical copings. These prefabricated copings are polymerised into denture base directly in the mouth of the patients. Clinical and radiographic evaluation is done in order to monitor soft and hard tissue outcome. Technical complications and patient satisfaction were recorded.

**Results:** During a total observation period of 25.7 months (range 12–66) seven implants were removed, all other implants presented healthy peri-implant soft tissue conditions showing low value of clinical parameters ( $mSBI > 1$ ;  $mPLI = 1$ ). Cumulative survival rate was 97.9%. Radiographic examination showed an excellent bone healing and stable crestal bone level. Four patients were not satisfied with aesthetic of rehabilitation; all other appreciated function, aesthetic and retention of the restoration.

**Conclusion:** Basing on the present data it was concluded that four implants with high primary stability, may support immediate loading in edentulous maxilla.

331	Poster – Topic Long-Term Studies
-----	----------------------------------

Evaluation of implant stability by RFA in immediate loading

**Presenter:** Iliescu AA

*UMF Carol Davila Bucharest, Bucharest, Romania*

**Co-authors:** Alexandru Andrei I, Radita I, Anca D, Alexandru P, Mihai B

*UMF Carol Davila, Bucharest, Romania*

**Background and aim:** This study was performed to observe the stability changes of immediate loaded Screw Plant (Implantdirect, California, USA) dental implants with SBM (Soluble Blast Media) surface placed in both jaw using one-stage surgical procedure by measuring Implant Stability Quotient (ISQ) using Ostell device (Integration Diagnostics AB, Sweden) over a period of 12 weeks.

**Materials and methods:** Eighteen patients (10 females and 8 males, mean age of 53.3 years) were included into this study.

Total 53 Screw Plant (Implantdirect, California, USA) dental implants with SBM (Soluble Blast Media) – 24 (45,3%) implants were placed in the mandible and 29 implants (54,7%) in the maxilla using standard surgical protocol. Osstell's ISQ (implant stability quotient) reading was obtained for each implant: at the time of the placement and after 2, 4, 6, 8 and 12 weeks of healing by single observer. Data were analyzed for different time, various anatomical locations and implant lengths and diameter.

**Results:** The mean primary stability (ISQ) of mandibular and maxillary implants was  $64.1 \pm 7.2$  and  $58.1 \pm 5.3$ , initial stability increased significantly with increasing bone density and stability changes were observed at different times in each case with a tendency to increase after 6 weeks in every case. All implants were clinically stable at the end of the monitoring period.

**Conclusion:** Implant stability is weakest at second to fifth week in all cases because of osteointegration process. There seemed to be a significant difference between maxilla vs. mandible and initial < final RFA values and there was no correlation between implant length and stability. RFA may be used as an objective guideline to determine whether to load the implant (ISQ > 50) immediate or later.

332	Poster – Topic Long-Term Studies
-----	----------------------------------

### Prosthetic rehabilitation with dental implants after enucleation of an odontoma: case report

**Presenter:** Koçak-Berberoğlu H

*Faculty of Dentistry Istanbul University, Istanbul, Turkey*

**Co-authors:** Brkic A<sup>1</sup>, Koçak-Berberoğlu H<sup>1</sup>, Erdem T<sup>2</sup>

<sup>1</sup>Department of Oral Surgery, Faculty of Dentistry Istanbul University, Istanbul, Turkey, <sup>2</sup>Department of Oral Diagnosis and Radiology,

Faculty of Dentistry, Istanbul University, Istanbul, Turkey

**Background and aim:** Odontoma represents one of the most seen benign odontogenic tumours contained from mature enamel, dentin, cementum and pulp tissue. It may appear in two forms; as multiple miniature or rudimentary teeth (compound odontoma), or as amorphous conglomerations of hard tissue (complex odontoma). Clinically, odontoma often interfere with the eruption of permanent teeth and can be involved in delayed eruption or retention of adjacent teeth. The aim of this report is to present a prosthetic rehabilitation with dental implants in posterior mandible, after surgical enucleation of complex odontomas.

**Materials and methods:** A 27 years old female patient was referred to our department, with a complaint of swelling from the right side of posterior mandible, which was present for 2 years. Clinical examinations disclosed a hard consistent bone expansion in the region of the lower first and second molar teeth from the vestibule side of the jaw. A panoramic radiographs revealed two well circumscribed radioopaque masses, located between and under the roots of the teeth. Under local anesthesia it was performed enucleation of odontomas with extraction of the first and second molars. One year after follow-up period, the missing teeth were replaced with dental implants, following the routine oral implant protokol. Two ITI Standard Plus Implant's

with lengths of 10 and 12 mm and diameters of 3.3 and 4.1 mm, were placed at the former element sides of the first (10 mm, 3.3 mm) and second molar tooth (12 mm, 4.1 mm).

**Results:** The patient is under follow-up for 4 years without any complications.

**Conclusion:** Dental implants are the best solution, for replacement of missing teeth, especially in the cases of good bone preservation. In some cases of treated jaw cysts or benign tumours, the prosthetic rehabilitation with dental implants can give very good results. However, a long-term follow up is necessary to avoid an unnecessary complications such are recurrences or implant failure.

333	Poster – Topic Long-Term Studies
-----	----------------------------------

### A multi-centre study of an innovative wide body implant for molar replacement

**Presenter:** Ackermann A

*Private Practice, Johannesburg, South Africa*

**Co-authors:** Vandeweghe S<sup>1</sup>, Tsjachaloff A<sup>2</sup>, Bronner J<sup>3</sup>, Ackermann A<sup>4</sup>, Hattingh A<sup>5</sup>, De Bruyn H<sup>1</sup>

<sup>1</sup>Department of Periodontology & Oral Implantology, University Hospital, University of Ghent, De Pintelaan 185, 9000 Ghent,

Belgium, <sup>2</sup>Private Practice in Maxillofacial Surgery, Pinneberg,

Germany, <sup>3</sup>Private Practice in Prosthodontics, Pietermaritzburg, South

Africa, <sup>4</sup>Private Practice in Prosthodontics, Johannesburg, South

Africa, <sup>5</sup>Private Practice in Periodontics, Sevenoaks, UK

**Background and aim:** Wide body implants have previously been advocated for use as 'rescue' implants in compromised sites e.g. in failed implant sites or in order to achieve improved primary stability in areas of poor bone quality. Consequently, poorer results for wide-bodied implants have been reported compared with regular diameter implants. The aim of this study was to retrospectively evaluate the outcome of a new wide body implant (MAX<sup>®</sup> implant, Southern Implants<sup>®</sup>, Irene, South Africa) specifically designed for immediate placement in molar extraction sockets.

**Materials and methods:** Patients with at least one MAX implant were examined by two independent examiners in four private practices to determine implant success and survival. Clinical evaluation included assessment of the peri-implant tissue condition (probing depth, plaque and bleeding index) and prosthetic outcome. The level of patient satisfaction was determined from completion of the OHIP-14 questionnaire. Radiographic evaluation included a baseline radiograph at implant placement and a new radiograph at time of evaluation to measure bone level changes. In 14 cases, a cone-beam scan was taken to evaluate the buccal and lingual/palatal bone levels.

**Results:** A total of 75 patients (31 males, 44 females), mean age 58, were treated with 93 MAX implants (59 in the maxilla, 34 in the mandible). The maximum diameter of the tapered implants was 8, 9 or 10 mm. Twenty-nine implants were immediately loaded and 69 were immediately placed in molar extraction sockets. Mean follow-up period was 14 months (3–34). In total four implants failed (4.3%). Mean bone loss 1 year after surgery was 0.46 mm (SD 1.08; range – 5.45 to 3.25). The success rate,

based on bone loss < 1.5 mm during the first year, was 91.4% at implant level. No correlation was found with smoking, implant position, loading protocol, timing of implant placement or prosthetic variables. OHIP scores revealed high patient satisfaction.

**Conclusion:** The MAX implant demonstrated a good survival rate of 95.7% and stable bone conditions after 1 year, with very limited bone loss. Demanding situations including immediate loading or immediate placement in the posterior jaw had no negative influence on treatment outcome.

#### 334 Poster – Topic Long-Term Studies

### Tooth agenesis: patient characteristics and treatment concepts of the Bernhard Gottlieb School of Dentistry

**Presenter:** Heuberger S

*Bernhard Gottlieb University Clinic of Dentistry, Vienna, Austria*

**Co-authors:** Heuberger S, Mair B, Fögl A, Gruber R, Watzek G

*Clinic of Dentistry, Bernhard Gottlieb University, Vienna, Austria*

**Background and aim:** To provide the patient characteristics and treatment concepts of tooth agenesis at Bernhard Gottlieb School of Dentistry from 1992 to 2007.

**Materials and methods:** Patients with the primary diagnosis of agenesis, oligodontia, hypodontia, or aplasia were identified through computer- and hand-based survey.

**Results:** A total of 304 patients (172 females, 132 males) were assigned with the primary diagnosis of agenesis, oligodontia, hypodontia, or aplasia. The mean age of patients at the date of primary diagnosis was 16.4 years. The averaged number of missed teeth was seven per patient, with mainly the lower second premolar being absent at a prevalence of the order of 17.4%. At the time of the survey, 104 patients have completed their therapy at an average duration of 47 months. Among these patients, 93 obtained a fixed prosthetic restoration. Eighty-seven patients are currently under treatment for agenesis, oligodontia, hypodontia, or aplasia. At the time of survey, 60 patients underwent external augmentations, 24 patients received maxillary sinus elevation, and 11 patients had distraction osteogenesis. In total, 537 dental implants were placed in 141 patients. Transplantation of 16 teeth was carried out in 14 patients.

**Conclusion:** The Department of Oral Surgery at the Bernhard Gottlieb School of Dentistry is a center for the treatment of tooth agenesis. Based on this set of data we now gain further information that helps us with treatment planning in young individuals with tooth agenesis.

#### 335 Poster – Topic Long-Term Studies

A 5-year prospective follow up study on 136 patients treated either with implants with a machined surface (Brånemark MK III) or an oxidized surface (Brånemark tiunite Mark III). One stage, two stage and immediate loading protocols are used

**Presenter:** Jungner M

*Karolinska University Hospital, Stockholm, Sweden*

**Co-authors:** Jungner M<sup>1</sup>, Lundgren S<sup>2</sup>, Lundqvist P<sup>3</sup>

<sup>1</sup>*Department of Oral- and Maxillofacial Surgery, Karolinska*

*University Hospital, Stockholm, Sweden, <sup>2</sup>Department of Oral- and*

*Maxillofacial Surgery, Umeå University, Umeå, Sweden, <sup>3</sup>Private*

*Clinic, Umeå, Sweden*

**Background and aim:** As osseointegrated dental implants have become a treatment of choice more widely, an increasing amount of publications have focused on the possibilities to reduce the healing time in favour of functional loading. Primary stability of the implants, at the time for surgery is considered to be the key factor for success. For this reason focus is set on shape and surface characteristics of the implants to increase the success rate, and reduce the overall treatment time.

**Materials and methods:** A total of 136 patients, were treated with Nobel Biocare, Implants. Totally 394 implants were placed, of which 199 were oxidized titanium implants (Nobel Biocare, TiUnite<sup>TM</sup>) and 195 with turned titanium surface (Nobel Biocare, Mark III<sup>TM</sup>). Sixty-three patients underwent a one-stage surgical protocol, of which 24 where objected to early functional loading. The remaining 73 patients were treated with a traditional two-stage surgical protocol. Patients were examined, after at least 5 years of loading after receiving the supra-construction. Clinical examination regarding signs of peri-implantitis, bleeding on probing, the cantilever extensions of the supra-constructions and gingival pocket depth on the distal and mesial aspect of each implant are recorded. All patients also have undergone an examination by digital intra-oral X-rays, for recording and describing the marginal bone level. The bone level and marginal bone loss on each implant on the digital X-rays are measured using a computer-based software for standardized calibration and ability to show real-world distances.

**Results:** Preliminary results are that eight implants were lost in six patients (three males and three females), seven in the maxilla and one in the mandible. All failed implants were Mark III implants, inserted following the traditional two-stage protocol. The implant success rate was 98.2% for the whole patient group, divided as a 100% success rate following the implants with oxidized surface (Nobel Biocare, TiUnite<sup>TM</sup>) compared with a success rate of 96.4% with implants with turned surface (Nobel Biocare, Mark III<sup>TM</sup>). The marginal bone level and the presence of peri-implantitis in the groups will be analysed during spring 2009 and reported.

**Conclusion:** Implants with oxidized surface (Nobel Biocare, TiUnite<sup>TM</sup>) seems in our study to have an increased survival rate compared with implants with turned surface (Nobel Biocare, Mark III<sup>TM</sup>). Results of the radiologically examined marginal bone level will be reported.

## Management of severe hypodontia with bone grafting procedures and implant restorations

**Presenter: Keller P**

*Privatzahnklinik Schloß Schellenstein, Olsberg, Germany*

**Co-authors: Keller P, Khoury F**

*Privatzahnklinik Schloß Schellenstein, Olsberg, Germany*

**Background and aim:** Congenital absence of teeth is a common dental anomaly but severe hypodontia, where six or more permanent teeth excluding third molars are absent, has a much lower prevalence. Hypodontia shows a high proportion of affected individuals with previous history of congenital absence of teeth. Frequently these patients have limited development of the alveolar process, tooth malposition and loss of vertical dimension.

**Materials and methods:** Between 1996 and 2007, 15 patients (nine females and six males) affected by severe hypodontia were treated with implants. The average of missing teeth of the patients was 12. Placement of implants can be accomplished only when skeletal maturity is completed. Particularly important is an adequate interim restoration to ensure functional, aesthetic and psychological well being of the patient. A splint therapy is realised in adolescents to achieve the optimal vertical dimension. One hundred and forty-one titanium implants were placed by the patients with an average age of 19 years (range 17–22 years). Twenty-eight sinus floor augmentations were performed. Several lateral and vertical bone augmentations of the alveolar process were performed using autogenous bone grafts mostly harvested from the mandible. The implants were inserted at the same time or 3–4 months after the bone augmentation. Fixed implant-prosthetic restorations were performed. The average follow-up period was 64 months.

**Results:** In affected patients, the extensive lack of both deciduous and permanent teeth results in an important atrophy of the alveolar processes. Autogenous bone block grafting allows predictable bone augmentation in three dimensions. The quality and quantity of bone are the first indicators of long-term stability of implants. The 141 implants were osseointegrated, no implant was lost after their prosthetic restoration. Soft-tissue surgery allowed a greater width of keratinized gingiva necessary for hygiene maintenance and aesthetics. Follow-up has shown orthodontic stability, periodontal health and peri-implant bone levels adequately stable.

**Conclusion:** Patients affected with congenital absence of multiple teeth are appropriate candidates for tooth replacement using osseointegrated implants. Bone augmentation and soft tissue management to optimize aesthetics and longevity are needed for replacement of missing tissues. The comprehensive treatment planning with good coordination of orthodontists, prosthodontists and oral surgeon are decisive for a successful treatment outcome.

## Care and aftercare related to implant-retained dental crowns in the maxillary aesthetic region: a 5-year prospective randomized clinical trial

**Presenter: Visser A**

*University Medical Center Groningen, Groningen, The Netherlands*

**Co-authors: Visser A<sup>1</sup>, Raghoobar G<sup>1</sup>, Meijer H<sup>1</sup>, Meijndert L<sup>2</sup>, Vissink A<sup>1</sup>**

**Background and aim:** Of all published data on implant-retained single-tooth replacements, most studies report on surgical aspects, osseointegration, implant designs, implant characteristics, pain assessment, early loading, immediate loading and/or immediate placement, surgical/augmentation techniques, guided bone regeneration, and (soft) tissue aspects. To the best of our knowledge, there are no detailed studies focusing on the need for surgical and prosthetic care and aftercare related to implant-retained dental crowns. Therefore, the aim of this study was to prospectively assess surgical and prosthetic care and aftercare related to the placement of implant-retained dental crowns after local bone augmentation in patients missing one tooth in the maxillary aesthetic region.

**Materials and methods:** Ninety-three patients were randomly allocated to one of three local augmentation groups: (1) chin bone, (2) chin bone covered by a Bio-Gide<sup>®</sup> membrane, and (3) Bio-Oss<sup>®</sup> covered by a Bio-Gide<sup>®</sup> membrane. After local augmentation, implant placement (ITI) and fabrication of an implant-retained dental crown (cemented metal–ceramic dental crown) was performed. Prosthetic and surgical care and aftercare was scored from the first visit until 5 years after the augmentation of the implant region.

**Results:** The need for care and aftercare was comparable between the local augmentation groups. Three implants were lost (5-year implant survival rate: 96.7%). Surgical aftercare was needed in 9% of patients and consisted of care related to peri-implant tissue problems. Prosthetic aftercare was needed more often: all patients needed periodic routine inspections, 63% needed supplemental oral hygiene support and 16% needed additional prosthetic care, mainly consisting of fabricating new crowns (12%).

**Conclusion:** The need for surgical and prosthetic aftercare is minor. The method used for augmentation was irrespective of the patients' need for aftercare.

## The comparison of treatment outcome between autogenous block bone graft and distraction osteogenesis

**Presenter: Kook M**

*Chonnam National University, Gwang-Ju, Korea*

**Co-authors: Kook M, Uttom KS, Jung S, Park Y, Park H, Oh H, Ryu S**

*Chonnam National University, Gwang-Ju, Korea*

**Background and aim:** The goal of this study was to evaluate the resorption rate and comparison of resorption between autogenous

block bone graft and distraction osteogenesis to reach a decision about their maintenance ability.

**Materials and methods:** All 33 patients with 38 partially edentulous jaws were selected for this study, 24 areas were augmented by autogenous block bone graft (ABBG), remaining 14 were reconstructed by distraction osteogenesis (DO). Vertical resorption of the grafted bone, peri-Implant bone resorption and complications at different treatment stages were assessed by means of radiographic study and clinical examination to reveal the ultimate outcome of esthetic and functional rehabilitation.

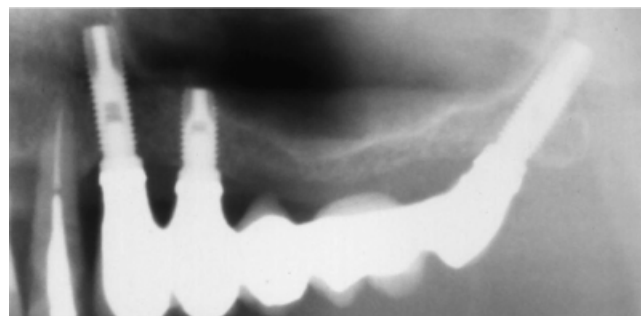
**Results:** The mean vertical bone gains for ABBG vs. DO were 5 and 6.2 mm, conversely the final vertical bone resorption were 1.7 mm (SD 1.0) and 1.1 mm (SD 0.8). The mean follow up period for ABBG and DO were 30.9 and 35.8 months. Two patients of ABBG showed complete bone resorption within 3 months of augmentation. Total 41 implants were placed on those 24 bone graft sites. The cumulative success and survival rate of implant for ABBG were 85% and 100%. On the other hand one failure occurred in DO group, since the gained bone was resorbed completely before implant placement and 49 implants were installed in 14 DO site, the cumulative success and survival rate were 92% and 100%. Beside this 38.88% and 58.33% minor complications were recorded for ABBG and DO, respectively.

**Conclusion:** Implant survival and success rate were almost same. Eventually both groups are effective for reconstruction of the deficient alveolar ridge but distraction osteogenesis is preferable for the large area augmentation.

by flapless surgery. Clinical follow-up was performed annually and parallel X-rays were taken to measure bone level. RFA was taken as of 2004.

**Results:** Cumulative success rate obtained was 96.6% (98.63% CSR for parallel walls implants and 93.61% CSR for tapered implants) The CSR in relation to diameter and shape was significant while it was not significant in relation to length. Smoking habit, bruxism, loading time and flapless or open surgery did not have significant differences also. Bone level was according to the literature (Albrektsson et al 1986, 1993; Ibanez et al 2005). A mean ISQ of 55.3 was obtained after healing period, only two implants were below 50.

**Conclusion:** Pterygomaxillary implants are a predictable treatment option. Placement in native bone and a short healing period compared with bone grafting procedures makes them an excellent alternative for the treatment of the atrophic posterior maxilla.



339 Poster – Topic Long-Term Studies

### Performance of double acid-etched pterygomaxillary implants: a clinical 1–10 years follow-up

**Presenter:** Ibañez JC

*Circulo Odontologico de Cordoba, Cordoba, Argentina*

**Co-authors:** Ibañez JC<sup>1</sup>, Monqaut J<sup>1</sup>, Juaneda A<sup>1</sup>, Tahhan M<sup>1</sup>, Ibañez C<sup>2</sup>, Juaneda S<sup>2</sup>

<sup>1</sup>*Circulo Odontologico de Cordoba, Cordoba, Argentina, <sup>2</sup>Programa de Formacion de Post-Grado en Implantes Oseointegrados, Cordoba, Argentina*

**Background and aim:** Pterygomaxillary implants are an alternative to bone grafting in the atrophic posterior maxilla. The aim of this investigation was to test the long-term clinical performance of double acid-etched implants placed using this technique.

**Materials and methods:** One hundred and twenty pterygomaxillary implants were inserted during a 1–10 years period in 82 consecutive patients. All of them were double acid-etched surface implants (Osseotite) and were splinted with at least to one more implant. Seventy-three implants were parallel walls ones and 47 were tapered. Twenty-nine implants were placed in smokers and 57 in bruxers. The width of the implants used was 3.75, 4 and 5 mm while the length was 11.5, 13, 15 and 18 mm according to bone morphology. Forty-nine implants were immediate loaded while 71 were deferred loaded (mean time for loading: 3.7 months). Forty-five implants were placed

340 Poster – Topic Long-Term Studies

Patient satisfaction after receiving dental implants with immediate loading in the atrophic maxilla, using the ohip questionnaire, 1 year results

**Presenter:** Erkapers M

*Uppsala County Council, Uppsala, Sweden*

**Co-authors:** Erkapers M<sup>1</sup>, Ekstrand K<sup>2</sup>, Thor A<sup>3</sup>, Toljanic JA<sup>4</sup>, Baer RA<sup>4</sup>

<sup>1</sup>*Uppsala County Council, Uppsala, Sweden, <sup>2</sup>University of Oslo, Oslo, Norway, <sup>3</sup>University of Uppsala, Uppsala, Sweden, <sup>4</sup>University of Chicago, Chicago, IL, USA*

**Background and aim:** Ability in analyzing and understanding patient assessment is crucial in developing implant technology further. This study evaluated patient satisfaction for patients receiving six implants in the upper jaw and an implant-supported bridge within 24 h after surgery using the Oral Health Impact Profile (OHIP) questionnaire.

**Materials and methods:** Fifty-one patients who were edentulous in the upper jaw were included in the study, which were performed at two centers. Six implants were placed in the maxilla and loaded with a temporary restoration within 24 h after installation of implants. Twenty–24 weeks later the permanent restorations were delivered. Patients were asked to complete the OHIP questionnaire before implant surgery and at three occasions throughout treatment. Data was collected and

analyzed as one solid group from both centers as well as in-between groups.

**Results:** Baseline satisfaction scores for the two different centers displayed no statistical differences. Treatment resulted in improved total OHIP scores in both centers, with no significant difference in-between centers. Furthermore, no significant differences were observed in any of the individual pre- and post-treatment OHIP domains between centers. All seven subgroups showed a statistically significant improvement in their post treatment OHIP score, whereas center 1 had a larger improvement in the psychological discomfort group compared with center 2.

**Conclusion:** Results from the OHIP questionnaire displayed increasing patient satisfaction after treatment with a fixed restoration on implants in the atrophic maxilla loaded within 24 h.

341	Poster – Topic Long-Term Studies
-----	----------------------------------

### Clinical evaluation of a new implant after the loading of the first 100 fixations

**Presenter:** Miguel B

*Hospital Quirón valencia, Benifaió, Valencia, Spain*

**Co-authors:** Beltrán M, Pascual A

*Hospital Quirón, Valencia, Spain*

**Background and aim:** The aim of this study is to report clinically and radiographically the effectiveness of a new implant as a solution in a variety of clinical situations.

**Materials and methods:** One hundred titanium implants (Internal, BioHorizons, Birmingham, USA) were inserted in a wide variety of anatomic situations. The implants were evaluated at the time of placement, at the time of loading (8–12 weeks before the surgery) and 2 months post-loading.

**Results:** Ninety-nine of the 100 implants were considered to have achieved a successful osseointegration and were loaded with cemented fixed restorations (95) or with Locator attachments (4). At the 2 months post-loading evaluation, the stability of the restorations was satisfactory in terms of clinical and radiographic evaluation.

**Conclusion:** Based on this early evaluation, BioHorizons Internal implants appears to be a successfully and predictable treatment option in partially or fully edentulous patients.

342	Poster – Topic Long-Term Studies
-----	----------------------------------

### Immediate implant-supported overdentures in dentulous mandible

**Presenter:** D'Errico M

*Clinic for Periodontal and Implant Surgery, Grumo Nevano, Italy*

**Co-authors:** Eccellente T, Piombino M, Rossi A, Capasso S  
*Clinic for Periodontal and Implant Surgery, Grumo Nevano, Italy*

**Background and aim:** To present a clinical result of immediate loading in edentulous mandible with overdenture.

**Materials and methods:** In 77 patients (44 F, 33 M), a total of 308 Ankylos implants were placed in edentulous mandibles (four

inter-foraminally implants in each jaw) and immediately loaded. One hundred and twenty-two implants were immediately inserted into fresh extraction sockets; 47 were delayed implants. Implant length ranged from 9.5 to 14 mm. Following implant placement, the SynCone abutments were screwed on the implants. These abutments are manufactured with a precise fit to prefabricated secondary conical copings, that are polymerised into the denture base directly in the mouth of the patients. Panoramic radiographs at implants placement, 6 months later and annually; mSBI and mPLI in different time intervals were recorded. Technical complications and patient satisfaction was evaluated.

**Results:** During the healing period four implant were removed. After a total observation period of 36 months (range 18–72 months) all other implants presented healthy peri-implant soft tissue conditions showing low value of clinical parameters (mSBI=1; mPLI=1). Implant success rate was 98.7%. X-ray showed an excellent bone healing and stable crestal bone level. Two patients were not satisfied with aesthetic of rehabilitation; all other appreciated function, aesthetic and retention of the restoration.

**Conclusion:** The present data, validates the predictability of immediate loading in edentulous mandible with overdenture.

343	Poster – Topic Long-Term Studies
-----	----------------------------------

### Immediate non-occlusal loading in partially dentulous patients

**Presenter:** Capasso S

*Clinic for Periodontal and Implant Surgery, Grumo Nevano, Italy*

**Co-authors:** Piombino M, Eccellente T, Capasso S, Piscitelli A

*Clinic for Periodontal and Implant Surgery, Grumo Nevano, Italy*

**Background and aim:** To report the efficacy of immediate non-occlusal loading in partially edentulous patients.

**Materials and methods:** Sixty-three Ankylos implants (Dentsply, Friadent, Mannheim, Germany) were inserted in 32 partially edentulous patients (18 females, 14 males). Age at implants placement ranged between 22 and 64 years (mean 39.9 years). Twenty-one implants were loaded with single crowns in anterior Maxilla, 42 implants with 10 bridgework. The total number of units replaced was 79. Implants in the mandible and in the maxilla were 23.8% and 76.2%, respectively. Twenty-six implants were placed consecutive to tooth extraction. Implant length ranged from 9.5 to 14 mm. All implants were immediately restored with acrylic non-occluding temporary restoration. Two months nutritional limitations are advised. After 3–6 months full occluding restorations were provided. Patients were scheduled for follow-up at 6 months, 1 year and annually. mPLI, mSBI, standardized periapical radiographs, technical complications and patients satisfaction were recorded.

**Results:** One single implant restoration was removed for mobility 5 weeks after placement. One implant supporting bridge-work in Maxilla was removed 9 months after placement. After a

total observation period of 36 months (range 24–50 months) the overall survival rate was 96.8%. All implants presented a healthy peri-implant soft tissue conditions (mSBI > 1; mPII > 1), and stable gingival contour. Radiographic mean bone loss evaluating both interproximal surfaces was 0.58 mm (range 0.34–1.63 mm). No technical complication occurred. All patients appreciated treatment modality, one patient was not satisfied with the aesthetic.

**Conclusion:** Implants can be successfully loaded immediately in partially edentulous patients. The implant design and surface make a significant contribution to the primary stability of the implant.

#### 344 Poster – Topic Long-Term Studies

**Presenter:** Badalov E

*Faculty of Dentistry, Istanbul University, Istanbul, Turkey*

**Background and aim:** The aim of this study to evaluate the complications of implant supported restorations which are fabricated by using Straumann (Straumann Waldenburg, Switzerland) implants.

**Materials and methods:** Two hundred fifty-six dental implants were inserted to 56 patients (30 males, 26 females) and restored with 99 prostheses. Twenty overdenture (12 ball, 8 bar retained) and 79 fixed prostheses (50 cemented, 29 screw-retained) were fabricated. Loosening of abutment and prosthesis screw, desimentation, fracture of porcelain veneer fracture, bar and dentures were regarded as prosthetic complications

**Results:** Follow-up time ranges in 1–5 years. Twenty-six complications in fixed prosthesis and 19 complications in removable prosthesis were observed.

**Conclusion:** More complications were observed in removable restorations, ball attached prosthesis and screw-retained prosthesis.

#### 345 Poster – Topic Long-Term Studies

Radiographic evaluation of marginal and crestal bone level around different implant neck designs and inter-implant distance

**Presenter:** Chung YJ

*Yonsei, Seoul, Korea*

**Co-authors:** Chung Yj, Han Ch, Kim SJ

*Yonsei Seoul, Republic of Korea*

**Background and aim:** For esthetic and functional implant restorations, marginal bone loss at the bone-implant interface and inter-implant crestal bone loss should be minimized. The objective of the present study was to evaluate the influence of macro-, microstructure of implant by observing the resorption pattern of marginal bone and crestal bone in three kinds of implants with different neck designs after 1 year of loading.

**Materials and methods:** The implants were placed in the molar region that had lost more than two teeth. Among these, the groups with an inter-implant distance of 1–2.5 mm (Group A) and 3–4.5 mm (Group B) were selected as subjects. The types of

the implants used were 32 Restore (Lifecore, Chaska, MN, USA), in which the upper part had a machined surface and the lower part had a rough surface blasted by calcium phosphate, 30 Ankylos (Friadent GmbH, Mannheim, Germany) with polished surface necks, and 32 Oneplant (Warantec, Seoul, Korea) with a rough-surfaced neck with microthreads.

**Results:** The marginal bone loss and crestal bone loss 1 year after functional loading was analyzed statistically, and the following are the results. (1) The marginal bone loss 1 year after functional loading, the three types of implant showed a statistically significant difference with no correlation to the inter-implant distance. Oneplant showed the least marginal bone loss with average of  $0.07 \pm 0.14$  mm. The marginal bone loss showed no significant difference according to the inter-implant distance in the same system. (2) Oneplant showed the least crestal bone loss with average of  $0.05 \pm 0.06$  mm, and it showed a statistically significant difference with other systems. (3) In comparing the crestal bone loss according to inter-implant distance in the same system, there was no statistically significant difference in Oneplant and Ankylos, but Restore showed a significant difference.

**Conclusion:** According to these results, the marginal and crestal bone loss were effected by the implant neck designs and surface characteristics, and it can be thought that microthread and rough surface attribute to the stability of marginal and crestal bone. Also, when the implants had microthread and rough surfaces, the crestal bone loss was minimized even when the inter-implant distance was < 2.5 mm, and showed no significant difference as when the distance was > 3 mm.

#### 346 Poster – Topic Long-Term Studies

Long-term studies

**Presenter:** Peña P

*European Implantology Forum, Madrid, Spain*

**Co-authors:** Peña DP, Palomero DR, Palomero DR Jr., Areses DR

*European Implantology Forum, Madrid, Spain*

**Background and aim:** To compare the behavior of two implant systems by using the same surgical protocol.

**Materials and methods:** Three hundred implants have been placed in 48 patients using the Nobel guide surgical protocol being immediately loaded within the next 24 h with a fixed prosthesis. One or two Nobel Biocare Replace implants were randomizely placed in the maxillary arch. The rest were Replant implants (Implant Direct). X rays were taken the day of placement, 6 months and 1 year later and bone measurements were performed around the implant platform.

**Results:** Only four implants failed to osseointegrate (three Nobel and one ID), all the rest of the 296 implants were successfully restored with fixed screw retained prosthesis. Implant bone levels were between 0 and 1.25 mm of bone resorption/remodeling which is in consistency of previous results.

**Conclusion:** Within the limits of this clinical study it can be concluded that both implant systems are equally successful used with a computer-guided immediately loaded surgical protocol.



## Survival-rate of 469 implants of two different diameter-reduced implant-systems over a 7.75 years period

**Presenter:** Karapetian V

*University of Cologne, Cologne, Germany*

**Co-authors:** Karapetian VE, Roels M, Joerg N, Zoeller J

*Uni-Koeln, Köln, Germany*

**Background and aim:** Implants with small diameters may be used where bone width is reduced but sufficient vertical bone height is available, or in single-tooth gaps with limited mesio-distal space, such as for the replacement of frontal and lateral maxillary or mandible incisors. The purpose of this study was to compare the prognosis of narrow implants (2.8–3.8 mm diameter) of two different implant systems (XIVE and templant).

**Materials and methods:** Over 93-month period, 469 narrow implants were inserted in 108 patients to support partial fixed prostheses and single-tooth crowns. Clinical and radiographic assessment data were provided.

**Results:** Five of 355 XIVE implants (1.4%) failed. Two of 114 templant implants (1.8%) failed. Cumulative survival and success rates were calculated with life-table analyses processed by collecting clinical and radiographic data. For XIVE implants, the cumulative survival rate was 98.6%. For templant implants, a cumulative survival rate of 98.2% was found. Cumulative survival and success rates of the two examined small diameter implant systems were not statistically significant different ( $P > 0.05$ ).

**Conclusion:** We suggest from these results, that there seems to be no significant difference between these two diameter-reduced implant systems. An important advantage seems to be, that by using a small diameter implant on patients with reduced bone width, dental practitioner can forgo a lateral augmentation.

## One year results of a clinical and radiological prospective swedish multicenter study of Neoss dental implants

**Presenter:** Dahlin C

*University, Gothenburg, Sweden*

**Co-authors:** Dahlin C, Widmark G, Bergqvist G, Kashani H, Furst B, Widbom T

*University of Gothenburg, Gothenburg, Sweden*

**Background and aim:** Neoss dental implant system has recently been introduced on the clinical arena. Early clinical and laboratory studies have demonstrated excellent bone response in the early healing phase and the clinical setting. The aim of this prospective study was to follow a large number of consecutively treated patients, with Neoss dental implant system, both clinically and radiographically. The current report constitutes the 1-year data of a planned 5-year study.

**Materials and methods:** The study included a total of 177 patients treated with 590 Neoss implants at 13 clinics in Sweden. The material comprised of 72 males and 105 females. The majority of patients were older than 50 years at the time of

implant placement. Of 177 included patients, 125 were treated with a two-stage protocol, 46 with a one-stage protocol (six of them with immediate function) and six with one-stage and two-stage in different regions of the jaw. The distribution within the material was 38 patients receiving single tooth replacement, 77 patients with partial reconstruction and 60 fully edentulous patients. Two additional patients had a single tooth replacement and a partial reconstruction in the same jaw. Radiographic evaluations were performed.

**Results:** Out of 590 implants, 11 early failures have been reported, giving a 1 year cumulative survival rate of 98.1%. The majorities of the failures were part of a full jaw therapy and located to the maxilla. Evaluation of function and esthetics at the 1 year visit resulted in 100% success for function and 98% success for the esthetic outcome. The number of withdrawal patients during the first year was 4. No adverse effects of the Neoss dental implants were reported, and complications were few and similar to those reported for implant treatment in general.

**Conclusion:** The present investigation showed a high cumulative survival rate of 98.1%. Marginal bone resorption was within normal ranges. No adverse effects of the Neoss implants were reported, and complications during the study period were few and similar to those reported to for other well documented implants system. Based on the present data collected in a multicenter setting, we conclude that Neoss dental implant is a safe predictable implant system. However, a continuous long-term follow-up is needed.

## Unconventional implants for distal extension fixed full-arch implant-supported dentures

**Presenter:** Saulacic N

*University of Berne, Berne, Switzerland*

**Co-authors:** Saulacic N<sup>1</sup>, Minoretti R<sup>2</sup>, Triaca A<sup>2</sup>

<sup>1</sup>Department of Cranio-Maxillofacial Surgery, University Hospital, University of Berne, Berne, Switzerland, <sup>2</sup>Center for Maxillofacial Surgery, Pyramide Clinic, Zurich, Switzerland

**Background and aim:** Excessive cantilever length of fixed implant-supported prosthesis may risks functional and bio-mechanical disadvantages. Here, we report the clinical outcome of unconventional implants placed in severely resorbed posterior ridges, in patients in whom the pre-implant surgery would be not considered as the first treatment of choice.

**Materials and methods:** Four patients with the implants placed in straight anterior line and available bone height in the posterior region of 6 mm were included in the protocol. A total of 22 anterior dental implants and eight Extra Oral (EO) implants (Straumann, Basel, Switzerland) with a length of 2.5–5 mm in the posterior ridges were placed. Implant success rate was defined according to the proposed criteria suggested by Buser et al. (1997). Assessed treatment outcomes included complications with implant components and suprastructures, as presented in an 8-year life table analysis.

**Results:** There were no conventional or EO implant failures. A mean distance from the most distal implant to the EO implant

was 27.2 mm (range 20.3–34.3 mm). Clinical and radiological findings indicated stable soft and hard tissue conditions around implants, without complications encountered during the observation period. The prosthetic plan was maintained in all patients.

**Conclusion:** The present study promoted the performance of short, unconventional implants to support long cantilever fixed dentures. The method applied may extend the clinical application of implants in severely resorbed posterior alveolar ridge environment.

#### 350 Poster – Topic Long-Term Studies

### Clinical & radiographic evaluation of standard diameter implants placed in the posterior region

**Presenter:** Choi JY

*St. Mary's Hospital, The Catholic University of Korea, Seoul, Korea*

**Co-authors:** Choi JY, Yoon HJ, Lee SH

*St. Mary's Hospital, The Catholic University of Korea, Seoul, Korea*

**Background and aim:** In the last decade, the use of wide diameter implant has been increased, especially in the posterior region. But frequently, placements of standard diameter implant in the posterior area have been needed due to their regional condition such as anatomical limitations. This study evaluated short-term clinical and radiographic follow-up of standard diameter implants placed in the posterior region.

**Materials and methods:** A total of 80 standard diameter implants (Oneplant, Warentec, Seoul, Korea) were consecutively placed in the posterior region of 33 partially edentulous patients. The mean age of the patients was 53 years. Implant diameter was 4.1–4.3 mm and lengths were from 8.5 to 11.5 mm, respectively. Clinical and radiographic examinations were conducted at direct after the placement, 3, 6, 12, 24 and 36 months. The survival rate was evaluated according to criteria by Buser & Cochran. Also success rate was evaluated with criteria by T. Albrektsson. Peri-implant bone quality classification recognized four groups (Lekholm & Zarb 1985).

**Results:** The cumulative survival rate of standard diameter implants loaded for a period of 1–3 years was 100%. Success rate was 98.7%. The mean radiographic coronal bone level at 3 month after implant placement was 0.52 mm ( $N=80$ ) compared with 0.45 mm ( $N=80$ ) at the time of implant placement. The mean radiographic coronal bone level at 6, 12, 24 and 36 month after implant placement was 0.62 mm ( $N=80$ ), 0.68 mm ( $N=54$ ), 0.68 mm ( $N=13$ ) and 1.67 mm ( $N=3$ ). Eight of the recipient sites displayed type-I bone quality, 21 showed type-II quality, 28 showed type-III quality and 23 showed type-IV bone quality. Only one implant failed. (Bone loss exceeding 1.5 mm after 1 year of placement.) The implant was failed in a type III bone quality and implant size was 4.1 × 8.5 mm. No peri-implant infection occurred some prosthetic complications occurred, such as screw loosening ( $N=1$ ) and dissolved cementation material ( $N=4$ ).

**Conclusion:** The present study describes successful outcome short-term following the use standard diameter implants in the

posterior region. And further comprehensive maintenance and follow-up schedules are required.

#### 351 Poster – Topic Long-Term Studies

### Implants as strategic abutments to improve removable partial dentures function and esthetics: a 10 years follow-up

**Presenter:** Mijiritsky E

*Tel-Aviv Dental Center, Tel-Aviv, Israel*

**Co-authors:** Mijiritsky E<sup>1</sup>, Richter J<sup>2</sup>

<sup>1</sup>Tel-Aviv Dental Center, Tel-Aviv, Israel, <sup>2</sup>Wurzburg University, Wurzburg, Germany

**Background and aim:** The purpose of this longitudinal, large-sample study was to evaluate the treatment outcome of removable partial dentures (RPDs) in partially edentulous patients treated with dental implants as additional strategic abutments.

**Materials and methods:** Seventy-eight partially edentulous patients with 132 dental implants in conjunction with RPDs participated in this study. Treatments were followed-up for a period of up to 10 years (3–10). The prosthetic elements that were used with the implants to support the RPDs were ball attachments, telescopes and bar connections. All patients were followed-up every 6 months. The presence of clinical signs of mobility and gingival inflammation around implants and teeth was evaluated. Prosthetic complications and patient satisfaction were evaluated.

**Results:** During the follow-up period, only five implants failed resulting in 96.2% implants success rate. During this period prosthetic complications were minor without affecting the prostheses function. No significant clinical signs of mobility or gingival inflammation around implants and teeth were reported. Patients reported good chewing ability and stability of the prosthetic devices. The analysis of the costs of implant with RPDs (IRPDs) compared with implant-supported FPDs showed that patients save > 50% on treatment costs when IRPDs are used.

**Conclusion:** On the basis of this longitudinal, large-sample clinical study, the following conclusions were drawn: (1) successful function over a prolonged period and a minor complication rate of implant-tooth-supported RPDs may be anticipated (2) the great variety of treatment modalities offered by tooth-implant-supported RPDs, appears to be useful as a treatment option for the partially edentulous patients.

#### 352 Poster – Topic Long-Term Studies

### Immediate loaded implants in the edentulous mandible

**Presenter:** Heschl A

*University Clinic of Dentistry and Maxillofacial Surgery, Graz, Austria*

**Co-authors:** Heschl A, Clar V, Wegscheider W, Lorenzoni M  
*University Clinic of Dentistry and Maxillofacial Surgery, Graz, Austria*

**Background and aim:** According to the Brånemark protocol, a stress free healing period is one of the most emphasised

requirements for implant integration. Studies have encouraged a progressive shortening of the healing period and immediate loading has been proposed for the edentulous mandible. This study evaluated the clinical outcomes of 158 immediately loaded XIVE implants. The results were based on clinical stability and survival rate.

**Materials and methods:** In the course of our investigation, 39 patients with edentulous mandibles have been treated with 158 implants following an immediate loading protocol. Four XIVE implants were placed in the interforaminal region located at position 34, 32, 42, 44 with diameters of 3.8, 4.5, 5.5 mm and a length of 11, 13 and 15 mm. All patients were restored immediately with an implant retained provisional prosthesis and 3–4 months post-insertion all implants were treated by a Dolder-bar retained overdenture or fixed prostheses.

**Results:** Two implant failures were observed after an observation period of 8 years. Resulting in a survival rate of 98.73%. The results of this investigation allowed for direct comparison of implant survival and clinical results between immediately loaded implants and standard implants.

**Conclusion:** According to the outcomes of this study the introduced protocol will result in a highly predictable treatment outcome. In spite of the many reports about successful immediate implant loading we still have to accept the fact, that at the present time only non-loading protocols are fully evidenced.

353	Poster – Topic Long-Term Studies
-----	----------------------------------

### Marginal bone level around implants supporting overdentures using Dolder bar

**Presenter:** Ahn CS

*Samsung Medical Center, Seoul, Korea*

**Background and aim:** The aim of this study was to compare the marginal bone level around implants and to evaluate implant survival rates in patients treated with implant-retained overdentures using Dolder bar/clip attachment at Samsung Medical Center.

**Materials and methods:** Total of 18 subjects, who received dental implants for overdentures at Samsung Medical Center, were selected for this study. All of the subjects were treated with two to four implants *ad modum* Brånemark and 17 overdentures were retained using only Dolder bar/clip attachment, while 1 of the subject received Dolder bar in combination with ERA attachment. Cumulative survival rate (CSR) was evaluated and bone quality was determined. The marginal bone level around implants were measured at placement and annually for the next 2 years. Also, the length of Dolder bar and the length of retentive clip were measured and their correlations to bone level were analyzed. The complications were carefully checked and reported. Wilcoxon's two-sample test, Wilcoxon's signed rank test and Spearman's correlation coefficient were used for statistical analysis.

**Results:** Generally, marginal bone loss around implants in the maxilla were greater in comparison with those in the mandible; however, the difference was not statistically significant. Also, bone loss was greater during the first year in both maxilla and

mandible; although there was no significant difference. Bar length and clip length had a strong positive correlation. Marginal bone loss had no significant correlation to bar length, clip length or bone quality.

**Conclusion:** Although there were no significant difference in this study, mean marginal bone loss in the maxilla (1.4 mm) over 2 years was greater in comparison with that in the mandible (0.81 mm) and bone loss in both arches was greater during the first post-surgical year. The results are consistent with the studies mentioned above. However, further study is necessary with a larger sample size for better agreement. Marginal bone loss did not have a significant correlation to either the bar length or the clip length. However, the clip length had a strong positive correlation to the bar length. This correlation, definitely, can be adjusted according to the clinician's preference. Under the same conditions, better retention can be achieved with a longer clip. Therefore, the length of the clip could be as long as possible in order to achieve better retention with no detrimental effect on the marginal bone around implants.

354	Poster – Topic Material Research
-----	----------------------------------

### Stability changes for immediately placed chemically modified surface dental implants

**Presenter:** Di Felice R

*Polytechnic University of Marche, Ancona, Italy*

**Co-authors:** Di Felice R<sup>1</sup>, De Dominicis A<sup>2</sup>, Frabboni P<sup>3</sup>, Coccia E<sup>1</sup>, Rappelli G<sup>1</sup>

<sup>1</sup>*Polytechnic University of Marche, Ancona, Italy*, <sup>2</sup>*Private Practice, Teramo, Italy*, <sup>3</sup>*Private Practice, Bologna, Italy*

**Background and aim:** Immediate implant placement into a tooth extraction site represent an important clinical option. This surgical approach allows to reduce overall treatment time and decrease the number of surgical experiences required by the patient. A new chemically modified titanium surface, SLActive (Straumann AG, Basel, Switzerland), recently developed, exhibiting high surface free energy, reduced atmospheric hydrocarbon contamination, and strong hydrophilicity, has been proposed for time-critical loading treatment protocols. A recently developed technology Resonance Frequency Analysis (RFA) allows us to examine the osseointegration process by assessing implant stability. The aim of this study is to evaluate by RFA the change in stability for SLActive implants placed immediately into extractions sites relative to SLActive implants placed in native bone.

**Materials and methods:** This prospective cohort study evaluated two SLActive implant patient populations. The control group (12 patients, 12 implants) required a single-stage, one-piece, rough-surface implant placed in nongrafted sites at least 6 months postextraction. The experimental group (nine patients, 12 implants) required extraction and immediate placement of implants. Resonance frequency analysis (RFA), a measure of implant stability, was performed following implant placement at 2-week intervals for the first 20 weeks.

**Results:** Placement protocol (control vs. immediate placement) do not result in significant ( $P < 0.001$ ) differences in implant stability. The reduction in stability, approximately from baseline to 2 weeks was, respectively, of 4.6% for experimental group and 6.3% for control group. The growth in stability from 2 to 4 weeks was, respectively, of 1.53% for experimental group and 6.14% for control group.

**Conclusion:** This study shows that immediate placement therapy, in the case of SLActive implants, do not effects changes in stability.

The influence of implant surface characteristics on osteogenic potential of bone particles resulting from placement of titanium screw-type implants

**Presenter:** Tabassum A

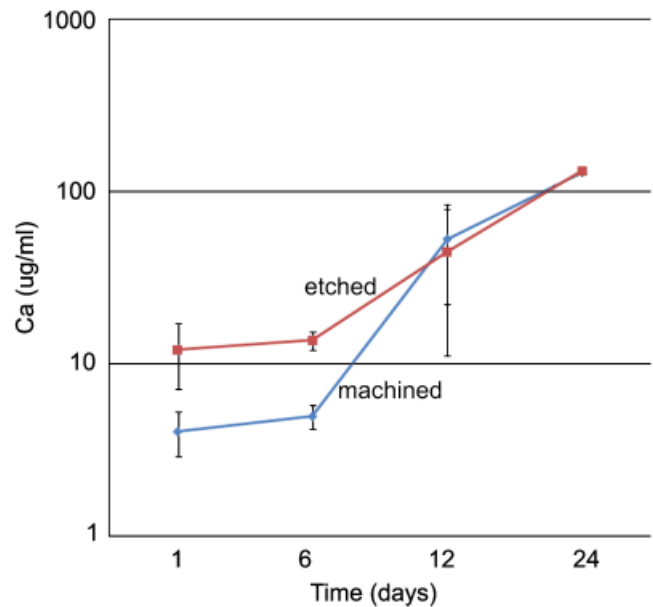

*Radboud University Nijmegen Medical Centre, Nijmegen, the Netherlands, Nijmegen, The Netherlands*  
Co-authors: Tabassum A, Walboomers XF, Wolke JGC, Meijer GJ, Jansen JA

*Department of Periodontology and Biomaterials, Radboud University Nijmegen Medical Centre, Nijmegen, The Netherlands*

**Background and aim:** Several biological (higher % bone implant contact) and mechanical (higher primary stability) advantages of the implant surface characteristics have been reported. However, besides these advantages, a third reason, why roughened implant surfaces show improved healing responses, was suggested. Previously we have demonstrated that bone debris, which is translocated during dental implant placement, has an osteogenic potential. Therefore, it was hypothesized that implant surface characteristics, such as surface-roughness and chemistry, can influence the amount of translocated bone debris/particles and thereby its osteogenic response.

**Materials and methods:** Three hundred and twelve small titanium screw type implants were used. All implants measured 4.5 mm in length and 0.53 mm in diameter. Onto these implants, three different surface topographies were applied: (1) as-machined, (2) blasted and acid etched (etched), (3) blasted and acid etched with a subsequent Ca-P coating (Ca-P coated). Surface testing was performed to characterize the roughness of all implants. Subsequently, holes were drilled into fresh rat cadaver femurs, and the implants were screwed in. After explanation, the implants were incubated in culture medium containing  $\beta$ -glycerophosphate and dexamethasone for four different time points. Subsequently, histology, scanning electron microscopy (SEM), DNA analysis, and calcium (Ca) content measurements were performed.

**Results:** SEM and histology revealed the presence of a bone-like tissue on the surface of all type of implants, as also confirmed by DNA and Ca measurements. Control samples which had not been placed into the bone did not show any mineralization in the same medium. For all implant types, during implant placement, bone particles were translocated by the inherent surface roughness of the implant. However, as compared with the smooth machined implants, the significantly higher roughness



of both the etched and Ca-P-coated surfaces accounted for more bone debris and thus elevated osteogenic response. With respect to translocated bone particles, no significant difference could be observed between the etched and the Ca-P-coated implants.

**Conclusion:** In the present study, for the first time, we demonstrated that implant surface roughness can increase the amount of the translocated bone particles and have a beneficial effect on the osteogenic response of these bone particles. It can be hypothesized that these particles behave like a miniature auto-graft and may play a significant role in peri-implant osteogenesis. However, further *in vivo* studies should be performed to better understand the role of these particles in the process of new bone formation and optimization of surface topography to take advantage of this additional effect of surface roughness.

## Silk fibroin membrane, Bio-Gide, Bio-Mend, lyoplant as barrier membranes in rat Mandibular defects: an evaluation by micro-CT

**Presenter: Shim H**

*Hallym University Sacred Heart Hospital, Anyang, Korea*

**Co-authors: Shim H<sup>1</sup>, Yoo S<sup>1</sup>, Yang B<sup>2</sup>**

<sup>1</sup>*Hallym University Sacred Heart Hospital, Anyang, Korea*, <sup>2</sup>*Hallym Sacred Heart Hospital, Anyang, Korea*

**Background and aim:** The objectives of this study were to determine whether a new silk fibroin barrier membrane can be useful in implant dentistry and to compare it with collagen membranes

**Materials and methods:** In 60 male Sprague-Dawley rats, a 2 standardized 5 mm circular defect was created in the calvarium (right and left). New bone formation was evaluated by micro-CT imaging. Five groups (control, silk fibroin membrane, Bio-GideR, Bio-MendR, LyoplantR) were evaluated at three time intervals (2, 4 and 8 weeks.) In the membrane groups the defects were covered; in the control group the defects were left uncovered. Data were analysed using a multiple regression model.

**Results:** New bone formation could be detected by micro-CT imaging. Bone formation was progressive in 8 weeks, when the calvarial defect was covered with a membrane. Overall, more bone formation was observed underneath the collagen membranes than the silk fibroin membranes.

**Conclusion:** In contrast to uncovered calvarial defects, substantial bone healing was observed in defects covered with a silk fibroin membrane. However, bone formation in silk fibroin membrane covered defects tended to be less than in the defects covered with collagen membranes. The high variation in the silk fibroin membrane samples at 8 weeks may be caused by the moderate adherence of this membrane to bone compared with collagen. These results indicate that further study is needed to optimize the properties of silk fibroin membranes.

the soft tissue were evaluated using an Olympus BX51 Microscope and Image-Pro Plus 5.1 software.

**Results:** Our histological study presented the remodeling of the P material after implantations. In 6 months following implantation, the biomaterials underwent almost complete remodeling into lamellar bone. This remodeling process probably proceeded from periosteum. The P material exhibits significant resorption and bone remodeling can be observed in the vicinity of the material. 6 months after the transplantation large pieces of material are not visible. The vitality of the new bone is very high and the Haversian systems are almost mineralized. Reactions of the big cells and toxic changes were not detected. The formation of 53% and 72% of new bone was observed after 3 and 6 months, respectively. Applying a simplified linear regression model to the time dependence of newly formed bone, soft tissue and residual P material the full resorption of the material and total fill of the defect by newly formed bone can be expected in a time period from 8.2 to 10.5 months.

**Conclusion:** The estimated resorption time of P material (8.2–10.5 months) well correlates to the observed resorption times (ranging from 4 to 12 months) of common TCP materials used in bone regeneration.<sup>[1]</sup>

**Reference:** <sup>1</sup>Garg A. (2004) *Bone Biology, Harvesting, Grafting for Dental Implants, Rationale and Clinical Applications*. Quintessence Publishing Co Inc.

## UV-treated titanium enhances initial adhesion and behaviors of osteoblasts

**Presenter: Iwasa F**

*UCLA School of Dentistry, Los Angeles, CA, USA*

**Co-authors: Iwasa F, Hori N, Yamada M, Suzuki T, Ueno T, Ogawa T**

*UCLA School of Dentistry, Los Angeles, CA, USA*

**Background and aim:** Cell adhesion on titanium is an important initial step for establishing osseointegration. We previously reported that ultraviolet (UV) light treatment of titanium promote bone formation around the implants and increase the strength of osseointegration. We hypothesized the initial cell attachment and adhesion plays a key role in this enhanced biological process. The objective of this study was to examine the potential of UV-pretreated titanium with respect to the attachment, spreading and anchorage of osteoblastic cells, as well as their development of a focal adhesion and cytoskeleton.

**Materials and methods:** Rat bone marrow-derived osteoblastic cells were cultured for 3 h on acid-etched titanium disks with and without UV light pretreatment. The number of cells attached to titanium disks was assessed by WST-1 stain. The spread and cytoskeletal development were evaluated by confocal microscopic image-based cytomorphometry with actin filament stain and by quantifying paxillin-mediated signaling. The expression of a focal adhesion protein, vinculin, was assessed by western blot and immunolocalization. The anchorage of cells was evaluated by quantifying the cells retained after trypsin-enzymatic and vibrational detachment.

## Bone formation around beta-TCP regeneration material- a histological study in beagle dogs

**Presenter: Strnadova M**

*Lasak Ltd., Prague, Czech Republic*

**Background and aim:** The Aim of this study was to evaluate the time dependence of new bone formation and material resorption.

**Materials and methods:** Poresorb-TCP (P) is a bioactive, resorbable, inorganic, crystalline, non-metallic material with osseointegrative properties intended for replacement of bone tissue. The P granules (size 1–2 mm) were implanted into the tibia of dogs for 3 and 6 months. Undecalcified thin sections (30–110 µm) were prepared using EXACT technology (EXACT, Hamburg, Germany). Toluidine blue and trichrom staining was used. The methodology was used according to Yang et al, (2003). The ratio of residual material, newly formed bone and

**Results:** After 3 h of incubation, the number of cells attached to UV-treated surfaces was significantly higher compared with untreated surfaces. The cells on UV-treated surfaces were larger with well-developed cell processes filled with organized actin filaments. Phosphoty<sup>31</sup>-paxillin (pY<sub>31</sub>)/paxillin ratio increased from 25% to 50% by UV treatment. Vinculin was expressed extensively and intensively (3.2 times) in the cells on UV-treated surface. The retention of the cells on UV-treated surfaces was approximately three times greater than that on untreated surfaces.

**Conclusion:** The UV treatment of titanium enhanced initial adhesion in osteoblasts, which may have resulted in an expedited spread, cytoskeletal development, and increased anchorage of the cells.

359	Poster – Topic Material Research
-----	----------------------------------

### Bone augmentation in rabbit calvariae: a comparative histopathologic animal study

**Presenter:** Karamlou M

*Shahid Beheshti School of Dentistry, Tehran, Iran*

**Co-authors:** Ghanavati F<sup>1</sup>, Gholami GA<sup>1</sup>, Asgari S<sup>2</sup>, Egbal J<sup>2</sup>, Ghanavati F<sup>3</sup>, Rahimi H<sup>4</sup>, S. Eshkevari P<sup>5</sup>, Karamlou M<sup>6</sup>, Sculean A<sup>7</sup>

<sup>1</sup>Department of Periodontology, Iran Center for Dental Research, University of Shahid Beheshti, School of Dental Medicine, Tehran, Iran, <sup>2</sup>Department of Endodontics, Endodontic Research Center, Iran Center for Dental Research, Tehran, Iran, <sup>3</sup>Newcastle Dental Hospital, Newcastle, UK, <sup>4</sup>Harvard School of Dental Medicine, Boston, MA, USA, <sup>5</sup>Dental Section Farzan Institute of Science, Research and Technology, Tehran, Iran, <sup>6</sup>University Of Shahid Beheshti, School of Dental Medicine, Tehran, Iran, <sup>7</sup>Department of Periodontology, Radboud University Medical Center, Radboud, the Netherlands Antilles

**Background and aim:** The regeneration of damaged or lost jaw bone tissue has been one of the vital endeavours in periodontal and maxillofacial surgery. Bone regeneration techniques constitute a valid surgical procedure for increasing bone quality and quantity in areas where insufficient bone volume prevents the stabilization of osseointegrated implants. Biomaterial for stimulating osseous regeneration should combine osteogenic, osteoconductive and osteoinductive properties. Besides they should be resorbed and replaced by newly formed bone. In this experiment the rabbit calvaria was challenged with Tri Calcium phosphate (TCP), Bovine-Derived Hydroxyapatite (BioOss), Calcium Sulphate (CaS), Demineralised Freeze-dried Bone Allograft (DFDBA) and an oily calcium hydroxide suspension (Osteoinductal), to evaluate and compare the bone histopathologic response to these materials.

**Materials and methods:** Thirty-four holes in the calvaria of 12 male Australian rabbits were randomly filled with TCP, BioOss, CaS, DFDBA and Osteoinductal and two holes were kept as control and 1 month later histological evaluation were performed on the samples using an optical microscope. The regenerated bone type and extension, the extent of the material which was absorbed, the amount of inflammation and the presence of

inflammatory cells i.e., foreign body giant macrophages, lymphocytes, monocytes, foreign body giant cells and plasmacells were recorded by the pathologist. Statistical analysis was carried out with Kruskal–Wallis, Fisher's exact test and ANOVA when appropriate.

**Results:** The type of regenerated bone in the defect area did not show a significant difference between the groups ( $P=0.3895$ ); while the amount of inflammation was significantly different ( $P=0.029$ ) BioOss had the least amount of inflammation and while the DFDBA group was associated with the highest amount of inflammation. The presence of foreign body giant cells was also significantly different ( $P=0.0009$ ) and there was no any considerable difference for the presence of other inflammatory cells ( $P>0.05$ ) concerning bone formation extension, no significant difference was detected between the groups ( $P=0.475$ ). Also DFDBA had the highest material resorption and TCP group had the lowest amount ( $P=0.002$ ).

**Conclusion:** DFDBA granules were the most resorbable material and it shows more inflammation than other substitutes in the rabbit calvaria. BioOss exhibit the least inflammation and TCP had the least capability for resorption. Giant cells have been detected mostly in Ostin samples while in TCP samples these were the least. BioOss showed the most amount of bone regeneration and DFDBA exhibited the least amount of bone formation.

360	Poster – Topic Material Research
-----	----------------------------------

### Bone healing in surgically created defects treated with autogenous graft bone, collagen AND $\beta$ -Tricalcium phosphate: a histometric study in ulna's pigeon

**Presenter:** Miño-Fariña N

*Universidad de Santiago de Compostela, Lugo, Spain*

**Co-authors:** Miño-Fariña N<sup>1</sup>, Muñoz-Guzón F<sup>1</sup>, López-Peña M<sup>1</sup>, González-Cantalapiedra A<sup>1</sup>, San Román-Ascaso F<sup>2</sup>, Rodríguez-Quiros J<sup>2</sup>

<sup>1</sup>Universidad de Santiago de Compostela, Lugo, Spain, <sup>2</sup>Universidad Complutense de Madrid, Madrid, Spain

**Background and aim:** The aim of this work was to study the ability of an equine collagen to stimulate bone formation and repair in cortical defect in pigeon long bones. Outcomes were compared with untreated defects and defects filled with an osteoconductive  $\beta$ -TCP ceramic.

**Materials and methods:** Seventeen 1-year-old pigeons were used. Under general anaesthesia, the surface of ulna and radius were exposed by a ventral surgical approach. A segmental fracture was created with a bone saw, and a 5–8 mm segment of mid-ulna diaphysis was removed. In control group the surgical defect was not filled. In autograft group, it was filled with cancellous bone and marrow that were harvested from the fragment of ulna that was extracted from the control group. In collagen group, it was filled by Emovet<sup>®</sup> and ceramic group was filled by Cidemarec<sup>®</sup>. To follow the healing process, animals were humanely euthanized at 1, 2, 4 and 6 weeks and the defects and surrounding tissues prepared for histological and histomorphometric analyses.



**Results:** Histomorphometry at 7 days, a small percentage of bone could be observed but no significant differences had appeared between different groups. At 14 days, the mean percentage of bone had increased to levels ranging from 20% to 25% of the total repair areas compared with 7 days. This repaired area was significantly higher in autograft group than that of all other groups. At 28 days, the mean percentage of bone continued increased to levels ranging from 10% to 15% of the total repair areas. Values for total repair area were significantly higher in autograft group than they were in collagen group. There were no significant differences between the rests of the parameters. At 42 days, total repair area had increased again compared with 28 days and, at this time point, cartilage only could be measurable in collagen group.

**Conclusion:** We demonstrated that the proportion and distribution of new bone formed by membranous and appositional mechanisms varied in different treatment groups. In autograft group, bone formation was mainly appositional on defect walls. In collagen group, membranous bone formation was the major mechanism observed. In the ceramic and control groups, appositional bone formation on the defect walls was supplemented by appositional and membranous bone formation between and within particles, particularly those nearest the defect walls. The results obtained for this study also suggested that those treatments had the same efficacy in bone remodeling and new bone matrix.

361	Poster – Topic Material Research
-----	----------------------------------

## Interactions between bone and titanium: new insights into the unique marriage between metal and biology

**Presenter: Wirthmann A**


*New York University College of Dentistry, Hamburg, Germany*

**Co-authors: Wirthmann A<sup>1</sup>, Paulmann C<sup>2</sup>**

*<sup>1</sup>New York University, New York, NY, USA, <sup>2</sup>Universität Hamburg, Hamburg, Germany*

**Background and aim:** Why did the connective tissue layer at the interface disappear with the roughening of implants and what enables bone to maintain its constant remodelling at the interface? On smooth surfaces fibroblasts proliferate forming a connective tissue layer. On rough surfaces they attach and transform to osteoblasts which then start to synthesize and express EM. Eventually EM is being reinforced by biological hydroxyapatite. From coating procedures with HA it is known that between the surface of titanium implants and the HA coating a thin 4 µ layer consisting of CaTiO<sub>3</sub> (perovskite) develops. In 2004 Yashima et al. (*Journal of Applied Crystallography* 37: 786–790) showed that Ca in the CaTiO<sub>3</sub> crystal is being bonded ionically instead of covalently as was previously thought. This would enable the calcium ion at the bone to implant interface to take part in the constant bone remodeling process. The aim of this study was to prove or disprove the existence of a CaTiO<sub>3</sub> layer being formed under biological conditions.

**Materials and methods:** Fully osseointegrated implants (approximately 2 years 'sleeping') were removed from the maxilla, NaCl irrigated to clean, aqua dest. Irrigated, air-dried and its surface investigated by X-ray powder diffraction analysis at the DESY synchrotron facility in Hamburg/Germany.



**Results:** The results repeatedly and clearly show the existence of CaTiO<sub>3</sub> at the implant surface. There was no indication of the existence of TiO<sub>2</sub>.



**Conclusion:** For the first time powder X-ray diffraction (XRD) analysis has proven CaTiO<sub>3</sub> to be formed under biological conditions at the surface of osseointegrated titanium implants. Simultaneously the TiO<sub>2</sub> layer obviously is being modified forming perovskite. The extraordinary strength of the status of osseointegration and its bacterial tightness can be explained by the fact that calcium ions of bone are integrated into titanium oxide crystals thus forming an earth crust abundant molecule called *perovskite*, while at the same time take part in the dynamic process of bone remodelling. The surface roughness represents the precondition for the environmental sensing of cells to trigger their specific responses, their genetic modula-

Source (4.5 GeV):	Bending magnet radius: 12.223 m, $E_e = 16.6$ keV Beam size (positron): $4.6 \times 1.1$ mm <sup>2</sup> FWHM (hor. x vert.) Vertical beam divergence: 0.04 mrad FWHM
Source distance:	37.0 m
Flux at sample:	$2 \times 10^{10}$ photons mm <sup>-2</sup> sec <sup>-1</sup>
Monochromator:	variable-wavelength double crystal, flat Si(111) or Ge(111), RÖMO-type (90°-turnable)
Energy range:	0.3 – 2.4 Å (5.4 – 41.5 keV), Si(111) and Graphite (002)
Energy resolution:	$\Delta\lambda/\lambda = 4 \times 10^{-4}$ (Si(111) at 12.4 keV), ca. $10^{-3}$ graphite
Higher harmonics:	$I(\lambda/2)/I(\lambda) = 10^{-3}$
Diffractometer:	Huber 4-circle Kappa-diffractometer (250 mm inner radius), $\alpha = 60^\circ$ second concentric detector circle horizontal/vertical table movement, horizontal diffractometer movement additional rotation/tilt movements
Angular range:	$-45^\circ < 2\theta < +140^\circ$ ; $-120^\circ < 2\theta < +130^\circ$ ; $-180^\circ < \omega, \kappa, \Phi < +180^\circ$ ( $\omega, \kappa$ depending on setup)
Step size:	$2\theta, \omega, \kappa, \Phi = 0.001^\circ$
Background:	typically 5 – 50 cps, depending on detector aperture and $2\theta$ -range
Goniometer head:	Standard IUCr-mount, the $\Phi$ -circle includes a height adjustment
Detectors:	NaI(Tl) scintillation counter, CCD-detector (marresearch), Ge solid state detectors

Experimental parameters:	
Wavelength:	0.060 nm (20.463 keV)
Beam size:	0.5 mm vertical, 1.5 mm horizontal (centered on Ti/Apatite interface)
Source distance:	37.0 m
Detector:	NaI(Tl) scintillation counter
Scan range:	$10.0 - 51.8^\circ 2\theta$
Step width:	$0.01^\circ$
Exposure time:	5.0 sec/step
Measuring time overall:	3.4h

tion, here the transformation of fibroblasts into osteoblasts. More research is necessary to identify the genes involved in that process, the origin of the Ca ions and the biochemical mechanisms that integrate Ca ions into TiO<sub>2</sub> crystals.

## The effect of placement on implant surface morphology

**Presenter:** Graham S

*University of Sheffield, Hull, UK*

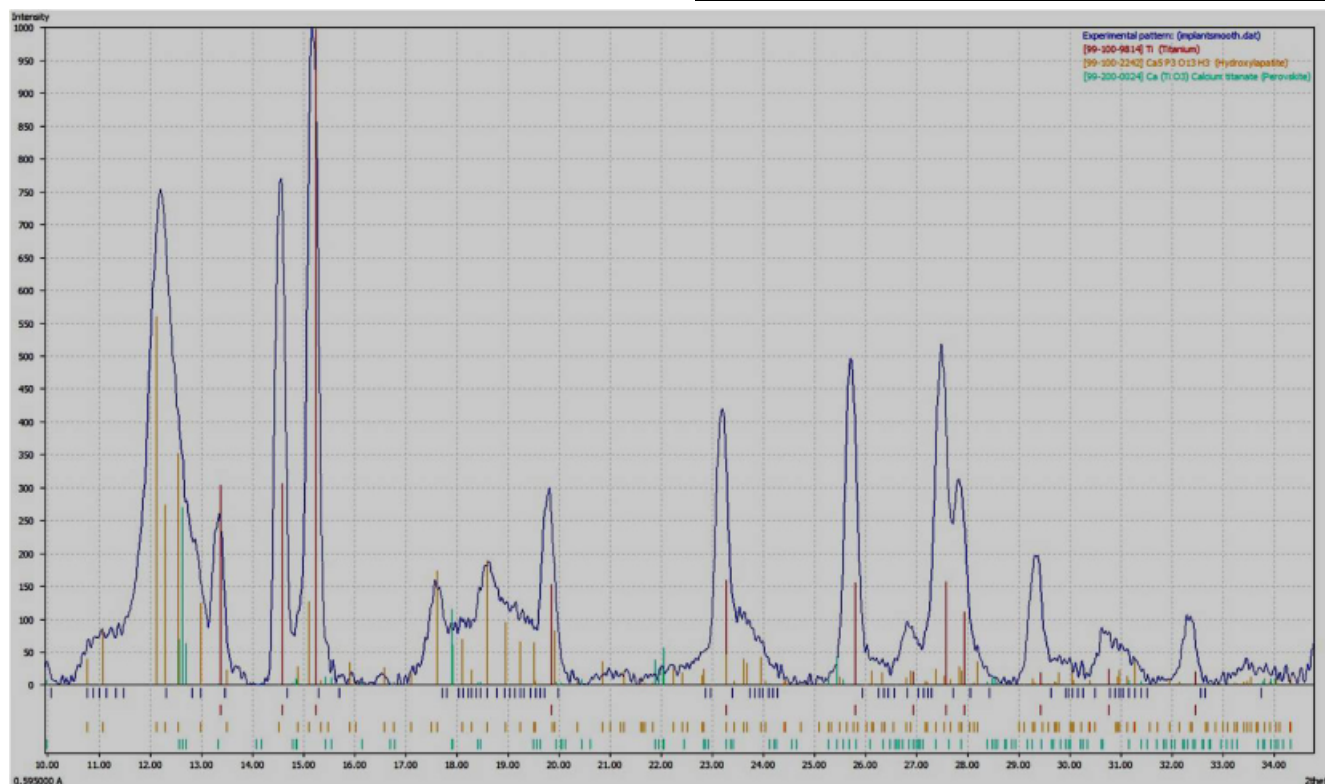
**Co-authors:** Graham S, Miller C

*School of Clinical Dentistry, University of Sheffield, Sheffield, UK*

**Background and aim:** Dental implants have specific morphologies with carefully designed surface topographies manufactured to fine tolerances for optimal performance at a cellular level. *In vitro* studies have shown these specifically designed micro-textured surfaces promote rapid osseointegration.<sup>[1,2]</sup> The aim of this study was to investigate the damage or change, if any that occurred to implant surfaces by placement into bone. The procedures used were designed to mimic clinical conditions.

**Materials and methods:** Products from two leading manufacturers, (Nobel Biocare AB, Goteborg, Sweden and Institut Straumann AG, Barel, Switzerland) were investigated *in vitro*. Six implants from each manufacturer were used, namely, Nobel-Perfect implants (Ti-Unite surface) and Straumann Solid screw implants (SLA surface). Osteotomies were performed and the implants placed according to the respective prescribed protocols into 'Tecnoss' bone (dehydrated porcine rib) with an insertion torque of 45 N cm. The implants were removed atraumatically and cleaned with an EDTA/Trypsin solution to remove osseous and organic debris. The implant surfaces were analysed using micro-CT, optical and electron (SEM) microscopy, pre- and post-implantation to determine the extent of surface damage.

**Results:** Optical microscopy enabled qualitative visual comparison of implant surface and morphology after placement. It





showed that both the implant surface and the implant body of the NobelPerfect implant had become distorted due to implantation, whereas only implant surface deformation was apparent on the Straumann Solid Screw implant. Closer inspection using SEM confirmed significant changes to the surface texture of both types of implants after placement. Micro-CT analysis showed a reduction in surface area of 21% for the NobelPerfect and 9% for the Straumann solid screw.

**Conclusion:** Placement of implants under simulated clinical conditions can cause distortion of implants as well as change to the surface topography. Both implant systems surfaces were affected; however the total extent of the changes was greater for the NobelPerfect implant. This brings in to question methodology for implant design and the validity of specific surface design. Moreover, the predicted success of, or speed of integration may be affected by the damage caused to implants during placement.

**References:** <sup>1</sup>Buser, D., Schenk, R. K. (1991) Influence of surface characteristics on bone integration of titanium implants. *Journal of Biomedical Material Research* 25(7): 889–902.

<sup>2</sup>Mustafa, K., Wennerberg, A. et al. (2001) Determining optimal surface roughness of TiO<sub>2</sub> blasted titanium implant material ... *Clinical Oral Implant Research* 12: 515–525.

363

Poster – Topic Material Research

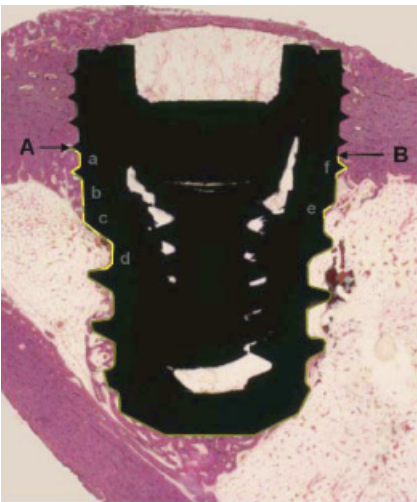
### Effect of static magnetic field on bone formation around SLA-treated titanium implant

**Presenter:** Leesungbok R  
*Kyung Hee University School of Dentistry, Seoul, Korea*  
**Co-authors:** Park GH, Leesungbok R, Kim HJ, Ahn S, Lee SW  
*Kyung Hee University School of Dentistry, Seoul, Korea*

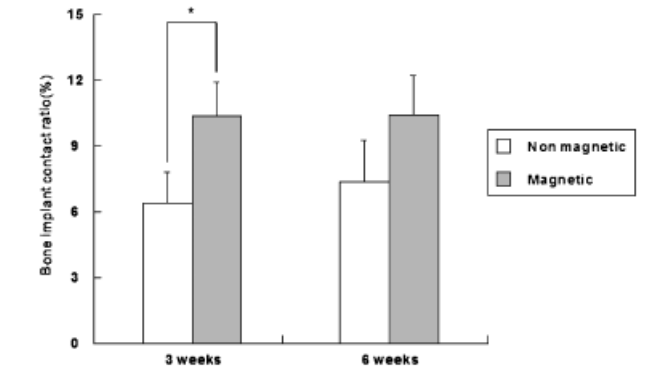
**Background and aim:** The purpose of this study was to compare the bone formation around commercial SLA-treated titanium implants with or without neodymium magnet in rabbit tibia through histomorphometric analysis.

**Materials and methods:** Commercial SLA-treated implants with or without neodymium magnets were placed in 20 rabbits. After incising the flat part of the rabbit's tibia and planting the specimens of titanium implants, the control group was stitched without the magnet insertion, while the experimental groups were inserted with neodymium magnets, fixed by pattern resin and stitched. 3 and 6 weeks after the surgery, the animals were sacrificed and the specimens were obtained. The undecalcified specimens were prepared for histomorphometric analysis of implant-bone contact ratio and bone quantity.

	Classification	n	Mean (%)	SD
BV	After 3 weeks, non-magnetic group	7	74.58	12.12
	After 3 weeks, magnetic group	7	75.99	10.26
	After 6 weeks, non-magnetic group	7	78.75	14.48
	After 6 weeks, magnetic group	7	82.94	9.55
BIC	After 3 weeks, non-magnetic group	7	6.41	2.80
	After 3 weeks, magnetic group	7	7.36	3.79
	After 6 weeks, non-magnetic group	7	10.36	3.07
	After 6 weeks, magnetic group	7	10.41	3.59



**Results:** (1) In histomorphometric findings of the cortical bone, the average bone volume ratios of the experimental groups (3 weeks; 72.99%, 6 weeks; 82.94%) were higher compared with that of the control group (3 weeks; 74.58%, 6 weeks; 78.76%). However, there were no significant differences between the control and the experimental groups ( $P > 0.05$ ). (2) In the marrow bone, the average bone-implant contact ratios of the experimental groups (3 weeks; 10.36%, 6 weeks; 10.41%) were higher compared with that of the control group (3 weeks; 6.41%, 6 weeks; 7.36%). After 3 weeks of implantation, there was a significant difference between the control and the experimental groups ( $P < 0.05$ ).



**Conclusion:** These results suggest that, in rabbit tibia, the SLA-treated titanium implants with neodymium magnet can trigger faster early peri-implant bone formation than those without one.

364

Poster – Topic Material Research

### UV treatment outcomes biological aging of titanium

**Presenter:** Suzuki T  
*UCLA School of Dentistry, Los Angeles, CA, USA*  
**Co-authors:** Suzuki T<sup>1</sup>, Hori N<sup>1</sup>, Att W<sup>1</sup>, Kubo K<sup>2</sup>, Iwasa F<sup>1</sup>, Ueno T<sup>1</sup>, Yamada M<sup>1</sup>, Maeda H<sup>2</sup>, Ogawa T<sup>1</sup>  
<sup>1</sup>UCLA School of Dentistry, Los Angeles, CA, USA, <sup>2</sup>Aichi-Gakuin University, Nagoya, Japan

**Background and aim:** The shelf life of titanium implant products, i.e., a possible time-related change of their bioactivity, has never been addressed. The objective of this study was to

examine the bioactivity of newly processed and aged titanium surfaces and determine whether ultraviolet (UV) light treatment of the titanium surface restores the possible adverse effects of titanium aging.

**Materials and methods:** Titanium disks, either acid-etched or sandblasted, were used immediately after processing (fresh surface) or after storing in dark for 4 weeks (aged surface). Some disks were treated with UV light for 48 h after 4 weeks of storage. Cell attractiveness of Ti was evaluated by examining migration at 3 h, attachment and spreading behaviors at 3 and 24 h using human mesenchymal stem cells. The cell proliferation and alkaline phosphatase activity (ALP) were also evaluated at days 3 and 10, respectively. Calcium deposition was measured at day 25. *In vivo* osteogenic capacity of titanium was evaluated by biomechanical push-in test in rat femurs.

**Results:** Albumin adsorbed to the aged surfaces was only 15% of that adsorbed to the fresh surfaces during 2-h incubation, whereas UV-treated aged surfaces adsorbed equivalent amount of albumin to that for the fresh surfaces. During 24-h incubation, the number of human mesenchymal stem cells attached to the aged surfaces was less than half of that for the fresh surfaces, whereas UV-treated aged surfaces increased the number three times. Proliferation, alkaline phosphatase activity, and calcium deposition of the cells were substantially lower on the aged surfaces than on the fresh surfaces, while those on the UV-treated aged surfaces were higher than on the fresh surfaces. The push in value at week 2 of healing was reduced to half after 4 weeks of titanium aging, whereas UV-treated aged implants increased the strength to the level equivalent to or even higher than the freshly prepared implants. Fresh and UV-treated aged surfaces were superhydrophilic, while the aged surface was hydrophobic.

**Conclusion:** The data suggests that bioactivity of titanium surfaces deteriorates with time and that UV treatment of the aged surface increases the bioactivity over the level of the freshly prepared surface.

system has been studied as an alternative. The aim of present study was to investigate bone formation of *E. coli*-expressed rhBMP-2 (ErhBMP-2) in a rat calvarial defect and ectopic subcutaneous model histologically and histometrically.

**Materials and methods:** ErhBMP-2 was obtained from refolding and purification of inclusion body extracted from transfected *E. coli* with cDNA of BMP-2 *in vitro*. Calvarial critical-sized defects and subcutaneous pouches were created in 144 male Sprague-Dawley rats, which were divided into six groups, each of which received one of following experimental conditions: (1) Sham-surgery control, (2) Acellular collagen sponge (ACS) control, (3) 2.5 µg ErhBMP-2/ACS, (4) 5.0 µg ErhBMP-2/ACS, (5) 10.0 µg ErhBMP-2/ACS, (6) 20.0 µg ErhBMP-2/ACS and were evaluated by histologic and histometric analysis following 2 or 8 weeks healing interval.

**Results:** In calvarial defect model, enhanced bone formation was observed in ErhBMP-2 treated group irrespective to dose of ErhBMP-2, whereas only limited amount of new bone was found in control groups. Histometrically, there were no significant differences among experimental groups in the aspects of defect closure, new bone area, and bone density. In ectopic subcutaneous model, bone formation was obvious at the periphery of implants in all animals treated with ErhBMP-2 at 2 weeks. However, at 8 weeks, only some animals showed the evidence of new bone formation even though degree of bone remodeling and amount of new bone was advanced.

**Conclusion:** Bone healing was affected by observation period and anatomic sites but not by selected dose difference. ErhBMP-2 could induce bone formation in the rat calvarial defect and subcutaneous model. Therefore, ErhBMP-2 is inferred to be osteoinductive under control *in vivo* and there seems to be definite potential as an alternative to rhBMP-2 produced in eukaryotic system for clinical use.

**Acknowledgement:** This study was supported by a grant of the Korea Health Care Technology R&D Project, Ministry for Health, Welfare & Family Affairs, Republic of Korea (A084447).

#### 365 Poster – Topic Material Research

Bone formation by *Escherichia coli*-expressed recombinant human bone morphogenetic protein-2 in a rat calvarial defect and ectopic subcutaneous model

**Presenter:** Lee J

*Yonsei University, Seoul, Korea*

**Co-authors:** Lee J<sup>1</sup>, Choi K<sup>2</sup>, Jung U<sup>1</sup>, Kim C<sup>1</sup>, Cho K<sup>1</sup>

<sup>1</sup>*Yonsei University, Seoul, Korea*, <sup>2</sup>*Cowellmedi Research Development Institute, Pusan, Korea*

**Background and aim:** Bone morphogenetic proteins (BMPs) have come into the spotlight in the area of orthopedics and dentistry because of its osteoinductive capacity. Most recombinant human BMPs have been obtained from mammalian cells such as Chinese hamster ovary (CHO) cells so far. However, low yields (ng/ml range) production of rhBMPs at high cost of this eukaryotic protein expression system is problematic for clinical application. Therefore, rhBMP produced in prokaryotic

#### 366 Poster – Topic Material Research

Stress distribution pattern of the different diameter and length of short implants in D2, D4 bone: 3-D finite elements analysis

**Presenter:** Pyo SW

*The Catholic University of Korea, Buchon, Korea*

**Co-authors:** Kim CH, Kim HK

*The Catholic University of Korea, Seoul, Korea*

**Background and aim:** The use of short implants has been accepted risky from biomechanical point of view. However, short implants appear to be a long-term viable solution according to recent clinical reports. The purpose of this study was to investigate the effect of different diameter and length of implant size to the different type of bone on the load distribution pattern.

**Materials and methods:** Stress analysis was performed using 3-dimensional finite element analysis (3D-FEA). A three-dimensional linear elastic model was generated. All implants modeled were of the various diameter (Ø 4.0, 4.5, 5.0 and 6.0 mm) and

varied in length, at 7.0, 8.5 and 10.0 mm. Each implant was modeled with a titanium abutment screw and abutment. The implants were seated in a supporting D2 and D4 bone structure consisting of cortical and cancellous bone. An amount of 100 N occlusal load of vertical and 30° angle to axis of implant and to buccolingual plane were applied.

**Results:** As a result, the maximum equivalent stress of D2 and D4 bones has been concentrated upper region of cortical bone. As the width of implant is increased, the equivalent stress is decreased in cancellous bone and stress was more homogeneously distributed along the implants in all types of bone. The short implant of diameter 5.0 mm, 6.0 mm showed effective stress distribution in D2 and D4 bone. The oblique force of 100 N generated more concentrated stress on the D2 cortical bone.

**Conclusion:** Within the limitations of this study, the use of short implant may offer a predictable treatment method in the vertically restricted sites.

367 Poster – Topic Material Research

## Nitrided surface layers advancing titanium alloy surfaces for implant surgery

**Presenter:** Wychowski P

*Medical University of Warsaw, Warsaw, Poland*

**Co-authors:** Czarnowska E<sup>1</sup>, Wychowski P<sup>2</sup>, Zajackowska A<sup>1</sup>, Sowinska A<sup>1</sup>, Bierla J<sup>3</sup>, Wierzchon T<sup>4</sup>

<sup>1</sup>Pathology Department, The Children's Memorial Health Institute, Warsaw, Poland, <sup>2</sup>Department of Oral Surgery, Medical University of Warsaw, Warsaw, Poland, <sup>3</sup>Faculty of Veterinary Medicine, Warsaw Agricultural University, Warsaw, Poland, <sup>4</sup>Faculty of Materials Sciences and Engineering, Warsaw University of Technology, Warsaw, Poland

**Background and aim:** Increasing severe implant requirements and functional perfections even in patients with poor bone conditions are cause of efforts to their improvement. Since implant surface properties affects the rate and extent of osseointegration its modification are an area of interest. Therefore, the aim of this study was modification of titanium alloy surface properties in micro and nano-scale that improves mechanical, topographical and physiochemical features of implant followed by its better biocompatibility and bioactivity.

**Materials and methods:** Surface of titanium alloy Ti6Al4V type was modified by producing nitrided surface layer under glow discharge conditions. Surface microstructure, topography and hardness and wear resistance were investigated in comparison with reference titanium alloy. Its bioactivity was tested in SBF while biocompatibility *in vitro* with human osteoblast-like cells Saos2 line and fibroblasts. There were analyzed fibronectin and cell adhesion, and proliferation, and metabolic activity (ALP and TGF-β1 synthesis), and cytokine production (IL-1, 6 and TNFα).

**Results:** Produced surface layers TiN + Ti<sub>2</sub>N + αTi(N) type were about 20 μm thick and presented diffusion character therefore do no change details parameter. They improved hardness and wear resistance of the base material and bioactivity in range of calcium phosphates disposition. Its external zone – TiN

exhibited nano-grain structure and topography characterized by parameter  $R_a = 1.31 \mu\text{m}$ . This surface improved initial fibronectin and fibroblast and osteoblast adhesion and their metabolic behavior compared with titanium alloy.

**Conclusion:** In conclusions an advantages of nitriding under glow discharge conditions is that TiN surface layers exhibit increased surface energy and can be produced on details with sophisticated shape. These facts together with the surface layer microstructure and nanotopography provide conditions that profitably affect cell interactions with implant and alter cell behavior. These may benefit osseointegration of dental implants. However, further *in vivo* investigations are needed.

**Acknowledgment:** This study is in acknowledgments of PB-117/ERA/2006/02/01 grant.

368 Poster – Topic Material Research

## Interdisciplinary studies on titanium and titanium alloys experimental dental implants

**Presenter:** Soare ML

*Metav Research & Development, Bucharest, Romania*

**Co-authors:** Soare ML<sup>1</sup>, Roman I<sup>1</sup>, Alexandrescu E<sup>1</sup>, Fratila C<sup>2</sup>, Petre A<sup>3</sup>, Dinischiotu A<sup>4</sup>, Serban AI<sup>5</sup>

<sup>1</sup>Metav Research & Development, Bucharest, Romania, <sup>2</sup>Research & Development National Institute for Nonferrous and Rare Metals, Bucharest, Romania, <sup>3</sup>Faculty of Dental Medicine, University of Medicine and Pharmacy "Carol Davila", Bucharest, Romania, <sup>4</sup>Molecular Biology Center, University of Bucharest, Bucharest, Romania, <sup>5</sup>Department of Preclinical Sciences, Faculty of Veterinary Medicine, University of Agricultural Sciences and Veterinary Medicine, Bucharest, Romania,

**Background and aim:** The requirements that dental alloys must fulfill refer to chemical inertness in contact with body fluids, biocompatibility, bioactivity and osseointegration. Titanium proved to be suitable to be used as dental implant, as it combines these properties in an optimum manner. There are known such implants processed by SLA technology and also by anodic oxidation. This paper proposes a new surface, achieved by a modified SLA technology combined with anodic oxidation and thermal processing and presents the results of some interdisciplinary investigations on two groups of samples, titanium (T) and TA6V4 alloy (A), respectively. As reference, in each group there were used crude and only alumina sandblasted (s) samples, respectively.


**Materials and methods:** A Subsequent processing of samples in each group consisted in a modified SLA processing that lead to very fine cavities (1 μm), followed by anodic oxidation (P<sub>5</sub>, P<sub>6</sub>, P<sub>10</sub>) and thermal treatment, 500°C, 60 min in air, P<sub>9</sub> and P<sub>11</sub>. There are performed electrochemical tests in Ringer solution, microstructural, microcompositional and biology tests. There were also started some preclinical and clinic tests which are still in process.

**Results:** Cyclic voltammetry showed spontaneous passivation capacity of the alloy samples, while titanium samples remain active around the corrosion potential and they electrochemically passivate under polarization. For alloy samples, the lowest

passivity current at 500mVs.c.e. was measured for P<sub>5</sub>, while for thermal treated samples the measured values were 105 times higher. Alloy samples also show more noble corrosion potentials, sandblasting generally increases the corrosion potential of titanium and especially of alloy samples, Figure 1. Anodic (and thermal) processing further increase the corrosion potential, more significantly for the alloy samples. Electron microscopy reveals that sandblasting and chemical processing create a proper relief before anodizing, while afterwards the oxide presents specific morphologies, Figure 2. The biological tests have shown that the concentration of the proinflammatory cytokine IL-6 was lowered for the alloy samples compared with the titanium ones, Table 1.

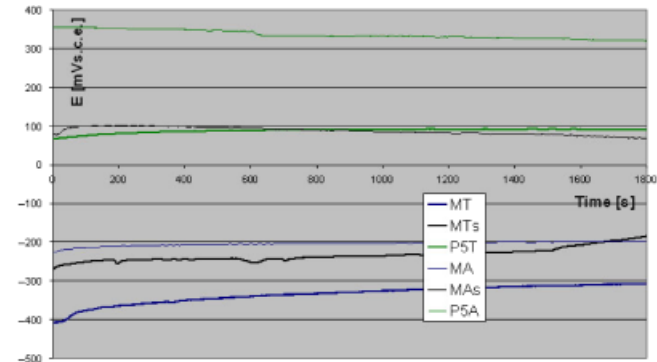
**Table 1** Concentration of IL-6 in the culture medium of hFOB cells in contact with crude (M), sandblasted (Ms) and anodized samples (P5, P6, P9, P10 and P11) Titanium samples

	Concentration of IL-6 (pg IL-6/mg total protein)
M <sub>0</sub>	226.7
MT	243.3
MTs	500.0
P <sub>5</sub> T	560.0
P <sub>6</sub> T	593.3
P <sub>9</sub> T	526.7
P <sub>10</sub> T	590.0
P <sub>11</sub> T	573.3
Alloy samples	Concentration of IL-6 (pg IL-6/mg total protein)
M <sub>0</sub>	220.4
MA	301.4
MA <sub>s</sub>	260.9
P <sub>5</sub> A	307.3
P <sub>6</sub> A	515.9
P <sub>9</sub> A	301.4
P <sub>10</sub> A	542.0
P <sub>11</sub> A	365.2



**Fig. 1.** Backscattered electron images achieved on sandblasted (a × 4000), sandblasted and acid anodized titanium alloy (c × 8000), QUANTA INSPECT F Scanning Electron Microscopy.

**Conclusion:** The best sample indicated by the electrochemical tests, P<sub>5</sub>A, also generated one of the lowest concentrations of secreted IL-6. The biological tests were in good agreement to the electrochemical ones, since for both types of testings the best results were obtained for the same alloy sample processed by its particular technological path. For the alloy samples, sandblasting decreases the level of secreted cytokine but the applied thermal treatment seems to be detrimental for the alloy stability in Ringer solution.



**Fig. 2.** Time evolution of the electrode mixed potential (versus saturated calomel electrode as reference Radiometer device).

Retaining screw: the effect design and surface characteristics have on pre load, how to achieve better pre-load and a protocol for maintaining it

**Presenter:** Cumming L  
*Southern Implants, Centurion, South Africa*  
**Co-authors:** Coombes H  
*Southern Implants, Irene, South Africa*

**Background and aim:** Retaining screw pre-load is a factor directly influencing the success of implant integration. The pre-load determines the ability of the connection between the implant and abutment to withstand angulated forces and prevent the joint from opening. Compromised joints can result in screws breaking, restoration fracture and loss of osseointegration. These undesirable outcomes are costly and time consuming to rectify. The aim of this study is to quantify the effect that material properties, coatings and screw designs have on screw pre-load. A protocol is also to be drawn up based on these results to best maintain pre-load.

**Materials and methods:** A commercially available titanium grade 5 (Ti-6Al-4V alloy) screw was used as a benchmark for this study. Varying torques were applied to screws and the pre-load was measured by means of a strain gauge. The following materials were tested: titanium grade 5, gold and various coating on titanium screws. An innovative method for increasing the preload on a titanium screw was tested as an alternative to a more expensive gold screw.

**Results:** Overall, gold screws achieve 183 % more pre-load than titanium screws. The effect of different coatings vary between 89%–122% compared with the titanium grade 5 benchmark. A screw tightening protocol was developed in order to maintain optimum pre-load.

**Conclusion:** The gold screws are far superior in achieving pre-load, however, without a maintenance protocol gold screws tend to lose pre-load. Using the protocol suggested can aid practitioners in taking full advantage of the material properties of screws.

Clinical and histological study on the bone regenerative efficacy of synthetic oligopeptide-coated bone (OSSGEN-XI5®) in socket preservation

**Presenter: Park J**

*Seoul National University, Seoul, Korea*

Co-authors: Park J, Koo KT, Kim Ti, Seol YJ, Lee YM, Ku Y, Rhyu IC, Chung CP

*Seoul National University, Dental Hospital, Seoul, Korea*

**Background and aim:** The aim of the present study was to evaluate the bone regeneration capacity of synthetic peptide-coated bone bovine (Ossgen-XI5®) compared with the non-modified deproteinized bovine bone in the extraction socket of maxillary teeth.

**Materials and methods:** Twenty Maxillary teeth were selected. At the time of surgery, the distance from the midpoint of the extraction site perpendicular to the line connecting the occlusal surfaces of adjacent teeth was recorded at the most occlusally situated point both buccally and palatally. In addition, the depth of the extraction socket and the bucco-palatal width were also recorded. After measuring, graft particles were filled and packed and resorbable collagen membrane was placed to cover the marginal portion of the alveolar socket wall. Primary soft tissue closure was conducted via periosteal releasing incision on buccal flap. After 6 months follow-up, peripical radiograph was taken to identify the ossification of the socket and re-entry surgery was done to measure the dimensional change.

**Results:** Upon surgical re-entry at 6 months, bone fill was evident in the socket and bone regeneration was observed in the previously dehiscenced buccal plates. Clinically, there were no significant differences between the experimental and control groups. In the aspects of clinical parameters, the average change in the height of bony wall was  $+1.25 \pm 2.04$  mm in the experimental group and  $+1.20 \pm 2.01$  mm in the control group, and the depth change was  $+7.30 \pm 3.74$  mm in the experimental group and  $+7.10 \pm 3.07$  mm in the control group. The average change in widths was  $-1.30 \pm 1.33$  mm in the experimental group and  $-1.40 \pm 1.07$  mm in the control group, and when the values were converted, the percentage of width reduction was  $-13.15 \pm 12.92\%$  in the experimental group and  $-15.19 \pm 10.87\%$  in the control group. Histologically the two groups seemed to show a slight difference in composition of newly formed bone.

**Conclusion:** Peptide-coated bone mineral, used in the present study, is an effective bone substitute with the potential to enhance bone regeneration in the preservation of extraction sockets.

Development of a novel-loading device for the investigation of bone adaptation around dental implants in an animal model

**Presenter: Rahimi A**

*University of Bonn, Bonn, Germany*

Co-authors: Abboud M, Wahl G, Bourauel C, Rahimi A

*University of Bonn, Bonn, Germany*

**Background and aim:** The animal experiment on the reindeer antler as a novel animal model novel with a precise loading device shall serve for investigation of the bone remodeling processes in the implant bed. The main interest is directed towards the time and loading-dependant behavior of the bone around the implants.

**Materials and methods:** Autonomous loading simulators were designed, that can be fixed to the antler and manage the cyclic loading of the implants over a predefined time span. For controlling and driving the motor a control unit was designed. It allows defining different loading protocols and consists of a motor driver circuit and a matchbox-sized microcontroller board with integrated 12-bit analogue/digital converter (Phytec, Germany). A specially developed software running on the micro-processor board enables to define different loading protocols, measures the motor current, and counts the loading cycles applied. The control unit can be connected over a wireless Data Communications Module to a host-PC. The chosen accumulators ensure an autonomous operating time of up to 90 days. The force of the device can be controlled with an accuracy of approximately  $\pm 8\%$ . The mechanical part of the device can be attached to the antler and is capable of cyclically loading the implant with forces of up to 100N.

**Results:** From biomechanical point of view, the material parameters of cortical and trabecular bone are of highest relevance and have an impact on the results of numerical simulations. Reindeer antlers showed that the elastic and the fracture behavior are analogous to that of human bone. The designed loading device remained stable and accurate measurements of implant stability in the reindeer antler are possible. The precise loading control enables researchers to compare between loaded and non-loaded implants, showing the difference in osseointegration histological. Biomechanical investigation can follow after the loading device was with taken and the implant is harvested after shedding of the antler or before by cutting segments out of the antler.

**Conclusion:** Decisive and important benefits of this animal model and the loading device are that the animals must not be sacrificed after experimentation, the load on the implant can be applied and controlled without repeated narcosis and specimens of antler tissue can be prepared for biomechanical and histological studies from antler segments at every time. The presented loading device has shown to be very accurate over time regarding loading cycles and measurements and can give new insights in the timeline of implant osseointegration.

The influence of cement type on separation of crown from prosthetic abutment under exposure of temperature

**Presenter:** Linkevicius T

*Institute of Odontology, Faculty of Medicine, Vilnius University, Vilnius, Lithuania*

**Co-authors:** Tomas L<sup>1</sup>, Egle V<sup>1</sup>, Giedrius K<sup>1</sup>, Eugenijus V<sup>2</sup>, Algirdas P<sup>2</sup>, Simonas G<sup>2</sup>

<sup>1</sup>*Institute of Odontology, Vilnius University, Vilnius, Lithuania,*

<sup>2</sup>*Vilnius Implantology Center, Vilnius, Lithuania*

**Background and aim:** It is well known that cement-retained restorations on implants experience mechanical failures during years of service. Sometimes complications are so severe that veneering porcelain correction or remaking of the prosthesis becomes valid options. In that case restoration is usually retrieved together with prosthetic abutment from implant, if permanent cement was used for fixation of the prosthesis. Therefore, it is important to separate the crown from the abutment without the damage to both. Thus, the aims of the study were: (1) to determine the influence of cement type on separation of crown from abutment; (2) to establish mechanical factors having an impact on strength of restoration adherence to abutment; (3) to estimate the average separation temperature of each cement.

**Materials and methods:** One hundred and twenty prosthetic implant abutments of various diameter, namely 40Un of 3.5 mm (33.3%), 64 abutments of 4.0 mm (53.3%) and 16U of 5.0 mm (13.3%) diameter were used in this study. The same amount of cobalt-chromium frameworks with occlusal openings were fabricated and placed on abutments with following cements–resin modified glass ionomer cement (RGIC), zinc phosphate cement (ZPC) and dual-cure resin cement (RC). All specimens were divided in four groups: (1) polished abutments and passive frameworks; (2) polished abutments and non-passive frameworks; (3) sand-blasted abutments and passive frameworks; (4) sand-blasted abutments and non-passive frameworks. Every specimen was placed in dental oven (VITA Vacumat 40T) for 5 min in 300°C temperatures. The abutment and metal framework were tried to separate. If not successful, the specimen was put to oven for 5 min increasing temperature for 50°C till 800°C. Statistical analysis was carried out using SPSS (v15).

**Results:** (1) RGIC exhibited the lowest ( $P < 0.05$ ) and ZPC showed the highest ( $P < 0.05$ ) separation temperature of framework from abutment; (2) The passivity of the framework did not have statistically significant influence on the height of the separation temperature for any cement ( $P > 0.05$ ). Sandblasting of abutments correlated with higher separation temperature for ZPC and RC; (3) The average temperatures for RGIC were 306°C (SD = 23), RC – 363°C (SD = 70) and for ZPC – 496 (SD = 203).

**Conclusion:** It can be concluded, that (1) if restoration is cemented with RGIC, it can be easily separated from abutment; (2) RGIC shows lowest mechanical properties; (3) it can be recommended to place restoration with abutment for 5 min in oven with 300–350°C if RGIC was used for cementation, 350–

400°C for RC, but there is no recommended temperature for ZPC due to very high standard deviation.

Human gingival fibroblast adhesion to various prosthetic materials

**Presenter:** Rutkunas V

*Vilnius University, Vilnius, Lithuania*

**Co-authors:** Rutkunas V<sup>1</sup>, Sabaliauskas V<sup>1</sup>, Juciute R<sup>1</sup>, Bukelskiene V<sup>2</sup>

<sup>1</sup>*Division of Prosthodontics, Vilnius University, Vilnius, Lithuania,*

<sup>2</sup>*Institute of Biochemistry, Vilnius, Lithuania*

**Background and aim:** Adhesion of fibroblasts to dental materials is of critical importance to provide efficient soft tissue ‘seal’. The aim of the study was to test probing surface adhesion forces of human gingival fibroblasts to various prosthetic materials using atomic force microscopy.

**Materials and methods:** Fibroblast cells were extracted and cultivated from human gingival tissues obtained from a patient undergoing gingivectomy procedure. Proteomic analysis was performed to determine cell type. Fibroblasts were cultured on selected prosthetic materials including polished titanium, sand-blasted titanium, polished zirconium, sand-blasted zirconium, pressed and feldspathic ceramics, gold and chromium–cobalt alloys, bis-acryl composite, methyl-methacrylate based material. The different surfaces were analyzed using an atomic force microscope (AFM) and a scanning electron microscope while fibroblast adhesion strength was evaluated using AFM by applying lateral detachment force to individual live cells. The data concerning cell adhesion strength was statistically analyzed using one-way ANOVA test and Tukey multiple comparison test.

**Results:** Results indicated that the lateral force required to detach fibroblast cell from a substrate differed depending on the nature of the material surface: detachment force for titanium and zirconium was significantly greater compared with other groups. Sound-blasted titanium and zirconium had more surface energy and promoted increased cell adhesion strength compared with polished titanium and zirconium specimens. Fibroblasts appeared to follow the direction of small irregularities on surfaces of other specimens.

**Conclusion:** Within the limitations of this study it may be suggested that adhesion can be controlled, through appropriate biomaterial nature and design such as surface roughness. Smooth surfaces revealed significantly lower adhesion strength than roughened specimens ( $P < 0.05$ ).

The influence of screw retightening and diamond like carbon coating of conical connection type implant abutment on screw loosening

**Presenter:** Jung-Je W

*Seoul National University, Seoul, Korea*

Co-authors: Woo JJ, Koak JY, Yang JH, Heo SJ, Lee JB, Han JS, Kim SH, Lim YJ, Kim MJ, Kwon HB

*Seoul National University, Seoul Korea*

**Background and aim:** It is difficult to assess the loosening tendency of conical connection type implant with diamond like carbon (DLC)-coated one-piece abutments after cyclic loading, and also to know the retightening effect. This study was performed to investigate the influence of one-piece abutment screw retightening and Diamond like coating after  $5.0 \times 10^4$  cyclic loading.

**Materials and methods:** Thirty-two ITI SLA implant were divided into four groups. Group A, C-titanium abutment, group B, D – DLC-coated abutment. DLC coating was done on 16 implant abutments with 13.56Mhz r.f. plasma CVD method. All abutments were tightened with  $35 \text{ Ncm}^{-1}$  torque. Group A, B –  $20 \times 10^4$  cyclic loading after  $5 \times 10^4$  cyclic loading, group C, D – after  $20 \times 10^4$  Cyclic loading. After cyclic loading, periotest values (PTVs) were taken and removal torque values of abutments were measured with a digital torque gauge. After assessing the removal torque, investigate the abutment screw surface with FE-SEM. All data were expressed as mean  $\pm$  standard deviation. Comparison of data was performed using one-way ANOVA. SPSS (release 15.0, Inc., Chicago, USA) software supported statistical evaluation.

Classification of groups group	Type of abutment screw	N
A	Titanium abutment	8
B	DLC-coated abutment	8
C	Titanium abutment	8
D	DLC-coated abutment	8

**Results:** (1) The removal torque of group B after  $5.0 \times 10^4$  cyclic loading is slightly greater than group A, but not significantly higher than others ( $P > 0.05$ ).

(2) The final removal torque values after  $20.0 \times 10^4$  cyclic loading of group A is bigger than group C, and group B is bigger than group D, but not significantly higher ( $P > 0.05$ ).

(3) The final removal torque values after  $20.0 \times 10^4$  cyclic loading of all groups are not significantly different ( $P > 0.05$ ).

Loosening Torque Value (N/cm) after cyclic loading Group	N	After $5.0 \times 10^4$ cyclic loading		After $5.0 \times 10^4$ cyclic loading	
		Mean	SD	Mean	SD
A	8	31.6250	1.18773	30.5000	1.81265
B	8	32.5038	2.53210	31.6250	1.30247
C	8			30.1250	2.47487
D	8			31.2500	1.83225

**Conclusion:** Removal torque values of retightened and DLC-coated conical connection type abutment were slightly higher than others after  $20.0 \times 10^4$  cyclic loading, but not significantly.

Four years clinical observation of thin hydroxyapatite-coated one-piece implant

**Presenter:** Kasugai S

*Tokyo Medical and Dental University, Tokyo, Japan*

Co-authors: Kasugai S, Shiota M, Tachikawa N, Kondo H, Kuroda S, Fujimori T, Munakata M, Nakata H, Kobayashi H

*Tokyo Medical and Dental University, Tokyo, Japan*

**Background and aim:** Since hydroxyapatite (HA) is highly bio-compatible and osteoconductive, clinical effectiveness of HA-coated implants has been recognized. However, in most of HA-coated implants HA thickness is more than  $20 \mu\text{m}$  and mechanical weakness of the coating is a great concern. The purpose of the present study is to evaluate clinical effectiveness and safety of thin HA-coated one-piece implant.

**Materials and methods:** The Clinical Research Committee of the institute approved this clinical trial. The fixture part of pure titanium screw-type one-piece implant was coated with  $1-2 \mu\text{m}$  HA with sputtering technique. After obtaining informed consents we installed 94 implants in 51 cases in 45 patients. We periodically measured implant mobility with 'Perio Test' up to 1 year. Bone level around the implants with dental X-ray, peri-implant mucosa condition and patients' satisfaction in oral functions were also examined and scored up to 4 years.

**Results:** One implant was removed at 3 weeks because of implantitis and another implant was fractured at 13 months. At 1 year, survival rate of the implants was 98.9% and the average value of implant mobility in Perio Test and the average value of bone resorption around the implants was ' $-2.5$ ' and ' $0.52 \text{ mm}$ ', respectively. At 4 years, survival rate of the implants was 97.8% and the average bone resorption around the implant was  $0.60 \text{ mm}$ . Unfavorable mucosa reaction was not observed and the all of the remaining implants were stable in function and patients' satisfactory levels were extremely high.

**Conclusion:** The present results demonstrate effectiveness and safety of the thin HA-coated one-piece implant. This implant would be useful for the site, where neither high esthetic outcome nor angulation of the prosthesis is required.

Influence of hydrophilicity of microrough titanium dental implant surfaces on the initial blood-interaction and the activation of the blood coagulation cascade

**Presenter:** Tugulu S

*Thommen Medical AG, Waldenburg, Switzerland*

Co-authors: Tugulu S<sup>1</sup>, Hall H<sup>2</sup>, Schlottig F<sup>1</sup>

<sup>1</sup>Thommen Medical AG, Waldenburg, Switzerland, <sup>2</sup>Swiss Federal

Institute of Technology, Zürich, Switzerland

**Background and aim:** The activation of the blood clotting cascade during implant placement represents the initial step of the wound healing cascade and implant integration. During this process the adsorption, activation and replacement of blood proteins is accompanied by a rapid adherence, aggregation,



activation and degranulation of thrombocytes on the surface of the implant. Especially the release of chemotaxins and cytokines like platelet factor 4 or RANTES and of growth factors like platelet derived growth factor (PDGF) or transforming growth factor (TGF-beta) from activated thrombocytes are pivotal for the wound healing cascade. The release of these factors induces the recruitment of immune cells and the recruitment and differentiation of mesenchymal cells and triggers angiogenesis.

**Materials and methods:** The aim of this study was to simulate and to compare the primary contact of alkali treated and of untreated sandblasted and thermally acid etched (SBA) Ti implants with the physiological environment, i.e. blood, upon implant placement. The phenomenological events that occur on the surfaces of untreated and alkali treated SBA Ti implants after blood contact were investigated using scanning electron microscopy (SEM). Furthermore the extent and type of activation of the blood clotting cascade was compared as a function of alkali treatment by quantifying the blood clotting markers Thrombin-anti-Thrombin (TAT), Kallikrein and soluble P-Selectin. C5a activation was compared as a marker for the activation of the complement system.

**Results:** Titanium (Ti) surfaces are negatively charged at physiological pH and are therefore potent contact activators of the blood clotting cascade. However this beneficial property is deteriorated on most conventional Ti implant surfaces by an adsorbed layer of hydrocarbons. This layer renders the implant surface hydrophobic and might alter protein adsorption and hence contact activation. *In vitro* and *in vivo* data emphasize the importance of surface charge and surface energy for the successful and rapid osseointegration of Ti implants. Compared with untreated implants alkali treated microrough Ti implants are hydrophilic with increased wettability. Furthermore experimental evidence exists that alkali treatment increases the net negative surface charge of the implants and influences protein adsorption. This makes alkali treated microrough Ti implants to promising candidates with increased contact activation potential.

**Conclusion:** Concluding this contribution will discuss the activation of the blood clotting cascade and the complement system in the context of the physicochemical properties of alkali treated and untreated Ti dental implant surfaces.

#### 377 Poster – Topic Material Research

Histological evaluation of the quality of bone formation induced by an injectable calcium phosphate cement in osseous defects created in rabbits

**Presenter:** Gehrke SA

Bioface Institut, Santa Maria, Brazil

**Co-authors:** Gehrke SA<sup>1</sup>, do Nascimento PC<sup>2</sup>, Bohrer D<sup>2</sup>, Machado LC<sup>2</sup>

<sup>1</sup>Bioface Institut, Santa Maria, Brazil, <sup>2</sup>University of Santa Maria, Santa Maria, Brazil

**Background and aim:** The aim of the present study was to assess the influence of an injectable calcium phosphate cement on new bone formation in rabbit tibiae. The bone growth was assessed by analysing histological sections taken 30 and 60 days after surgery.

**Materials and methods:** Six adult New Zealand rabbits (*Oryctolagus cuniculus*) were used in this study. Three were sacrificed after 30 days, the other three after 60 days. Each animal provided four sites (two in each tibia). The sites were cylindrical, with a diameter of 4 mm and a length of mm. The sites in the right tibiae were filled with a calcium phosphate cement (PD VitalOs Cement<sup>®</sup>, Produits Dentaires SA, Switzerland) (EXP). The left tibiae provided control sites (CON), left empty (only blood clot). After sacrifice, were obtained sections were stained with the Hematoxylin/Eosin and the Masson's trichrome methods.

**Results:** An intense cell proliferation along with large formation of collagen and bone matrix can be observed in the experimental group (EXP) after 30 days. This large number of cells is still present after 60 days. This demonstrates the excellent osteoconductive properties of the calcium phosphate cement. The cellular activity in the control sites (CON) is much less important at both 30 and 60 days after surgery. The sections at 60 days are similar to those at 30 days in the control group, showing no major difference in terms of bone quality, amount of new bone and number of cells involved in the bone neoformation process.

**Conclusion:** The difference between the results of the experimental and control sites at 30 and 60 days indicate that the grafting with the VitalOs calcium phosphate cement promotes new bone formation, providing the grafted area with a greater amount of cellular activity. This would theoretically allow successful installation of implants in a sufficient bone bed. Additional studies would be necessary to confirm this statement.

#### 378 Poster – Topic Material Research

Retention forces of a new implant-supported bar attachment system

**Presenter:** Steiner M

University Hospital Schleswig Holstein, Campus Kiel, Kiel, Germany

**Co-authors:** Steiner M, Ludwig K, Kern M

Department of Prosthodontics, Propedeutics and Dental Materials, Kiel, Germany

**Background and aim:** The aim of this study was to evaluate the retention forces of a new prefabricated bar attachment system (SFI-Bar<sup>®</sup>, Cendres + Métaux, CH) during long-term loading through cyclic attaching and detaching. In addition, the influence of various sealing materials at the microleakage between the tube bar and the bar connectors was tested.

**Materials and methods:** The SFI-Bar<sup>®</sup> system consists of an adjustable tube bar and gold matrix, two ball-joints and two implant adapters. The components can be adjusted intraorally for chair-side application. To enable measurements two implant analogues were placed in a specimen holder and each was set up with an implant-adapter (35 Ncm). The joints of the tube bars were sealed with three different materials (AGCCem, Wieland D; GapSeal, H&W, D; Cervitec plus, Ivoclar, FL) in four combinations with eight specimens each. The inner cavity of the tube bar was filled with liquid red dye. The assembled SFI-Bars<sup>®</sup> were fixed (15 Ncm) onto and checked concerning initial microleakage. The attachment system was assembled in parallel



conjunction to their female counterparts in a chewing simulator. Attaching and detaching cycles were set to repeat every 2 seconds and values were recorded over 50,000 repetitions. The mean retention forces at the beginning and the ending of load were calculated. ANOVA was applied with  $\alpha \leq 0.05$ .

**Results:** All groups showed a loss of retention forces. Their means differ between 40.1–29.3 N initially and 27.6–20.3 N after 50,000 loading cycles. Comparing the mean retention forces between groups no statistical differences were found at the beginning ( $P=0.2435$ ), at the end ( $P=0.2255$ ) or between the loss of retention forces due to loading ( $P=0.12$ ). No sealing compound remained completely sufficient. Microleakage occurred in some groups immediately and after 10,000 loading cycles all groups exhibited microleakage.

**Conclusion:** Long-term retention forces of the new SFI-Bar<sup>®</sup> remained above 20N which is considered clinically adequate. An adhesive resin sealing seems not to be necessary due to the non-significant differences compared with non-adhesive gels.

**Acknowledgement:** This study was supported by Cendres + Métaux, Biel, CH.

#### 379 Poster – Topic Material Research

### Porous titanium granules for implant stability in posterior maxillo for delate or immediate placement

**Presenter:** Kiki F

*Moscow Post Graduate University, Moscow, Russian Federation*

**Co-authors:** Kiki F<sup>1</sup>, Sayeduld P<sup>2</sup>, Bjursten PM<sup>3</sup>, Bystedt P<sup>4</sup>

<sup>1</sup>Estetdent-Implant Center, Moscow, Russian Federation, <sup>2</sup>Moscow

Postgraduate Stomatology University, Moscow, Russian Federation,

<sup>3</sup>University of Lund, Lund, Sweden, <sup>4</sup>Private Doctor, Stokholm, Sweden

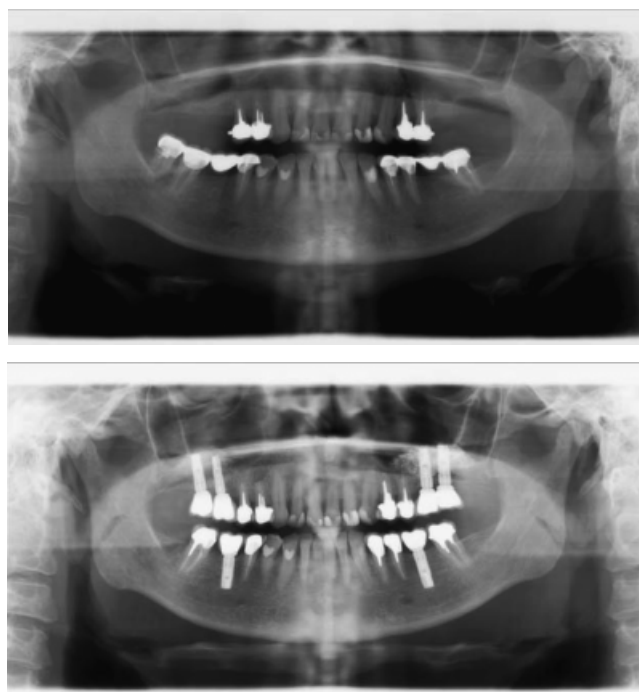
**Background and aim:** Resorption Resorption of grafting material may lead to unpredictable long-term when rehabilitating the resorbed posterior maxilla. Nonresorbable, osteoconductive bone substitutes may therefore be an advantage over autogenous bone. Titanium granules, in the form of Tigran were introduced on the market as a non-resorbable grafting material.

The aim of the present clinical cases was to test titanium granules as osteoconductive -non-resorbable material for augmentation of sinus floor before or in combination of immediate instolation.

**Materials and methods:** Eleven patients with uni- or bilateral edentulism of the posterior maxilla were treated for augmentation of sinus floor before – or in combination of immediate instolation of 25 Osseospeed (Astra Tech AB Molndal, sweden). Residual bone height was 2–5 mm. A staged protocol with implant placement 5–9 months after the augmentation procedure was used when primary stability was hard to achieve (five patients) Measurement with Osstell mentor was carried for implants placed immediately with the augmentation – with protocol (first day) (3 weeks) (2 months) (abutment placement).

**Results:** The patients have been followed 12–48 months after prosthetic loading, one patient in the two-stage group had infection after 3D reconstruction of an extreme atrophy maxilla, and was treated (first with augmentation titanium granules),

and delated implant placement. All the patients had a successful results with a predictable prosthetic outcome.



**Conclusion:** Titanium granules seem to function as augmentation material in the sinus floor with one- or two-stage protocol – it takes a longer time (7–9) months healing for the two-stage procedures. Satisfactory initial stability can be achieved and dose not seem to interfere with the integration of osseous implants.

#### 380 Poster – Topic Material Research

### *In vitro* evaluation of microbial leakage in the implant-abutment interface, in Morse-taper implants

**Presenter:** Aloise JP

*Heliópolis Hospital, São Paulo, Brazil*

**Co-authors:** Aloise JP<sup>1</sup>, Curcio R<sup>1</sup>, Laporta MZ<sup>2</sup>, Rossi L<sup>2</sup>, da Silva AMA<sup>1</sup>, Rapoport A<sup>1</sup>

<sup>1</sup>Heliópolis Hospital, São Paulo, Brazil, <sup>2</sup>Fundaáo Santo André, Santo André, Brazil

**Background and aim:** The tapered conical abutments having an interference fit presenting a large contact surface with the implant were chosen for this study because they are considered the most suitable alternatives for avoiding microbial leakage between implant-abutment connections (King et al. 2002; Brogini et al. 2003; Dibart et al. 2005). The aim of this study was to determine and compare the frequency of bacterial leakage of *Streptococcus sanguinis* biotype II bacteria along the implant-abutment interface between two system of morse-taper dental implants, the pure taper-interference fit (Bicon<sup>®</sup>) and the taper-integrated screw (Ankylos<sup>®</sup>) employing different methods of activation of the taper abutments: tapped-in and screwed-in, with a new *in vitro* model.

**Materials and methods:** This prospective study was developed at the Biology Laboratory of the Department of Microbiology of

Fundação Santo André (Santo André, Brazil) and the Molecular Biology Laboratory of Heliópolis Hospital (São Paulo, Brazil), through the period, June 11 until July 11 of 2008. Twenty sterile assemblies were selected and attached, ten Bicon<sup>®</sup> and ten Ankylos<sup>®</sup> implants, according to manufacturers' specifications, then were totally immersed within 20 test tubes containing a sterile nutrient solution BHI (Brain-Heart Infusion). The internal part of the 20 implants was previously inoculated with 0.1 µl of *S. sanguinis* II (ATCC 10557) and then connected to the respective abutments. The assemblies were incubated under anaerobic conditions for 14 days in a bacteriologic oven at 37°C, and monitored daily to observe solution cloudiness and therefore microbial leakage on the interface of the assemblies.

**Results:** There was solution cloudiness, showing bacterial growth, inside two Bicon<sup>®</sup> assemblies and two Ankylos<sup>®</sup> assemblies 48 h after incubation, the microbial leakage was traced by checking the suspension positive for the presence of *Streptococcus* sp. None of the sterility controls were contaminated.




Fig. 1. Assemblies contaminated numbers 21 and 20.




Fig. 2. Assemblies contaminated numbers 21 and 30.

**Conclusion:** (1) Irrespective of which of the two systems of activation of morse-taper implant connection was analyzed, tapped-in (Bicon<sup>®</sup>) or screwed-in (Ankylos<sup>®</sup>), this *in vitro* experiment showed bacterial leakage along the implant-abutment interface. (2) The frequency of bacterial leakage along the implant-abutment interface, with the two different morse-taper

implant systems, was 20% of the assemblies of each system and there were no statistical differences between them.

## Osteogenic stimulation of human mesenchymal cells by collagen-modified Ti surfaces

**Presenter:** Morra M

*Nobil Bio Ricerche, Portacomaro, Italy*

**Co-authors:** Morra M<sup>1</sup>, Cassinelli C<sup>1</sup>, Cascardo G<sup>1</sup>, Bollati D<sup>1</sup>, Rodriguez Y, Baena R<sup>2</sup>

<sup>1</sup>Nobil Bio Ricerche, Portacomaro, Italy, <sup>2</sup>University of Pavia, Pavia, Italy

**Background and aim:** Implant surface modification by bone-stimulating molecules could promote quicker and sustained bone regeneration in difficult implant sites. Collagen I is involved in osteogenesis and plays an essential role in BMPs activity. Surface modification of Ti implants by collagen enhances osteointegration in different animal models. Understanding relevant mechanisms could define indications and potential of this approach. The aim of this work is to perform a basic study on the behavior of Human Mesenchymal Cells (HMC) from bone marrow on doubly acid etched Ti surfaces modified by the covalent linking of collagen I.

**Materials and methods:** Grade 4 Ti disks were subjected to double acid etching treatment. One set of samples was further surface modified by covalent linking of porcine collagen I. Samples were evaluated by scanning electron microscopy and X-ray photoelectron spectroscopy. HMC were cultured on doubly acid etched and collagen-modified doubly acid etched Ti disks. Cell adhesion and growth were evaluated by fluorescence microscopy. Expression of osteogenic genes by Real-Time PCR tracked the progression of undifferentiated cells towards the osteogenic pathway. Experiments were performed in triplicate, statistical significance of data was evaluated by Wilcoxon's signed-rank test

**Results:** Fluorescence microscopy shows a higher number of HMC on collagen-modified surfaces with respect to control doubly acid etched Ti. The difference between data is statistically significant ( $P < 0.05$ ) at every time point checked (4, 12, 24 and 96 h). Cells change morphology at longer time (1–2–3 weeks) on collagen-modified surfaces, suggesting the onset of differentiation. RT-PCR shows upregulation of genes related to osteogenesis (collagen I and, most of all, alkaline phosphatase) by cells grown on collagen-modified Ti, confirming HMC differentiation along the osteogenic pathway on doubly acid-etched Ti surfaces bearing surface-linked collagen fibrils. Cells on plain doubly acid-etched Ti surfaces remain undifferentiated

**Conclusion:** The modification of implants surfaces by collagen I offers competitive advantage to HMC in the race to the implant surface, with respect to plain Ti surfaces. Collagen modification enhances HMC adhesion, directing cells towards the osteogenic pathway. Collagen endows implant surfaces with specific osteogenetic bioactivity. In clinical practice, this could lead to benefits in sites rich in cellular components or marrow (poor quality trabecular bone). Indications could exist in sites

involving bone augmentation and regeneration by cellular materials, inorganic fillers are less indicated to benefit from this approach.

### Cell biological activity on implant surfaces with different microstructure, roughness and chemical composition: an *in vitro* investigation

**Presenter:** Conserva E

Genova University, Albenga, Italy

**Co-authors:** Conserva E<sup>1</sup>, Lanuti A<sup>2</sup>, Menini M<sup>1</sup>

<sup>1</sup>Genova University, Genova, Italy, <sup>2</sup>Private Practice, Gubbio, Italy,

**Background and aim:** The interaction between cells and implant is determined by surface microstructure (roughness, pore dimension, depth and density) and chemical composition. Cells are not influenced by the properties of bulk material. To date is not yet clear which biological cell activity is affected by these parameters. The purpose of this study was to investigate if cell adhesion, spreading, proliferation and differentiation could be influenced by implant surface characteristics.

**Materials and methods:** The originality of this investigation was to test fixtures ready to use instead of model systems like disks. A number of 39 fixtures with a sandblasted surface (SB) (Ankylos<sup>®</sup>, Dentsply/Friadent) and of 39 with a grit blasted and high temperature acid-etched surface (GBAE) (Ankylos Plus<sup>®</sup>, Dentsply/Friadent) were investigated. Implants tested were from the same manufacturer, have identical macrostructure, same processes of production, decontamination, packaging and sterilization. The only factor that differentiates them was surface treatment. First implant macro- and microstructures were analyzed by SEM, at high and low voltage, then the surface roughness by Stereo-SEM analysis and chemical composition by XPS analysis. In biological tests SaOS-2 Osteoblasts coming from human osteosarcoma and human Mesenchymal Stem Cells (hMSCs) were used.

**Results:** The GBAE surface showed less surface contaminants such as Si, Cl, Al than the SB one and a very high percentage of Titanium, 19.7%, compared with the 14.2% of sandblasted surface (+38.7%). Both surfaces showed similar values of mean roughness ( $R_a$ ) but the depth of the porosity ( $R_z$ ) and density ( $R_{sm}$ ) were statistically increased in the GBAE surface ( $P < 0.01$ ). Cells on the GBAE surface showed better adhesion, had a greater amount of proliferation ( $P < 0.05$ ) and spread more rapidly. No statistically significant differences were found in ALP activity: both surfaces investigated supported cell differentiation toward an osteoblastic phenotype.

**Conclusion:** The quality ( $R_z$ ,  $R_{sm}$ ) but not the quantity ( $R_a$ ) of surface roughness seems to play a part in determining cell adhesion, morphology and proliferation. The macro/micro pore structured design and chemical composition can influence cell adhesion, morphology and proliferation but not differentiation. Since the only different parameters between the two groups are the quality of roughness ( $R_z$ ,  $R_{sm}$ ) and chemical composition are these that could determine the greater cell proliferation and spreading. Surface roughness, the micro design and surface

chemical composition did not play a role into *in vitro* cell differentiation.

### Histomorphometric and torque out evaluation of new laser treated implant surfaces: an *in vivo* study on ovine iliac crest

**Presenter:** De Benedittis S

University 'G. D'Annunzio' of Chieti, Campobasso, Italy

**Co-authors:** De Benedittis S<sup>1</sup>, Berardi D<sup>1</sup>, Malagola C<sup>2</sup>, Trisi P<sup>3</sup>, Perfetti G<sup>1</sup>

<sup>1</sup>University 'G. D'Annunzio' of Chieti, Campobasso, Italy, <sup>2</sup>Faculty of Medicine and Surgery, University of Rome "La Sapienza" II, Rome, Italy, <sup>3</sup>Bio.C.R.A., Pescara, Italy

**Background and aim:** Implant surface roughness and purity play a fundamental role in the osseointegration process. Common methods of roughness production generate irregular and unrepeatable surface patterns, and even contaminate implant surfaces with materials other than titanium which could interfere with the osseointegration process. On the other hand, laser engineering allows to preset those parameters which will determine implant roughness, in order to generate micrometric porosities repeatable in their shape, diameter and depth, as well as in their distribution and pitch. In addition, any contact between surface and the operating tools is avoided resulting in total absence of contaminants such as silica and aluminum. These particles, could have proinflammatory effects. The aim of this study is to carry out, in an animal model, a histomorphometric and biomechanic comparative evaluation between 20 and 30 laser implants and machined implants.

**Materials and methods:** Sample implants have a diameter of 3.8 mm and a length of 9 mm. 44 implants were inserted: 28 with half laser and half machined surface, seven with total laser surface, nine with total machined surface. They were placed in the iliac crest of five Bergamasca sheep, with an average weight of 60 kg, at the end of their skeletal growth. Animals were sacrificed 8 weeks after surgery, by an intravenous injection of Tanax (10 cm<sup>3</sup>). On all bone specimens histologic and histomorphometric analysis were estimated. On total laser and total machined implants, even biomechanical tests were carried out. On obtained data, a statistical analysis was performed.

**Results:** Biomechanical results show how the average Torque-out value of total laser implants are up to three times higher than machined implants value. Histomorphometric results demonstrate statistically significant differences ( $P < 0.0001$ ) in favour of laser surfaces.

**Conclusion:** In this study, histologic, histomorphometric and biomechanical results show how laser surface engineering is a viable method to obtain high superficial purity and an extremely regular and repeatable surface micromorphology, able to give a positive influence to bone cell response and to enhance osseointegration percentage value.

## Effect of fluoride and albumin in the electric potential of titanium implants coupled to a base metal restorative alloy

**Presenter:** Alfonso J

*Murcia University, Alicante, Spain*

**Co-authors:** Sanchez-Perez A<sup>1</sup>, Jornet-Garcia A<sup>1</sup>,

Moya-Villaescusa MJ<sup>1</sup>, Jacobo-Perez C<sup>2</sup>

<sup>1</sup>Department of Periodontology, Faculty of Medicine and Dentistry, Murcia University, Murcia, Spain, <sup>2</sup>Faculty of Medicine and Dentistry, Murcia University, Murcia, Spain

**Background and aim:** The actual use of fluoride composes in mouthwashes and implant surfaces can modify the electric potential of titanium implants. This effect can be altered by the buffer action of proteins like albumin. The aim of our study is register the electric potentials of titanium implants and the couple titanium implants-base metal alloy in four different solutions *in vitro*, in order to know the effect of both fluoride and albumin in the electric potential of implants.

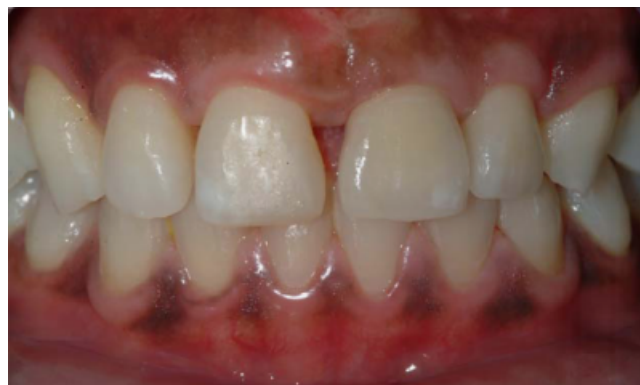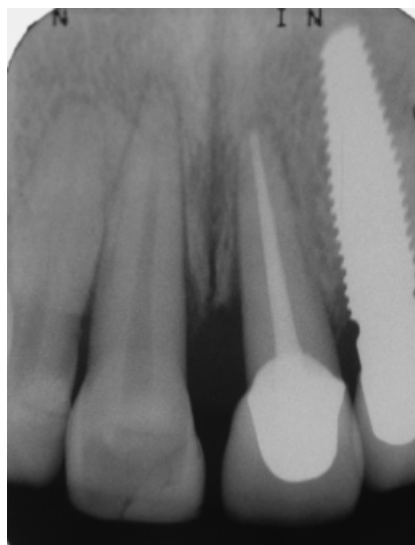
**Materials and methods:** A sample of 20 dental implants (Microdent System), with metal abutment base (cobalt-chromium) and four different solutions: (1) artificial saliva (a.s.), (2) a.s. + 0.01% Fl, (3) a.s. + 0.1% Fl and (4) a.s. + 0.1% Fl + 0.1% albumin. The test solutions had similar pH (6-7) and temperature (37°C + 0.5°C). The measurement device is composed by one electronic redox-potential meter, one periodontal probe as counter electrode and one referential electrode (Ag/AgCl, KCL). The electric potentials were measured on implants with 12 mm length and 3.75 diameter (N=20).

**Results:** The average potentials of Ti-implants measured in each solution were: (1) 258 mV, (2) 281 mV, (3) 360 mV and (4) 264 mV. For the couple Co-Cr alloy/Ti-implant the average potentials in each solution were: (1) 303 mV, (2) 318 mV, (3) 412 mV and (4) 385 mV. This results show that the electric potentials were higher for the couple implant-abutment in the four test solutions. Besides, the fluoride increases the potentials, the higher the concentration, the higher the potential. On the other hand, the addition of albumin decreases the potential.

**Conclusion:** The fluoride increase the electric potential of titanium implants with a similar pattern been coupled or not to a Co-Cr abutment. When we add albumin the effect of fluoride decreases.

material. Nevertheless, more clinical studies in 'true' conditions need to be conducted for validation of such an implant material. Indeed, esthetic implant sites often need hard and soft tissues management before implant placement that might compromise implant success rates. The aim of the present study was to evaluate prospectively the clinical outcomes of an experimental one-piece zirconia implant, in non-restrictive conditions.

**Materials and methods:** Twenty experimental one-piece zirconia implants were placed in esthetically demanding sites in 15 consecutive patients (12 women, 3 men; aged ranged from 18 to 65 years, mean 35.3 years). Heavy smokers were excluded (> 10 cigarettes per day). No restriction was addressed when previous bone regenerations/preservations were performed. Flapless or minimally invasive approaches were used in every implant sites. Provisional restorations were placed immediately. Outcomes were evaluated clinically and radiographically at baseline, 6, 12 and 18 months. Surgical, biological and prosthetic complications were also assessed.



**Results:** Most of the implants (90%) were placed at the anterior maxilla. Fourteen implants were placed in areas subjected to previous bone management and three implants were installed in fresh extraction sockets. Details in Table I. Every implant

## One-piece zirconia implant with a concave transmucosal profil: an 18-month prospective study

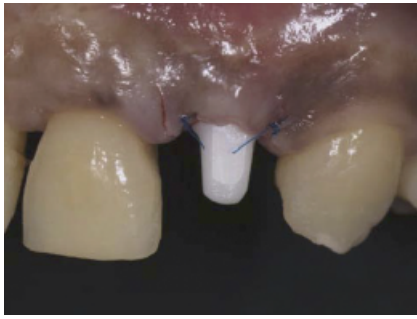
**Presenter:** Lambert F

*University of Liège, Liège, Belgium*

**Co-authors:** Lambert F, Rompen E

*University of Liège, Liège, Belgium*

**Background and aim:** Zirconia (ZrO<sub>2</sub>) seems to have the adequate mechanical and biological properties as dental implant



placement reached a adequate primary stability (insertion torque  $> 30 \text{ N cm}^{-2}$ ). All implants osteointegrated and were successfully restored with full ceramic crowns or bridges. The implant survival and success rates reached, respectively, 100% and 95%. One implant fractured at placement because of an excessive insertion torque ( $> 50 \text{ N cm}^{-2}$ ). No further complication occurred.

**Table I**

N = Implants	Implant site
6	Autogenous bone graft (Bone blocks)
8	Extraction socket preservation
3	Extraction and immediate implant
1	Implant placement + GBR
2	Non-augmented alveolar bone crest

**Conclusion:** From the preliminary results of this prospective clinical trial, one-piece zirconia implants seem to success after 18 months, despite they were often placed in critical clinical situations (bone augmentations) and immediately restored. Further follow-up is needed to evaluate the long-term outcomes of zirconia implants.

**386 | Poster – Topic Material Research**

Physicho/chemical characterization, biomechanical and histologic evaluation of three different grit-blasting and acid-etching surface treatments: An experimental study in dogs

**Presenter: Freire J**

*Private Practice, Florianopolis, Brazil*

**Co-authors:** Marin C<sup>1</sup>, Granato R<sup>1</sup>, Suzuki M<sup>2</sup>, Gil JN<sup>1</sup>, Freire JN<sup>3</sup>, Coelho P<sup>4</sup>

<sup>1</sup>Universidade Federal de Santa Catarina, Florianopolis, Brazil, <sup>2</sup>Tufts University, Boston, MA, USA, <sup>3</sup>Private Practice, Florianopolis, Brazil,

<sup>4</sup>New York University, New York, NY, USA

**Background and aim:** The objective of this study was to physicho/chemically characterize and compare the biomechanical fixation and bone-to-implant response to three different grit-blasting and acid-etching procedures in titanium alloy surfaces.

**Materials and methods:** The surfaces were characterized by electron microscopy (SEM), atomic force microscopy (AFM),

and X-ray photoelectron microscopy (XPS). Sand-blasted/acid-etched (SBAA), TCP-blasted/acid-etched (TBAA), and TCP-blasted (TB) screw type implants were placed along the proximal tibia of six beagle dogs ( $n = 12$  per surface) remaining for 3 and 5 weeks. Following euthanization, the limbs were retrieved and the implants were biomechanically tested (torque to interface fracture) in an automated system until a 10% drop from the maximum torque was recorded. Bone-to-implant contact (BIC) was determined for all specimens. Statistical analysis was performed by one-way ANOVA at 95% level of significance and Tukey's post-hoc test for multiple comparisons.

**Results:** Surface characterization showed that all surface treatments resulted in moderately rough surfaces. However, SBAA presented rougher profiles compared with the others. The biomechanical testing results showed significant differences between the implant surface groups ( $P < 0.01$ ; mean  $\pm$  95% CI in Ncm; 3weeks – TBAA =  $99.66 \pm 9.81$ , TB =  $93.35 \pm 9.82$ , SBAA =  $88.76 \pm 9.81$ ; 5 weeks – TBAA =  $117.41 \pm 9.81$ , TB =  $104.58 \pm 9.82$ , SBAA =  $96.01 \pm 9.81$ ). No differences in BIC were observed between groups.

**Conclusion:** Despite the rougher profile observed for the SBAA surface, bioactive ceramic grit blasting with or without subsequent acid etching resulted in higher biomechanical fixation after 5 weeks *in vivo*.

**387 | Poster – Topic Material Research**

Evaluation of the biomechanical fixation of a Ca-P molecular incorporation vs. a dual acid etched surface: an experimental study in dogs

**Presenter: Gil JN**

*Universidade Federal de Santa Catarina, Florianopolis, Brazil*

**Co-authors:** Gil J<sup>1</sup>, Marin C<sup>1</sup>, Granato R<sup>1</sup>, Suzuki M<sup>2</sup>, Lima C<sup>3</sup>, Oliveira S<sup>3</sup>, Lenharo A<sup>4</sup>, Coelho P<sup>5</sup>

<sup>1</sup>Universidade Federal de Santa Catarina, Florianopolis, Brazil, <sup>2</sup>Tufts University, Boston, MA, USA, <sup>3</sup>Universidade Federal de Uberlandia, Uberlandia, Brazil, <sup>4</sup>INEPO, Sao Paulo, Brazil, <sup>5</sup>New York University, New York, NY, USA

**Background and aim:** The objective of this study was to evaluate the biomechanical fixation of a Ca-P molecular incorporation versus a dual acid-etched surface in a dog tibia model.

**Materials and methods:** Dual acid-etched (control) and molecular Ca-P incorporation surfaces (Nanoss, SIN-AMG, Brazil-USA, Test) implants ( $n = 12$  each) screw type Tryon cylindric implants (SIN-AMG, GA, USA) were placed along the proximal tibia of six mongrel dogs ( $n = 12$  per surface) remaining for 2 and 4 weeks. Following euthanization, the limbs were retrieved and the implants were biomechanically tested (torque to interface fracture) in an automated system until a 10% drop from the maximum torque was recorded. Statistical analysis was performed by ANOVA at 95% level of significance and Tukey's post-hoc test for multiple comparisons.

**Results:** The biomechanical testing results showed significantly higher torque to interface fracture for the Test group implants



when compared with control ( $P < 0.04$ ; mean  $\pm$  95%CI in N cm; Control =  $95.78 \pm 10.62$ , Test =  $118.7 \pm 10.62$ ). A significant increase in torque to interface fracture was also found between 2 and 4 weeks implantation time. No differences in bone-to-implant contact was observed between groups and times in vivo.

**Conclusion:** The molecular incorporation of Ca-P positively influenced biomechanical fixation at early implantation times.

#### 388 Poster – Topic Material Research

The histologic evaluation of the resorbability and degradation of the absorbable collagen sponge following implantation on the three wall intrabony defects

**Presenter:** Sangmin L

*Seoul Veterans Hospital, Seoul, Korea*

**Co-authors:** Lee Sm<sup>1</sup>, Kim C<sup>2</sup>

<sup>1</sup>*Seoul Veterans, Seoul, Korea*, <sup>2</sup>*Yonsei University, Seoul, Korea*

**Background and aim:** Absorbable collagen sponge has been extensively used as carriers in bone tissue engineering due to its biocompatibility, biodegradation, low antigenicity, and high tensile strength. For evaluation of its biocompatibility, this study is compared the 8-weeks histologic results of periodontal healing with open flap curettage implanted buffer/Absorbable collagen sponge or open flap debridement only in the intrabony defects.

**Materials and methods:** Bilateral 3-wall intrabony periodontal defects were surgically induced in the premolar region in the maxilla and mandible in eight young adult Korean mongrel dogs. The surgical control groups received a flap operation only, while the collagen groups were treated with phosphate-buffered saline/Absorbable collagen sponge. The subjects were sacrificed 8-week after the operation, and a comparative evaluation was performed.

**Results:** The 8-week histologic results presented a low inflammatory response and similar periodontal healing in both groups. Absorbable collagen sponge dose not have negative or positive effects in periodontal healing and is almost resorbed in 8-weeks.

**Conclusion:** The low cost of production associated to the biocompatibility, absorbable collagen sponge is a promising carriers for bone defects treatment.

#### 389 Poster – Topic Material Research

Analyses of fractures of splinted posterior implants

**Presenter:** Yamaguchi Y

*Tokyo Medical and Dental University, Tokyo, Japan*

**Co-authors:** Yamaguchi Y<sup>1</sup>, Tachikawa N<sup>1</sup>, Kondo H<sup>2</sup>, Munakata M<sup>1</sup>, Ichinose S<sup>3</sup>, Shiota M<sup>2</sup>, Kasugai S<sup>2</sup>

<sup>1</sup>*Tokyo Medical and Dental University, Clinic for Implant Dentistry, Tokyo, Japan*, <sup>2</sup>*Tokyo Medical and Dental University, Oral*

*Implantology and Regenerative Dental Medicine, Tokyo, Japan*,

<sup>3</sup>*Tokyo Medical and Dental University, Instrumental Analysis Research Center for Life Science, Tokyo, Japan*

**Background and aim:** Titanium has been widely used as the most reliable material for dental implant. Although titanium

has an excellent mechanical characteristic, fractures of titanium implants have been reported. The purpose of the present study was to investigate implant fracture mechanism by analyzing the fractured implant surfaces.

**Materials and methods:** Fractured implants in four cases that had been splinted and placed in lower posterior region were examined. The fracture surfaces were analyzed with stereoscopic microscopy, scanning electron microscopy (SEM), and electron probe X-ray microanalysis (EPMA). Longitudinal sections of those implants were also prepared to observe details of their structure.

**Results:** Stereoscopic microscope observations revealed that a fatigue crack started at the lingual or buccal site. The fracture of the implant appeared to proceed along the circumference of the implant and end perpendicular to the long axis. SEM analyses showed striation like geometry suggesting metal fatigue. Corrosion of titanium would not be relevant to the fracture, due to the fact that chlorine was not detected by EPMA analysis. Panoramic radiograph showed that the fracture occurred at the border between osseointegration zone and bone resorption zone. The longitudinal sections and SEM photos demonstrated that the thinnest part of implant body was 500  $\mu$ m, at which the fracture line started. The fracture direction of the splinted implants was not mesio-distal but bucco-lingual. The level of the bone was positioned in the vicinity of the fractured site.

**Conclusion:** Based on these results, we speculated the following. It is likely that bending stress concentrated to the level of abutment screw tip when an occlusal force was applied to the superstructure. When bone level around the implant became close to the abutment screw tip, the repetitively concentrated bending stress would result in the fracture. The pitch of the external threads and internal threads of the implant was different. For that reason, the implant thickness changes periodically and the structurally thinnest part exists. When such a weak part locates at the tip level of the abutment screw, where the fracture occurs the most frequently, it will become the fulcrum of bending stress and thereby promote the concentration of stress.

#### 390 Poster – Topic Material Research

Surface characteristics and biocompatibility of titanium coated with dentin-derived hydroxyapatite by RF magnetron sputtering

**Presenter:** Yang Jin L

*College of Dentistry, Chonnam National University, Gwang Ju, Korea*

**Co-authors:** Lee Yj<sup>1</sup>, Son MK<sup>1</sup>, Vang MS<sup>1</sup>, Kim YJ<sup>1</sup>, Lee SH<sup>2</sup>, Lee DJ<sup>3</sup>, Lee KK<sup>3</sup>, Kim JH<sup>1</sup>

<sup>1</sup>*Department of Periodontology, School of Dentistry, 2nd Stage of Brain Korea 21 Project for School of Dentistry, Gwang Ju, Korea*, <sup>2</sup>*IAM private Dental Clinic, Sun Cheon, Korea*, <sup>3</sup>*School of Materials Science and Engineering, Chonnam National University, Gwang Ju, Korea*,

**Background and aim:** The aim of this study was to evaluate surface characteristics and biological properties of the dentin-derived hydroxyapatite coating on titanium substrate.

**Materials and methods:** Dentin-derived hydroxyapatite was derived from extracted human teeth with calcination method at 850°C. The commercially pure titanium (ASTM Grade II cp-Ti) was used as a metallic substrate and a radio frequency (RF) magnetron sputtering method was used as a coating method. Scanning electron microscopy (SEM) and energy dispersive X-ray analysis (EDX) were utilized to investigate the coating aspects and composition. Atomic force microscopy (AFM) and surface profiler were used to assess the surface morphology and roughness. Corrosion tests were performed in phosphate buffered saline at a  $36.5 \pm 1^\circ\text{C}$  in order to determine the corrosion behavior of the uncoated and coated specimens. The biocompatibility of dentin-derived HA coating specimens with fetal rat calvarial cell and human gingival fibroblast was assessed by SEM, ELISA analysis and RT-PCR gene expression analysis.

**Results:** The coating appeared to thin and homogeneously cover the surfaces without change of titanium substrate. The EDX analysis of this coating surface indicated the presence of Ca, P elements. The mean surface roughness of cp-Ti and dentin-derived coating specimens was  $0.27\text{ }\mu\text{m}$ ,  $1.7\text{ }\mu\text{m}$ , respectively. The corrosion test indicated the stable passive film of coating samples. SEM observations of fetal rat calvarial cell and human fibroblast cell on coated surface showed that cells have proliferated and developed a network of dense interconnections. ELISA analysis showed that the coating samples were not stimulated of the concentration of IL-6 and RANKL. The RT-PCR gene expression analysis also showed that there are no significant differences of gene expression between the non-coated and coated specimens.

**Conclusion:** These results suggest that dentin-derived hydroxyapatite coating with RF magnetron sputtering method has good surface characteristics and biocompatibility.

391	Poster – Topic Material Research
-----	----------------------------------

The effect of the micro and nanostructural surface of titanium implants on the proliferation activity of osteoblast cells

**Presenter:** Joób - Fancsaly Á

*Semmelweis University, Budapest, Hungary*

**Co-authors:** Joób-Fancsaly Á<sup>1</sup>, Huszar T<sup>1</sup>, Bogdán S<sup>1</sup>, Karacs A<sup>2</sup>, Pető G<sup>2</sup>, Divinyi T<sup>1</sup>, Barabás J<sup>1</sup>

<sup>1</sup>*Semmelweis University, Budapest, Hungary*, <sup>2</sup>*MTA-MFA, Budapest, Hungary*

**Background and aim:** Surface morphology is attributed a decisive role in the osseointegration of dental implants. It is supposed that surface elements in the nanometre range have an effect on the activity and proliferation of osteoblast cells. The objective of the present studies was to analyse the effect of various surface modifications of test implants on osteoblast cells.

**Materials and methods:** MC3T3 osteoblast cells were cultured for two weeks on 24-well plates in DMEM + 10% FBS medium on the surface of titanium disks with surfaces modified by various methods. Then the proliferation activity of cells on

the surface was measured with the MTT method and with a DNA proliferation test. At the same time the morphological changes of the cell populations forming on the surface were studied with SEM and AFM.

**Results:** Electron microscopic and AFM studies proved that nanometre surface structures influence cell activity and differentiation. The results of cell proliferation studies suggest that nanometre surface roughness does increase cell proliferation.

**Conclusion:** The nanometre differences in surface roughness probably influence cell activity, mitosis and extra cellular matrix production through an effect on cytoskeleton function and transcription activity. The present study examined which surface modification method could be the most effective as far as the proliferation and activation of osteoblast cells playing a role in osseointegration is concerned.

392	Poster – Topic Material Research
-----	----------------------------------

Heat progression in human bone caused by trephine osteotomies: influence of irrigation mode concerning drilling depth, drill diameter and drill wear out

**Presenter:** Arnhart C

*Medical University of Vienna, Bernhard Gottlieb Dental School, Vienna, Austria*

**Co-authors:** Arnhart C<sup>1</sup>, Pommer B<sup>1</sup>, Unger E<sup>2</sup>, Cepic L<sup>1</sup>, Huber C<sup>1</sup>, Watzak G<sup>1</sup>, Watzek G<sup>1</sup>

<sup>1</sup>*Department of Oral Surgery, Bernhard Gottlieb Dental School, Medical University of Vienna, Vienna, Austria*, <sup>2</sup>*Department of Biomedical Engineering and Physics, Medical University of Vienna, Vienna, Austria*

**Background and aim:** Trephine osteotomies (TO) may cause rise in local temperature due to friction. Thermal injury of bone causes cell necrosis and protein denaturation delaying local regenerative capacity. In order to assess the influence of drilling depth, drill diameter and drill wear during TO thermal changes were monitored in this in vitro model. Further the impact of a supplementary internal irrigation system was examined.

**Materials and methods:** Overall 400 TO (STOMA® trephines 5/6 and 8/9 diameter) were realized to a depth of 6 mm in 10 unfixed human calvarias by a standardized procedure applying a constant force of 37 N and a rotation speed of 2000 rpm. Test group consisted of technically modified trephines with an additional internal cooling system. For control standard trephines with a conventional external irrigation system were used. Temperature was recorded on surface and in a depth of 2, 4 and 6 mm by a 4-canal-thermocouple placed in a vertical canal drilled 1 mm adjacent to the drilling site.

**Results:** A depth dependent rise in temperature could be observed with a maximum at 4 mm ( $P < 0.05$ ). Drill diameter has no influence on bone heating ( $P > 0.05$ ). Diameter size 8/9 accomplishes the cutting procedure twice as long as size 5/6 ( $P < 0.05$ ). Worn trephines cause higher temperatures ( $\Delta T = 14.44^\circ\text{C}$  vs.  $12.14^\circ\text{C}$ ) ( $P < 0.05$ ). Modified 8/9 trephines produce less heat than the standard 8/9 trephines ( $\Delta T = 11.87 \pm 5.86^\circ\text{C}$  vs.  $14.38 \pm 4.5^\circ\text{C}$ ) ( $P < 0.05$ ) though their drilling time is longer ( $P < 0.05$ ).

**Conclusion:** TO cause extensive rise in temperature and therefore are at risk to cause thermal injury. Modification of larger trephines and the use of a supplementary internal irrigation system significantly reduce bone heating.

393 | Poster – Topic Material Research

### Biomechanical responses on different implant diameters: a finite elements simulation

**Presenter:** Baggi L

*University tor Vergata, Rome, Italy*

**Co-authors:** Baggi L, Arullani C, di Girolamo M

*University tor Vergata, Rome, Italy*

**Background and aim:** The implant abutment connection has been one of the most developing points in implants systems, especially with the introduction of the platform shifting concept where the shape and position of the implant-abutment coupling and gap plays a very important role. The aim of this study was to evaluate the mechanical properties of the implant abutment connection of Ankylos System.

**Materials and methods:** Three Ankylos implants of 3.5 mm (A), 4.5 mm (B), 5.5 mm (C) and 11 mm length with a Balance posterior abutment, either in Ti6Al4V and in zirconia were analyzed with a FEA simulation. Finite-element simulations for implants are carried out considering a functional load applied at the top of the abutment angled at about  $22 \pm$  with reference to z. The lateral component of the force along buccal–lingual axis (opposed to the x axis direction, is as summed equal to 100 N and the vertical intrusive one is 250 N. Von Mises stress field  $3/4VM$  is used as a global stress measure for characterizing load transfer mechanisms on a given implant or device.

**Results:** The results of the analysis shows that for the implant–titanium abutment the tensile break point is around 1170 MPa and in the range of this study the force applied do not reach this limit in the neck region of the abutment, while in the shoulder region this limit can be reached, even if the plastic deformation of titanium could dissipate the excess of load. Regarding the implant–zirconia oxide abutment the tensile break point is around 820 MPa for the yttrium-stabilized zirconia and 1300 MPa for the yttrium–aluminium-stabilized zirconia. For the first case (yttrium-stabilized zirconia) the break point is reached in both neck and shoulder region, while in the second case (yttrium–aluminium-stabilized zirconia) the break point is never reached considering the forces used in this study.

**Conclusion:** Within the limits of this study, we can consider that clinically whichever the diameter of the implant we can use the titanium alloy balance posterior abutment without problem of overloading the system. Regarding the forces transferred to bone from the three different diameter implants, the 3.5 shows the highest loading forces but always within the safe range, so we can assume that this diameter can be safely used in the maxillary and mandibular posterior regions even for molar elements.

394 | Poster – Topic Material Research

A comparative histological and immunohistochemical study of wound healing following incision with a scalpel, diode laser or Er, Cr:YSGG laser in guinea pig oral mucosa

**Presenter:** Yoon HJ

*St. Mary's Hospital, The Catholic University of Korea, Seoul, Korea*

**Co-authors:** Jin JY<sup>2</sup>, Lee SH<sup>1</sup>, Yoon HJ<sup>1</sup>

<sup>1</sup>*St. Mary's Hospital, The Catholic University of Korea, Seoul, Korea,*

<sup>2</sup>*Practice in Private Clinic, Seoul, Korea*

**Background and aim:** This study was undertaken to compare the wound healing following incisions with either a scalpel, a diode laser or an Er,Cr:YSGG laser in Guinea pig oral mucosa.

**Materials and methods:** Three types of wounds were randomly made with either a stainless steel scalpel, a Diode laser or an Er,Cr:YSGG laser in the buccal mucosa of each of 24 Guinea pigs. Five Guinea pigs were sacrificed on days 1, 3, 5 and 7 post-surgery. Four Guinea pigs were sacrificed on day 14 post-surgery. Biopsy samples from each oral mucosa wound were examined using light microscopy and the expression of TNF- $\alpha$  and TGF- $\beta$ 1 was determined by immunohistochemical staining. The expression of TNF- $\alpha$  and TGF- $\beta$ 1 was evaluated by calculating the percentage of positively stained cells and immunostaining intensity using a scale of 0–3.

**Results:** Infiltration of inflammatory cells rapidly decreased at day 5 post-surgery in all three groups of animals. The highest level of TNF- $\alpha$  expression was found at day 1 post-surgery for the Diode laser wounds. The intensity of TNF- $\alpha$  immunostaining was the highest at day 3 post-surgery and the lowest at day 7 post-surgery for all three groups of animals. For the scalpel wounds, a lower level of TGF- $\beta$ 1 expression was seen until day 3 post-surgery and a higher level from day 7 post-surgery compared with laser wounds. The intensity of TGF- $\beta$ 1 immunostaining was the highest at day 1 post-surgery for the Diode laser wounds

**Conclusion:** Although the Diode laser is considered a good cutting device for the oral mucosa, more tissue damage occurs than with the use of a scalpel or an Er,Cr:YSGG laser. However, additional larger studies will be needed before fully endorsing its widespread use.

395 | Poster – Topic Material Research

Lessons from the bone marrow: how biomaterials can affect the differentiation of stem cells into osteoclasts and osteoblasts

**Presenter:** Gruber R

*Medical University of Vienna, Vienna, Austria*

**Co-authors:** Gruber R, Agis H, Watzek G

*Medical University of Vienna, Vienna, Austria*

**Background and aim:** Collagen membranes and bone substitutes are commonly used in oral implantology. The process of consolidation relies on the differentiation of stem cells into



osteoclasts, the cells that resorb bone and into osteoblasts, the cells that form bone. Thus, the interactions between the biomaterials and the stem cells can affect the consolidation process. The extent, however, to which collagen membranes and bone substitutes can modulate the differentiation of stem cells into mature osteoblasts and osteoclasts is generally unknown.

**Materials and methods:** We therefore examined the effect of a collagenous membrane (Bio-Gide, Geistlich Biomaterials, Wolhusen Switzerland), a deproteinized bovine bone mineral (Bio-Oss, Geistlich Biomaterials), and potential carriers (carboxymethylcellulose and hydroxypropylmethyl cellulose) on the differentiation of osteoclasts (tartrate-resistant acid phosphatase-positive multinucleated cells) and osteoblasts (alkaline phosphatase-positive colony formation) in primary murine bone marrow cell cultures.

**Results:** Bone marrow cell cultures revealed that the number of osteoclasts was significantly decreased when hematopoietic stem cells were cultivated on the surface of the collagenous membrane. When stem cells are cultivated in the presence of conditioned medium from deproteinized bovine bone mineral, no substantial changes in osteoclastogenesis were observed. Carboxymethylcellulose caused a substantial reduction of osteoclastogenesis, while hydroxypropylmethyl cellulose showed only minor effects under these conditions. The formation of alkaline phosphatase-positive colonies from mesenchymal stem cells was not substantially affected by the biomaterials.

**Conclusion:** Our findings indicate that the bone marrow in vitro model is suitable to learn how biomaterials can affect the differentiation of stem cells into osteoclasts and osteoblasts. The data led us to suggest that suppression of osteoclastogenesis holds a potential explanation why Bio-Gide can protect a defect site from unwanted bone resorption. We found that, by selecting the appropriate carrier, the consolidation process of Bio-Oss can be modulated. The bone marrow in vitro model can help us to understand the in vivo behavior of established biomaterials and support the preclinical development of new innovative biomaterials.

#### 396 | Poster – Topic Material Research

The effect of tensile force installed in the tightened abutment screw on peri-implant marginal bone stresses

**Presenter: Khraisat A**

*Faculty of Dentistry, University of Jordan, Amman, Jordan*

**Co-authors: Khraisat A**

*Faculty of Dentistry, University of Jordan, Amman, Jordan*

**Background and aim:** Marginal bone resorption, even in mild forms, is one of the most important shortcomings in modern implant dentistry. The aim of this study was to investigate, solely, the effect of tensile (compact) force installed in the tightened abutment screw on peri-implant marginal bone stresses in the absence of any external or functional loads.

**Materials and methods:** Based on commercially available implant system, models of implant parts were built and positioned

properly in a CAD assembly using CAD software (CATIA V5 R17 SP5). The bone block and the three mechanical parts; implant, abutment, and abutment screw were built as single parts without cross references to each other. For the finite element analysis, meshing and the generation of boundary conditions, loads, and interactions were performed with CATIA V5. The entire model was exported to ABAQUS 6.7 with AFC 2.4. The outer threads of the implant were connected to the bone with a rigid connection. The contact of the implant's collar with the bone was simulated with a frictionless contact with a 'hard' normal behavior. The sole tightening torque of 40 Ncm was applied on the screw on its axis of rotation. The resultant effects of tightening torque on implant/abutment joint assembly and the surrounding bone were analyzed.

**Results:** The application of tightening torque on the abutment screw lead to the compression of the implant collar during and after tightening. Post-tightening tensile force installed in the abutment screw caused compression that resulted in implant axial deformation of about 3 µm at joint level. This, in turn, resulted in stress distribution on the bone in the region of the implant's collar that had a magnitude of 60 MPa. In addition, a tilting deformation of the implant's collar could also be monitored and was inflicted on bone as stress in radial direction.

**Conclusion:** The solely installed tensile (compact) force in the abutment screw deforms the implant collar at joint level axially and horizontally. This deformation should result in compressive stresses on marginal bone even in the absence of any external or functional loads.

#### 397 | Poster – Topic Material Research

CAD-CAM implant-supported zirconia–ceramic full arch prosthesis: 12 months study

**Presenter: Rossi G**

*Private Practitioner, Chieti, Italy*

**Co-authors: Di Alberti L, Camerino M, Donnini F, Di Vera A, Germano R**

*Private Practitioner, Chieti, Italy*

**Background and aim:** This study evaluated the clinical performance of screwed and cemented CAD-CAM customized zirconia implant-supported full arch prosthesis. Additionally, the marginal fit between the selected implant components was measured and the clinical gingival response was monitored.

**Materials and methods:** Ten patients were consecutively selected for a prospective study of 15 implant-supported restorations. CAD CAM customized zirconia complexes full arches prosthesis were prepared, then ceramic was performed directly. Plaque and gingival indices were recorded monthly intervals over a 12-month period.

**Results:** All zirconia-ceramic CAD CAM full arches prosthesis offered sufficient stability to support implant supported reconstructions in anterior and premolar regions. The soft and hard tissue reaction toward zirconia was favorable.

**Conclusion:** We can conclude that full arch zirconia bridges is an highly aesthetic and favorable approach for oral rehabilitation

Fracture strength and failure analysis of provisional implant supported composite resin crowns: polyetheretherketone temporary abutments vs. solid titanium temporary abutments, an *in vitro* study

**Presenter: Santing H**

UMCG, Groningen, The Netherlands

**Co-authors:** Santing H<sup>1</sup>, Meijer H<sup>1</sup>, Raghoobar G<sup>1</sup>, Ozcan M<sup>2</sup>

<sup>1</sup>UMCG Department of Oral and Maxillofacial Surgery, Groningen, The Netherlands, <sup>2</sup>UMCG Center for Dentistry and Oral Hygiene, Groningen, The Netherlands

**Background and aim:** This study compared the fracture strength of implant supported composite resin restorations on Polyetheretherketone (PEEK) temporary abutments and solid titanium temporary abutments.

**Materials and methods:** This study included 12 groups consisting of three types of provisional abutments: The Straumann® RN synOcta® Temporary Meso Abutment, the Straumann® RN synOcta® titanium posts for temporary restorations and the Nobel Biocare® Immediate Temporary Abutment NobRpl RP with composite resin restorations [Solidex®, Shofu, Higashiyama-Ku, Kyoto, Japan) on four different locations in the upper jaw (right central incisor, right lateral incisor, right cuspid and right first bicuspid and one control group consisting of all ceramic implant supported crowns (right central incisor). Each group consisted of eight specimens yielding to a total of 104 specimens. The specimens were tested in a universal testing machine with a crosshead speed of 1.0 mm/min until fracture occurred. The data were statistically analysed for differences using one-way analysis of variance (ANOVA) and the Tukey's test. *P*-values <0.05 were considered to be statistically significant in all tests.

**Results:** Composite resin restorations on PEEK temporary abutments showed significant lower fracture loads ( $95 \pm 21$  N) for the central incisor than composite resin restorations on titanium temporary abutments ( $1009 \pm 94$  N). No significant differences were found for the other locations in the upper jaw.

**Conclusion:** Composite resin restorations on PEEK abutments showed a significantly lower fracture resistance compared with composite resin restorations on titanium temporary abutments for the reconstruction of the central incisor.

Effect of rat adipose-derived mesenchymal cells on calcium phosphate formation on micro-arc oxidized titanium surface

**Presenter: Chen Z**

Guanghua School of Stomatology, Sun Yat-sen University, Guangzhou, China


**Co-authors:** Chen Z<sup>1</sup>, Li Z<sup>1</sup>, Yi J<sup>1</sup>, Xu J<sup>2</sup>

<sup>1</sup>Guanghua School of Stomatology, Sun Yat-Sen University, Guangzhou, China, <sup>2</sup>School of Materials Science and Engineering, Harbin Institute of Technology, Harbin, China


**Background and aim:** Adipose-derived mesenchymal cells (ADMCs) have been suggested to be a more convenient source of mesenchymal origin than those isolated and expanded from bone marrow when regarding their abundance and accessibility in bone tissue engineering. There is little data available, however, regarding the effect of ADMCs on calcium phosphate formation on titanium biomaterials. This study was therefore to investigate the *in vitro* effect of rat ADMCs on calcium phosphate formation on micro-arc oxidized (MAO) modified titanium surfaces by a scanning electron microscope (SEM) with an energy dispersive spectrometer (EDS).

**Materials and methods:** Commercial pure titanium discs were used as the substrates for MAO treatment. Rat ADMCs at the third passage were seeded at a density of 10,000 cells/cm<sup>2</sup> on the MAO-modified titanium discs serving as the experimental group. The cells were left to adhere and grow for 24 h and then induced to osteogenic differentiation by adding osteogenic supplement (10 nM/l dexamethasone, 0.2 mM/l ascorbic acid and 10 mM/l  $\beta$ -glycerolphosphate) to the DMEM medium. In the control group, no cells were seeded on the MAO-modified titanium discs, while only medium with osteogenic supplement was added. The adhesion status of ADMCs was analyzed with SEM (Philips XL30, Holland). The surface element composition was analyzed with EDS.

**Results:** ADMCs were shown to just attach to the substrate when seeded on the titanium for 1 h, while the filopods were stretched out and adhered to the substrate intensively for 2 hours in the experimental group (Fig. 1). Acicular crystals were observed on the cells' surfaces after ADMCs were induced to osteogenic differentiation for 7 days (Fig. 2). These acicular



crystals, with a Ca/P ratio of 1.45 measured by EDS, could be identified in almost every  $\times 1000$  fields of the microscope in the experimental group. On the other hand, such acicular crystals could only be detected in about every 20  $\times 1000$  fields of the microscope in the control group.



**Conclusion:** ADMCs enhanced calcium phosphate formation on MAO treated titanium surface when induced to osteogenic differentiation.

**Acknowledgement:** Supported by Chinese NSFC Grant, 30500570.

#### 400 Poster – Topic Material Research

### Early human bone response to laser metal sintering surface topography: a histologic evaluation

**Presenter:** Shibli J

*University of Guarulhos, Guarulhos, Brazil*

**Co-authors:** Shibli J<sup>1</sup>, Mangano C<sup>2</sup>, Mangano F<sup>3</sup>, Iezzi G<sup>4</sup>, Cardoso L<sup>1</sup>, Onuma T<sup>1</sup>, Ferrari D<sup>1</sup>, Piattelli A<sup>4</sup>

<sup>1</sup>University of Guarulhos, Guarulhos, Brazil, <sup>2</sup>University of Insubria-Varese, Varese, Italy, <sup>3</sup>Private Practice, Como, Italy, <sup>4</sup>University of Chieti, Chieti, Italy

**Background and aim:** Earlier studies have shown that direct laser metal sintering (DLMS) technique produces structures with complex geometry that allow better osteoconductive properties. The aim of this study was to evaluate the influence of the DLMS topography on bone-to-implant contact (BIC%), on bone density in the threaded area (BA%) as well as bone density outside the threaded area (BD%) in type IV bone after 8 weeks of unloaded healing.

**Materials and methods:** Thirty patients (mean age  $51.34 \pm 3.06$  years) received one micro-implant (2.5 mm diameter and 6 mm length) each during conventional implant surgery in the posterior maxilla. Thirty micro-implants with three topographies were evaluated: 10 machined (cpTi); 10 sandblasted and acid etched surface (SAE) and 10 DLMS micro-implants. DLMS surface topography was prepared by a selective laser sintering procedure using a Ti-6Al-4V alloy powder with a particle size of 1–10 µm.

After 8 weeks, the micro-implants and the surrounding tissue were removed and prepared for histomorphometric analysis.

**Results:** Four micro-implants (2 cpTi, 1 SAE and 1 DLMS) showed no osseointegration after the healing period. Histometric evaluation indicated that the mean BIC% was higher for the DLMS and SAE surfaces ( $P=0.0002$ ). The BA% was higher for the DLMS surface, although there was no difference with the SAE surface. The BD% was similar for all topographies ( $P>0.05$ ).

**Conclusion:** Data suggest that the DLMS and SAE surfaces presented a higher bone-to-implant contact rate compared with cpTi surfaces under unloaded conditions, after a healing period of 8 weeks.

#### 401 Poster – Topic Material Research

### Preload loss of different screw retention systems as a function of time and tightening/removal sequences

**Presenter:** Bernardes S

*Latin American Institute of Research and Dentistry Education, Curitiba, Brazil*

**Co-authors:** Rocha Bernardes S<sup>1</sup>, John H<sup>2</sup>, John K<sup>2</sup>, Howell P<sup>2</sup>, Chiarello Mattos Md G<sup>3</sup>

<sup>1</sup>Latin American Institute of Research and Dentistry Education, Curitiba, Brazil, <sup>2</sup>Eastman Dental Institute, London, UK, <sup>3</sup>Sao Paulo University/Dental School of Ribeirão Preto, Ribeirão Preto, Brazil

**Background and aim:** Screw loss is one important failure in Implant Dentistry which can result in screw fracture, prosthesis failure, increased bone loss or even implant failure. Loss of preload in the retention screw is a possible reason for the problem, and manufacturers have been developing different implant/abutment interfaces and screw designs and materials to minimise the problem. Screw retightening after a period of time has also been suggested as a method of reducing preload loss.

**Materials and methods:** Preload loss of different prosthetic screws was evaluated during the first 5 min after tightening and over five consecutive tightening/removal sequences (five samples of the following groups: external hex implants, titanium and DLC screws tightened to 32 Ncm; internal hex, titanium screws, 20 Ncm; Morse taper implants, one piece abutment, 20 and 32 Ncm). The samples were inserted on an electronic torque driver and the preload (N) results were measured continually by strain gauges attached to the cervical third of custom implant bodies (smooth surface, without threads). Calibration procedures were performed to all samples.

**Results:** There was no detected preload loss over the 5 min observation period. ANOVA tests performed within the groups did not indicate a statistical difference for any of the 5 torque/untorque sequences. For the preload analysis, there were no statistical differences (Tukey) between the external hex groups with different screws ( $P=.963$ ) and the Morse taper groups ( $P=.990$ ). The internal hex group had the highest results preload, which was statistically different from those of the other two groups ( $P=1.000$ ).

**Conclusion:** There were no settling process for any of the groups during the first 5 min after tightening, neither before or after the five tightening/removal sequences. External hex implants were associated with a lower preload over the implant cervical third. For the internal interfaces, the Morse taper implants presented higher structural reinforcement over the area, independent of the applied torque, both at 20 or 32 Ncm, because of it, torques of 32 Ncm were more appropriate for this group. Internal hex interfaces resulted in the higher stress over the implant cervical third.

### Effectiveness of different implant neck surfaces on osteointegration and inflammation: a multicenter pilot study

**Presenter:** Calderini M

*Private Practitioner, Chieti, Italy*

**Co-authors:** Di Alberti L, Camerino M, Donnini F, Reale G, Buonavventura F, Di Alberti C, Calderini M

*Private Practitioner, Chieti, Italy*

**Background and aim:** Cell-surface interactions play a crucial role for biomaterial application in implantology. It is evident that not only the chemical composition of solid substances influence cellular adherence, migration, proliferation and differentiation but also the surface topography of a biomaterial. The progressive application of nanostructured surfaces in medicine has gained increasing interest to improve the cytocompatibility and osteointegration of dental implants. Increased surface roughness of dental implants enhances the process of osseointegration. It increases bone conduction and increases BIC in all types of bone, resulting in elevated removal torque values. Surface roughness elevated the CSR of implants implanted in adverse conditions as augmented ridges and sinuses and areas of poor bone, such as the posterior maxilla, and in some cases abolished the deleterious effect of smoking. A growing number of clinical studies suggest that early and immediate loading of rough-surfaced implants may lead to predictable osseointegration.

**Materials and methods:** This clinical single blind controlled study has tested and studied during the 12 weeks bone healing period the effectiveness of two different implant neck surface treatments of Mistral one stage implant (MIS, Israel) on osteointegration, bone-implant contact, bone-implant densitometry and RFA analysis.

**Results:** The full treated neck has showed a better and faster osseointegration process compared with smooth neck. Nevertheless a slightly higher percentage of inflammation cases have been showed in the full neck study group.

**Conclusion:** Following the results of this multicenter study we can conclude that a full treated neck single step implant may improve the osseointegration process but may lead in some cases to more gingival inflammation around the neck of the fixtures.

### Injectable calcium-phosphate grafting promotes new bone formation: bone markers study in a rabbit model

**Presenter:** Gehrke SA

*Bioface Insitut, Santa Maria, Brazil*

**Co-authors:** Gehrke SA<sup>1</sup>, König B Jr<sup>2</sup>, Salles MB<sup>1</sup>

<sup>1</sup>Bioface Insitut, Santa Maria, Brazil, <sup>2</sup>University of São Paulo, São Paulo, Brazil

**Background and aim:** The aim of the present study was to assess the influence of an injectable calcium phosphate cement on new bone formation in rabbit tibiae. The bone growth was followed-up through the injection of polyfluorochromic bone markers over different periods of time, up to 8 weeks. The histological sections were analysed by fluorescence microscopy.

**Materials and methods:** Four adult white New Zealand female rabbits (*Oryctolagus cuniculus*) with an average weight of 3.5 kg were used in this study. The animals were kept free in an appropriate facility and fed *ad libitum* with standard laboratory diet. The bone grafting material used in this study was an injectable calcium phosphate cement (PD VitalOs Cement<sup>®</sup>, Produits Dentaires SA, Switzerland). Bone defects were created by drilling with a trephine bur (diameter 4 mm) inside each tibia (two sites next to each other per tibia). The cement was injected to fill the sites of the right tibia of each animal (experimental sites, EXP). The left tibiae provided control sites (CON), left empty (only blood clot). The injection of polyfluorochromic bone markers was performed at specific time intervals (alizarin at days 14 and 21, calcein at days 28 and 35, tetracycline at days 42 and 49). The sacrifice of the animals took place at day 56 (8 weeks after grafting).

**Results:** The grafted sites (EXP) showed deposition of new bone and complete resorption of the material, especially in the tetracycline and calcein phases, represented by brown and green colors respectively in fluorescent light. These results indicate that bone neoformation in grafted samples had already started between day 14 and 28 after surgery. An intensive new formation of bone was noticed. The new bone was highly fluorescent, which is a sign for its maturity. Non-grafted samples (CON) showed a stronger bone deposition in the calcein marker phase, represented by the green color in fluorescent light. These results clearly indicated a delayed bone new formation in controls, which did not start before day 28 after surgery. The brown color of the tetracycline does not appear clearly, which indicates that the bone neoformation process slows down after day 35. Moreover, the fluorescence of the new bone tissue was weak in non-grafted samples, which is typical for less mature bone.

**Conclusion:** PD VitalOs Cement was used very efficiently as a bone grafting material. The histological sections of the areas augmented with the cement have shown the ability of the product to promote predictably osteogenesis, resulting in a firm osseous tissue once the cement is completely resorbed.

Fractal analysis: a novel method to study roughness organization of implant surface topography

**Presenter: Piattelli A**

*University of Chieti-Pescara, Chieti, Italy*

**Co-authors: Piattelli A<sup>1</sup>, Perrotti V<sup>1</sup>, Degidi M<sup>2</sup>, Aprile G<sup>1</sup>, Iezzi G<sup>1</sup>**

<sup>1</sup>University of Chieti-Pescara, Chieti, Italy, <sup>2</sup>Private Practice, Bologna, Italy

**Background and aim:** Surface roughness is important for implant osseointegration. It has mostly been assessed by width parameters analysis. Fractal dimension ( $D_f$ ) is a parameter that describes the organization of surface roughness. The greater is  $D_f$  value, the more chaotic is the surface topography. It has been found that cell adhesion and proliferation are lower on chaotic surfaces, and thus on substrates with high  $D_f$  values. The aim of this study was to analyze the  $D_f$  of three different implant surfaces.

**Materials and methods:** Forty-five disk-shaped, commercially pure Grade 2 titanium samples (10 × 2 mm) with three different surface topographies (DENTSPLY, Friadent GmbH, Mannheim, Germany) were analyzed in the present study: group A: machined surface; group B: DPS (deep profile structure) surface; group C: PLUS surface. Samples belonging to the three different groups were mounted onto aluminum stubs and sputter gold-coated for surface characterization by SEM. Samples have been processed for scanning electron microscopy (SEM) and images at × 50,000 and × 20,000 have been collected, binarized and skeletonized using ImageJ 1.40g (Wayne Rasband, National Institute of Health, Bethesda, MD, USA) for quantitative analysis of  $D_f$ .  $D_f$  was calculated using the box-counting method by FracLac 2.5 release 1D, a plugin of ImageJ (A. Karperien, Charles Sturt University, Australia).

**Results:**  $D_f$  values were correlated to the image magnification. At × 50,000,  $D_f$  value for machined, DPS and PLUS were 1.78, 1.59, and 1.42, respectively. At × 20,000,  $D_f$  values were higher for all the examined groups and more specifically, 1.77, 1.64, 1.59 for machined, DPS and PLUS surface, respectively.

**Conclusion:**  $D_f$  is widely and successfully used as a measurement to characterize anatomic structures (i.e.: heart, lungs, liver, kidney, retina, blood vessels, neurons), physiologic processes (i.e.: angiogenesis, pharmacokinetic, bone healing on radiography) and pathologic processes (i.e.: tumor growth).  $D_f$  analysis provides not only an index of roughness size values, but also a measure of roughness spatial organization; therefore, it could be a promising method to differentiate between rough surfaces capable of supporting osseointegration.

Clinical and histological study in alveolar bone following post-extraction socket augmentation using master GRAFT<sup>®</sup> granules

**Presenter: Wakimoto M**

*Okayama University Graduate School of Medicine, Dentistry and Pharmaceutical Sciences, Okayama, Japan*

**Co-authors: Wakimoto M<sup>1</sup>, Ueno T<sup>2</sup>, Hirata A<sup>1</sup>, Shirasu N<sup>1</sup>, Yamada T<sup>1</sup>, Matsumura T<sup>3</sup>, Sano K<sup>2</sup>, Sugahara T<sup>4</sup>, Aghaloo T<sup>5</sup>, Moy PK<sup>5</sup>**

<sup>1</sup>Okayama University Graduate School of Medicine, Dentistry and

Pharmaceutical Sciences, Okayama, Japan, <sup>2</sup>University of Fukui

Hospital, Yoshida-County, Japan, <sup>3</sup>Okayama University Hospital,

Okayama, Japan, <sup>4</sup>Aichi-Gakuin University, Nagoya, Japan,

<sup>5</sup>University of California Los Angeles School of Dentistry, Los Angeles, CA, USA

**Background and aim:** Sufficient bone volume is required for stabilization and integration of dental implants. Bone augmentation may be needed in some patients before implant placement to establish adequate bone volume. After tooth extraction, the alveolar ridge will commonly decrease in volume and change morphologically. Although autogenous bone grafts are the gold standard procedure, its shortcomings are known to limit bone sampling volume, infection of both donor and recipient sites and cause postoperative disorders such as paresthesia. Clinical and histological evaluation was performed of sockets grafted with Master graft granules in patients before dental implantation.

**Materials and methods:** In 79 patients with an age range between 16 and 88 years (average age 58.13 ± 13.44 years old, 44 males and 35 females), Master Graft<sup>®</sup> granules were used to graft the extraction socket defect to preserve ridge form and after tooth extraction. Master Graft<sup>®</sup> granules were covered with a cellulose sponge. At the time of implant placement, after 4–5 months of healing, bone core samples were taken from the grafted sites for histologic and radiographic evaluation in 15 patients (19 samples). We also investigated whether or not the patients had underlying diseases, whether patients were smokers, graft sites, implant positions, and implant survival rates.

**Results:** Postoperative healing was uneventful in all cases. Radiographically, calcification and increased density were observed in the specimens. Histologically, newly formed bone was observed in the grafted sites, as well as, surrounding the Master Graft<sup>®</sup> granules. Osteoblastic and osteoclastic cells appeared in all specimens. All sockets grafted were able to support dental implants, while short-term osseointegration was predictable and successful. The survival rate of implants was 99.0% (105/106).

**Conclusion:** The findings of the present study suggest the efficacy of using Master Graft<sup>®</sup> granules for the alveolar socket augmentation procedure. The augmentation was able to maintain alveolar ridge contours and volume to provide sufficient support for dental implants. Acceptable results were obtained with implant survival rate and bone formation using Master Graft<sup>®</sup> granules.

## Comparative investigation of various implant surfaces by SEM-analysis

**Presenter: Duddeck D**

*University of Cologne, Cologne, Germany*

**Co-authors:** Duddeck DU, Neugebauer J, Scheer M, Möller F, Herrera HM, Zoeller JE

*University of Cologne, Cologne, Germany*

**Background and aim:** The surface of dental implants determines the initial phases of the biological response to the implant and affects its ability to integrate into the surrounding tissue. Surface modifications were realized through additive or subtractive treatment of the titanium-implants and sandblasting and etching procedures in combination or as a single treatment established as a state of the art manufacturing process. The aim of this poster is to present topographic effects of the different manufacturing processes on sterile packed dental titanium implants.

**Materials and methods:** Twenty-three different dental implants with machined, sandblasted, acid-etched and sandblasted-acid-etched surfaces have been investigated. The purpose of the present study was to analyze implant surfaces by means of scanning electron microscopy (SEM), backscattered electron imaging (BSI) and Energy Dispersive X-ray (EDX) Analysis.

**Results:** Aside impure machined threads (two implants) and superficial titanium chips (one implant) 18 implants showed organic (carbonic) contaminations as single spots (smallest diameter 20 µm, largest diameter 70 µm) or as a systematic contamination specially on the outer edges of the threads (four implants), that may have their origin in the manufacturing-process and/or in the specific handling-process from the titanium blank to the sterile packed implant. Inorganic residues were found like aluminum, silicon, phosphor, sulfur and chlorine. EDX Analysis and BSI demonstrated especially that particles of aluminum oxide remained after the manufacturing-process of sandblasted implants across the titanium surface. Residues of phosphor were found on the two anodically oxidized implants in the study. Different concentration of oxygen were found in the surface of all examined implants (lowest 9 at%, highest 60 at%). This suggests that the thickness of the titanium-oxide layer varies between implants.

**Conclusion:** Depending on the manufacturing process the examined implants showed a wide variety of embedded particles, organic and inorganic residues. But there is no evidence, that surface contamination could have an effect on Osseointegration of titanium dental implants.

## The conical bridge (modified telescopic system): a 'new' dual concept in the rehabilitation of the (atrophied) edentulous jaw

**Presenter: Bettens R**

*H.-Hartziekenhuis Roeselare-Menen, Roeselare, Belgium*

**Co-authors:** Rolf B<sup>1</sup>, Antoine vW<sup>2</sup>, Gerland V<sup>3</sup>, Kris DV<sup>3</sup>, Filip B<sup>4</sup>

*<sup>1</sup>Plastic and Maxillofacial Surgery, H.-Hartziekenhuis Roeselare-Menen, Roeselare, Belgium, <sup>2</sup>Tandprothetische Praktijk van Werkhoven bv, Oisterwijk, The Netherlands, <sup>3</sup>Dental Labo Vanderbeken, Oostende, Belgium, <sup>4</sup>Dental Clinic Bogaert, Aalter, Belgium*

**Background and aim:** The choice between a fixed or a removable implant born prosthesis is of utmost importance and should conventionally be made before the actual treatment is started. In this early stage it is often difficult to foresee the possible drawbacks (on speech, oral hygiene and esthetics) of a fixed construction, especially in the atrophied edentulous jaw. Ideally the choice between fixed or removable should be reversible at any time during and after the treatment phase without excessive costs. The Conical Bridge which is typically designed as a removable telescopic bridge, can be easily adapted to become a screw retained fixed bridge, thanks to the specific (patented) conical abutments, which are manufactured completely by CAD-CAM-technique.

**Materials and methods:** More than 30 fully edentulous jaws were rehabilitated with the Conical Bridge during an 18-month period. In the upper jaw four or six implants and in the lower jaw four or four implants were used. Several implant systems were utilized (Straumann<sup>R</sup>, Replace<sup>R</sup>, Ankylos<sup>R</sup>, Camlog<sup>R</sup>).

**Results:** No implants were lost. Initially some adjustments to the design were made in order to overcome issues with retention and phonetics. All patients were fully satisfied with the outcome of their prosthetic therapy. With only minor adjustments the Conical Bridge could be used both as a fixed or as a removable bridge.

**Conclusion:** We present the 'Conical Bridge' a modification of the well-tried telescopic bridge concept, which offers the additional option to permanently choose between a fixed or removable full arch rehabilitation.

## The effect of surface modification on early bone healing around plateau root form implants: an experimental study in rabbits

**Presenter: Coelho P**

*NYU, New York, USA*

**Co-authors:** Marin C<sup>2</sup>, Rodrigo G<sup>2</sup>, Marcelo S<sup>3</sup>, Jose G<sup>2</sup>, Paulo C<sup>1</sup>

*<sup>1</sup>New York University, New York, NY, USA, <sup>2</sup>Universidade Federal de Santa Catarina, Florianopolis, Brazil, <sup>3</sup>Tufts University, Boston, MA, USA*

**Background and aim:** The objective of this study was to evaluate the biomechanical fixation and bone-to-implant contact (BIC) of plateau root form implants of varied surfaces.

**Materials and methods:** Plateau root form implants with 3.5 mm in diameter by 8 mm in length presenting four surfaces

( $n = 16$  each) -machined (M), alumina-blasted/acid-etched (AB/AE), alumina-blasted/acid-etched + nanothickness bioceramic coating (Nano), and plasma sprayed calcium-phosphate (PSCaP) were bilaterally placed at the distal femur of 16 New Zealand rabbits, remaining for 2 and 4 weeks *in vivo*. After sacrifice, the implants were subjected to torque to interface fracture and were subsequently nondecalcified processed to  $\sim 30\mu\text{m}$  thickness slides for histomorphology and bone-to-implant contact determination. Statistical analysis was performed by ANOVA at 95% level of significance considering implantation time and implant surface as independent variables and torque to interface fracture and BIC as dependent variables.

**Results:** Torque to interface fracture was significantly affected by implant surface ( $P < 0.001$ ) whereas it was not affected by implantation time ( $P > 0.20$ ). Implantation time and implant surface had significant effects on BIC at  $P < 0.04$  and  $P < 0.001$ , respectively. The highest torque to interface fracture and BIC was observed for the PSCaP.

**Conclusion:** Implant surface significantly influenced early bone healing around plateau root form implants.

#### 409 Poster – Topic Material Research

Evaluation of AS-machined, GRIT-Blasted/acid-etched, nanothickness bioceramic coated, and plasma spray of calcium-phosphate surfaces on plateau root form implants: an experimental study in dogs

**Presenter:** Marcelo S

Tufts University, Boston, USA

**Co-authors:** Granato R<sup>2</sup>, Marin C<sup>2</sup>, Marcelo S<sup>3</sup>, Jose G<sup>2</sup>, Paulo C<sup>1</sup>

<sup>1</sup>New York University, New York, NY, USA, <sup>2</sup>Universidade Federal de Santa Catarina, Florianopolis, Brazil, <sup>3</sup>Tufts University, Boston, MA, USA

**Background and aim:** The objective of this study was to evaluate the early bone response (biomechanical fixation and bone-to-implant contact (BIC) to plateau root form with four different surface treatments.

**Materials and methods:** Plateau root form implants with 3 mm in diameter by 8 mm in length presenting four surfaces ( $n = 12$  each) -machined (M), alumina-blasted/acid-etched (AB/AE), alumina-blasted/acid-etched + nanothickness bioceramic coating (Nano), and plasma sprayed calcium-phosphate (PSCaP) were placed at the radius diaphyses of beagle dogs remaining *in vivo* for 3 and 5 weeks. After sacrifice, the implants were subjected to torque to interface fracture and were subsequently nondecalcified processed to  $\sim 30\mu\text{m}$  thickness slides for histomorphology and bone-to-implant contact (BIC) determination. Statistical analysis was performed by ANOVA at 95% level of significance considering implantation time and implant surface as independent variables and torque to interface fracture and BIC as dependent variables.

**Results:** Torque to interface fracture was significantly affected by implant surface ( $P < 0.001$ ) whereas it was not affected by implantation time ( $P > 0.55$ ). Implantation time and implant surface had significant effects on BIC at  $P < 0.001$  and  $P < 0.01$ ,

respectively. The highest torque to interface fracture and BIC was observed for the PSCaP, followed Nano, AB/AE, and M groups.

**Conclusion:** The PSCaP surface treatment positively influenced the early bone healing around plateau root form implants.

#### 410 Poster – Topic Material Research

The effect of implant surface and macrodesign on initial stability. a study in dogs

**Presenter:** Marin C

Universidade Federal de Santa Catarina, Lages, Brazil

**Co-authors:** Marin C<sup>2</sup>, Granato R<sup>2</sup>, Suzuki M<sup>3</sup>, Gil JN<sup>2</sup>, Coelho P<sup>1</sup>

<sup>1</sup>New York University, New York, NY, USA, <sup>2</sup>Universidade Federal de Santa Catarina, Florianopolis, Brazil, <sup>3</sup>Tufts University, Boston, MA, USA

**Background and aim:** The initial stability of dental implants is often times used as a predicament of its possible successful outcome. The purpose of this study was to evaluate the effect of different surface treatments and implant macrodesigns on implant initial stability and bone morphology in a beagle model.

**Materials and methods:** The third and fourth mandibular premolars of adult beagle dogs ( $\sim 1.5$  years of age) were extracted and the sites allowed to heal for 8 weeks. Subsequently, different combinations of macrodesign and implant surface treatment in screw root form implant designs (3I-Nanotite, Astra Tech-Osseospeed, Intra-Lock-Osseo) with similar diameter and length were placed following the suggested manufacturer's surgical protocol. The implants remained for 1 and 3 weeks *in vivo* ( $n = 6$  per system and implantation time). Following euthanization, the mandibles were retrieved and the implants were torque tested to interface failure with custom tooling adapted in an automated machine. Statistical analysis was performed by one-way ANOVA at 95% level of significance and Tukey's *post hoc* test for multiple comparisons. Histomorphologic evaluation was performed under an optical microscope at various magnifications.

**Results:** Significant differences were noted between groups following biomechanical testing ( $P < 0.001$ ; mean  $\pm$  95%CI in Ncm; 1 week – 3I Nanotite =  $19.43 \pm 8.39$ , Astra Osseospeed =  $23.48 \pm 8.39$ , Intra-Lock Osseo =  $107.6 \pm 8.39$ ; 3 weeks – 3I Nanotite =  $25.17 \pm 10.27$ , Astra Osseospeed =  $76.2 \pm 10.28$ , Intra-Lock Osseo =  $94.82 \pm 10.27$ ). Histomorphologic evaluation showed woven bone formation as early as 1 week for all implant systems. At 3 weeks, higher degrees of bone microstructural organization were observed.

**Conclusion:** The combination of macrodesign and surface treatment affected the initial stability of the implants.

The effect bone width and probe orientation on initial stability of different implant systems: a resonance frequency analysis study

**Presenter:** Tozum TF

*Hacettepe University, Faculty of Dentistry, Ankara, Turkey*

**Co-authors:** Tozum TF<sup>1</sup>, Bal BT<sup>2</sup>, Turkyilmaz I<sup>3</sup>

<sup>1</sup>Department of Periodontology, Hacettepe University, Ankara, Turkey,

<sup>2</sup>Department of Prosthodontics, Gazi University, Ankara, Turkey,

<sup>3</sup>Division of Implant Prosthodontics, The University of Texas Health Science Center, San Antonio/Texas, USA

**Background and aim:** Resonance frequency (RF) analysis is a sensitive, objective and non-invasive technique developed for dental implantology, where it measures the stability of the implant in the bone socket. Although many factors seem to have an impact on the RF values [implant stability quotient (ISQ)] of dental implants, there is a lack of evidence about some other parameters, which may have an influence on implant stability. The aim of the study was to determine whether initial stability of a dental implant differs when the bucco-lingual width of the bone changes, to determine whether different orientations affect the RF measurements in the RF device, and to investigate two dental implants with different morphologies with regards to their initial stability.

**Materials and methods:** Two endosseous implant systems (First system: more aggressive thread design and less number of threads, and second system: less number of threads) with diameters of 3.75 and 4.2 mm and with a length of 13 mm were used. Following the insertion of implants, bucco-lingual thinning of the models was performed in 2 mm increments ranging between 0 and 8 mm.

**Results:** A statistically significant decrease for ISQ values was noticed for both diameters and both systems for the all dimensional time-points of the blocks ( $P < 0.05$ ). Second system (more number of threads) resulted with higher ISQ values for both diameters compared with the first system (lower number of threads) ( $P < 0.001$ ).

**Conclusion:** The orientation of the probe influenced the measurements, where a standard orientation is advisable for the magnetic RF device. Different implant surface geometries seem to behave in a different pattern in terms of initial stability. Dimensional changes in bucco-lingual direction seems to have an impact on the initial stability, where wider implants also presented higher ISQ values compared with narrow ones.

Retaining screw: the effect design and surface characteristics have on pre load, how to achieve better pre-load and a protocol for maintaining it

**Presenter:** Coombes H

*Southern Implants, Centurion, South Africa*

**Co-authors:** Cumming L

*Southern Implants, Irene, South Africa*

**Background and aim:** Retaining screw pre-load is a factor directly influencing the success of implant integration. The pre-load determines the ability of the connection between the implant and abutment to withstand angulated forces and prevent the joint from opening. Compromised joints can result in screws breaking, restoration fracture and loss of osseointegration. These undesirable outcomes are costly and time consuming to rectify. The aim of this study is to quantify the effect that material properties, coatings and screw designs have on screw pre-load. A protocol is also to be drawn up based on these results to best maintain pre-load.

**Materials and methods:** A commercially available titanium grade 5 (Ti-6Al-4V alloy) screw was used as a benchmark for this study. Varying torques were applied to screws and the pre-load was measured by means of a strain gauge. The following materials were tested: titanium grade 5, gold and various coating on titanium screws. An innovative method for increasing the preload on a titanium screw was tested as an alternative to a more expensive gold screw.

**Results:** Overall, gold screws achieve 183% more pre-load than titanium screws. The effect of different coatings vary between 89% and 122% compared with the titanium grade 5 benchmark. A screw tightening protocol was developed in order to maintain optimum pre-load.

**Conclusion:** The gold screws are far superior in achieving pre-load, however, without a maintenance protocol gold screws tend to lose pre-load. Using the protocol suggested can aid practitioners in taking full advantage of the material properties of screws.

Does surgical experience influence primary implant stability?

**Presenter:** Papadimitriou D

*Eastman Dental Center, Rochester, NY, USA*

**Co-authors:** Romanos G<sup>1</sup>, Papadimitriou D<sup>1</sup>, Schmidt E<sup>1</sup>, Begic-Romanos E<sup>2</sup>, Feng C<sup>3</sup>, Caton J<sup>1</sup>

<sup>1</sup>Eastman Dental Center, Division of Periodontology, Rochester, NY,

USA, <sup>2</sup>Eastman Dental Center, Division of General Dentistry,

Rochester, NY, USA, <sup>3</sup>Department of Biostatistics, University of Rochester, Rochester, NY, USA

**Background and aim:** A primary prerequisite for implant integration is initial implant stability in order to control micro-movements at the interface. The purpose of this experiment was to evaluate the primary stability (PS) of implants placed



by clinicians with different experience levels in an in vitro model.

**Materials and methods:** One hundred and fifty implants (Straumann standard wide neck; 10 mm length and  $\varnothing$  4.8 mm) were placed by three clinicians (50 each) with different clinical experience in implant surgery, such as: Group 1: an expert, Group 2: a resident in implant surgery and Group 3: a general dentist without surgical experience at all. The implants were placed in fresh bovine ribs. Measurements of PS were performed electromechanically using Periotest® (PV) and resonance frequency analysis (RFA) using the Hostel® device (ISQ values) by an independent masked examiner. One-way analysis of variance (ANOVA) with Tukey's *post hoc* multiple comparisons was utilized to compare the implant stability among the three groups of clinicians.

**Results:** All implants were mechanically stable. The mean PV for Group 1 was  $-1.7 (\pm 3.87)$ , for Group 2  $-0.94 (\pm 2.83)$  and for Group 3,  $1.52 (\pm 3.76)$ . The mean ISQ values were  $75.44 (\pm 8.04)$ ,  $78.02 (\pm 7.41)$  and  $72.58 (\pm 9.72)$ , respectively. The ANOVA shows significant difference among three clinicians in PV ( $P$ -value  $< 0.0001$ ) and ISQ ( $P$ -value  $= 0.006$ ). Specifically, the Tukey's (multiple comparison) test showed significant differences in PV between the general dentist vs. expert vs. the resident. There was difference in RFA between the general dentist vs. the resident.

**Conclusion:** Within the limitations of this study, significant differences in implant PS were found for clinicians with different surgical experience.

414	Poster – Topic Material Research
-----	----------------------------------

## Evaluation of the cytotoxicity of permanent and provisional prosthetic materials

**Presenter:** Sabaliauskas V

*Vilnius University, Vilnius, Lithuania*

**Co-authors:** Sabaliauskas V<sup>1</sup>, Rutkunas V<sup>1</sup>, Juciute R<sup>1</sup>, Bukelskiene V<sup>2</sup>

<sup>1</sup>*Division of Prosthodontics, Vilnius University, Vilnius, Lithuania,*

<sup>2</sup>*Institute of Biochemistry, Vilnius, Lithuania*

**Background and aim:** In order to achieve good integration implant abutment (prosthetic) materials have to be highly biocompatible with soft tissues. The aim of the study was to evaluate the cytotoxicity of permanent and provisional prosthetic materials using in vitro model.

**Materials and methods:** Human gingival tissues were collected (with informed consent) from patients undergoing periodontal surgical procedures and fibroblasts were cultured *in vitro*. Cell type was determined by performing proteomic analysis. Selected prosthetic materials including titanium, zirconium, feldspathic ceramic, pressable leucite-based ceramic material, methyl-methacrylate, bis-acryl composite, gold and chrome-cobalt alloy specimens ( $5 \times 2$  mm) were fabricated. The toxicity of prepared specimens was tested by exposing them to cell culture medium up to 5 days at 37°C under sterile conditions. Cell viability was estimated using MTT [3-[4,5-dimethylthiazol-2-yl]-2,5-diphe-

nyltetrazolium bromide) assay. The data concerning cell viability were statistically analyzed using one-way ANOVA test and Tukey's multiple comparison test.

**Results:** Results obtained after 48 h showed no toxic effect of titanium, polished zirconium and roughened zirconium compared with control group. Cytotoxic effect was observed in gold, chrome-cobalt alloys as well as in ceramic and provisional prosthetic materials. Chrome-cobalt alloy and methacrylates based material significantly reduced cell viability compared with control group ( $P \leq 0.001$ ). After 120 h of incubation the tested materials caused an increase in cellular activity except methacrylate-based material which resulted in significant decrease.

**Conclusion:** Titanium, zirconium proved to be non-toxic. Gold alloy and ceramics had low impact on reduction of cell viability. Methacrylate-based material had highest cytotoxic effect on fibroblast cells.

415	Poster – Topic Material Research
-----	----------------------------------

## Flow properties of elastomeric impression materials for implant prosthesis

**Presenter:** Aladag A

*Ege University School of Dentistry, Izmir, Turkey*

**Co-authors:** Aladag A, Comlekoglu E, Gungor MA, Sagirkaya E, Artunc C

*Department of Prosthodontics, School of Dentistry, Ege University, Izmir, Turkey*

**Background and aim:** Elastomeric impression materials have become routine for implant denture impressions. To get reliable and precise impressions, these materials require special rheological and flow properties in order to ensure optimal wetting. The flow properties of six materials were evaluated using a shark fin test device.

**Materials and methods:** Six impression materials, three additional type (Elite HD – Zhermack, Detaseal – Detax, SiliconA – Cavex) and three condensation type (Exasoft – Detax, StabiSil – Cavex, Speedex – Coltene Whaledent) polyvinylsiloxane were included in the study. The flow properties for each impression material were determined immediately after completion of mixing time by measuring the ability flow up a tapered slit to form a 'shark fin'. Ten replicas were obtained for each material. Digital photographs of the samples were taken (Nikon Coolpix P80, Tokyo, Japan) and height and area of the shark fin test samples were measured with an image processing software (Lucia, Nikon Corporation, Tokyo, Japan). The means of each group were analysed by one-way analysis of variance. Welch test was used to determine the significant differences ( $P = 0.05$ ). For *post hoc* multiple comparison of groups, Dunnett's T3 test for groups with unequal variance was used.

**Results:** The height and area values (mean  $\pm$  SD) of the samples were given in table. Elite HD exhibited the highest height and area values while, Silicon A, Detaseal-Lite and Speedex showed the lowest.

	Elite-HD	Exasoft	Cavex StabiSil C	Cavex Silicon A	Detaseal-Lite	Speedex
Height (mm)	25,1 ± 2,5 <sup>a</sup>	16,8 ± 2,4 <sup>b</sup>	14,1 ± 1,5 <sup>b,c</sup>	12,7 ± 1,4 <sup>c,d</sup>	12,0 ± 1,0 <sup>d</sup>	12,9 ± 1,6 <sup>c,d</sup>
Area (mm <sup>2</sup> )	282,8 ± 15,2 <sup>a</sup>	175,5 ± 18,5 <sup>b</sup>	155,8 ± 13,0 <sup>b,c</sup>	142,1 ± 18,8 <sup>c,d</sup>	138,1 ± 10,0 <sup>d</sup>	133,6 ± 24,1 <sup>d</sup>

**Conclusion:** Additional type elastomeric impression material, Elite HD, showed superior flow properties supporting a high clinical reliability.

416 Poster – Topic Material Research

Bilateral sinus elevation using PRGF technology: a report of two cases

**Presenter:** Orive G

*Private Clinic, Vitoria, Spain*

**Co-authors:** Gorka O, Eduardo A

*Private Clinic, Vitoria, Spain*

**Background and aim:** The aim of this study was to evaluate the potential effects of plasma rich in growth factors (PRGF) technology and its autologous formulations in two consecutive patients in which bilateral sinus lift augmentation was carried out.

**Materials and methods:** Two consecutive patients received bilateral sinus floor augmentation. Both patients presented a residual bone height of class D (1–3 mm). The effects of PRGF combined with bovine anorganic bone (one side) were compared with the biomaterial alone (contralateral side). Furthermore, the effects of using liquid PRGF to maintain the bone window and autologous fibrin membrane to seal the defect were evaluated. A complete histological and histomorphometrical analysis was performed 5 months after surgery and the level of vascularization in the new forming bone was determined.

**Results:** PRGF technology facilitated the surgical approach of sinus floor elevation. The control area was clearly more inflamed than the area treated with PRGF technology. Patients referred also to an increased sensation of pain in the control area. PRGF treated samples had more new vital bone than controls. In patient #1, image processing revealed 21.4% new vital bone in the PRGF area versus 8.4% in the control area whereas in patient #2, 28.4% new vital bone was quantified in the PRGF area compared with the 8.2% of the control side. The immunohistochemical processing of the biopsies revealed that the number of blood vessels per mm<sup>2</sup> of connective tissue was 116 vessels in the PRGF sample vs. 7 in the control biopsy.

**Conclusion:** These preliminary results suggest that from a practical point of view and in the short-term evaluation, PRGF may present a role in reducing tissue inflammation after surgery, increasing new bone formation and promoting the vascularization of bone tissue.

417 Poster – Topic Material Research

Cell behavior on different rough surfaces of titanium by wire-type electrical discharge machining

**Presenter:** Otsuka F

*Showa University, Tokyo, Japan*

**Co-authors:** Otsuka F, Kataoka Y, LEE WS, Sugiyama K, Miyazaki T

*Department of Oral Biomaterials and Technology, Showa University School of Dentistry, Tokyo, Japan*

**Background and aim:** We have showed to improve dental implant surface by wire-type electric discharge machining (W-EDM). W-EDM made rough surface with irregular morphology and thick oxide layer on titanium surface. This surface modification by W-EDM was effective for the cell behavior of osteoblastic cell (MC3T3-E1). We previously reported that adsorption of serum proteins was enhanced by the TiO suboxide layer of through inorganic adsorption to the surface and initial cell adhesion, differentiation increased on W-EDM specimen through adsorbed serum proteins to the surface. The purpose of this study was to research cellular response on two kinds of titanium with different roughness surface modified by W-EDM.

**Materials and methods:** Polished titanium plates were prepared as a control and two different roughness surface titanium plate (each 10 × 10 × 1 mm) made by W-EDM. The roughness parameter ( $R_a$ ) of these specimen modified by W-EDM were  $R_a$  2.0 and 4.0 μm, respectively. The surface of each specimen was analyzed by scanning electron microscopy (SEM), X-ray diffraction spectroscopy (XRD). MC3T3-E1 cells were incubated in α-MEM, containing 10% fetal bovine serum (FBS) and 1% penicillin/streptomycin. Each specimen was washed by ultrasonic washing machine using ethanol and acetone. Cells were placed at the density of 5000 cells/cm<sup>3</sup> for all sample. Cell morphology on the sample was observed by SEM and fluorescent dyeing after cell was fixed. The number of cells was counted on a day, and 3 days and 7 days later. Similarly expression of gene (integrin αV, alkaline phosphatase, and GAPDH) was examined by PCR.

**Results:** An uneven rough surface was observed by the modified titanium surface. As a result of the observation of the cell morphology, modified titanium surface was observed progress of the stress-fiber than control. The number of cells on modification surface by W-EDM was increased compared with polished titanium.

**Conclusion:**

## Changes in electric potential of titanium implants due to temperature variations

**Presenter:** Sanchez Perez A

*Universidad de Murcia, Murcia, Spain*

**Co-authors:** Arturo SP, Alfonso JG, Maria Jose MV, Carmen JP

*Universidad de Murcia Murcia Spain*

**Background and aim:** Nowadays the use of titanium implants is commonly accepted to restore lost teeth. The intraoral temperature can vary from patient to patient due to a lot of factors. As electric potential depends of local environment, these temperatures variations can modify the potential of implants. The aim of our study is measure the electric potential of titanium implants at three different temperatures.

**Materials and methods:** The sample of 20 dental implants (Microdent System) was measured in artificial saliva (pH 6–7) at three different temperatures:  $34^{\circ}\text{C} + 0.5^{\circ}\text{C}$ ,  $37^{\circ}\text{C} + 0.5^{\circ}\text{C}$  and  $40^{\circ}\text{C} + 0.5^{\circ}\text{C}$ .

The measurement device is composed by one electronic redox-potential meter, one periodontal probe as counter electrode and one referential electrode (Ag/AgCl, KCL). The electric potentials were measured on implants with 12 mm length and 3.75 diameter ( $N = 20$ ).

**Results:** The average potential found were: 228 mV at  $34^{\circ}\text{C} + 0.5^{\circ}\text{C}$ , 258 mV at  $37^{\circ}\text{C} + 0.5^{\circ}\text{C}$  and 278 mV at  $40^{\circ}\text{C} + 0.5^{\circ}\text{C}$ . This three averages are significant different ( $P < 0.05$ ) (one-way ANOVA). This result shows that temperature variations of three degree can bring about significant differences in the electric potential of titanium dental implants.

**Conclusion:** Small temperature variations can bring about significant differences in the electric potential of titanium dental implants.

## Correlating implant stability to bone structure

**Presenter:** Rozé J

*Inserm U791, Nantes, France*

**Co-authors:** Rozé J<sup>1</sup>, Babu S<sup>1</sup>, Saffarzadeh A<sup>2</sup>, Gayet M<sup>3</sup>, Hoornaert A<sup>2</sup>, Layrolle P<sup>1</sup>

<sup>1</sup>INSERM U791, Laboratory for Osteoarticular and Dental Tissue Engineering, Faculty of Dentistry, Nantes, France, <sup>2</sup>ERT2004, Clinic research in odontology, Faculty of Dentistry, Nantes, France, <sup>3</sup>CHU, Radiology and Medical Imaging Department, Nantes, France

**Background and aim:** The aim of the study was to demonstrate a possible correlation between bone microarchitecture and primary implant stability.

**Materials and methods:** Twenty-two implants (Ankylos and Star-umann) were inserted into the maxillae and mandibles of human cadavers. Bone structure was determined by computed tomography in three specimens (male, age 53; females, 67; females, 80). A strict clinical protocol was used for implantation. Primary implant stability was measured by resonance frequency analysis (Osstell Mentor). The bone structure was analyzed by micro-

computed tomography. Bone histomorphometrical parameters were calculated and correlated to primary implant stability.

**Results:** Implant stability quotients (ISQ) ranged from 50% to 70% depending on specimens and sites. Histomorphometry indicated differences in the bone microstructures of the specimens. However, ISQ values were not related to trabecular bone histomorphometrical parameters. The sole correlation was found between ISQ values and cortical bone thickness.

**Conclusion:** This study confirms the relevance for primary stability of cortical thickness around implants. The thickness of cortical bone can be assessed using a standard clinical CT.

## Dental implant design and size refinements

**Presenter:** Emanuelli S

*University of Genova, Sanremo, Italy*

**Co-authors:** Musante B, Nario E, Currarino F, Blasi G, Emanuelli S

*University of Genova, Genova, Italy*

**Background and aim:** Clinical guidelines guide the clinicians in selecting implant design and size, our aim is to study anatomy and apply guidelines to anatomical sites in order to select the ideal implant design and size for each anatomical situation. Computer 3D reconstruction software as Procera may be used to measure anatomy to this task.

**Materials and methods:** Twenty-four dicom sets of edentulous patients have been uploaded on a Procera Nobelguide Software and 308 potential implant sites were measured. Ten measurements each site were recorded on a database:

HR (Height of Anatomical site),  
C<sub>t</sub>, M<sub>t</sub>, E<sub>t</sub> (coronal, medium, extreme thickness)  
C<sub>w</sub>, M<sub>w</sub>, E<sub>w</sub> (coronal, medium, extreme width)  
BD<sub>1</sub>, Bd<sub>2</sub> (Bone Density 1 and 2)

**Results:** Out of the 308 sites, 26 (8.4%) presented severe resorption, 66 (21%) medium resorption, 92 (29.9%) low resorption, 124 (40.3%) no resorption. Tables and Histograms are presented on the more meaningful data.

**Conclusion:** A methodology of measurement and characterization of a potential implant site is described, a database has been developed to store the data and a software to assist clinician and researcher to select, evaluate and possibly improve implant design and size.

## The use of collagen capsule for a sinus lift augmentation

**Presenter:** Cardoso R

*ACDC, Sao Paulo, Brazil*

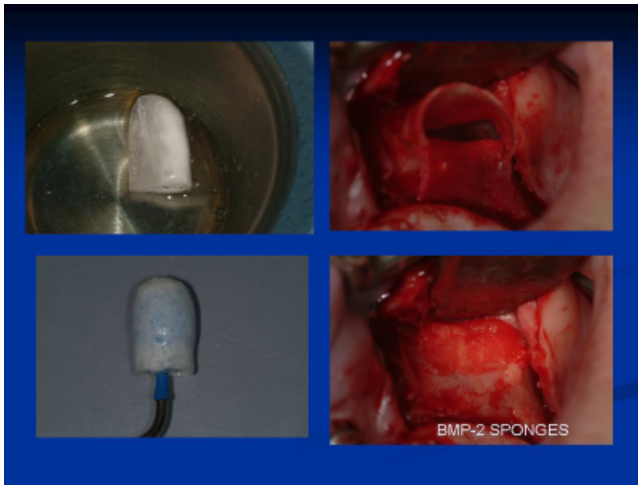
**Co-authors:** Cardoso R<sup>1</sup>, Malmquist J<sup>2</sup>

<sup>1</sup>ACDC Campinas, Brazil, <sup>2</sup>AAOMS, Portland, USA

**Background and aim:** The new Collagen Biomaterial is an off-white, biocompatible, cross-linked, resorbable membrane matrix engineered from highly purified type I collagen derived from bovine Achilles tendon. This study showed the efficacy of the application of the Collagen Biomaterial associated with

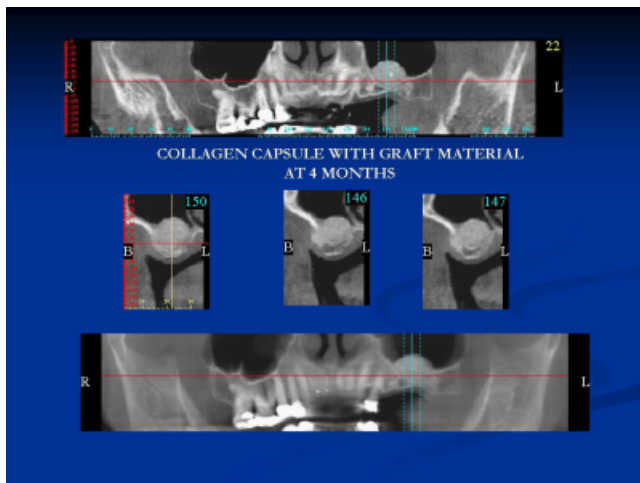
INFUSE, an osteoinductive form of BMP, in the sinus lift reconstructions for future rehabilitation with dental implants.

**Materials and methods:** Twenty patients were submitted to the surgery, using the mini balloon to make the sinus lift associate with collagen capsule biomaterial with graft material.



#### Results:

Clinical and radiographic control was done at the baseline and postoperative phase. The results showed the new bone formation in all cases, and the histology showed the resorption of the collagen over 45–60 days.



**Conclusion:** The use of this new Collagen Biomaterial associated with INFUSE demonstrated a predictable height in the majority of the cases and allowed for bone graft containment. This avoided the need for surgeries with onlay block graft.

Peri-implant soft tissue reactions around one and two-piece titanium implant implementation of an animal study

**Presenter:** Bolle C

LMI UMR CNRS 5615, Lyon, France

Co-authors: Bolle C<sup>1,2</sup>, Exbrayat P<sup>2</sup>, Malquarti G<sup>2</sup>, FAU D<sup>3</sup>, Grosgeat B<sup>1,2</sup>, Gritsch K<sup>4</sup>

<sup>1</sup>Laboratoire des Multimateriaux et Interfaces UMR-CNRS 5615, UFR D'Odontologie, Université Lyon 1, <sup>2</sup>Service de Consultations et de Traitements Dentaires, Hospices Civils de Lyon, Lyon, France, <sup>3</sup>UPSP 2007-03-135-RT12B, Equipe Réparation Tissulaire, Interactions Biologiques et Biomateriaux, Université Lyon 1, Lyon, France,

<sup>4</sup>Laboratoire des Multimateriaux et Interfaces, University of Lyon

**Background and aim:** The evolution of ethical and legislative aspects (Revision of the Medical Devices Directive 93/42/EEC) complicates the management of animal studies. The aim of this work was to bring to light the different steps needed to carry out a preclinical study through the elaboration of an experimental protocol.

**Materials and methods:** Key points for the submission of projects to an Ethical Committee are: the scientific interest, the choice of animal model, pain evaluation and management and the staff training in animal experiment. For example, to study at early stages of tissue healing the influence of implant design and type of connection on soft tissue reaction, the different elements to take in account are:

- choice of animal model,
- determination of the number of animals,
- conception of the experimental design

**Results:** The choice of animal model: the beagle dog is easy to manipulate and presents osseous characteristics close to those of humans.

The determination of the number of animals: according to data, four animals per group would be a number sufficient to obtain significant results

Conception of the experimental design

- Connection design

Type A: two-piece implant with internal conus connection

Type B: one-piece implant with innovative reverse external conus connection surgery: extraction of six mandibular premolars under anesthesia. After 10 weeks of healing, three implants of type A and B were bilaterally placed with a randomized protocol.

Postoperative following: daily veterinary surveillance and sessions of oral hygiene.

· Analysis of the results: using classical histological methods and histomorphometry. The protocol was validated by the Ethical committee of the Veterinary National School of Lyon, hence the study has started.

**Conclusion:** The implementation of animal studies needs for ethical and legislative reasons to follow a rigorous procedure. The choice of animal model, the number of animals and pain management are important elements to enable the validation of this experimental protocol.

## Chemical properties of a new laser titanium implant surface

**Presenter:** Duvina M

*University of Florence, Florence, Italy*

**Co-authors:** Duvina M<sup>1</sup>, Tonelli P<sup>1</sup>, Del Frate S<sup>2</sup>, Aleo E<sup>2</sup>, Viviani C<sup>1</sup>, Borgioli A<sup>1</sup>, Delle Rose G<sup>1</sup>, Amunni F<sup>1</sup>, Giannelli M<sup>1</sup>, Duvina G<sup>1</sup>

<sup>1</sup>*Department of Oral Surgery, University of Florence, Florence, Italy,*

<sup>2</sup>*Geass Research Center, Udine, Italy*

**Background and aim:** Titanium and its alloys have become key materials mainly owing to their compatibility with human tissues and their mechanical strength. Several studies suggest that the topography and composition of titanium surface play a key role with respect to the implant clinical outcome, demonstrating their effects on cell and tissue response. When in contact with the body liquids, the implant surface undergoes to a series of dynamic modifications owing to ionic, molecular and finally cellular interaction. This phenomenon influences plasmatic proteins adsorption and the consequent activation of bone regeneration mechanisms. The aims of this study are: (1) to confirm that the laser roughening treatment does not introduce any form of contamination and does not alter the chemical-physical characteristics of the titanium; (2) to investigate the human plasma protein adsorption profile in order to understand which is the host tissues reaction when in contact with the laser treated surface.

**Materials and methods:** The most prominent fabrication methods used previously to produce defined topographies imply the risk that residues deriving from roughening treatments remain on the surface or that dangerous corrosion reactions are provoked with the discharge of metal ions. The new dental implant surface treatment technology based on a Nd:YAG diode pumped laser (DPSS laser) in Q-Switching (Geass, SyntheGra<sup>®</sup>) have allowed to create for the first time a perfectly controlled topography lacking in polluting agents. Titanium samples (2.5 mm thick and 6 mm in diameter) were used for all the experiments and were treated with the DPSS Nd:YAG Q-switching laser in order to obtain different patterns. The chemical analysis was made exploiting the SEM-EDX (Scanning Electron Microscopy – Energy Dispersive X-ray Spectroscopy) and XPS (X-ray Photoelectron Spectroscopy) technologies. To study the human proteins adsorption biochemical and fluorescent assays were used.

**Results:** The results obtained confirm the absence of contaminant elements on the surface treated with this new laser technology. This property positively influences the human plasma proteins adsorption in a predictable and reproducible way.

**Conclusion:** The new Sinter<sup>®</sup> surface has unique topographic and chemical properties promoting osseointegration and healing mechanisms.

## Accuracy of five implant impression technique: effect of splinting materials and methods

**Presenter:** Lee SJ

*Private, Daegu, Korea*

**Co-authors:** Lee SJ<sup>1</sup>, Cho SB<sup>2</sup>

<sup>1</sup>*Private Practice, Daegu, Korea,* <sup>2</sup>*Army, Daejeon, Korea*

**Background and aim:** An accurate and passively fitting prostheses is suggested as one of the critical requirements for long term implant success. Since the uneven distribution of occlusal loads and torquing stresses on the various elements due to problems related to poor fit of frameworks connected to implant may lead to marginal bone loss and failure of implants as well as loosening of screws and fatigue fractures of implant components. Precise transfer of the spatial relationships of implants from the mouth to the master cast with an impression is the first and critical step to ensure passive fit of implant framework. The purpose of this study was to evaluate the accuracy of the master casts obtained from five different impression techniques using various splinting Materials and methods.

**Materials and methods:** A stainless steel metal model with six  $3.75 \times 10$  mm ad modum Branemark external hex implant was fabricated to simulate a clinical situation. This metal model was embedded in epoxy resin to serve as stop for impression tray. And implant level impressions were made after impression copings were splinted using five different techniques. (1) Squared impression copings splinted with autopolymerizing acrylic resin 1 day before impression procedure and then sectioned. Final connection was performed just before the impression procedure. (2) Squared impression copings splinted with autopolymerizing acrylic resin just before impression procedure. (3) Primary impression was made with impression plaster and then secondary impression was made with polyether impression material. (4) Squared impression copings splinted with impression plaster. (5) Squared impression copings splinted with VPS bite registration material.

**Results:** From master model, five impressions and experimental models were made for each of two splinting methods. Consequently, total 25 experimental models were obtained and all measurements were made using a STRATO Bright 710 CNC (computer numerical control) coordinate measurement machine, capable of recording in the x-, y-, z- axes. Group 1 showed higher accuracy of the duplicated casts followed by group 3 and 4. There was no significant difference between group 3 and 4. And group 2 and 5 showed relatively large distortion value than any other groups.

**Conclusion:** Among five splinting methods, we could fabricated statistically most accurate reproduction (mean distortion values  $< 20 \mu\text{m}$ ) with group 1. But clinically acceptable accuracy could obtained from the splinting methods using impression plaster.

## Retrieval analysis on biointegration phases

**Presenter: Ciocan LT**

*U.M.F. 'Carol Davila', Bucharest, Bucharest, Romania*

**Co-authors: Ciocan LT<sup>1</sup>, Miculescu F<sup>2</sup>, Miculescu M<sup>2</sup>, Patrascu I<sup>1</sup>**

<sup>1</sup>*U.M.F. "Carol Davila" Bucharest, Faculty of Dental Medicine, Prosthetic Technology and Dental Materials Department, Bucharest, Romania,* <sup>2</sup>*University Politehnica from Bucharest, Material Sciences and Engineering Faculty, Bucharest, Romania*

**Background and aim:** This study was developed for evaluating the possible causes of losing primary stability of dental implants and to find possible associations between implant design or implant surface treatment and the quality of surrounding bone tissue.

**Materials and methods:** There been evaluated five titanium dental implants with different shapes and surface morphology by ESEM. All the implants have been extracted between 3 and 6 month from insertion time due to the loosening of primary stability.

**Results:** The one piece blade shape dental implant with surface prepared by machining, have been inserted and maintained to

the posterior region of the mandible for 4 month. In the SEM micrographs it can be noticed a decreased mitotic activity to the tip of blade implant. It appears that failure in retention of this implant was only due to the compression and to the lack of irrigation of the cortical bone where it was inserted. The one piece screw shape dental implant, having trapezoidal threads with high and long step and machined prepared surface, has been inserted and maintained in the anterior side of maxillae alveolar bone for 3 month. The SEM macrographs indicate a large surface of the implant covered by bone tissue in intimate contact with implant threads and a new bone formatted and matured bone in intimate contact with the implant. This suggest a biomechanical failure for this implant (due to deficient load applied on it).

**Conclusion:** The lost during 3–6 month of the primary stability for the dental implants evaluated at the interface was attributed for blood supply deficiency of the surrounding bone in case of the implants inserted in the anterior–lateral and lateral mandible bone, over compression implant surrounding bone with consecutive necrosis without leaving the possibility of normal healing both for the maxilla and the mandible or because of prosthetic load deficiency by applying forces out of the implant axis.