



Transworld Research Network
37/661 (2), Fort P.O.
Trivandrum-695 023
Kerala, India

Recent Advances in Cervical Cancer, 2011: 45-54 ISBN: 978-81-7895-522-3
Editor: Iztok Takač

4. Screening programs of cervical cancer

Goran Grubišić

Colposcopy Department at Polyclinic „Eljuga“, Bukovačka 121, 10 000 Zagreb, Croatia

Introduction

Cervical cancer is the second most common female cancer worldwide with about 493.000 new cases per year, and it is the most common female cancer in Africa, Asia and South America (1). About 273.000 women die from cervical cancer each year, 85% of which take place in developing countries (1). There were 12.800 new cases and 4.600 fatal outcomes in the US during the year 2000. Mean age of cervical cancer patients is 51.4 years, with an almost equal distribution in age groups 30 to 39 years and 60 to 69 years (2). In Croatia in the age groups between 25-39 years and 50-64 years, a decreasing trend of cervical cancer incidence is observed. An increase of cervical cancer incidence over the last 20 years has been observed in the age groups 40-44 and 45-49 years (2). According to the 2003 yearbook, 313 new cases of invasive cancer (13.7/100 000) and 493 cases of CIS in Croatia were discovered (3). Although the cervical cancer mortality rate is on the decrease, 100 women still die every year (3, 4). Throughout Europe every year about 60.000 women develop invasive cervical cancer and 30.000 die from this disease. In the same time there are 225.000 women in Europe who live with cervical cancer either in the phase of treatment, or no. Differences between developed and non developed European countries in cervical cancer incidence vary from country to country, i.e. in some Eastern European countries this rate is 2-5 times higher than in first 15 European countries, members of EU. This difference in great majority depends on the presence or the lack of well established programmes of prevention (3). Cervical cancer has a slow progress, from pre-invasive intraepithelial neoplasia (CIN) to invasive phases, which means that the disease can be diagnosed while in the phase of pre-invasive lesion, which can be treated successfully thanks to the regular screening of asymptomatic women (the Pap smear) (2). In developed countries, most cases of cervical cancer are diagnosed among women without the regular Pap smear (2).

Correspondence/Reprint request: Prof. Goran Grubišić, Colposcopy Department at Polyclinic “Eljuga” Bukovačka 121, 10 000 Zagreb, Croatia. E-mail: dr.goran.grubisic@gmail.com

Unfortunately, in developing countries, the screening of asymptomatic women is often not available. In addition to this sad fact, attitudes towards this disease and the lack of public health education make the situation even worse. This is the population in which we can find patients with cervical cancer in advanced stages, when the disease has spread into the bladder, the rectum, the nerve pathways of the pelvis, or the bones (2).

Symptomatology

Patients with microinvasive cervical cancer

Patients with microinvasive cervical cancer up to stage IA2 have no symptoms. These diagnoses are detected either due to organised or opportunistic screenings (abnormal cytology, colposcopy, targeted biopsy, endocervical curettage, LETZ - Loop Excision of the Transformation Zone, cold knife conisation).

“Microinvasive“ carcinomas more than 7 mm in width and 5 mm in depth may be accompanied with slight spotting or contact bleeding. At naked eye examination (speculotomy) these changes resemble vulnerable ectropion.

Patients with invasive cervical cancer

In everyday clinical practice in urgent gynecologic unit one can face invasive cervical cancer patients as those with heavy vaginal bleeding, or with malodorous vaginal discharge with spotting associated with body mass loss as well as fatigue.

In order to prevent invasive cervical cancer development, it should be extremely important to detect those women having any of the above mentioned symptoms, to catch with to organized systematic gynecological screening, including thorough patient's data collection, gynecologic examination (speculotomy, bimanual vaginal palpation, rectal examination, if needed with short anaesthesiologic relaxation), then transvaginal ultrasound as well as MRI examination (5).

Patients with frankly invasive carcinoma of the uterine cervix (stage IB1 to II A) may develop various degrees of symptoms (abnormal vaginal bleeding, malodorous vaginal discharge with spotting associated with body mass loss as well as fatigue, undefined lower abdominal cramps).

Abnormal vaginal bleeding is the most common symptom of invasive cervical cancer. Among sexually active women, the symptoms include postcoital bleeding, although one must not dismiss both the intermenstrual and the postmenopausal bleedings (2).

In comparison with endometrial cancer, which is rather quickly manifested by bleeding, cervical cancer among women who are not sexually active is asymptomatic until it reaches an advanced stage.

The large tumor mass is often infected, so there is a stenchy vaginal discharge present, even prior to vaginal bleeding.

Pretorius and colleagues report that in advanced stages of the disease the first signs can be the following: pelvic pain, pressure (that is tenderness in rectal or bladder regions) and occasional discharge of urine or faeces through vagina (6). The report includes 81 patients with the diagnosis of cervical cancer: 56% of them had vaginal bleeding as the first symptom of the disease, 28% had an abnormal Pap smear, 9% suffered from pain, 4% had vaginal discharge, and 4% had no symptoms.

It should be mentioned that small tumors, that is the earlier stage of the disease, were found among patients with an abnormal Pap smear.

Diagnostic procedures

Making an early diagnosis of cervical cancer can present a challenge for the following reasons:

- it is frequently asymptomatic,
- if there is no possibility of a gynecological examination in speculas for distinguishing the source of the disease in the endocervical canal or under the ectocervical epithelium, i.e. that in case of bulky tumour of the endocervical site, it may resemble speculoscopically as well as colposcopically “hyperthrophic uterine portio” but main invasive process is situated deeply in endocervix with endophytic penetration. It is smartly advised in such patients to perform thorough palpation, when one can experience enlarged uterine cervix associated with painful vaginal, as well as with rectal examination. Examination under anaesthesia enables the best way to palpate parametria. MRI is complementary in these cases too. Be aware of possible haemorrhage from cervical erosion.
- because of a fairly high percentage of false-negative Pap smear results, even among regular patients.

Gynecologic examination in cervical cancer diagnosing

In speculas the primary lesion is seen as: exophytic (**Figure 1**), endophytic, ulcerative, or polipoid.

If the tumor is growing under the epithelium or in the endocervical canal, ectocervix can seem alright macroscopically.

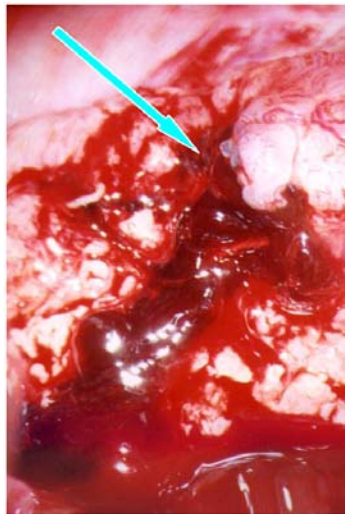


Figure 1. In this patient with frankly invasive cancer of the uterine cervix speculoscopy demonstrated primary exophytic lesion (arrow).

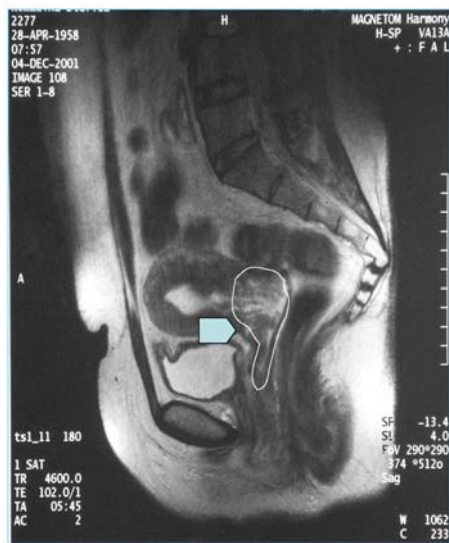

Figure 2. In this patient MRI demonstrated the extensity of the invasive uterine cancer. Observe the uterine cervix as well as posterior vaginal vault with neoplastic thin hypodensic zones (scribble lines and arrow).

The direct spread into the vagina is visible, but the infiltration can be subepithelial and possible only with obliterated vaginal vaults or the presence of cervical stenosis.

In later stages the visualisation of the cervix can be difficult. During manual palpation, the cervix feels indurated (except in pregnancy), and enlarged.

The size of the cervix can best be measured by rectal examination, which is necessary to estimate the spread of the disease on the parametrium, as well. MRI helps us to get more precise information on the spread (**Figure 2**) of the disease and thus the stage of the disease². Additional physical examination must include the palpation of the liver, of the supraclavicular and inguinal lymph nodes, in order to rule out metastatic disease².

Complementary contemporary radiology techniques in the assesment of cervical volume as well as the ultrasound diagnostics must be taken in mind (2).

Tissue sampling for patohistological verification is an inevitable part of diagnostic protocol.

Any tumor mass or ulceration calls for histological analysis, in this case for the so-called punch biopsy (excisio probatoria cervicis). Any unusually indurated or enlarged cervix needs to be analysed through biopsy and/or endocervical abrasion.

Cytological test in diagnosing cervical cancer

The sad fact, as we mentioned, is that those women with invasive cervical cancer involvement did not undergo regular cytologic examination. We must take in mind that during organised cytologic screening also those women with invasive cervical cancer can be detected (already anamnestically we can gain data of vaginal bleeding, discharge), speculscopy will show exulcerative tumor proces on the uterine cervix and vaginal vaults. From the other side cytologic detection of cells suspected on invasion lead us to perform target biopsy as well as diagnostic cold knife conisation.

Cytological diagnosis of conventional cervicovaginal smear or Pap test is one of the most efficient screening test known to date, which has been credited with the significant decline in the incidence and mortality of cervical carcinoma in the world (7). The measures of cervical cytology availability as a screening test are its sensitivity, specificity, predictive value and diagnostic accuracy. The sensitivity of cervical screening in Croatia is 90.0 %, specificity 98.6 %, positive predictive value 92.3 %, negative predictive value 98.1 % and overall diagnostic accuracy 97.2 % (7). The main objection to conventional cytology as a screening test refers to its low sensitivity, false positive and false negative results. In the last few decades new techniques of cervical cytology sampling and processing such as liquid-based cytology (LBC), have been developed. The advantages of LBC over conventional smear are a reduced rate of inadequate samples and false negative findings, a higher rate of abnormal cytology findings detected and significantly shorter time needed for analysis of a specimen prepared by LBC method⁸.

Human papillomavirus testing

In my opinion unnecessary in invasive cancer detection, but on the other side it is possible to find lymph node involvement with cancer tissue containing in situ hybridisation (ISH) signal of high risk HPV type 16 presence (**Figure 3**) as possible confirmation of HPV induced neoplastic process. Due to nonradioactive ISH there were identified HPV DNA types 6/11, 16/18 and 31/33/51 (Enzo Diagnostics Inc). Hybridisation signal of HPV DNA was detected exclusively in well differentiated areas of metaplastic and dysplastic epithelial lesions, as well as in single lymphogenic metastatic sites of the squamous uterine cervix cancer⁹.




Figure 3. “Pearl” of cancer - whiteish borders - double rectangular arrow. In situ hybridisation signal of HPV DNA detected in single lymphogenic metastatic site of the squamous cancer of the uterine cervix (arrow).

The role of colposcopy

Colposcopy is necessary if the gynecologist finds no unusual features of the cervix in the patient with symptoms or an abnormal Pap smear (**Figures 4, 5**).

On the other side if a firm diagnosis cannot be set after the biopsy, diagnostic cone biopsy is recommended (**Figure 6**). Colposcopic detection of microinvasive cancer depends on its size and location. The gynecologist can miss smaller lesions, although the

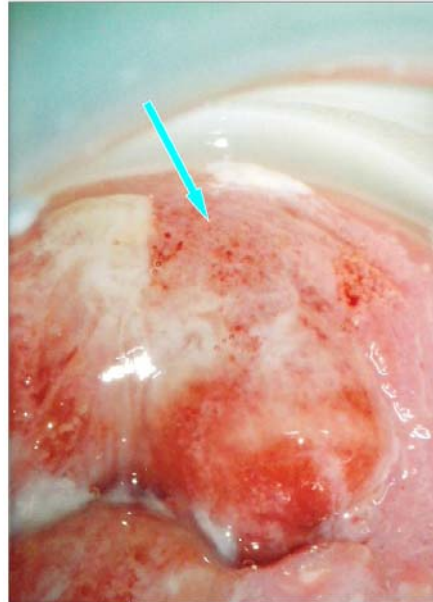

Figure 4. Anterior lip of the uterine cervix demonstrating coarse punctation as a sign of serious underlying lesion (microinvasive adenocarcinoma on punch biopsy, arrow).

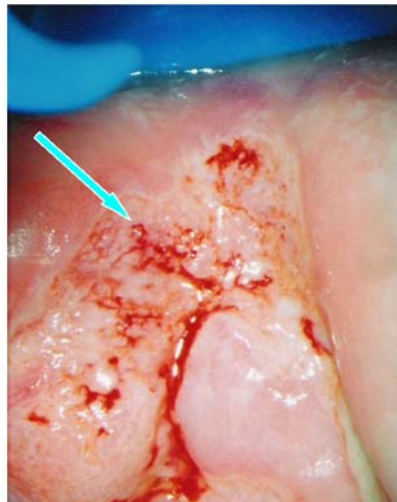

Figure 5. Speculoscopy demonstrates vulnerable and bloody surface confined on the uterine cervix, no larger than 2 cm in diameter, histopathology revealed carcinoma planocellulare invasivum cervicis uteri, FIGO stage: IB1 cervical cancer (arrow).

probability of stromal invasion increases with the level of lesion spread on the surface. If the microinvasive cancer is entirely within the endocervical canal, the ectocervix can seem alright during colposcopy. Signs of microcancers of the ectocervix are atypical blood vessels, prone to bleeding.

Colposcopy	Satisfactory finding	Unsatisfactory finding
Minor change	Control for 6 month HPV test Control colposcopy	Repeat PAP smear Due to new PAP follows further dg/th procedure
Major change	Biopsy + PHD	Biopsy + PHD
Invasive cancer suspected: Biopsy + PHD		

Figure 6. Our suggested protocol on the treatment of patients with the abnormal Pap smear depending on the colposcopic finding, taken from (10).

Both satisfactory or unsatisfactory colposcopic finding deal with thorough visibility of the uterine portio, SCJ- squamocolumnar junction and upper vaginal third.

Atypical blood vessels are located unusually and randomly, they differ in diameter, and often change direction, forming sharp angles.

Intercapillary distance is larger and changeable

The colposcopy enlarges the picture of the early invasive cancer and shows the surface and the atypical blood vessels. In these cases of IA1-IB1 thorough colposcopy may enable to find scribble shaped border between ill uterine cervix and rather health vaginal couple tissue. It is important in planning the size of upper third vaginal tissue involvement in radical hysterectomy removal, thus leaving middle and lower third of the vaginal tissue health and able to bring endovaginal irradiation source when needed. Schiller test can additionally enable to see the border allowing decision how great amount of upper vaginal third can be involved in radical hysterectomy dissection^{10,11,12}.

Endophytic tumors when enlarged, papillary surface and atypical blood vessels are visible.

Keratoses can mask the colposcopic finding of an underlying lesion, which is the reason why biopsy is necessary.

On the basis of our colposcopic experience uterine cervix adenocarcinoma has no distinctive features. We can spot all vascular changes that have been described so far.

Histology

In the presence of a satisfactory examination, colposcopically directed punch biopsy becomes the gold standard of diagnosis. All women with a smear showing high grade squamous intraepithelial lesion (HSIL) and more, should have material submitted for histology. In HSIL immature basal-type cells occupy more than the lower third of the epithelium. In addition there is nuclear crowding, pleomorphism and loss of the normal cell polarity¹³.

Management

Various stages of the disease can be diagnosed only through organized gynecologic screening, we used term systematic gynecologic examination. Only in these cases one can put appropriate gynecologic diagnosis of the invasive uterine cervix cancer disease.

From a clinician's point of view colposcopic suspicion of the early invasion differs from that made by naked eye examination (speculoscopy). We point out that differences in millimeters of disease on cervical "surface" mean worlds of diagnosis and treatment on which the therapeutic outcome in these patients depends.

The collaboration of the gynaecologist, the cytologist, and the pathologist implies that the current state of a patient needs to be discussed on several levels: the stage of the initial invasion, the sample on which the initial invasion was discovered, age and parity of the patient ¹⁴.

After we consider these levels, we can decide on further treatment of the patient ¹⁴.

The earlier the cervical cancer is diagnosed, the better the chances are of successful treatment.

Here are some basic issues in our everyday clinical, and gynecological and oncological practice. I will also take into consideration those patients in advanced stages of this horrible disease.

- A) The approach to the treatment of microinvasive planocellular cervical cancer IA1 diagnosed after LLETZ biopsy or classic test excision by forceps. What if the patient is a nulliparous, or if she had a baby once, or more times?
- B) The approach to the treatment of microinvasive planocellular cervical cancer IA2 diagnosed after LLETZ biopsy, or after classic test excision by forceps. What if the patient is a nulliparous, or if she had a baby once, or more times?
- C) The approach to the treatment of microinvasive planocellular cervical cancer IA1 diagnosed after LETZ biopsy or after classic cone biopsy by scalpel. What if the patient is a nulliparous, or if she had a baby once, or more times?
- D) The approach to the treatment of microinvasive planocellular cervical cancer IA2 diagnosed after LETZ cone biopsy, or after classic cone biopsy by scalpel. What if the patient is a nulliparous, or if she had a baby once, or more times?

What about the grey area? How to treat patients with stromal invasion of more than 5 mm, the spread larger than 7 mm, and the change still not visible to the naked eye?

Subdividing in colposcopically and in naked eye appearance of the invasive cervical cancer

Is subdividing necessary? From a clinician's point of view yes, it is, because we do not face stages of the disease, we face patients. Transition from one stage to another is slow and constant, so the above mentioned transition from IA2 to clearly visible stage IB1 has its own duration time.

What if the finding is an incidental finding at hysterectomy, or at a diagnostic cone biopsy, or at one of the mentioned excision of the cervical canal or probatory excisions?

All this needs thorough studying taking in mind FIGO classification which is today still one of the more acceptable for all those involved in cervical cancer diagnosis and treatment ^{15,16,17}.

As sole example we pointed these situations dealing with microinvasive carcinoma stagings (**Figures 7 and 8**). Collaboration of the gynecologist, the cytologist, and the pathologist implies that the current state of a patient needs to be discussed on several levels: the stage of the initial invasion, the sample on which the initial invasion was discovered, age and parity of the patient ¹⁴.

Margins clear, ECC negative, stage IA1 with no spread to lymphovascular area:

cone biopsy if the patient wants to preserve fertility

Margins and/or ECC positive dysplasia:

repeat cone biopsy

if conisation not appropriate, then perform hysterectomy +/- pelvic lymphadenectomy

modified radical hysterectomy

Stage IA1 with invasion into lymphovascular area

pelvic lymphadenectomy + conisation, or radical trachelectomy (for fertility reasons)

modified radical hysterectomy and pelvic lymphadenectomy

Figure 7. Algorithm in cases of microinvasion up to 5 mm or less, taken from (14).

Additionally it is necessary to point out that despite significant advances in imaging techniques, surgical staging is more accurate than clinical, nevertheless the FIGO Committee on Gynecologic Oncology decided that clinical staging should be continued¹⁷. Lymph nodal assessment is of poor prognostic factor regardless of the disease extent during staging, and is not necessary because surgical staging cannot be employed worldwide, especially in low-resource countries. The above two changes have been approved in the new staging system as follows: First, the subdivision of the tumor size (with a 4 cm cut-off in maximum diameter) has been applied for previous stage IIA, second the subdivision regarding the tumor size, and uni- or bilateral parametrial invasion has not been considered in previous stages IIB-IIIB, because of little available data and identity of treatment.

These new statements may alert gynecologic oncologists dealing with invasive cervical cancer problems. From one side we must take in mind new approaches, but from the other we must be aware in which conditions we diagnose and treat invasive uterine cervical cancer. All depend on socio-economic and professional achievements of a certain country. Taking in mind that any guideline is better than none, I would like to suggest the necessity of a thorough estimation of a clinician's/an institution's possibilities of diagnosis, consultation, treatment and follow up of these patients.

Conclusion

Cervical cancer screening is best accomplished due to organised programmes in community. The responsible body is the National Advisory Board of the Croatian Ministry of Health. Every patient detected having invasive cervical cancer undergoes widely accepted guidelines of diagnosis, treatment and follow up discussed on several levels: the stage of the initial invasion, the sample on which the initial invasion was discovered, age and parity of the patient etc. It is the only way to diminish this dangerous, but relatively well preventable disease.

References

1. Ferlay J, Bray F, Pisani P, Parkin DM. GLOBOCAN 2002: Cancer Incidence, mortality and Prevalence Worldwide, IARC Cancer Base No. 5. Version 2.0. (IARC Press, Lyon, 2004).
2. Hacker NF. Cervical cancer. In: Berek JS, Hacker NF. Practical gynecologic oncology. Lippincott, Williams & Wilkins, Philadelphia, 2000.

3. Znaor A, Strnad M. Cervical cancer in Croatia. *Coll Antropol* 2007; 31 (Suppl. 2): 37-40.
4. Croatian National Cancer Registry, Cancer Incidence in Croatia, Annual reports, Bulletin No 31. Croatian National Institute of Public Health, Zagreb, 2006.
5. Suren A, Osmers R, Kuhn W. 3D Color Power Angio TM imaging: a new method to assess intracervical vascularization in benign and pathological conditions. *Ultrasound Obstet Gynecol* 1998; 11: 133-7.
6. Pretorius R, Semrad N, Watring W, Fotheringham N. Presentation of cervical cancer. *Gynecol Oncol* 1991; 42: 48-52
7. Pajtler M, Audy-Jurković S, Kardum-Skelin I, Mahovlić V, Mozetić-Vrdoljak D, Ovanin-Rakić A. Organisation of cervical cytology screening in Croatia: Past, present and future. *Coll Antropol* 2007; 31 (Suppl. 2): 47-54.
8. Grubišić G, Pirkić A. Molecular pathology and immunohistochemistry of HPV induced lesions of the uterine cervix. Book of summaries of 3.rd Symposium Sexually Transmitted Diseases. Croatian Society of Infectologists of the Croatian Medical Association, Zagreb (Slavko Schoenwald ed) 2001: 16.
9. Grubišić G. Limitations of colposcopy in early invasive cervical cancer detection. *Coll Antropol* 2007; 31 (Suppl. 2): 135-8.
10. Grubišić G, Klarić P, Jakanović Lj, Soljačić-Vraneš H, Grbavac I, Bolanča I. Diagnostic approach for praecancerous and early invasive cancerous lesions of the uterine cervix. *Coll Antropol* 2009; 33: 1431-6.
11. Walker P, Dexeus S, De Palo G, †Barrasso R, Campion M, Girardi F, Jakob C, Roy M. International terminology of colposcopy: An updated report from the international federation for cervical pathology and colposcopy. *Obstet Gynecol* 2003; 101: 175-7.
12. Wright TC, Kurman RJ, Ferenczy A. Precancerous lesions of the cervix. In: Blaustein's textbook of pathology. Springer-Verlag, New York, 2002.
13. Bendet JL, Pecorelli S. Cancer of the cervix. *Internat J Gynecol Obstet* 2000; 70: 221-8.
14. Hacker NF. Cervical cancer - Algorithm for the management of patients with an abnormal Pap smear and inadequate colposcopy or microinvasive squamous cervical carcinoma on punch biopsy, In: Berek JS, Hacker NF (Eds). *Practical Gynecologic Oncology*, 3rd Edition. Lippincot Williams & Wilkins, Philadelphia, Baltimore, New York, 2000.
15. Pecorelli S, Zigliani L, Odicino F. Revised FIGO staging for carcinoma of the cervix. *Int J Gynaecol Obstet* 2009;105: 107-8.