

# Calcaneal Fracture – Standardized Protocol of Treatment

Nikica Daraboš<sup>1</sup>, Marijan Cesarec<sup>2</sup>, Denis Grgurović<sup>2</sup>, Anela Daraboš<sup>3</sup>, Esmat Elabjer<sup>1</sup> and Gojko Buljat<sup>1</sup>

<sup>1</sup> University Clinic of Traumatology, University of Zagreb, Zagreb, Croatia

<sup>2</sup> Department of Traumatology, General Hospital Varaždin, Varaždin, Croatia

<sup>3</sup> Scientific Unit, General Hospital Varaždin, Varaždin, Croatia

## ABSTRACT

*Calcaneal fracture (CF) treatment results are not always satisfied. Our aim was to compare medium-term results between standardized and unstandardized protocol in treatment of displaced intra-articular CF. We evaluate experience of our Department where 50 patients with CF in last 5 years – Group X have been treated with standardized protocol, and compare their postoperative results with unstandardized treatment's effects in 50 patients with CF cured 5 years before – Group Y. As based on Sanders classification, radiographic evaluation and Maryland Foot Score, postoperative results were satisfying in 100% X and 90% Y patients with intra-articular type I, in 86% X and 70 % Y patients with type II, and sufficient in 75% X and 52 % Y patients with type III, in 50% X and 33% Y patients with type IV. We suggest standardized protocol with operative treatment for types II, III and even for type IV of intra-articular CF.*

**Key words:** calcaneal fracture, standardized protocol, operative treatment, sustentacular fragment

## Introduction

Calcaneal fracture (CF) is the injury caused by falling down from heights or the one sustained in motor vehicle accidents. Treatment of CF is a great challenge for every surgeon. Open reduction and stable internal fixation with a lateral plate and without joint transfixation has been established as a standard therapy for displaced intra-articular fractures.<sup>1,2</sup>

The aim of this study was critical analysis and comparison of the medium-term results of open reduction and internal fixation (ORIF) of displaced intra-articular calcaneus fractures between the one patient's cohort with a standardized protocol and the another one with the same number of patients but with an unstandardized protocol.

## Materials and Methods

We evaluate the experience of our Department where 50 patients with CF have been treated in the last 5 years – group X, and compare their postoperative results with treatment's effects in 50 patients with CF cured 5 years before – group Y.

The study was reviewed by the General Hospital Varaždin Ethics Committee and performed in accordance with the ethical standards laid down in an appropriate version of the 1964. Declaration of Helsinki. All patients gave their informed consent prior to their inclusion in the study.

We analyze clinical records, gender, age, symptoms and signs. We evaluate preoperative, operative and postoperative radiographic pictures and CT- scans and treatment protocols, and finally the postoperative results with an physical examination and an extended protocol of questionnaire according to the Maryland Foot Score. So, a treatment of each case was reviewed. A review of relevant articles regarding epidemiological features, imaging studies together with the actual form of management according to the type of fracture was made.

All of the patients with CF had the same preoperatively protocol with clinical examination: amount of the bone dislocation, status of the skin and soft tissues – compartment syndrome, neurovascular and tendon status and evaluation of RTG and CT scans.

Conservative treatment of patients in both groups mean a standard protocol with or without reposition in intravenous anesthesia followed with or without cast immobilization.

Operative treatment of patients in both groups was performed with principal aims: reconstruction of the lever by restoration of height, length, width and axis of the calcaneus, anatomical reconstruction of all dislocated joint surfaces and bone fragments, restoration of function by primary stable osteosynthesis.

In the group X we treated patients with the standardized protocol divided in three phases: 1.) preoperative clinical, RTG and CT examination, conservative therapy and preparation/planning for the operation, 2.) standardized operative treatment: lateral approach Palmer (extended Seattle), open reduction and stable internal fixation with a lateral plate and without joint transfixation, 3.) postoperative care. Ideal terminus for the operation was in the first 6 to 8 hours after the injury when is the skin turgor of lateral calcaneus region satisfied, still. If it was not possible we prefer a delayed terminus of operative treatment – 7 days after the injury, but the most important within 3 weeks, after the resting, leg elevation, with eventual use of device for compressive pressure. The patient was placed in a lateral decubitus position on

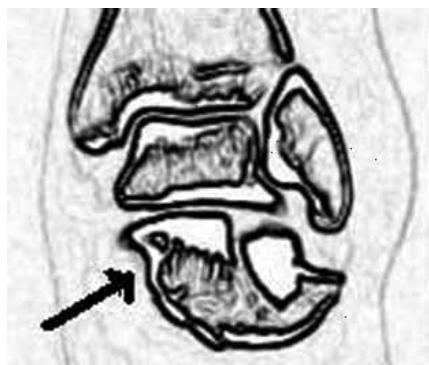

Fig. 1. The sustentacular fragment – the most important target of operation.

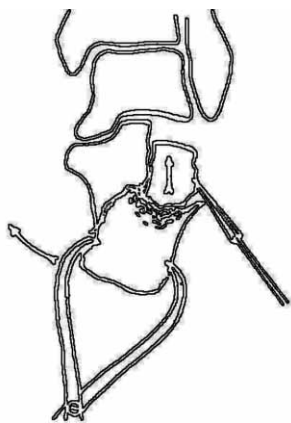


Fig. 2. Reduction maneuver of the subtalar joint fragment.



Fig. 3. Reposition of sustentacular fragment and tuber.

the noninjured side on a radiolucent operating table allowing intraoperative radiographic control. We used the lateral (Palmer) and extended lateral approach (Seattle). The approach was exercised in the fashion of a full thickness flap. The peroneal tendons had to be mobilized within their sheaths for the exposure of the calcaneocuboidal joint. The fibulocalcaneal ligament was detached from the bone and all preparation is epiperiosteal. The sustentacular fragment and its excellent reposition and fixation was the most important target of operation (Figure 1). At first we showed the pressed down fragments in totality with the movement of lateral fragment. After that, with the possible use of Shantz pins, we made a reduction maneuver of the subtalar joint fragment (Figure 2) and reposition of sustentacular fragment and tuber (Figure 3). We used the cancelous bone grafting in the 10 percentages of cases. At the end we performed a temporary fixation of reduced fragments with K wires (Figure 4) and the definitive stabile fixation with the AO calcaneal plate and screws.

While the operative treatment of patients in group X had standard protocol, it was not the same example in group Y (in the period of 5 years before group X). In this group the operative procedures were unstandardized in the preoperative preparation and planning and in the use

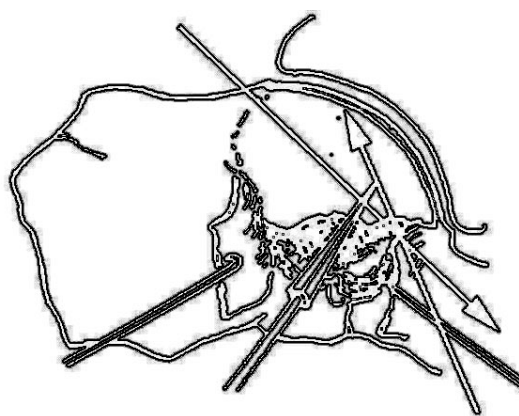


Fig. 4. Temporary fixation with K wires.

of a wide spectar of surgical procedures: different approaches, ORIF using a different plates, screws, K wires and with or without joint transfixation.

Postoperative care in both group of patients had the same rehabilitation aim as an early mobilization that includes active and passive range of motion exercise from the second postoperative day. Patients were restricted to partial weight bearing for 8–10 weeks. They were going back to a normal life activity within 4–5 months.

As we want to made a critical analysis and comparison of the medium-term results of open reduction and internal fixation (ORIF) of displaced intra-articular calcaneus fractures between the one patient cohort with a standardized protocol and the another one with the same number of patients but with an unstandardized protocol we use main outcome measurements : physical examination, an extended protocol of questionnaire according to the Maryland Foot Score and evaluation of postoperative radiographs.

## Results

In the group X there were forty five women and five men and in the group Y forty eight women and eight men. The average age in the group X was 50 (range 30–75) and in the group Y 52 (range 36–81).

Extra-articular type of CF had 2 patients in group X: one patient was operated (OP) and one was treated conservatively (CO). In group Y the same type of CF had 5 patients: one was operated and one four of them were treated conservatively. Intra-articular type of CF had 49 patients in group X and 45 in group Y. According to the Sanders classification of intra-articular CF, based on the evaluation of CT scans:- type I had 10 patients in group X (2 OP/ 8 CO) and 2 in group Y (1 OP/1CO) type IIA had 2 patients in group X and 2 in group Y, type IIB 2 in group X and 5 in groupY, type IIC 4 in group X and 3 in group Y, type IIIB 8 in group X and 5 in group Y, type IIIC 10 in group X and 9 in group Y, type IIIBC 12 in group X and 8 in group Y and type IV in 8 in group X and 3 in group Y.

As based on the measurements a postoperative results were satisfying in all patients with extra-articular type of CF in both groups, in 100% (group X) and 90% (group Y) with intra-articular type I, in 86% (group X) and 70 % (group Y) with type II. The postoperative re-

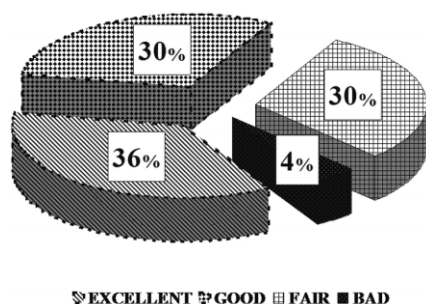


Fig. 5. The results of a treatment in the group Y.

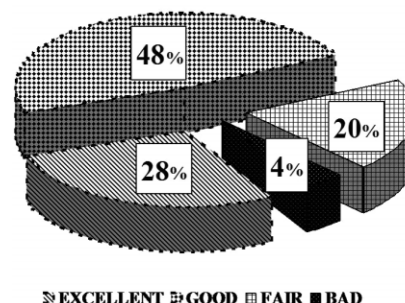


Fig. 6. The results of a treatment in the group X.

sults were sufficient in 75% (group X) and 52 % (group Y) with type III and in 50% (group X) and 33% (group Y) with type IV. At the end of the evaluated period, the results of a treatment in the group Y were unsatisfied in 34% of patients: bad in 4% and fair in 30%. In the same group there were 66% of satisfied results: 30% of good and 36% of excellent (Figure 5). The final relation among the results of treatment in group X was: unsatisfied in 24% of patients: bad in 4% and fair in 20%, and satisfied in 76%: good in 48% and excellent in 28% (Figure 6).

The difference in the X and Y groups, concerning the numbers of satisfied treatment's results of with CF is statistically significant ( $p < 0.01$ ). Statistical significances were calculated using  $\chi^2$  test.

## Discussion

Open reduction and internal fixation is the treatment of choice for displaced intra-articular calcaneal fractures at many orthopaedic trauma centers. But, according to Bukley R et al.<sup>3</sup> the functional results after nonoperative care of displaced intra-articular calcaneal fractures are equivalent to those after operative care.<sup>3</sup> Csizy M. et al.<sup>4</sup> report that initial open reduction and internal fixation of patients with displaced intra-articular calcaneal fracture minimized the likelihood that subtalar fusion would be required.<sup>4</sup>

Schepers et al.<sup>5</sup> indicate favourable results for the percutaneous technique compared with the open technique. Despite similar rates of postoperative infection and secondary arthrodesis, the total outcome scores and preserved subtalar motion were overall good to excellent in their study.<sup>5</sup> According to the outcome of historic controls from randomized trials and meta-analyses, anatomical reduction of joint congruity and the overall shape of the calcaneus are the most important prognostic factors. The extended lateral approach respects the neurovascular supply to the heel and allows a good exposure of the fractured lateral wall, and the subtalar and calcaneocuboid joints in most fractures.<sup>6</sup> Operative treatment of intra-articular calcaneal fractures according to Palmer provided encouraging results, since restoration of Böhler's angle was obtained. Main advantages include an absence of hardware prominence, resulting in an absence of skin complication, and a stable fixation.<sup>7</sup> Treatment results

are adversely affected by open fractures, delayed reduction after more than 14 days and individual risk factors such as high body mass index and smoking.<sup>8</sup>

In our study, all of the patients in group X were treated with the same standardized protocol. Thanks to a better understanding of three-dimensional nature of CF we found that the sustentacular fragment and its excellent reposition and fixation is a key of a good operative result. We managed our standardized operative treatment on the base of this conclusion.

According to our experience from this study the difference in the X and Y groups, concerning the numbers of satisfied treatment's results of patients with CF is statistically significant. Statistical significances give us evidence that only the standardized operative protocol of

CF treatment, as it was in group Y, could give us the best results.

Our last conclusion before 3 years<sup>2</sup> was a suggestion of conservative treatment for all extra-articular and type I of intra-articular CF, and operative treatment for type II and type III of intra-articular CF whereas there was still dilemma in the relation to the treatment of type IV. Now, after many years of experience and attained good results we suggest operative treatment for type IV, also.

## Acknowledgement

The source of all funding for the study has been obtained by the National Health Insurance.

We thank Vera Sršan Živanović (Department of General Surgery and Traumatology, General Hospital Varaždin).

## REFERENCES

1. RAMMELT S, ZWIPP H, Calcaneus fractures: facts, controversies and recent Developments, *Injury*, 35 (2004) 443. — 2. DARABOS N, CESAREC M, GRGUROVIC D, Calcaneal fracture – our experience, In: Abstracts Book, SICOT meeting, Istanbul, Turkey (2005) 115. — 3. BICKLEY R, TOUGH S, MC CORMACK R, PATE G, LEIGHTON R, PETRIE D, GALPIN R Operative compared with nonoperative treatment of displaced intra-articular calcaneal fractures: a prospective, randomized, controlled multicenter trial, *J Bone Joint Surg Am.* 84 (2002) 1733. — 4. CSIZY M, BUCKLEY R, TOUGH S, LEIGHTON R, SMITH J, MC CORMACK R, PATE G, PETRIE D, GALPIN R, Displaced intra-articular calcaneal fractures: variables predicting late subtalar fusion, *J Orthop Trauma*, 17 (2003) 106. — 5. SCHEPERS T, SCHIPPER IB, VOGELS LM, GINAI AZ,

MULDER PG, HEETVELD MJ, PATKA P, Percutaneous treatment of displaced intra-articular calcaneal fractures, *J Orthop Sci*, 12 (2007) 22. — 6. RAMMELT S, BARTHEL S, BIEWENER A, GAVLIK JM, ZWIPP H, Calcaneus fractures. Open reduction and internal fixation, *Zentralbl Chir*, 128 (2003) 517. — 7. DI SCHINO M, BENSAIDA M, VANDENBUSSCHE E, AUGEREAU B, NICH C, Results of open reduction and cortico-cancellous autograft of intra-articular calcaneal fractures according to Palmer. *Rev Chir Orthop Reparatrice Appar Mot*, 94 (2008) 135. — 8. WESTPHAL T, HALM JP, PIATEK S, SCHUBERT S, WINCKLER S, Quality of life after calcaneal fractures. A matched-pairs trial with a standardized German control group, *Unfallchirurg*, 106 (2003) 313.

N. Daraboš

University Clinic of Traumatology, University of Zagreb, Draškovićeva ulica 19, 10000, Zagreb, Croatia  
e-mail: darabos.dr@vz.t-com.hr

## PRIJELOMI PETNE KOSTI – STANDARDIZIRANI PROTOKOL TRETMANA

### SAŽETAK

Rezultati tretmana prijeloma petne kosti nisu uvijek zadovoljavajući. Želja nam je bila usporediti srednjoročne rezultate između standardiziranog i nestandardiziranog protokola u tretmanu unutar-zglobnih prijeloma petne kosti s pomakom fragmenata. Ocjenjivali smo iskustvo našeg odjela gdje je u posljednjih 5 godina, zbog prijeloma petne kosti, 50 bolesnika bilo tretirano standardiziranim protokolom – grupa X, te uspoređivali njihove poslijeoperacijske rezultate s rezultatima nestandardiziranog tretmana kod 50 bolesnika sa prijelomom petne kosti liječenih u periodu od 5 godina ranije – grupa Y. Na temelju Sandersove klasifikacije, radiološke evaluacije i Maryland ocjenke funkcionalnosti stopala, poslijeoperacijski rezultati su bili zadovoljavajući u 100% X i 90% Y bolesnika s tipom I unutar-zglobnog prijeloma petne kosti, u 86% X i 70% Y bolesnika s tipom II prijeloma, u 75% X i 52% Y bolesnika s tipom III prijeloma, te u 50% X i 33% Y bolesnika s tipom IV prijeloma. Obzirom na rezultate predlažemo standardizirani protokol operacijskog tretmana za tipove II, III pa čak i za tipove IV unutar-zglobnih prijeloma petne kosti.