

Pelvic Peritonization after Laparoscopic Abdominoperineal Resection for Low–Rectal Carcinoma Treatment: Surgical Technique

Nikica Družijanić¹, Zdravko Perko¹, Darko Sršen¹, Zenon Pogorelić², Dragan Schwarz³, Joško Juričić¹

¹Department of Surgery, University Hospital Split and Split University School of Medicine, Spinčičeva 1, 21000 Split, Croatia

²Department of Pediatric Surgery, University Hospital Split and Split University School of Medicine, Spinčičeva 1, 21 000 Split, Croatia

³Department of Surgery, General Hospital Sveti Duh, Sveti Duh 64, 10 000 Zagreb, Croatia

Corresponding Author: Zenon Pogorelić, MD, PhD, Department of Pediatric Surgery, University Hospital Split, Spinčičeva 1, 21 000 Split, Croatia

Tel: +38521556182, Fax: +38521556225, E-mail: zenon@vip.hr

KEY WORDS:

Abdominoperineal rectum amputation; Pelvic peritonization; Laparoscopy

ABBREVIATIONS:

Abdominoperineal Resection (APR); Transanal Micro Surgery (TEM); Abdominoperineal Rectum Amputation (LAPA); Laparoscopic Pelvic Peritonization (LPP)

SUMMARY

Abdominoperineal resection is a standard method of low-rectum carcinoma treatment. It is associated with significant morbidity and mortality rates, which decreased with the development of preoperative diagnostic procedures, new surgical techniques and new surgical instruments. In this article, laparoscopic pelvic peritonization was used after laparoscopic rectum amputation for low-rectum carcinoma treatment. Pelvic peritonization is performed after laparoscopic recto-sigmoid extirpation, using the extended absorbable intracorporeal suture with titanic clip applica-

tion after every second suture. The role of titanic clip is to grasp the extended suture and to mark the postoperative irradiation field. Laparoscopic pelvic peritonization after laparoscopic abdominoperineal rectum amputation is a simple procedure with clinical importance in possible adhesion and postirradiation enteritis prevention. This procedure can satisfy all oncological requirements and minimally invasive surgery principles and is acceptable for every patient in which rectum amputation is indicated.

INTRODUCTION

Abdominoperineal resection (APR) is the gold standard for low-rectal carcinoma treatment, but has a high incidence of postoperative morbidity and mortality. Because of new diagnostic procedures and new surgical techniques development, the "sphincter saving procedures" has become the standard for rectum carcinoma treatment with a significant decrease in number of APR. Nevertheless, APR must be performed for some indications. These include non-differentiated tumors placed 0-3 cm from the anus with a mucinous component when transanal micro surgery (TEM) is not possible (1) or coloanal anastomosis performing after preoperative evaluation, etc. If APR is indicated, we believe that laparoscopic abdominoperineal rectum amputation (LAPA) with laparoscopic pelvic peritonization (LPP) can be considered as one of the procedures because of all minimally invasive surgery advantages (2, 3), possible postirradiation enteritis and adhesions prevention and the lower associated cost of the procedure.

SURGICAL TECHNIQUE

After the creation of standard CO₂ pneumoperitoneum, the sigma was mobilized. After the inferior mesenteric artery had been found, secured and cut, total mesorectal excision was performed, giving

consideration to peritoneum, and lateral from the large intestine. Then we started with the perineal part of procedure. After dissecting the anus from the surrounding tissue, the distal part of sigmoid colon, together with rectum, tumor and anus, were extracted transperineally. A drainage tube was placed perineally and the perineal wound was closed. After a creating a pneumoperitoneum again, LPP was performed using an extended absorbable intracorporeal suture. After every second or third loop of a running suture, a titanic clip was placed on the suture to assist suturing. This maneuver helped us to avoid continuous protrusion of suture which could cause the tissue tearing, making the LPP impossible. The peritonization was finished the same way with one titanic clip between the last suture and peritoneum. A peritoneal aspiration drainage was used to develop negative pressure inside the area between the bottom of pelvis and newly sutured peritoneum to close that area and prevent tissue tearing under the weight of small intestine. There was no abdominal drainage. The procedure was finished by performing a definitive sigmoidostomy (Figure 1, 2).

The titanic clips are visible on abdomen X-ray which can be important and helpful for oncologist to determine the area for postoperative radiotherapy,

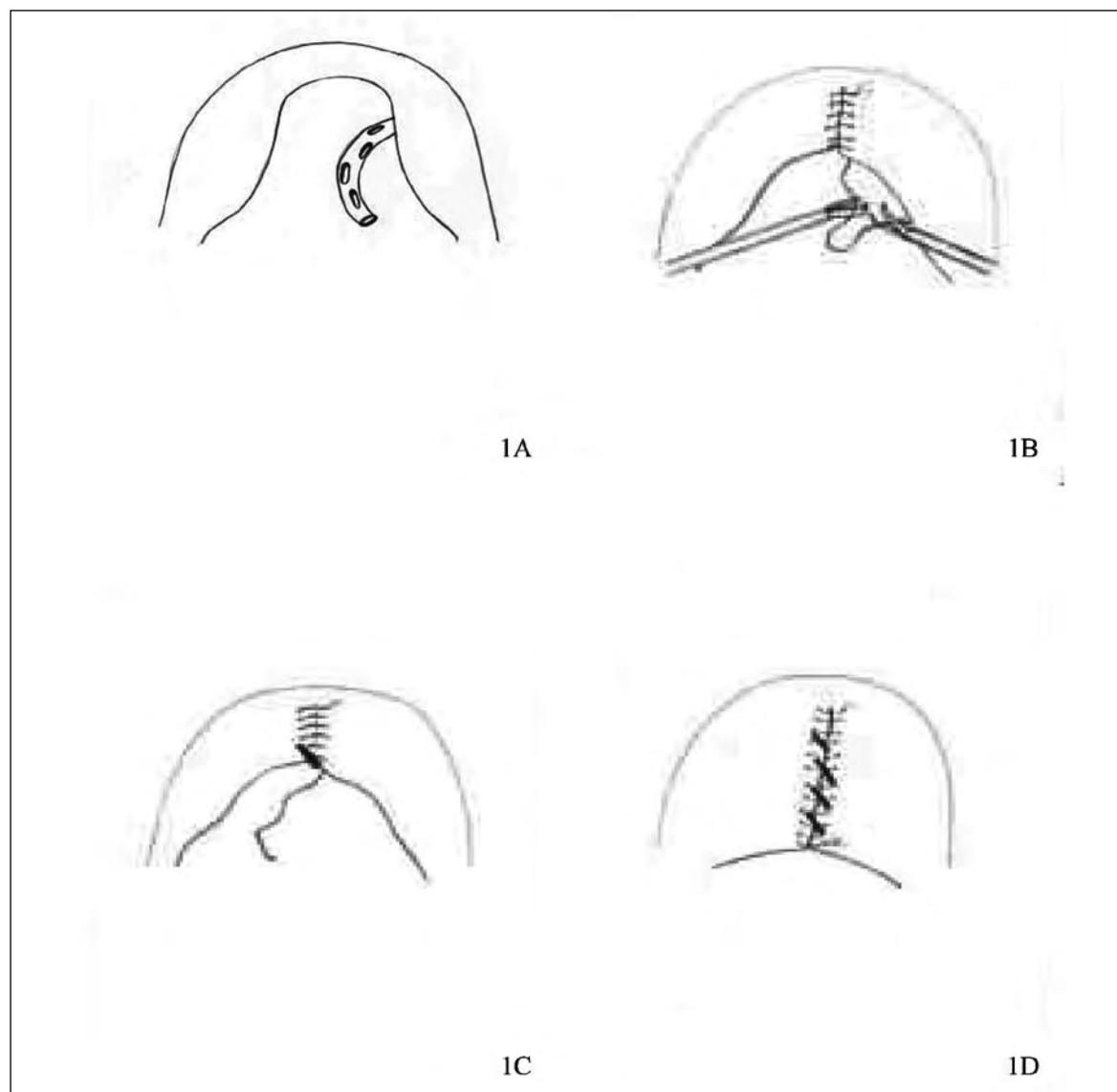


FIGURE 1 Schema of laparoscopic pelvic peritonization after LAPA. **1A** Perineal drainage tube. **1B** Sutting the peritoneum. **1C** Clip plasing. **1D** Finished pelvic peritonization

if necessary (**Figure 3**).

DISCUSSION

The standard procedure for low-rectum carcinoma treatment is abdominoperineal resection (APR). The fundamental principles of procedure was described by Charles Mayo in 1904 upon the ideas of Czerny from 1884. Many modifications were presented after that but the final technique was established by Miles in 1908 and Lloyd-Davis in 1938 (4, 5).

The aim of the procedure is to ligate the inferior mesenteric artery on its point of departure from aorta and to extirpate the tumor and anus together with distal sigma and rectum. It is very important to extirpate regional lymphatic nodes (presacral, lateral and distal from tumor) and to perform terminal sigmatic colostomy at the end of the procedure. This procedure became the standard

procedure despite its complications and high incidence of morbidity and mortality. The morbidity and mortality rates after APR decreased during the years because of the better preoperative diagnostics and preparations and better postoperative treatment (transfusion, antibiotics, parenteral feeding, thromboprophylaxis, etc.).

Despite that, the development of new diagnostic procedures (endoscopy, endoscopic ultrasound, CT, MSCT, MRI, etc.) increased the role of "sphincter saving procedures" (anterior high and low rectum resection by Dixon) and transanal endoscopic microsurgery (TEM) (1), decreasing the number of APR procedures to 10-15% of all rectum procedures for malignant diseases, especially after the improvements of no differences in the 5-year survival between APR and "sphincter saving procedures" (6, 7).

It is very important to evaluate the right indications for APR. The preoperative procedure must

FIGURE 2

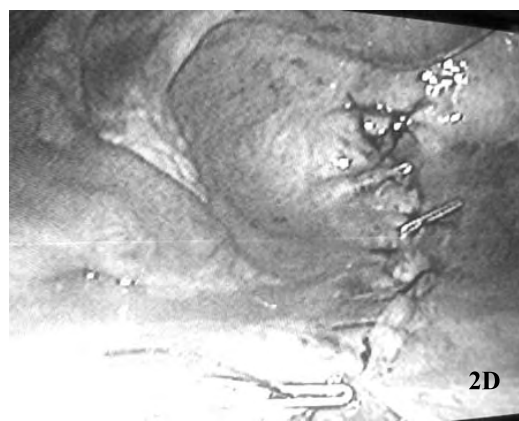
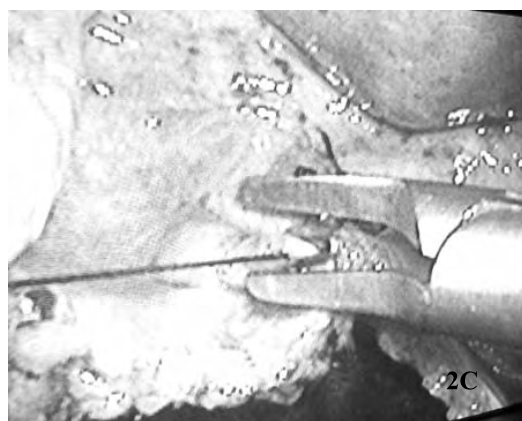
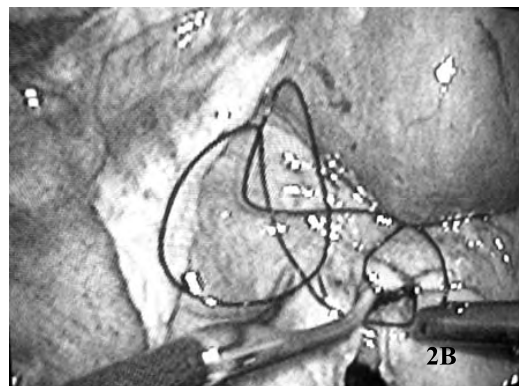
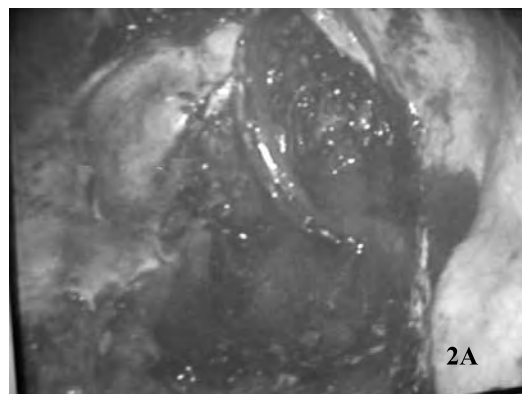
Intraoperative pictures of laparoscopic pelvic peritonization after LAPA.

2A Perineal drainage tube.

2B Suturing the peritoneum.

2C Clip placing.

2D Finished pelvic peritonization



provide information about on the height, size and distance of tumor from anal sphincter, morphological tumor characteristics, positive or negative family anamnesis, patient's age and condition, sphincter function, other diseases (ASA classification), as well as possible and expected postoperative morbidity and mortality (8).

The evaluation of possibility of low-rectum carcinoma treatment must be performed after a complete preoperative diagnostic procedure (CEA, CA 19.9, standard laboratory examinations, colonoscopy, irigography, MSCT of abdomen). If TEM or coloanal anastomosis can't be performed because of the tumor location or its invasion, APR, with or without neoadjuvant or adjuvant chemotherapy and radiotherapy, is indicated. The APR is also indicated for anal tumors, tumors of anal canal, non-differential tumors 0-3 cm from anal canal and ulcerative tumors. If there is an indication for APR procedure, we believe that the laparoscopic abdominoperineal rectum amputation (LAPA) has to be considered as one of the procedures.

LAPA has all positive characteristics of minimally invasive surgery such as low postoperative morbidity and mortality, faster recovery, shorter hospitalization, prevention of adhesions and cost

decrease. We believe that the LPP, performed in the way of extended absorbable suture with the titanium clips application after every third suture, can become an integral part of LAPA procedure (9).

Depending on the staging of disease, the postoperative chemotherapy and radiotherapy must be performed. The irradiation of pelvis can cause the development of interintestinal adhesions if the small intestine is inside the pelvis. It can also cause the development of postirradiatic enteritis with all its complications and risks. The role of LPP is to prevent the small intestine descending inside the newly developed area, keeping the small intestine outside the pelvis, which prevents possible small intestine obstructions. All these advantages increase patient's quality of life and decrease the postoperative morbidity and mortality.

The main problem to perform LPP can be the deficit of parietal peritoneum. It can be a challenge to save enough parietal peritoneum. However, we believe that the laparoscopic technique of suturing is well known to many surgeons and our suggestion of placing the titanium clip after every second suture makes that technique easier for this procedure. That is the reason why the parietal peritoneum saving must be considered during the procedure,

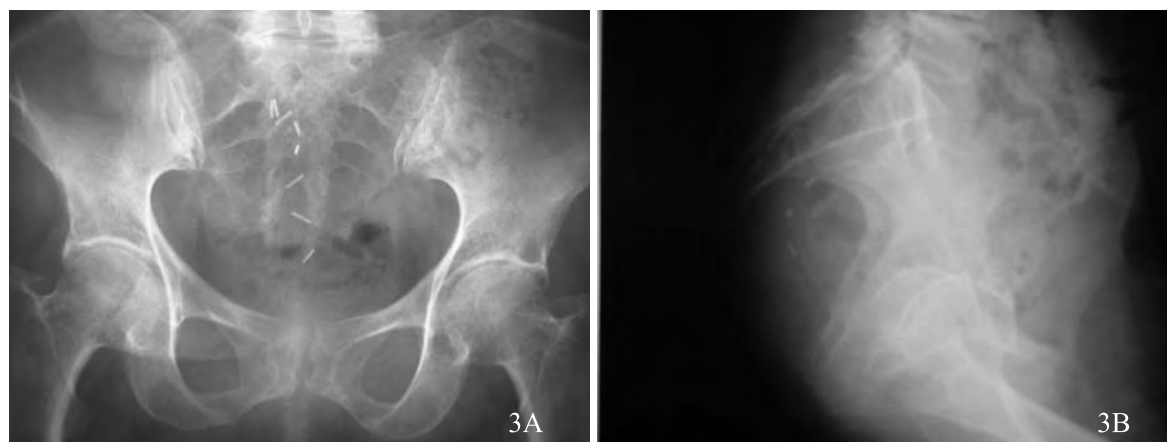


FIGURE 3 X-ray of abdomen after LAPA with LPP.
3A AP X-ray of abdomen.
3B Lateral X-ray of abdomen

before the TME, but it mustn't obstruct the radicalization of the procedure. LPP must be performed respecting all oncological principles. It is not easy but it is possible. It requires good surgical laparoscopic technique and training but we think that it is worth of it because of the possible positive effects

of LPP. If the oncological principles are respected, this technique becomes safe and useful. After solid training, it becomes easy to perform without significantly increasing the length of the procedure

REFERENCES

1. Družijanić N, Perko Z, Kraljević D, Juričić J, Maras Šimunić M, Bilan K, Krnić D, Pogorelić Z, Tomić S, Sršen D: Harmonic Scalpel in Transanal Microsurgery. *Hepatogastroenterology* 2008; 55:356-358.
2. Perko Z, Pogorelić Z, Bilan K, Tomić S, Vilović K, Krnić D, Družijanić N, Kraljević D, Juričić J: Lateral Thermal Damage to Rat Abdominal Wall after Harmonic Scalpel Application. *Surg Endosc* 2006; 20:322-324.
3. Perko Z, Družijanić N, Bilan K, Pogorelić Z, Kraljević D, Juričić J, Sršen D, Krnić D: Laparoscopic Colon Surgery: Our Results. *Coll Anthropol* 2008; 32:187-191.
4. Ravitch MM: Varieties of stapled anastomosis in rectal resection. *Surg Clin North Am* 1984; 64:543-567.
5. Ommer A, Girona-Johannkemper M, Jung KP, Berg E: Total mesorectal excision and colonic J-pouch-anal anastomosis in the therapy of low rectal carcinoma – results in 116 patients. *Zentralbl Chir* 2002; 127:775-780.
6. Lavery C, Lopez-Kostner F, Pelley JR: Treatment of colon and rectal cancer. *Surg Clin North Am* 2000; 80:535-563.
7. Wibe A, Sise A, Anderson E, Tretli S: Oncological outcomes after total mesorectal excision for cure cancer of the lower rectum: anterior vs. abdominoperineal resection. *Dis Colon Rectum* 2004; 47:48-56.
8. Cotte E, Lifante JC, Cherki S, François Y, Vignal J, Peix JL, Glehen O: Rectal amputation by pure perineal approach with laparoscopic colostomy apalliative therapeutic option for low or anal cancers for elderly patients with multiple comorbidities. *Ann Chir* 2006; 1131:100-103.
9. Družijanić N, Perko Z, Juričić J, Kraljević D, Bilan K, Krnić D, Sršen D, Pogorelić Z: Laparoscopic pelvic peritonization after abdominoperineal rectum amputation – 7th Croatian Congress of Endoscopic Surgery, Zagreb 2006. *Acta Chir Croat* 2006; 3: 24-25.