

## Case report

## Nasal dermal sinus cysts with intracranial extension in a child mosaic for a supernumerary ring chromosome 20

Bernarda Lozić<sup>a</sup>, Draško Cikojević<sup>b</sup>, Vlatko Ledenko<sup>c</sup>, Marisa Klančnik<sup>b</sup>, Ružica Lasan<sup>d</sup>, Tatijana Zemunik<sup>e,\*</sup><sup>a</sup> Department of Pediatrics, University Hospital Split, Spinčičeva 1, 21000 Split, Croatia<sup>b</sup> Department of Otorhinolaryngology, University Hospital Split, Spinčičeva 1, 21000 Split, Croatia<sup>c</sup> Department of Neurosurgery, University Hospital Split, Spinčičeva 1, 21000 Split, Croatia<sup>d</sup> Department of Pediatrics, Clinical Hospital Centre Zagreb, Kišpatičeva 12, 10000 Zagreb, Croatia<sup>e</sup> Department of Medical Biology, University of Split, School of Medicine, Šoltanska 2, 21000 Split, Croatia

## ARTICLE INFO

## Article history:

Received 19 July 2011

Received in revised form 11 November 2011

Accepted 27 December 2011

Available online 26 January 2012

## Keywords:

Nasal dermal sinus cyst

Intracranial extension

Supernumerary ring chromosome 20

Frontonasal region

Embryonic developmental error

Surgical treatment

## ABSTRACT

Nasal dermal sinus cysts are congenital malformations that result from anomalous embryological development and are not prescribed to any specific genetic defect. The occurrence of a supernumerary ring 20 that causes a partial trisomy 20 mosaicism is a rare chromosome abnormality and no common phenotype has been described yet. We present a unique case of a 3.5-year-old child with a supernumerary ring chromosome 20 mosaicism associated with nasal dermoid with intracranial extension. It is possible that this genetic defect contribute to embryonic developmental errors of the frontonasal region. The clinical presentation, surgical treatment, and literature review of this case are discussed.

© 2012 Elsevier Ireland Ltd. All rights reserved.

## 1. Introduction

The term nasal dermal sinus cyst (NDSC) includes all lesions containing ectoderm (stratified squamous epithelium) and mesoderm (adnexal structure) located in midline nasofrontal area [1]. Unlike other craniofacial dermoids, the nasal lesions can be presented as a cyst, a sinus, or a fistula and may have an intracranial extension [1]. Nasofrontal dermoid sinus cysts arise in the early embryonic development. Pathogenesis involves the incomplete obliteration of neuroectoderm in the process of frontonasal region development [2,3]. NDSCs are of ectodermal origin and occur as a result of failure in embryologic separation of neuroectodermal and ectodermal tissues [4]. The most widely accepted theory is based on Grunwald theory from 1910, later termed the *prenasal theory* by Pratt et al. and the *cranial theory* by Bradley et al. [2,5]. This theory is based on the finding that neuroectodermal tract retreats, and dermal attachments follow its course. When the dura mater retreats from the prenasal space back into the cranium, it may pull the nasal ectoderm upward and inward to form a sinus or a cyst [1]. The resulting epithelial lining

forms a dermal sinus or cyst, depending on its connection to the nasal dorsal skin [6].

The distal opening of a dermal sinus may be found anywhere from the glabella to the columella [7]. Dermoids are usually midline, whereas epidermoids occur mainly in the tip of the nose or slightly lateral to the nose. Meta-analysis showed that the incidence of NDSCs with intracranial communication was approximately 20% [8].

NDSCs have not been ascribed to any specific genetic defect. They have been associated with other congenital lesions, primarily with the lesions of first branchial arch, the congenital lesions of the face and brain that incidence ranges between 5 and 41% [1,9].

Wardinsky et al. assumed that presence of associated anomalies increases the probability of intracranial extension of a nasal dermoid [10]. NDSCs arise sporadically; however a familial association has been reported in the literature [11,12].

Supernumerary marker chromosome (SMC) including extra ring chromosomes occurs with a frequency of 0.14–0.72/1000 in newborns. The risk for phenotypic abnormalities associated with a marker chromosome depends on several factors such as inheritance, chromosomal origin, and the morphology, content, and structure of the marker [13,14]. The occurrence of an additional ring chromosome 20, r(20), is a rare chromosome abnormality and no common phenotype has been described yet [14].

\* Corresponding author. Tel.: +385 21 557 888; fax: +385 21 557 895.

E-mail address: [tzemunik@mefst.hr](mailto:tzemunik@mefst.hr) (T. Zemunik).

This report presents a rare case of NDSC with intracranial extension in a 3.5 year old boy who carried an extra ring chromosome 20 short arm that caused a partial trisomy 20 mosaicism.

The boy had a soft swelling secreting sebaceous material from the dimple in the frontal midline at the base of the nose, which was suspected to be a frontal encephalocele or nasal dermoid.

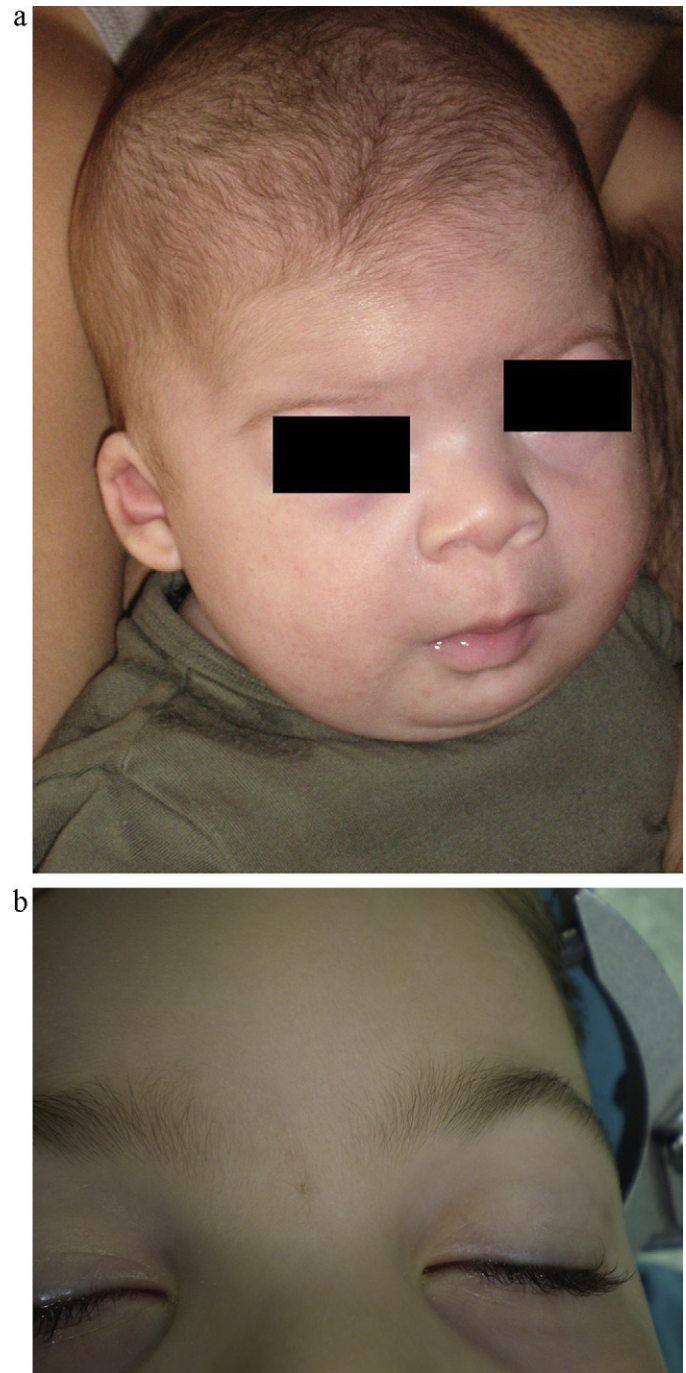
Magnetic resonance imaging (MRI) brain evaluation showed that it was a nasal dermoid with intracranial extension that requires surgical management. We described a technique of excision of the nasal dermoid with intracranial extension involving a brow incision which allows wide exposure of the nasal bones and also exposure of the frontal bone.

## 2. Case report

The proband was the only child of a 24 year old healthy mother and 25 year old healthy father. There was no family history of chromosomal disorder, consanguinity, craniofacial or midline nasal abnormality. The child was born at term (birth weight was 4050 g – 90th centile; birth length 52 cm – 90th centile) by vaginal delivery.

He was admitted to University Hospital Split, Department of Pediatrics at the age of 4 months because of a urinary tract infection and slight motor development delay. Physical examination showed craniofacial dysmorphisms including: slightly prominent forehead, round course face with hypertelorism, epicanthus, wide flat nasal bridge with dimple at base of nose in midline, wide nostrils, long philtrum; high arched palate; low-set small and thick ears (Fig. 1A and B). Because of the numerous dysmorphisms of the face, a chromosomal analysis of peripheral lymphocytes was performed during infancy using GTG (Giemsa-Trypsin-Giemsa) banding technique. It showed the presence of two cell lines in the karyotype: 46,XY[30]/47,XY,+dn mar[70]. In 30% of metaphases, normal 46,XY karyotype was observed and in an additional 70%, an extra marker (mar) chromosome was detected (Fig. 2). The parental karyotypes were normal. To identify the origin of de novo small supernumerary marker chromosome (sSMC), FISH analyses were performed on lymphocyte metaphase spreads from the patient. The following probes were used according to manufacturers's protocol (Kreatech Diagnostic, Amsterdam, the Netherlands): whole chromosome painting (WCP) of all chromosomes, chromosome 20 centromeric (D20Z1), WCP probe specific for chromosome 20, probes specific for detection of 20q at region 20q12 (PTPRT) and 20q11.21 (MAPRE1). FISH using WCP of all chromosome showed that the supernumerary ring chromosome was totally derived from chromosome 20 (Fig. 3A). No additional hybridization signal was detected on other chromosomes. Centromere specific probe of chromosome 20 and probe specific for detection of 20q11.21(MAPRE1) showed three signals corresponding to the centromeres of both normal 20 and the marker chromosome centromere while probe specific for detect of 20q12 region (PTPRT) was negative (showed two signals) (Fig. 3B). Standard cytogenetic and molecular investigations revealed that the patient carried an extra ring chromosome 20. That ring formation involves mostly a short arm of chromosome 20 and a small part of long arm of chromosome 20 that caused a partial trisomy 20 mosaicism. A breakpoint has been determined between points 20q11.21 and 20q12 in the long (q) arm of chromosome 20. The proband karyotype according to ISCN (2009) had 47,XY,+mar dn. ish r(20)(p13q11.21)(wcp20+,MAPRE1+,PTPRT–,D20Z1+) (Fig. 3A and B) [15].

During his life, the additional clinical features were observed: broad neck, umbilical hernia, right hydrocele testicle and left mobile testicle, heart scan showed secundum atrial septal defect (ASD), spine X-rays showed spina bifida occulta, normal mental



**Fig. 1.** (A) Five months old patient, note prominent forehead, round course face with hypertelorism, epicanthus, wide flat nasal bridge, wide nostrils, long philtrum and low-set small and thick ears. (B) 3.5 years old patient, note dimple at base of nose in midline.

development. Extensive additional investigations were normal and they included: hematologic, biochemical, endocrine and ophtalmological observations.

At the age of 3.5 years, in addition to the previously described phenotypic characteristics, the boy had intermittent headaches and soft swelling with discharge of sebaceous material from the dimple in the frontal midline at the base of the nose, which was suspected to be a frontal encephalocele or nasal dermoid.

Multipolar, high-resolution, thin section MRI was obtained. A sagittal T1 weight MRI showed a prominent high-intensity signal above the crista galli (arrow) with ovoid formation predominantly



**Fig. 2.** GTG-banded metaphase spread of the patient showing the marker chromosome (arrow indicate two homolog pair of chromosome 20 and marker chromosome).

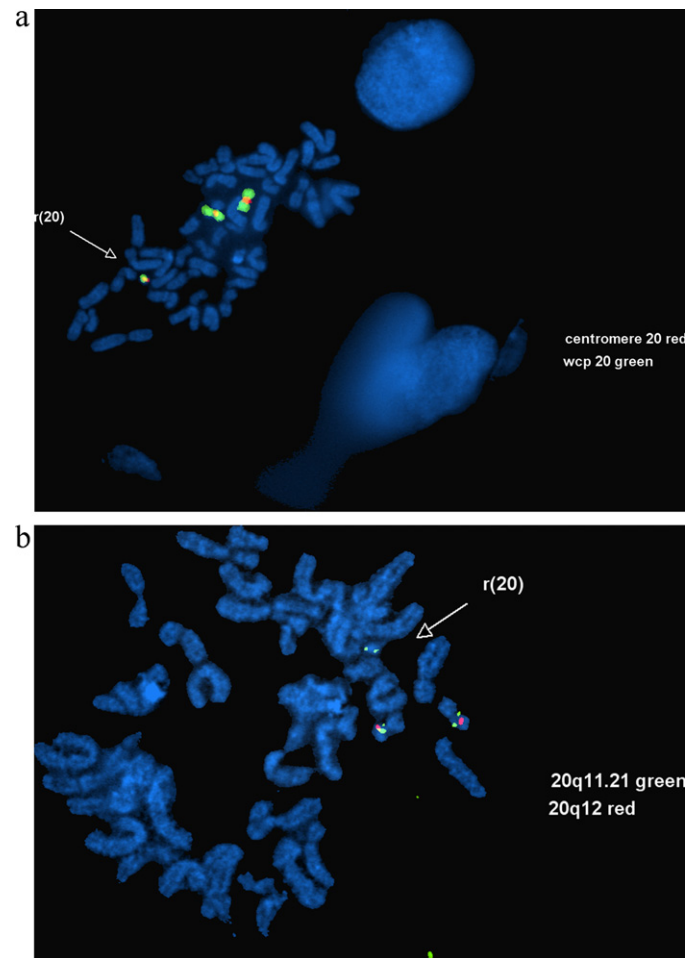
of cystic character of 13 mm × 11 mm in diameter (Fig. 4A and B). At the cranial pole of formation, discontinuity dura to 4 mm in length was seen, but there were no evidence of brain protrusion. T2-weighted MRI demonstrated prominent low-intensity signal, fat-suppressed T1 weighed images were used to MRI reveals the dermoid characteristics. MRI brain evaluation showed that it was a nasal dermoid with evidence of intracranial extension (Fig. 4B).

The patient underwent a surgical technique of excision of nasal dermoid with intracranial extension involving a brow incision which allowed wide exposure of the nasal bones and also exposure of the frontal bone. The cutaneous punctum was removed in continuity using an elliptical incision around the sinus opening (the skin part is sent for additional genetic analysis).

The bone was carefully abraded, and in this way the fistula was followed. The fistula passed through nasofrontal suture, into the diploe/lamellae of the frontal bone, stepwise going up and continued into the cyst. The dermoid cyst was fully displayed, but under surgical microscope, the limits to the dura were failed to observe. The following opening of the cyst, demonstrated the rear wall of the cyst, which was also the border to the endocranium due to a 4 mm gap of missing dura. The back side of the cyst was opened to demonstrate the relationship of the cyst to the brain, but any intracerebral extensions were not obtained (Fig. 5). Then, the whole cyst was removed with a surgical sonde on the inside of its wall. A synthetic dura with “TachoSil” was made and a titanium plate was placed on the outside. Complete removal of the cyst was confirmed with the computerized tomography (CT) scan after surgery (Fig. 6).

This technique gives a cosmetically acceptable scar, excellent exposure and minimal dural exposure. It required staying in hospital for 1 week and therapy with antibiotics. Sutures were removed 1 week post-operatively.

There were no other intraoperative complications, including meningitis, cerebrospinal fluid leak, hyposmia, damage to the sinuses, cerebral oedema, epilepsy, cognitive deficits and osteomyelitis of the frontal bone.



**Fig. 3.** (A) FISH using whole chromosome painting (wcp) probe specific for chromosome 20 (green signal), probe specific for the centromeric region chromosome 20 (red signal) on a child's metaphase spread. Homolog pair of chromosome 20 is painted in green and centromere 20 in red. Arrow indicate the small ring chromosome (20p) of the patient. (B) FISH using locus specific probe for region 20q12 (PTPRT) is painted in red and 20q11.21 (MAPRE1) is painted green. Arrow indicate the small ring chromosome was negative for red signal showing breakpoint.

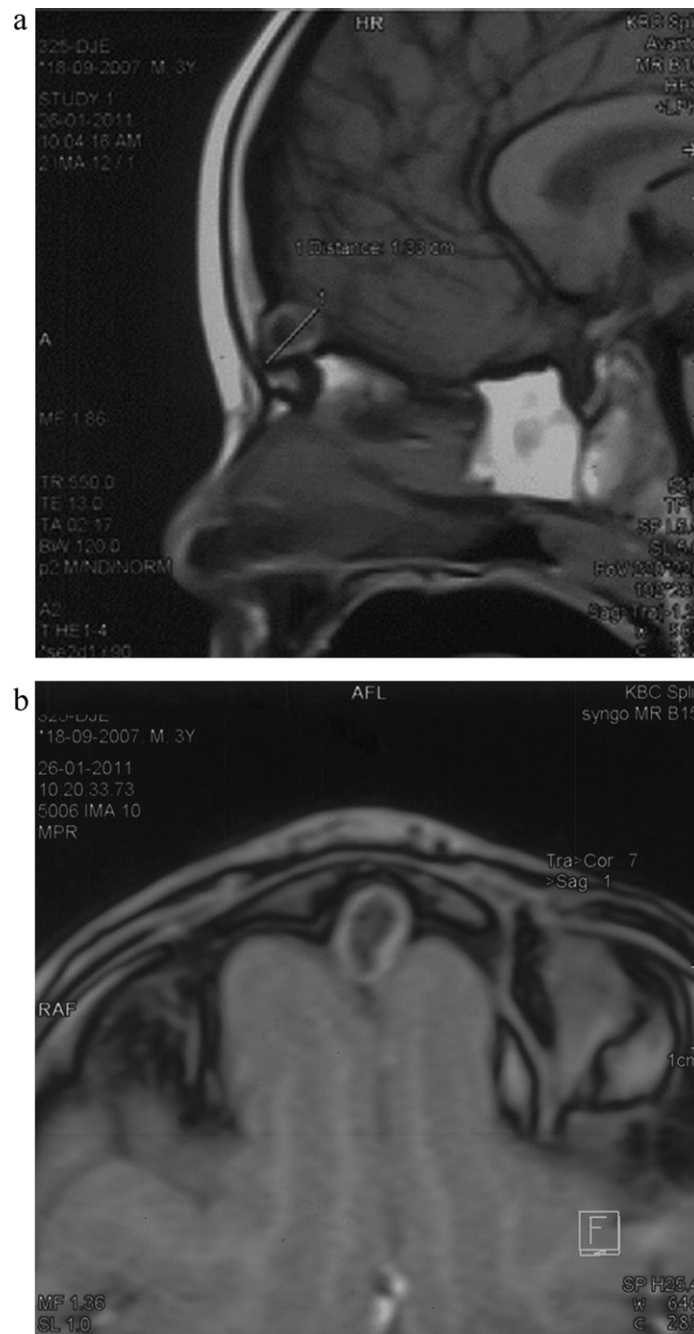
After the surgery, during the hospitalization, standard cytogenetic analysis from peripheral blood (lymphocytes) was repeated and showed that the percentage of the aneuploid cells slightly decreased, from 70% to 49%. The result of FISH analysis performed on skin fibroblast after cultivation of skin taken around the sinus openings cut during the surgery, revealed a similarly result of mosaic status with additional r(20) (p13q11.21) presented in 42% of 200 examined interphases. The percentage of cells with extra r(20) chromosome was similar in peripheral blood and fibroblasts at the 3.5 years of age.

Histology examination using a light microscopy confirmed a dermoid cyst lined by squamous epithelium with hair follicles.

### 3. Discussion

NDSC is rare developmental anomaly that arise sporadically. A familial connection has been reported in the literature, especially in cases for frontonasal dermoid cysts, but it does not show any genetic linkage [11,12]. However, Bratton et al. in their case report and a review of literature have suggested an autosomal dominant inheritance of single gene transmission [12]. Wardinsky et al. proposed that presence of associated anomalies increase the





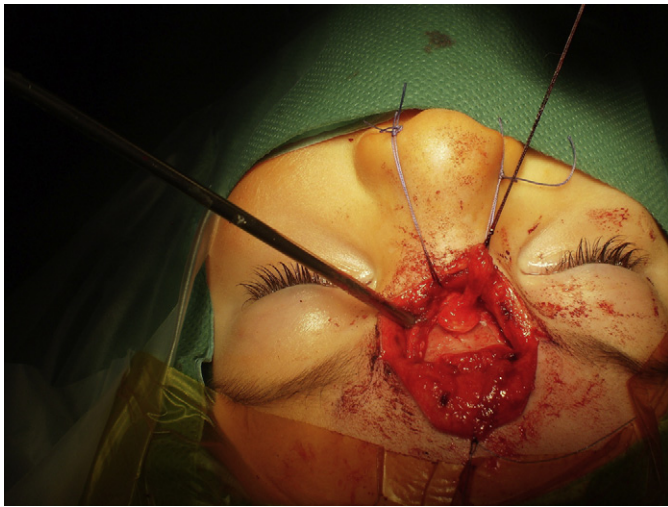
**Fig. 4.** Presentation of T1 weighted MRI scans of nasal dermoid, sagittal view (A) and coronal view (B).

probability of intracranial extension of a frontonasal dermoid but no one has ever related NDSC with chromosome disorder [10].

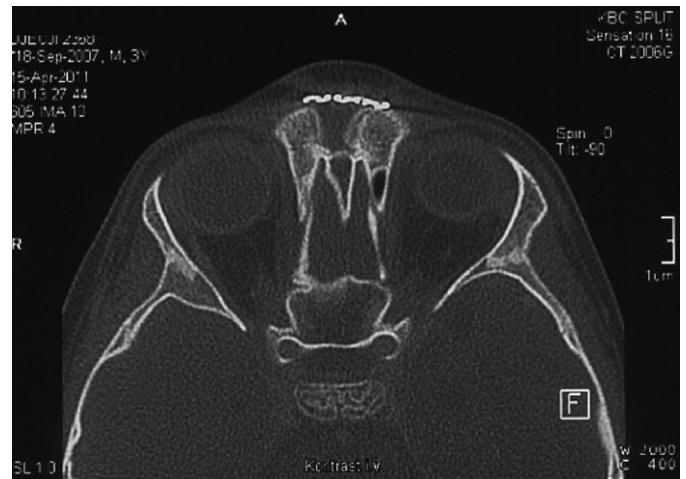
An additional ring chromosome 20, r(20) is a rare chromosome abnormality and due to the great variability of symptoms phenotype/karyotype correlation has been extremely difficult to established [14]. We reported a 3.5 year old boy with no mental and growth retardation symptoms, most commonly found in chromosomal disorder. His main symptom was midline face abnormality, symptomatically medial sinus at the root of the nose. Because of facial dysmorphisms, a chromosomal analysis of peripheral lymphocytes was performed during the infancy and a very rare chromosomal disorder with sSMC was found, but it could not predict a particular phenotype in the boy. By application of molecular cytogenetic technique (FISH), we identified the chromosomal origin, inheritance, and the morphology of sSMC in order

of better estimation of the risk for phenotypic abnormalities associated with a marker chromosome as it was mentioned in the literature [13].

Cytogenetic and molecular investigations revealed that the patient was carried an extra ring of chromosome 20 involving mostly a short arm and small part of long arm of chromosome 20 that caused a partial trisomy 20 mosaicism in two different tissues in similar proportion. This case report suggests that cell line with supernumerary ring 20 may be attributed to faulty embryonic development of the nasofrontal region leading to formation of nasofrontal dermoid sinus cysts. The application of molecular cytogenetic analysis in cases with rare congenital lesion like this, especially if it is associated with other congenital anomalies, is necessary and may prove higher incidence of rare chromosomal abnormality in future.



**Fig. 5.** Dissection of nasal dermal sinus cyst.



**Fig. 6.** Coronal view of the CT scan of the frontal nasal region after cyst removal with integrated titanium plate.

The presence of associated anomalies in the boy confirmed our suspicion that his nasal dermoid had intracranial extension and was in agreement with assumption observed in the previous literature [10]. Medial dimple at the root of the nose was obvious at birth, but was asymptomatic up to 3.5 years. When a soft swelling discharging sebaceous material from the dimple appeared, we performed preoperative MRI brain evaluation that showed a nasal dermoid had intracranial extension that required surgical management.

The applied surgical technique provided an excellent surgical, and also a satisfactory cosmetic effect. The bone window of the frontal bone was of minimal size, and was only done as big as was needed to follow the channel of the fistula.

The canal of the fistula ran from the nasofrontal suture, and then went through the two lamellae of the frontal bone, where it was removed by an osteoplastic procedure. It was difficult to determine the continuity of the fistula. Even the smallest remnant of tissue from the fistula or cyst in 50–100% of the cases results in recurrence [16].

Since the frontal sinus was still developing and demonstrating an infundibulum with adequate mucosal tissue, we decided not to obliterate the sinus, but to insert titanium plates instead. In this way further development of the frontal sinus was possible and esthetic defect of the forehead was minimized.

Surgical intervention at around 3 years of age is advised, but if it does not perform, the complications like meningitis, encephalitis, headache and psychic disturbances can occur.

After surgical procedure we reevaluated the cytogenetic analyses because our finding of supernumerary ring chromosome 20 was the only case that had midline nasal abnormality and has not been reported in the medical literature before. We found that the percentage of the aneuploid cells (cell line with ring 20) slightly decreased, from 70% to 49% in same tissue (lymphocytes) in the past three years. The degree of mosaicism is a critical element in the determination of phenotype in sSMC cases [17]. Limited data currently do not permit consistent genotype–phenotype correlations to be made [18]. Our results indicate that higher percentage of supernumerary r(20) chromosome cells (70%) and slightly motor development delay were present in four months old proband, but at the age of 3.5 years, lower percentage (49%) of supernumerary r(20) cells and normal psychomotor development were observed. It is in concordance with previously published case reports that showed that mosaicism involving chromosome 20p trisomy obtained in approximately 50% or greater lymphocytes results in psychomotor retardation, craniofacial abnormalities and

clinodactyly [19]. Dynamic level of mosaicism might also alter the risk associated with an abnormal phenotype. The effects of clinical outcomes are presumably dependent on tissue distribution of two cell lines. For this reason we determined the percentage of aneuploid cell lines in a part of ectoderm (taken during surgical procedure). Standard cytogenetic and FISH analyses of skin fibroblast were obtained after cultivation of skin and revealed a similar result of mosaic r(20) (p13q11.21) in 42% of 200 examined interphases. The percentage of cells with extra r(20) chromosome was similar as in peripheral blood and fibroblasts in the 3.5 years old child.

To the best of our knowledge, so far, in the literature eight cases of supernumerary r(20) chromosome detected postnatally were reported with detailed phenotypic characteristics [19–25]. Among those patients, a developmental delay/mental retardation, ear anomalies, and hand/feet anomalies were seen as a shared clinical feature, irrespective of the degree of mosaicism. None of the reported cases had midline face abnormality. Interestingly, one child presented in 1996 with additional ring chromosome 20p also had mild developmental delay, mild dysmorphic feature with midline nasofrontal mass. That mass was consisted of a frontal lipoma [21].

In addition, it is generally accepted that the presence of euchromatin that makes a marker chromosome destroy the phenotype [26]. We used molecular cytogenetic to determine gene content of sSMC and confirmed that it was a mostly a short arm of chromosome 20 and a small part of long arm of chromosome 20. A breakpoint has been determined between points 20q11.21 and 20q12 in the long (q) arm of chromosome 20. All of these factors, helped us to predict the clinical significance and to determinate the prognosis for the boy. However, further developmental follow-up is warranted.

#### 4. Conclusion

In this report we present the follow-up of the 3.5-year male patient with supernumerary ring chromosome 20 mosaicism associated with dysmorphic facial features and rare congenital lesion of nasal dermoid with intracranial extension which often poses diagnostic and surgical dilemmas. The derivative chromosome was characterized by standard cytogenetic and fluorescent in situ hybridization in order to delineate breakpoints and better determinate gene content of r(20) chromosome in order to help us to predict the clinical significance and to determinate the prognosis for the boy and compare him with other cases. We

described surgical treatment of the frontonasal dermoid with intracranial extension in the boy, performed without complications. The applied surgical technique provides excellent surgical and satisfactory cosmetic effect.

We also present the importance of cytogenetic examination in affected individuals in order to stimulate further genetic investigations and increase the identification of cases with rare chromosome abnormality without a defined clinical phenotype.

## Acknowledgement

We are grateful to the patient and his family for participating in this study.

## References

- [1] R.B. Sessions, Nasal dermal sinuses: new concepts and explanations, *Laryngoscope* 92 (1982) 1–28.
- [2] L.W. Pratt, Midline cysts of the nasal dorsum: embryologic origin and treatment, *Laryngoscope* 75 (1965) 968–980.
- [3] D.D. Weiss, C.D. Robson, J.B. Mulliken, Transnasal endoscopic excision of midline nasal dermoid from the anterior cranial base, *Plast. Reconstr. Surg.* 102 (1998) 2119–2123.
- [4] E.H. Harley, Pediatric congenital nasal masses, *Ear Nose Throat J.* 70 (1991) 28–32.
- [5] P.J. Bradley, The complex nasal dermoid, *Head Neck Surg.* 5 (1983) 469–477.
- [6] R. Rahbar, P. Shah, J.B. Mulliken, C.D. Robson, A.R. Perez-Atayde, M.R. Proctor, et al., The presentation and management of nasal dermoid: a 30-year experience, *Ear Nose Throat J.* 129 (2003) 464–471.
- [7] T.P. Naidich, R.E. Osborn, B.S. Bauen, et al., Embryology and congenital lesions of the midface, in: P.M. Som, A.T. Bergenon (Eds.), *Head, Neck Imaging*, 2nd ed., Mosby, St. Louis, 1991, pp. 1–17.
- [8] M. Hanikeri, N. Waterhouse, N. Kirkpatrick, D. Peterson, I. Macleod, The management of midline transcranial nasal dermoid sinus cysts, *Br. J. Plast. Surg.* 58 (2005) 1043–1050.
- [9] D.W. Morgan, J.N. Evans, Developmental nasal anomalies, *J. Laryngol. Otol.* 104 (1990) 394–403.
- [10] T.D. Wardinsky, R.A. Pagon, R.J. Kropp, P.W. Hayden, S.K. Clarren, Nasal dermoid sinus cysts: association with intracranial extension and multiple malformations, *Cleft Palate Craniofac. J.* 28 (1991) 87–95.
- [11] J.L. Plewes, I. Jacobson, Familial frontonasal dermoid cysts: report of four cases, *J. Neurosurg.* 34 (1971) 683–686.
- [12] C. Bratton, D.L. Suskind, T. Thomas, E.A. Kluka, Autosomal dominant familial frontonasal dermoid cysts: a mother and her identical twin daughters, *Int. J. Pediatr. Otorhinolaryngol.* 57 (2001) 249–253.
- [13] M.D. Graf, L. Christ, J.T. Mascarello, P. Mowrey, M. Pettenati, G. Stetten, et al., Redefining the risks of prenatally ascertained supernumerary marker chromosomes: a collaborative study, *J. Med. Genet.* 43 (2006) 660–664.
- [14] N. Guediche, S. Brisset, J.J. Benichou, N. Guérin, P. Mabboux, M.L. Maurin, et al., Chromosomal breakpoints characterization of two supernumerary ring chromosomes 20, *Am. J. Med. Genet. A* 152A (2010) 464–471.
- [15] L.G. Shaffer, M.L. Slovak, L.J. Campbell (Eds.), *ISCN: International System of Human Cytogenetic Nomenclature*, S Karger AG, Basel, 2009.
- [16] R.L. Heywood, M.J. Lyons, L.A. Cochrane, R. Hayward, B.E. Hartley, Excision of nasal dermoids with intracranial extension – anterior small window craniotomy approach, *Int. J. Pediatr. Otorhinolaryngol.* 71 (2007) 1193–1196.
- [17] A. Kolialexi, S. Kitsiou, H. Fryssira, C. Sofocleous, E. Kouvidi, G.T. Tsangaris, et al., Identification of autosomal supernumerary chromosome markers (SMCs) by fluorescent in situ hybridization (FISH), *In Vivo* 20 (2006) 473–478.
- [18] T. Liehr, U. Claussen, H. Starke, Small supernumerary marker chromosomes (sSMC) in humans, *Cytogenet. Genome Res.* 107 (2004) 55–67.
- [19] E.D. Austin-Ward, S. Castillo, Y. Dragnic, P. Sanz, S. Salazar, J.H. Knoll, Clinical findings in a patient mosaic for a supernumerary ring chromosome 20, *Am. J. Med. Genet.* 91 (2000) 171–174.
- [20] R. Viersbach, H. Engels, G. Schwanitz, Identification of supernumerary der(20) chromosomes by FISH in three patients, *Am. J. Med. Genet.* 70 (1997) 278–283.
- [21] I.M. Van Langen, M.A. Otter, D.C. Aronson, W.C. Overweg-Plandsoen, R.C. Hennekam, N.J. Leschot, et al., Supernumerary ring chromosome 20 characterized by fluorescence in situ hybridization, *Clin. Genet.* 49 (1996) 49–53.
- [22] D.F. Callen, M.L. Ringenbergs, C.J. Freemantle, P. Woodroffe, E.A. Haan, Chromosomal origin of small ring marker chromosomes in man: characterization by molecular genetics, *Am. J. Hum. Genet.* 48 (1991) 769–782.
- [23] E. Blennow, G. Anner en, T.-H. Bui, E. Berggren, E. Asadi, M. Nordenskjöld, Characterization of supernumerary ring marker chromosomes by fluorescence in situ hybridization (FISH), *Am. J. Hum. Genet.* 53 (1993) 433–442.
- [24] J.A. Crolla, F. Long, H. Rivera, N.R. Demnis, FISH and molecular study of autosomal supernumerary marker chromosomes excluding those derived from chromosomes 15 and 22: results of 26 new cases, *Am. J. Med. Genet.* 75 (1998) 355–366.
- [25] M.R. Pinto, M.L. Fonseca e Silva, J. Aguiar, I. Quelhas, M.R. Lima, Supernumerary ring chromosome 20 in a mother and her child, *Am. J. Med. Genet. A* 133A (2005) 193–196.
- [26] P. Stankiewicz, E. Bocian, K. Jakubów-Durska, E. Obersztyn, E. Lato, H. Starke, et al., Identification of supernumerary marker chromosomes derived from chromosomes 5, 6, 19, and 20 using FISH, *J. Med. Genet.* 37 (2000) 114–120.