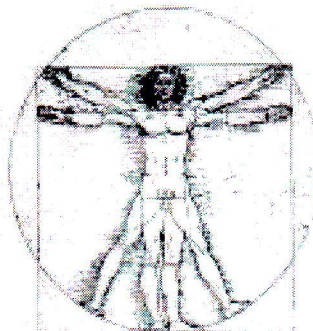


ZAMM



MAAM

# ***ACTA MORPHOLOGICA***

*PUBLIKACIJA NA ZDRU@ENIETONA ANATOMI I MORFOLOZI NA MAKEDONIJA*

*PUBLICATION OF MACEDONIAN ASSOCIATION OF ANATOMISTS AND MORPHOLOGISTS*

**ACTA MORPHOLOGICA**  
*Medical journal*  
*of*  
*Macedonian Association of Anatomists and Morphologists (MAAM)*

**Published**  
*Twice a year*

**EDITORIAL BOARD**

**Editor in Chief**  
*Dobрила Tosovska-Lazarova*  
*Skopje, Republic of Macedonia*

**Editors**  
*Gordana Teofilovski-Parapid*  
*Belgrade, Serbia*

*Andreas H. Weiglein*  
*Graz, Austria*

*Guido Macchiarelli*  
*L'Aquila, Italy*

*Petru Matusz*  
*Timisoara, Romania*

*Erdogan Sendemir*  
*Bursa, Turkey*

*Alessandro Riva*  
*Cagliari, Italy*

*Sadeta Sekic*  
*Sarajevo, BiH*

*Julija Zhivadinovik*  
*Skopje, Republic of Macedonia*

**Scientific Committee**  
*Anga Strateska-Zafirovska*  
*Vesna Janevska*  
*Eleni Dokic*  
*Kostandina Korneti-Pekavska*  
*Marija Papazova*  
*Natasa Janevska-Nakeva*  
*Nevena Kostova*  
*Niki Matveeva*

**Pre-Press**  
*Elizabeta Chadikovska*  
*Ace Dodevski*

**Print**  
*Printing office "Ilko" - Gostivar*

**Corresponding address**  
*Institute of Anatomy, Medical Faculty, 50 Divizija 6, Skopje, R. Macedonia*  
*Tel/fax: ++389 2 3125304*  
*e-mail: acta\_morphologica@yahoo.com*

---

## CONTENT

- |    |                                                                                                |
|----|------------------------------------------------------------------------------------------------|
| 5. | A rare case of origin of the obturator artery from the femoral artery Djударic Luka, Bobinac D |
|----|------------------------------------------------------------------------------------------------|
7. Anthropometric parameters of growth in preschool children Trpkovska Biljana
  10. Sex and age specific differences of some anthropometric parameters and bmi in macedonian adolescents Biljana Bojadzieva Stojanoska, Janevska Nakeva N, Zafirova B, Matveeva N, Chadikovska E, Gontarev S
  15. Ductal carcinoma of the prostate mixed with acinar adenocarcinoma. A case report Janevska Vesna, Bajdevska D, Zrmanovska A, Kostadinova-Kunovska S, Zhivadinovik J
  18. Novel RET mutations in macedonian patients with pheochromocytoma and paraganglioma Jovanovic Rubens, Kostadinova-Kunovska S, Janevska V, Spasevska L, Trajkov D, Petrusevska G
  28. Extended spectrum beta-lactamase (ESBL) strains of *E.coli* as a cause of urinary tract infections in hospitalized patients Gerasimovska Kitanovska Biljana, Gerasimovska V
  33. Nosocomial infection with *stentrophomonas maltophilia* as a risk in haemodialysis patients with central venous catheters Gerasimovska Vesna, Gerasimovska-Kitanovska B, Popovska –Jovanovska K
  38. Prolonged oral contraceptive therapy in female patient causing acute pulmonary thromboembolism: a case report Boshev Marjan, Otljanska M
  42. Types of atlanto-axial subluxation in patients with rheumatoid arthritis Kuchi Avni, Perchinkova Mishevska S
  49. Anomalous pulmonary venous connection (total and partial form)- single centre experience Kuzevska-Maneva Konstandina, Kacarska R, Gjorkova-Angelovska B, Jovanovska V, Neshkovska-Shumenkovska M, Maneva E
  53. Pneumococcal serotypes and their resistance to penicillin Kotevska Vesna, Cekovska Z, Mircevska G, Kaftandzieva A, Petrovska M
  60. Agents present in work environment and their association with laryngeal cancer Pavlovskа Irina, Orovcanec N, Tausanova B, Zafirova-Ivanovska B
  64. INFORMATION FOR AUTHORS
  67. **AN EXCLUSIVE STATEMENT FOR PUBLICATION**



## A RARE CASE OF ORIGIN OF THE OBTURATOR ARTERY FROM THE FEMORAL ARTERY

Djudaric Luka, Bobinac D

Department of Anatomy, School of Medicine University of Rijeka, Rijeka, Croatia

### Abstract

During the anatomical dissection of the pelvic blood vessels we found a very rare variation of the obturator vessels. The obturator artery arises from the femoral artery and the obturator vein ends in the femoral artery. Knowledge of this possibility in clinical medicine, especially in surgery is very important because the injury of the obturator artery during the surgery can cause a life-threatening consequences for the patient.

**Key words:** obturator artery, obturator vein, variation, dissection

### Introduction

The obturator artery (OA) is, according classification by Jastschinski, cited by Braithwaite, a medium calibre vessel and in a high percentage it has a variable origin [1]. It is described that the medium calibre arteries are more frequently variable than those of large calibre such as a. glutea superior and a. glutea inferior. These arteries show regularity in origin and position [1]. The OA is described in anatomical handbooks as a parietal branch from the anterior trunk of the internal iliac artery [1, 2, 3, 4]. The OA passes forward over the internal obturator muscle and through the canalis obturatorius it reaches the medial side of thigh among the adductor muscles. The OA travels with two companion veins and the obturator nerve. In the pelvic cavity, in the iliac fossa the OA provides branches for the iliac bone and muscle and for the bladder [4]. Outside the pelvis the OA gives the branches that supply ligamentum capitis femoris, the head of the femur and the adductors of the thigh. Just before that OA enters into the canalis obturatorius it gives the ramus pubicus. This branch ascends laterally on the inner surface of pubic bone and anastomoses with the pubic branch of the inferior epigastric artery. When the caliber of this anastomosis is greater than 2 mm it has clinical significance because its injury can cause a fatal bleeding and it is called corona mortis [5]. Karakurt found this anastomosis in 28.5% cases [6]. The surgeons should be aware of that possibility when they access to this area. Variations of the origin and course of the arteries are also clinically important and knowledge of those possibilities will ensure a successful approach and intervention in particular area. The origin of the OA shows many variations, of which there are numerous data in the literature [1, 2, 3]. According to the frequency, after the origin of the OA from the anterior trunk of the iliac artery is its origin by common trunk with the inferior epigastric artery from the external iliac artery and afterward the OA as direct branch of the external iliac artery. As a rarest origin of the OA back in 1836. Reid was pointed out the femoral artery [7]. Emura et al. have reported in 1989. two different cases of the OA origin out of 10 hemipelvises. In one case from the femoral artery arise two trunks; one trunk is the origin for a. profunda femoris and a. circumflexa femoris lateralis, and the second trunk gives a. circumflexa femoris medialis, a. epigastrica inferior and a. obturatoria. In the second case from the femoral artery arise a.

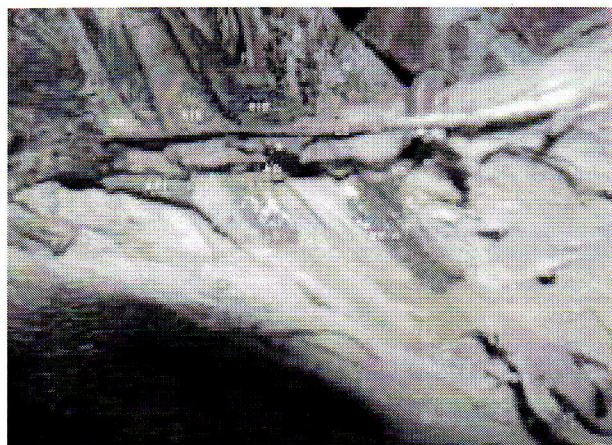
circumflexa femoris lateralis and by the common trunk a. profunda femoris, a. circumflexa femoris medialis, a. epigastrica inferior and a. obturatoria [8]. The OA always leaves the pelvic cavity trough canalis obturatorius, regardless to its origin. Likewise, in the case when originate from the femoral artery, Reid described that the OA runs toward the canalis obturatorius. In that case the OA leaves the femoral triangle and runs upward and medially and enters into the pelvic cavity below the inguinal ligament [7]. Here the OA cross the pecten pubis and by the inner surface of the pubic bone goes toward the canalis obturatorius. The position of the OA on the superior edge of the superior branch of the pubic bone is dangerous if the surgeon does not have that in mind because the injury of the OA can cause a severe consequence. Thus, injured OA can cause a consequences as well as injuries of the corona mortis. Therefore each vascular canal on that position should be called corona mortis. In the area above the branch of the pubic bone are performed numerous surgical operations (femoral hernia, osteotomies for acetabular dysplasia, ilioinguinal approach on acetabulum) or it could be a pelvic fracture and the source of hemorrhage may remain unrecognized. By this case report we want to draw attention on the OA origin from the femoral artery.

### Case report

We performed the dissection of the pelvic blood vessels (male, age 70) on formalin fixated anatomical specimen. In the right hemipelvis we found a irregular origin of the OA. During the preparation of the anterior trunk of the internal iliac artery we have not found the OA. On the inner surface of the superior branch of the pubic bone we found the artery and vein for which we, following their course, found that they are leaving the pelvic cavity trough canalis obturatorius. Therefore, we concluded that those vessels are obturator artery and vein, but with irregular origin. We continued the dissection towards the lower limb, carefully following the OA to its origin and vein to its end. We found that the OA arises from the front of the femoral artery in the upper third of the femoral triangle (Figure 1). By presenting the entire artery, we saw that it ascends medially and cross the femoral vein from the front. The OA leaves the femoral triangle trough lacuna vasorum and crossing the pecten pubis it enters to a pelvic cavity. In our case we found



only one obturator vein and it is parallel to the OA and in front of the OA. The obturator vein ends into the femoral vein from the front, at 1.5 cm lower level than is the origin of the OA. The calibre of the OA and OV is 3.5 mm. During the dissection of the blood vessels of the left part of the pelvis we found the regular anatomical pattern.



**Fig. 1.** Photography of the right side of the specimen show the femoral triangle with the origin of the obturator artery and termination of the obturator vein.

#### Legend:

NF nervus femoralis, AEI arteria epigastrica inferior, AIE arteria iliaca externa, VIE vena iliaca externa, AO arteria obturatoria, VO vena obturatoria, AF arteria femoralis, VF vena femoralis, LI ligamentum inguinale

#### Discussion

The OA as a branch of the femoral artery is a very rare anatomical variation and we consider that it is important to admonish that. Knowledge of this possibility in clinical medicine, especially in surgery is very important. The reported case that we described has double significance because there is found only one OA. The OA positioned on the upper edge of the superior branch of the pubic bone is great danger in surgery because as variation is a rare and the consequences of its injury are serious. In this area are often surgical operations of the femoral hernia, osteotomies and gynecological operations. The injury of the OA, regard to its caliber of 3.5 mm can be lethal. Since that along described OA is not present the regular OA, we can consider that the OA is aberrant. The situation when along the regular OA coexist the accessory OA is less dangerous if one of those vessels is injured than it is in our case. As a consequence of injured OA in our case the blood supply of structures which are irrigated by the OA (iliac bone and muscle, femoral head, lig. capitis femoris and adductor muscles) will be reduced. Practical importance of knowing the possibility of described anatomical relations is in those two serious aspects of consequences that will occur if the OA is injured. The surgeons must be aware of the anatomical variations,

especially of the vessels that are significant in the caliber and often are variable in the origin and topography. Therefore we consider it is very important to publish such findings.

#### References

1. Braithwaite JL. Variations in origin of the parietal branches of the internal iliac artery. *J Anat*; 1952; 86: 423-30.
2. Gilroy AM, Hermey DC, DiBenedetto LM, Marks SC, Page DW, Lei QF. Variability of the obturator vessels. *Clin Anat* 1997; 10(5):328-32.
3. Namking M, Woraputtaporn W, Buranarugsa M, Kerdkoonchorn M, Chaijarookhanarak W. Variation in origin of the obturator artery and corona mortis in Thai. *Siriraj Med J* 2007; 59(1):12-5.
4. Williams PL, Warwick R (ed.) (1973) *Gray's Anatomy*. 35th edition. Longman, London, p. 721.
5. Rusu MC, Cergan R, Marius Motoc AG, Folescu R, Pop E. Anatomical considerations on the corona mortis. *Surg Radiol Anat* 2010; 32(1):17-24.
6. Karakurt L, Karaca I, Yilmaz E, Burma O, Serin E. Corona mortis: incidence and location. *Arch Orthop Trauma Surg* 2002; 122:163-4.
7. Reid J. On the varieties of the obturator artery, and the relation of these to the femoral ring. *Edinburgh Medical and Surgical Journal* 1836; 45:65-70.
8. Emura S, Shoumura S, Ishizaki N, Yamahira T, Ito M, Chen HY, Isono H. The anatomical study on the branches of the femoral artery (II). Comparison with the findings of Adachi's classification. *Kaibogaku Zasshi* 1989; 64(3):196-205.