



IMPRESUM

NAKLADNICI

Filozofski fakultet Sveučilišta u Zagrebu, Odsjek za arheologiju
Arheološki muzej u Zagrebu

ZA NAKLADNIKE

Damir Boras, Filozofski fakultet Sveučilišta u Zagrebu
Jacqueline Balen, Arheološki muzej u Zagrebu

UREDNIŠTVO

Mirjana Sanader, Ante Rendić-Miočević, Domagoj Tončinić, Ivan Radman-Livaja

RECENZENTI

Marin Zaninović, Marina Miličević Bradač, Aleksandar Durman

OBLIKOVANJE I PRIPREMA ZA TISAK

Srećko Škrinjarić, Arheološki muzej u Zagrebu

TISAK

Tiskara Zelina d.d.

NAKLADA

500 primjeraka

Dissertationes et Monographie 7

Urednica serije: Mirjana Sanader
Prihvaćeno na Vijeću Arheološkog zavoda 31. listopada 2012.

Filozofski fakultet Sveučilišta u Zagrebu

ISBN: 978-953-175-470-5

Arheološki muzej u Zagrebu

ISBN: 978-953-6789-72-6

Izdavanje knjige financijski su poduprli:

Ministarstvo znanosti, obrazovanja i sporta Republike Hrvatske
Gradski ured za obrazovanje, kulturu i šport Grada Zagreba

Copyright © 2013

Filozofski fakultet Sveučilišta u Zagrebu, Odsjek za arheologiju
Arheološki muzej u Zagrebu

CIP zapis dostupan u računalnome katalogu Nacionalne i sveučilišne
knjižnice u Zagrebu pod brojem 844382.

Korice: Gardunski tropej (Arheološki muzej u Splitu, inv. br. D 129, foto: T. Seser, oblikovanje: S. Škrinjarić)

XVII ROMEC ZAGREB 2010



XVII ROMAN MILITARY EQUIPMENT CONFERENCE ZAGREB 2010

24TH - 27TH MAY, 2010

RADOVI XVII. ROMEC-A

Rimska vojna oprema u pogrebnom kontekstu

PROCEEDINGS OF THE XVIITH ROMAN MILITARY EQUIPMENT CONFERENCE

Weapons and Military Equipment in a Funerary Context

AKTEN DER 17. ROMAN MILITARY EQUIPMENT CONFERENCE

Militaria als Grabbeilage

M. Sanader / A. Rendić-Miočević / D. Tončinić / I. Radman-Livaja (ur.)

Zagreb, 2013.

SADRŽAJ
CONTENS
INHALT

Predgovor / Vorwort	6	Xenia Pauli Jensen		Zrinka Buljević		Sanja Ivčević	
Nenad Cambi		IMITATION AND TRANSFORMATION	177	GLASS PHALERAE IN THE	289	PROJECT TILURIUM	435
ROMAN MILITARY TROPAEA FROM DALMATIA	9	- ROMAN MILITARIA IN SOUTH		ROMAN PROVINCE OF DALMATIA		- ROMAN MILITARY EQUIPMENT	
Janka Istenič		SCANDINAVIAN GRAVE FINDS		Sanja Ivčević		Tomislav Šeparović / Ana Pavlović	
EARLY ROMAN GRAVES WITH WEAPONS IN	23	Thomas Grane		FIRST-CENTURY MILITARY GEAR	299	PROJECT TILURIUM - COIN FINDS	455
SLOVENIA: AN OVERVIEW		A LATE ROMAN MILITARY BELT FROM	185	FROM SALONA		Zrinka Buljević	
Achim Rost / Susanne Wilbers-Rost		ZEALAND?		Stefanie Hoss		PROJECT TILURIUM - GLASS FINDINGS	463
BESTATTUNGEN AUF DEM SCHLACHTFELD	37	† Vesna Girardi Jurkić		A THEORETICAL APPROACH TO	317	Zrinka Šimić-Kanaet	
VON KALKRIESE		WEAPONS IN THE LATE ANTIQUE AND	193	ROMAN MILITARY BELTS		PROJECT TILURIUM - ROMAN POTTERY	471
Torsten Kleinschmidt		BARBARISED GRAVES OF ISTRIA (CROATIA)		Ildar Kayumov / Alexander Minchev		FROM TILURIUM	
VETERANEN ODER "ZIVILISTEN"?	49	Tino Leleković		THE <i>KAMBEΣTPION</i> AND OTHER ROMAN	327	Mirjana Sanader / Marina Miličević Bradač	
FRÜHKAISERZEITLICHE WAFFENGRÄBER IM		IS IT A BATTLE KNIFE? THE PROBLEMS OF	207	MILITARY EQUIPMENT FROM THRACIA		/ Dino Demicheli	
TREVERERGEBIET		INTERPRETATION OF THE ROMAN KNIFE		Mario Novak		PROJECT TILURIUM - A "POET" IN THE	483
Annelies Koster		FROM SISCIA (SE CEMETERY)		TAVERN BRAWLS, BANDITRY AND BATTLES -	347	MILITARY CAMP AT TILURIUM	
WEAPONS IN A LATE 1 ST CENTURY GRAVE IN	77	Bartosz Kontny		WEAPON INJURIES IN ROMAN IADER		Domagoj Tončinić / Sanja Ivčević	
NIJMEGEN (NL)		OUTSIDE INFLUENCE OR LOCAL	215	Martin Lemke		DAS PROJEKT TILURIUM -	493
Zsolt Mráv		DEVELOPMENT? SEAXES FROM THE		STONE PROJECTILES DISCOVERED	357	WAFFENDARSTELLUNGEN AUF	
GRAVES OF AUXILIARY SOLDIERS AND	87	CEMETERIES OF THE BALT TRIBES IN		IN THE <i>CASTR</i> <i>LEGIONIS NOVAE</i>		GRABSTELN AUS TILURIUM	
VETERANS FROM THE FIRST CENTURY AD		NORTHERN POLAND (THE ELBLĄG GROUP)		NEAR SVISHTOV (BG)		Ivana Jadrić-Kučan / Igor Borzić	
IN THE NORTHERN PART OF PANNONIA		Doina Benea		Suzana Matešić		STAKLO PUHANO U KALUP IZ BURNUMA	517
Nemanja Mrđić / Angelina Raičković		RÖMISCHE MILITÄRGRÄBER IN DACIA	235	RÖMISCHE HELME AUS DEM	365	Igor Borzić / Ivana Jadrić-Kučan	
SOLDIERS BURIALS WITH WEAPONS AT	117	SUPERIOR		THORSBERGER MOOR		OPSKRBA HRANOM U RIMSKOM LEGIJSKOM	523
VIMINACIUM CEMETERY		Asja Tonc / Ivan Radman-Livaja / Marko Dizdar		Annette Frölich		LOGORU U BURNUMU - ANALIZA AMFORA	
Miomir Korać / Snežana Golubović		THE WARRIOR GRAVE FROM SVETA TROJICA	245	IRON AGE MEDICAL INSTRUMENT CASES	371	Mladen Jovičić	
KNIVES AND DAGGERS IN GRAVES FROM	133	NEAR STARIGRAD PAKLENICA		EXCAVATED IN DENMARK. FIRST-AID		CULT OF JUPITER DOLICHENUS ALONG THE	537
VIMINACIUM		Branka Migotti		EQUIPMENT FOR WOUND-CLOSING,		SERBIAN PART OF THE LIMES IN MOESIA	
Gerda von Bülow		CAN SOLDIERS ON 3 RD -CENTURY STELAE IN	259	EXCAVATED FROM A DANISH OFFERING BOG		SUPERIOR AND PANNONIA INFERIOR	
ROMULIANA-GAMZIGRAD IN DER PROVINZ	151	PANONNIA BE RECOGNIZED ONLY BY THE		AND FROM A FEMALE GRAVE		Igor Vukmanić	
DACIA RIPENSIS -EIN NEU ENTDECKTES		SAGUM?		Boštjan Laharnar		THE DANUBE LIMES IN CROATIA - LIMES	549
WAFFENGRAB		Kristina Džin		EARLY ROMAN MILITARY EQUIPMENT	379	OFFICE ACTIVITIES 2008-2010	
Katarzyna Czarnecka		REPRESENTATIONS OF WEAPONS ON THE	273	FROM THE FORTIFIED SETTLEMENTS IN THE		Program / Program / Programm	555
WARRIORS IN THIS WORLD	163	ARCH OF THE SERGIJ IN PULA, THE SERGIJ'S		NOTRANJSKA REGION (SW SLOVENIA)		Popis sudionika / Praticipants / Teilnehmer	558
AND THE AFTERLIFE PRZEWORSK CULTURE		LAST RESTING PLACE		Ivan Bogdanović			
GRAVES CONTAINING WEAPONS				ROMAN STONE AND CLAY SHOT FROM	393		
				VIMINACIUM AMPHITHEATRE			
				Mirjana Sanader / Domagoj Tončinić			
				DAS PROJEKT TILURIUM	411		

Mario Novak

TAVERN BRAWLS, BANDITRY AND BATTLES - WEAPON INJURIES IN ROMAN IADER

Mario Novak
Hrvatska akademija znanosti i umjetnosti
Odsjek za arheologiju
Ante Kovačića 5
HR-10000 Zagreb
CROATIA
mnovak@hazu.hr

RIMSKA VOJNA OPREMA U POGREBNOM KONTEKSTU · WEAPONS AND MILITARY EQUIPMENT IN A FUNERARY CONTEXT · MILITARIA ALS GRABBEILAGE

INTRODUCTION

Bone injuries have been one of the most studied pathological conditions in archaeological samples, as well as one of the most reliable indicators of living conditions of past populations¹.

Unfortunately, despite the increased interest in bioarchaeological research of Croatian skeletal samples in recent years, bone injuries have rarely been the primary object of bioarchaeological analysis. So far, only three papers² predominantly address the issue of bone trauma in Croatian archaeological populations. The lack of weapon-injury studies in Croatian bioarchaeology prompted the anthropologists working at the Department of Archaeology of the Croatian Academy of Sciences and Arts in Zagreb to carry out a comprehensive analysis of the frequency and distribution of weapon-related skeletal injuries in the Roman period skeletal sample from Zadar which is presented in this paper.

¹ GRAUER - ROBERTS 1996; DJURIĆ et al., 2006.

² ŠLAUS - NOVAK 2006; NOVAK - ŠLAUS 2010; ŠLAUS et al., 2010.

MATERIAL AND METHODS

The modern city of Zadar is situated on the eastern Adriatic coast in contemporary Croatia. The settlement was founded as a Roman veteran colony (Colonia Iulia Iader) in 48 BC, most likely by Caesar himself³. During the Roman period it was one of the largest urban settlements in the Roman province of Dalmatia - estimates of the size of Zadar's population during the early Empire range between 4 and 10,000 while the number of inhabitants during the 4th century is estimated to be between 20 and 40,000⁴.

Because of urban reconstructions in the Zadar area during the last two decades, a rescue excavation of a Roman necropolis consisting of more than 2,000 skeletal and incinerated graves was carried out in 1989/1990 and 2005/2006 in the Relja city district (Fig. 1). The excavations were coordinated by the archaeologists from the Archaeological museum in Zadar. Graves are dated between the 1st and 6th centuries

³ SUIĆ 2003.

⁴ NEDVED 1992; PERIČIĆ 1999; SUIĆ 2003; GRAOVAC 2004.



Fig. 1. Map of the modern city of Zadar with marked position of the Relja necropolis. The Roman Iader was situated on the peninsula to the west.

AD based on grave goods and horizontal stratigraphy⁵. Of eight skeletons that exhibited weapon injuries five were simple inhumations in plain ground (gr. 18, 135, 269, 295, 719), one inhumation covered with *tegulae* (gr. 661), one inhumation in amphora (gr. 598) (Fig. 2), and one inhumation in grave vault (gr. 378) - these burials are dated between the 2nd and 6th c. AD⁶. The majority of skeletal burials from this site were damaged postmortem by later inhumations and construction activities; the preservation of the skeletons ranges between good and excellent.

⁵ BRUSIĆ - GLUŠČEVIĆ 1990; FADIĆ 2007.

⁶ GLUŠČEVIĆ - ALIHODŽIĆ, personal communication. I would like to thank Smiljan Gluščević and Timka Alihodžić from the Archaeological Museum in Zadar for providing the archaeological data for the graves containing the individuals with weapon injuries from the Zadar-Relja site.

The sex and age-at-death of the recovered individuals were determined at the osteological laboratory of the Croatian Academy of Sciences and Arts in Zagreb, based on methods described in Buikstra and Ubelaker⁷. Some bioarchaeological aspects of the Roman period population from Zadar, such as frequencies and distribution of bone fractures and indicators of subadult stress, have already been published⁸. The actual Roman weapons used in possible reconstructions during forensic analyses were borrowed from the Archaeological museum in Zagreb⁹.

⁷ BUIKSTRA - UBELAKER 1994.

⁸ NOVAK - ŠLAUS 2010a, 2010b.

⁹ I would like to thank Ivan Radman Livaja from the Archaeological Museum in Zagreb for valuable advices and for enabling me the use of Roman weaponry for the purpose of forensic analyses.

CASES OF WEAPON INJURIES IN IADER

Among the 641 individuals from the Zadar-Relja site eight skeletons (all males) exhibit weapon-induced injuries: sharp force lesions and projectile injuries. All recorded bone trauma are located in two main body regions: cranium and lower extremities.

Of the eight skeletons with weapon injuries three skeletons exhibit antemortem trauma, while five skeletons exhibit perimortem trauma:

1) TC Relja, 1989/1990, grave 598 - male, between 31 and 40 years. An antemortem healed cut, 4 mm in length, is present on the frontal bone, superior of nasion. The lesion was inflicted by a sharp-edged weapon (long-bladed knife or sword).

2) TC Relja, 1989/1990, grave 661 - male, between 41 and 45 years. A perimortem penetrative trauma, 10x7 mm in size, is present on the left parietal bone (Fig. 3); a cone-shaped defect, 25x16 mm in size, is present on the endocranial side of the skull (Fig. 4). It was most probably inflicted by a projectile (arrowhead).

3) TC Relja, 1989/1990, grave 719 - male, between 36 and 45 years. Two antemortem healed cuts are located on the cranium: 1) an elongated cut, 30 mm in length, is present on the left parietal bone; 2) an elongated cut, 36 mm in length, is present on the left parietal bone, inferior of the first trauma (Fig. 5). Both wounds were inflicted by a sharp-edged weapon (sword).

4) TC Relja, 2005/2006, grave 378B - male, between 36 and 40 years. A massive perimortem cut, 95 mm in length, is present on the left parietal bone and the occipital bone (Fig. 6). The wound was inflicted by a sword penetrating deep into the cranial vault.

5) Relja-Vrt, 2005/2006, grave 18 - male, between 41 and 50 years. An antemortem healed cut, 32 mm in length, is present on the left parietal bone. It was inflicted by a sharp-edged weapon (long-bladed knife or sword).

6) Relja-Vrt, 2005/2006, grave 135 - male, between 31 and 40 years. Perimortem cut, 14x12 mm in size, is present on the medial side of the proximal third of the right femur (Fig. 7). The wound was inflicted by a sharp-edged weapon (sword).

7) Relja-Vrt, 2005/2006, grave 269 - male, around 50 years. Two perimortem cuts are located on the cranium: 1) a tangential cut, 43x21 mm in size, is present

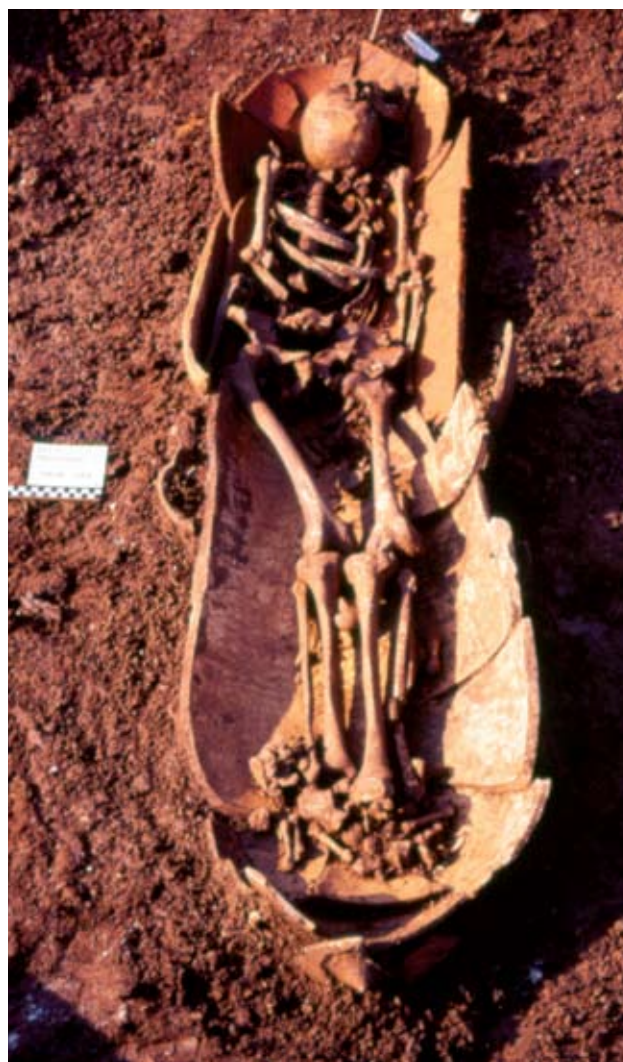

Fig. 2. Zadar-TC Relja, grave 598, burial in amphora. Photo published with permission of Archaeological Museum in Zadar.

on the right parietal bone (Fig. 8); 2) a 39 mm long cut is present on the left parietal bone, penetrating into the cranial vault (Fig. 9). Both wounds were inflicted by a sword.

8) Relja-Vrt, 2005/2006, grave 295 - male, between 31 and 35 years. Perimortem cut, 16x13 mm in size, is present on the antero-medial side of the proximal third of the right femur (Fig. 10). The wound was inflicted by a sword.




Fig. 3. Perimortem trauma on the left parietal bone inflicted by a projectile. Ectocranial side of the skull. TC Relja, 1989/1990, grave 661, male, between 41 and 45 years.



Fig. 4. Endocranial 'cone' shaped defect inflicted by a projectile. TC Relja, 1989/1990, grave 661, male, between 41 and 45 years.

DISCUSSION

The written sources and archaeological artefacts that testify of deliberate violence in the Roman period Iader are scarce. According to historic sources, the province of Dalmatia was peaceful and prosperous province until the 3rd century when the global crisis that engulfed the Roman Empire also reflected on Zadar and Dalmatia. The city was not directly threatened but the military anarchy and internal unrest in the Empire endangered economy and trade while land and sea routes were unsafe for traffic¹⁰. During the Visigoth invasion in 378 northern Dalmatia and Iader were not affected by the devastations, at least according to the written sources and archaeological remains. The only document that mentions devastations brought by the barbarian tribes in Dalmatia is the St. Jerome's letter to Heliodorus¹¹. In 452, during the Hunnish incursion the region around Zadar was again spared, and when the Ostrogoths conquered Zadar and Dalmatia in 480 AD they let the local population to live in their faith and by their traditions¹². Additionally, archaeological artefacts indicating occurrence of deliberate violence in Iader are very rare - at the Relja necropolis only one spear tip and three javelin heads were found¹³.

The general lack of written sources and archaeological artefacts concerning interpersonal violence may indicate that occurrence of deliberate violence in Iader was infrequent. It is possible, even probable, that

numerous violent episodes such as cases of banditry along the roads or minor armed clashes were never recorded by historic sources. However, the presence of eight skeletons exhibiting ante- and perimortem bone trauma inflicted by some kind of weapon strongly suggest increased levels of interpersonal violence. In order to get a better picture concerning the deliberate violence associated with the use of cold weapons in Iader a possible reconstruction of these violent events was conducted using the authentic Roman weaponry. During the reconstruction an attempt was made to discern whether the recorded injuries resulted from the violent episodes of a larger scale or violence of lesser intensity, based on the location and morphology of the trauma, type of the weapon used and the direction from which the wound was induced.

Individual buried in grave 378B beside the massive perimortem trauma to the left side of the cranium exhibits multiple injuries of the ribs (three healed fractures of the 7th, 8th and 9th left ribs) and two antemortem blunt force fractures on the left side of the skull. Taking into consideration the sex and age of the individual, as well as the presence of multiple injuries, one can presume that the individual was a soldier. Unfortunately, there are no archaeological artefacts or epigraphic monuments to verify this hypothesis. Judging by the size and morphology of the perimortem trauma it was inflicted by a Roman *spatha* - a long sword characteristic of the middle and late Roman Empire (in general use in the Roman cavalry from the 1st century AD, and in the infantry since late 2nd or early 3rd century AD¹⁴). For the

¹⁰ SUIĆ 2003.

¹¹ SUIĆ 2003.

¹² SUIĆ 2003.

¹³ GLUŠČEVIĆ - ALIHODŽIĆ, personal communication.

¹⁴ STEPHENSON 2001; BISHOP - COULSTON 2006.



Fig. 5. Two antemortem cuts on the left parietal bone. TC Relja, 1989/1990, grave 719, male, between 36 and 45 years.

purpose of a reconstruction a *spatha* of the Lauriacum-Hromowka type (Siscia, 3rd c. AD) was used (Fig. 11). The blow to the head was of such intensity that it almost detached left side (left parietal bone, and part of the occipital bone) from the rest of the cranium. Such injuries sustained during a battle are well known from historic sources like the Ammianus' Marcellinus¹⁵ description of the siege of Amida in 359 '...and that in front of me a soldier with his head cut in two, and split into equal halves by a powerful sword stroke, was so pressed on all sides that he stood erect like a stump'. In this particular case the blow came from behind of the attacked individual, judging by the position and the angle of the sword (Fig. 12), and it may be presumed that the individual was running away. When all the facts are summarised, the most feasible explanation would be that the individual buried in grave 378B was a soldier killed at a battlefield by a powerful sword blow to the head, most probably trying to escape from the attacker(s). After his death, the individual's body was brought to Zadar where it was buried properly according to the custom at the Relja necropolis. Such scenario was already proposed by Golubović et al.¹⁶ in case of the adult male skeleton from grave 152 in Viminacium.

Two cases of perimortem cuts on the proximal thirds of the right femurs (graves 135 and 295) most probably are a result of a sword attack, probably *spatha*, during a battle, with a goal of severing the femoral artery and quickly killing the opponent. The inner thigh is one of the most desirable places on a human body

¹⁵ Ammianus Marcellinus 18.8.12.

¹⁶ GOLUBOVIĆ et al., 2010.



Fig. 6. A massive perimortem cut on the left side of the skull. TC Relja, 2005/2006, grave 378B, male, between 36 and 40 years.

for the attacker because the sword cut to the femoral artery results in an almost instant death (less than five minutes) due to a massive blood loss (Fig. 13). Considering that the vast majority of the population is right-handed, an attacker would strike with a sword in his right hand aiming for the right femoral artery of the opposing individual, especially if the victim is wearing helmet and upper-body armour. When sex and age of the two individuals exhibiting perimortem cuts are taken into consideration (males aged between 31 and 40 years), as well as the location of bone injuries and the weapons used it may be presumed, as in the case of individual from grave 378B, that both of these individuals were soldiers who died during battle and were brought and buried in Zadar.

Based on the position and morphology of the cranial injuries recorded on male skeleton from grave 269 it may be presumed that the first, non-lethal, strike was inflicted from an elevated position, probably by a horseman carrying a *spatha*. The horseman was situated behind the victim who was trying to run away from the attacker (Fig. 14). After the victim fell to the ground, the second blow that penetrated deep into the skull instantly killed him. This individual might represent a victim of banditry or a similar violent act, rather than a soldier who died on a battlefield, because of his age. Namely, this person is much older (around 50 years) than the other individuals from Iader with weapon injuries that were presumed soldiers. According to Scheidel¹⁷ during the Principate approximately two-thirds of all legionaries enlisted between ages sev-

¹⁷ SCHEIDEL 2007.

¹⁸ MACMULLEN 1966.



Fig. 7. Perimortem cut on the proximal third of the right femur. Relja-Vrt, 2005/2006, grave 135, male, between 31 and 40 years.



Fig. 8. A tangential perimortem cut on the right parietal bone. Relja-Vrt, 2005/2006, grave 269, male, around 50 years.



Fig. 9. Perimortem cut on the left parietal bone. Relja-Vrt, 2005/2006, grave 269, male, around 50 years.

enteen and twenty, and more than half of all recruits would not complete a full term of active duty due to violent deaths, camp-related diseases etc. If majority of those recruits who survived twenty-five years of military service enlisted around age of twenty, it may be presumed that they retired around age of forty five. Therefore, it is unlikely that the individual in question was an active soldier who died in battle, but it is more likely that this male was attacked from an ambush, possibly by bandits (*latrones*) somewhere along the road. Banditry in the Roman Empire was sparse in the 1st century, gradually increased in the 2nd century until it grew virtually out of control in the later Empire¹⁸. Banditry combined with violence most often occurred in rural areas, along the roads, as opposed to towns and villages¹⁹. Blummell²⁰ states that 'Bandits posed escalating dangers to the traveller that ranged from highway robbery, which was usually accompanied by violence...or in a worst-case scenario to robbery accompanied by murder'. Numerous inscriptions reveal that deaths due to bandits were a common enough occurrence to give rise to the expression *interfectus a latronibus* ('killed by bandits') and are found on tombstones throughout the Empire²¹, even in the province of Dalmatia²². Of course, banditry is only one of the possible scenarios, but according to the skeletal injuries recorded it is certain that during the last moments of his life this individual unsuccessfully tried to run away from the attacker who was trying to kill him.

It is possible that a similar violent act occurred in the case of a skeleton from grave 661. This individual died from the trauma to the posterior left side of the cranium most probably inflicted by an arrow. A possible reconstruction implies that the attacker was standing behind the victim on the left side. The victim was most probably unaware of the danger strongly suggesting some kind of ambush - an arrow penetrated the skull and caused an instant death (Fig. 15). The shape and dimension of the lesion suggest the use of a bodkin tanged arrowhead (Fig. 16 and 17). It was suggested by Stephenson²³ that this type of arrowheads was used for armour piercing. In this case it is not possible to reconstruct all the details regarding the last moments of this individual, but it is certain that he fell a victim of an ambush, unaware of the attack, whether as a soldier on the battlefield or as a prey to the bandits somewhere along the road.

¹⁹ BLUMELL 2007.

²⁰ BLUMELL 2007.

²¹ BLUMELL 2007.

²² ILS 5112.

²³ STEPHENSON 2001.

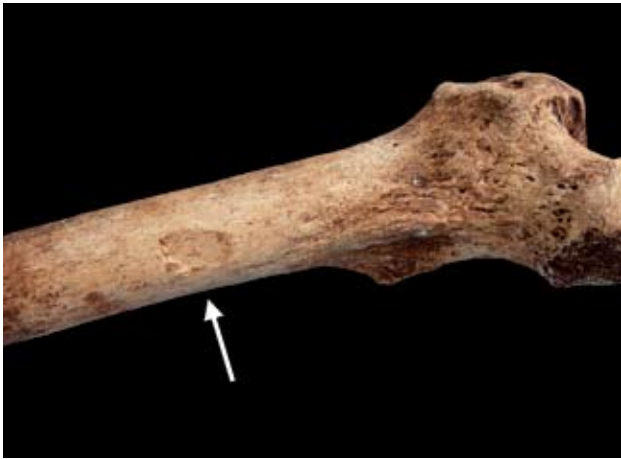

Fig. 10. Perimortem cut on the proximal third of the right femur. Relja-Vrt, 2005/2006, grave 295, male, between 31 and 35 years.



Fig. 11. Roman spatha of the Lauriacum-Hromowka type from Siscia (3rd c. AD). Archaeological Museum in Zagreb.




Fig. 12. A reconstruction of the direction and the intensity of a sword strike using the spatha of the Lauriacum-Hromowka type and the skull belonging to the male from grave 598.

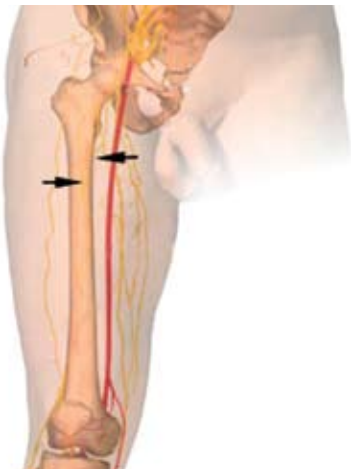

Fig. 13. A schematic image of the right leg with the position of the femoral artery and marked positions of perimortem cuts recorded on skeletons from graves 135 and 295.



Fig. 14. A possible reconstruction of the first, non-lethal cut (after ŠLAUS 2006).

The skeletons buried in graves 18, 598 and 719 share some common characteristics regarding the injuries. Firstly, all trauma were induced by sharp-bladed weapons, such as long-bladed knives or swords; secondly, all three individuals survived the violence in which these injuries occurred; thirdly, the trauma on all three skeletons are of much smaller dimensions and intensity compared to the injuries in other individuals from Iader (e.g. graves 269 and 378B). Based on these characteristics it may be hypothesised that the individuals with small and healed cranial cuts possibly participated in violent episodes of lesser intensity such as tavern brawls or street fights with occasional use of sharp edged weapons. In this type of deliberate violence it is not the aim of the attacker to permanently disable, i.e. to kill the opponent, but to scare or humiliate him. Of course, this scenario may be wrong, but the morphology and size of the recorded injuries as well as the absence of other bone trauma on these skeletons offer only one solution.

The total frequency of violent deaths (taking into account only injuries macroscopically visible on bones) in Iader is 0.8% - five out of 641 skeletons exhibit perimortem bone injuries. On the other hand, in an antique period composite skeletal sample from Croatia (Štrbinci, Zmajevac, Osijek, Vinkovci, Vid, and Kaštel Sućurac) only two out of 657 individuals exhibit perimortem bone trauma - the frequency of violent deaths in composite sample is 0.3%. The question is why is the rate of violent deaths in Iader three times higher compared to the other Roman period sites from Croatia? Unfortunately, the current state of research of this subject does not provide a satisfactory solution. The need for more multidisciplinary studies involving physical anthropologists, archaeologists, historians and experts in Roman warfare has to be emphasised if we are to answer this question. Nevertheless, it is certain that the actual rate of violent deaths in both cases is underestimated and was probably much higher because skeletal injuries represent no more than 40% of all injuries acquired during assaults²⁴, i.e. most of the fatal injuries inflicted by some kind of a weapon in archaeological as well in modern populations are soft tissue trauma not visible on bones.

²⁴ JUDD 2008.

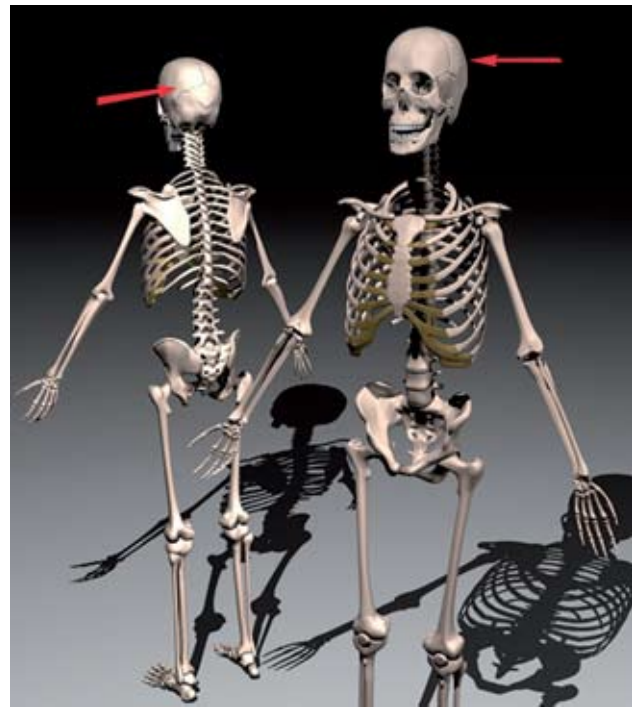


Fig. 15. A reconstruction of direction of the arrow impact, suggesting an ambush (illustration of a skeleton taken from www.3-d-models.com/3d-model_files/380m819.htm).

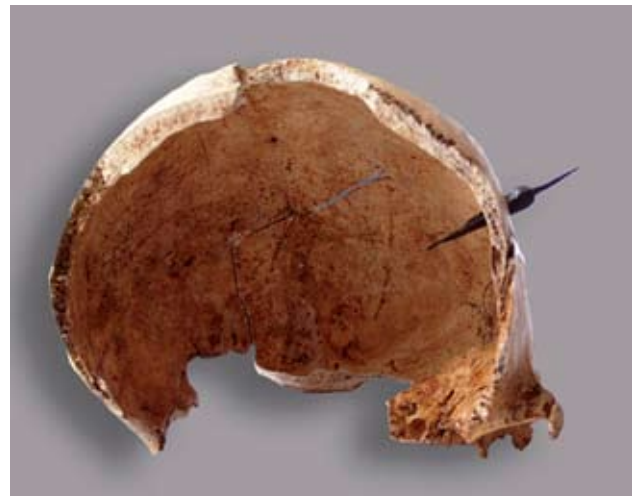


Fig. 16. A bodkin tanged arrowhead penetrating deep into the skull, frontal view, a reconstruction. Archaeological Museum in Zagreb.

CONCLUSION

After the detailed forensic analysis of the weapon-related trauma in the Iader skeletal sample and the possible reconstruction of the events in which these injuries were sustained it may be concluded that the risk of deliberate violence in Iader between the 2nd and 6th century was extraordinary high.

The anthropological analysis conducted on 641 skeletons revealed eight adult males exhibiting ante- and perimortem bone injuries inflicted by some kind of a weapon. The forensic analysis indicates that two types of weapons were used: sharp-edged weapons (swords such as *spathae* and/or long-bladed knives) and projectiles (arrows). Head and proximal parts of lower extremities are the two body regions that were the primary targets of attacks. According to the location and morphology of the injuries, the intensity of the blows and the types of weapons used, the hypothesis was made that the victims were soldiers and civilians alike. The events in which these individuals were attacked most probably include violent episodes of large scale violence such as armed battles as well as violent events of lesser intensity such as cases of banditry or tavern brawls.

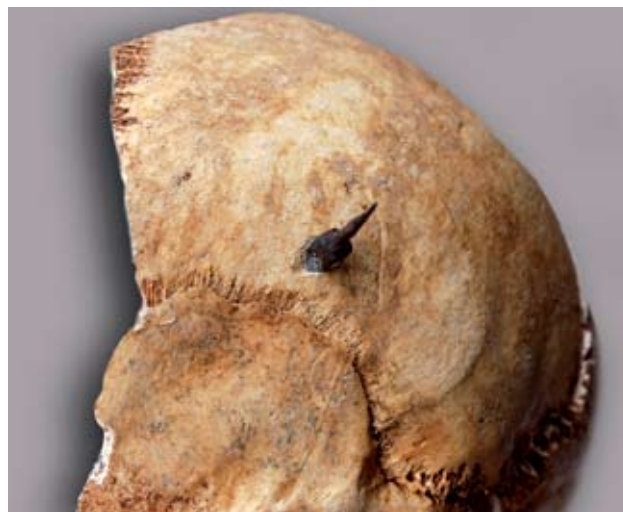

Fig. 17. A bodkin tanged arrowhead penetrating into the skull, lateral view, a reconstruction. Archaeological Museum in Zagreb.

BIBLIOGRAPHY

- BLUMELL 2007: L. H. Blumell, Beware of Bandits!: Banditry and Land Travel in the Roman Empire, *Journeys* 8, 2007, 1-20.
- BRUSIĆ - GLUŠČEVIĆ 1990: Z. Brusić - S. Gluščević, Zadar: istraživanje antičkog grada mrtvih, Zagreb, 1990.
- BUIKSTRA - UBELAKER 1994: J. E. Buikstra - D. H. Ubelaker, Standards for data collection from human skeletal remains, Fayetteville, 1994.
- BISHOP - COULSTON 2006: M. C. Bishop - J. C. N. Coulston, Roman Military Equipment: From the Punic Wars to the Fall of Rome, Oxford, 2006.
- DJURIĆ - ROBERTS - RAKOČEVIĆ - DJONIĆ - LEŠIĆ 2006: M. P. Djurić - C. A. Roberts - Z. B. Rakočević - D. D. Djonić - A. R. Lešić, Fractures in Late Medieval skeletal populations from Serbia, *American Journal of Physical Anthropology* 130, 2006, 167-178.
- FADIĆ 2007: I. Fadić, Nadgrobni tituli Petronije Urse i Emilija Atacina iz antičkog groba u Zadru, *Opuscula Archaeologica* 31, 2007, 165-182.
- GOLUBOVIĆ - MRDJIC - SPEAL 2010: S. Golubović - N. Mrdjić - C. S. Speal, Killed by the arrow: grave No. 152 from Viminacium. In: H. J. SCHALLES - A. BUSCH (eds.), *Waffen in Aktion. Akten der 16. International Roman Military Equipment Conference (ROMEC) 2007*, Xantener Berichte 16, 2010, 55-63.
- GRAOVAC 2004: V. Graovac, Populacijski razvoj Zadra, *Geoadria* 9, 2004, 51-72.
- GRAUER - ROBERTS 1996: A. L. Grauer - C. A. Roberts, Paleoepidemiology, healing and possible treatment of trauma in a medieval cemetery population of St. Helen-on-the-Walls, York, England, *American Journal of Physical Anthropology* 100, 1996, 531-544.
- JUDD 2008: M.A. Judd, The parry problem, *Journal of Archaeological Science* 35, 2008, 1658-1666.
- MACMULLEN 1966: R. MacMullen, *Enemies of the Roman Order: Treason, Unrest, and Alienation in the Empire*, Cambridge, 1966.
- NEDVED 1992: B. Nedved, Stanovništvo Zadra od 1. do 3. stoljeća (1. dio), *Diadora* 14, 1992, 109-264.
- NOVAK - ŠLAUS 2010a: M. Novak - M. Šlaus, Bone traumas in Late Antique populations from Croatia, *Collegium Antropologicum* 34, 2010, 1239-1248.
- NOVAK - ŠLAUS 2010b: M. Novak - M. Šlaus, Health and disease in a Roman walled city: an example of Colonia Iulia Iader, *Journal of Anthropological Sciences* 88, 2010, 189-206.
- PERIČIĆ 1999: Š. Peričić, *Razvitak gospodarstva Zadra i okolice u prošlosti*, Zagreb - Zadar, 1999.
- SCHEIDEL 2007: W. Scheidel, Marriage, families, and survival in the Roman imperial army: demographic aspects. In: P. ERDKAMP (ed.), *Companion to the Roman Army*, Oxford, 2007, 417-434.
- STEPHENSON 2001: I. P. Stephenson, *Roman Infantry Equipment: The Later Empire*, Stroud, 2001.
- SUIĆ 2003: M. Suić, *Antički grad na istočnom Jadranu*, Zagreb, 2003.
- ŠLAUS - NOVAK 2006: M. Šlaus - M. Novak, An analysis of traumas in medieval samples from Kliškovac and Crkvari, *Prilozi Instituta za arheologiju u Zagrebu* 23, 2006, 213-228.
- ŠLAUS - NOVAK - VYROUBAL - BEDIĆ 2010: M. Šlaus - M. Novak - V. Vyroubal - Ž. Bedić, The harsh life on the 15th century Croatia-Ottoman empire military border: Analyzing and identifying the reasons for the massacre in Čepin, *American Journal of Physical Anthropology* 141, 2010, 358-372.