

# Clinical Cases of Soft-Tissue Surgery with X-Runner in QSP Mode

**Dragana Gabric Panduric, Davor Katanec, Irina Filipovic Zore**  
*Department of Oral Surgery, School of Dental Medicine, University of Zagreb, Croatia*

## ABSTRACT

Many oral tissue pathologies and healthy oral soft tissues require special treatments. This report presents the use of the Er:YAG laser with an X-Runner handpiece in QSP mode for three different clinical situations: leukoplakia removal, implant exposure during the second stage of implant placement, and a hyperpigmentation treatment. In each case, the treatment was based on the principle of laser ablation, with excellent coagulation and precision. Automatic guidance of the laser beam allowed higher repetitions to be used, and consequently the procedures were completed faster. After the treatments, a perfect healing process, with no recurrence of the lesion or other potential complications, was observed. Faster healing significantly shortened the prosthetic reconstruction time.

*Article: J. LA&HA, Vol. 2013, No.2; pp.34-37.*

*Received: December 11, 2013; Accepted: December 18, 2013*

© Laser and Health Academy. All rights reserved.  
Printed in Europe. [www.laserandhealth.com](http://www.laserandhealth.com)

## I. INTRODUCTION

There are many situations in oral surgery that require the removal of pathological, changed or healthy soft tissue. In the case of oral lesions, some lesions require treatment but others don't. Either there is a tendency of malignant transformation, or an aesthetic problem for a patient, or else a lesion can represent a functional problem for the patient. Treatment for oral lesions may include antibiotics or a change of lifestyle for some lesions and medications for others. Additional treatment may include surgical excision, cryosurgery or laser ablation and excision to remove an oral lesion [1]. There are certain limitations with every treatment modality. Besides recurrences as a post-surgical limitation, there are significant differences also between surgical excisions. Classical excision with a scalpel is made under local or general anesthesia, depending on the size of the lesion and the general health of the patient. If a bigger excision is made, there will be a mucosal defect that needs to be covered by a mucosal graft. This represents quite a demanding surgical intervention; the overall treatment

becomes invasive, long-lasting, and the post-operative period can become quite long [2].

Hyperpigmentation of the gingiva is caused by melanin pigmentation as a result of melanin granules produced by melanoblasts intertwined between epithelia cells at the basal layer of gingival epithelium. The degree and size may vary from one individual to another, but in most cases it represents an aesthetic problem [3]. There are some treatment methods reported, such as gingival abrasion and scalpel, with variable results [4].

The second stage of an implant procedure requires the exposure of the implant. Classically it is performed with a scalpel, causing bleeding and an open-wound risk of infection and discomfort for the patient. It requires a certain time for healing before the next step can be performed, which means delayed time for prosthetic reconstruction [5].

Lasers have been studied as high potential surgical tools due to their coagulative properties and reduced oedema and pain [6]. Especially the Er:YAG laser (the most highly absorbed laser in water) appears to be a very promising tool for excision and ablation in the oral cavity. The principle of ablation is completely the same, whether for oral lesion removal, gum hyperpigmentation removal or the ablation of healthy soft tissue as a necessary step in the treatment process (as in the second stage of implant surgery).

Since the width or "operating point" of the laser beam, as typically defined by laser manufacturers, is of a dimension of 1 mm or less, the laser usually operates like a classical surgical tool. Therefore, treatment that require a larger area to be covered require very precise handpiece movements by the operator.

Recently, there has been a completely new laser treatment method available that involves the use of a digitally controlled dental laser handpiece. It provides the possibility to guide the Er:YAG laser beam automatically in the required shape and dimension. Such precise coverage of large areas is highly appreciated by surgeons and dentists.

## II. CASES

### a) Leukoplakia

A 30-year-old female patient with leukoplakia on the tongue (Figure 1) was referred to the Department of Oral Surgery, School of Dental Medicine at the University of Zagreb. The leukoplakia lesion was located on the left side of the tongue, in a size of 7 mm x 4 mm. An Er:YAG laser (LightWalker AT, Fotona, Slovenia) with a non-contact X-Runner digitally controlled handpiece was used for ablation of the lesion. The laser settings were as follows: pulse energy 120 mJ, pulse mode QSP, frequency 20 Hz. A rectangular shape in the dimensions of 4 mm x 4 mm with the X-Runner handpiece was selected according to the lesion shape and size. The handpiece was held at a distance of 15 mm from the lesion surface and the water spray level was set to 10 ml/min. The X-Runner handpiece was held in position to cover half of the leukoplakia, the pilot beam marked out the treatment area, and the ablation was started. After a complete removal of half of the leukoplakia, the ablation of the other half was done. The treatment lasted only 2 minutes because the laser beam covered the entire lesion automatically. There were eight X-Runner passes necessary to ablate the lesion completely. During the procedure, the operational field was wiped with sterile gauze soaked in 1% normal saline solution and covered with Miradont gel (Hager Werken) to promote healing. There was a complete absence of bleeding and no visual observation of any thermal effects (Figure 2). No analgesic was prescribed. Eight days after the treatment, no reoccurrence of the lesion or other potential complications were observed (Figure 3).

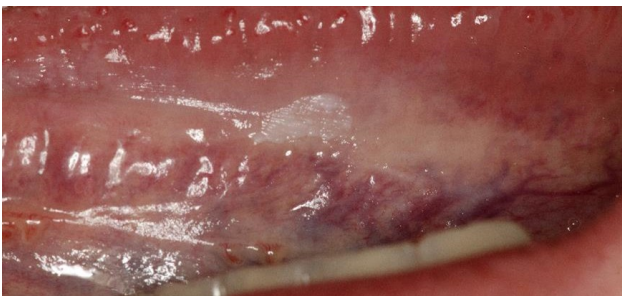


Fig. 1: Lingual Leukoplakia – before

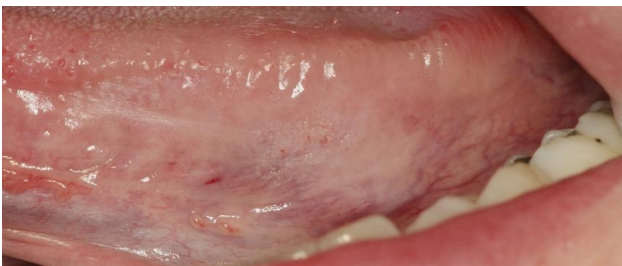


Fig. 2: Lingual Leukoplakia – immediately after the treatment with X-Runner

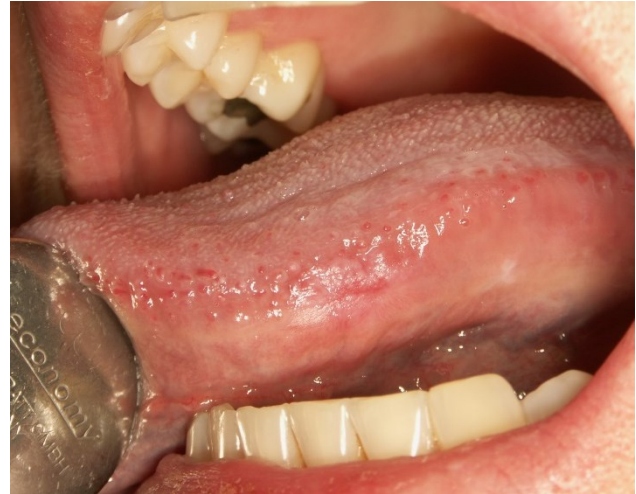

Fig. 3: Lingual Leukoplakia – 8 days after the treatment with X-Runner

### b) Implant exposure

A 56-year-old female came for the second stage of implant placement: implant exposure. The first implant of the upper arch was exposed by scalpel and the second with an Er:YAG laser (LightWalker AT, Fotona, Slovenia) with a non-contact X-Runner digitally controlled handpiece. The laser settings were: pulse energy 120 mJ, pulse mode QSP, frequency 20 Hz. A circular shape of 6 mm in diameter with the X-Runner handpiece was selected. The handpiece was held at a distance 15 mm from the surface and the water spray level was set to 10 ml/min. The treatment area of the X-Runner was positioned around the marked position of the implant (Figure 4). The gingiva around the implant was minimally affected. The situation after placing temporary healing abutments showed a significant difference between both exposure procedures. The X-Runner handpiece with QSP setting provided a minimally invasive treatment (Figures 5, 6). The control examination after 3 days showed a perfect healing process for the implant exposed with X-Runner, which significantly shortened the prosthetic reconstruction time needed (Figure 7).

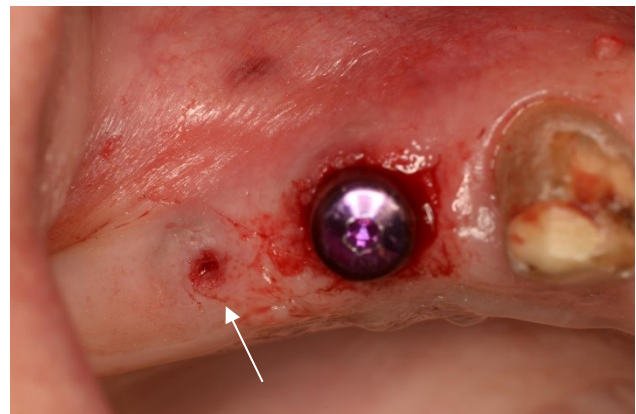


Fig. 4: Before implant exposure, marked position of the implant

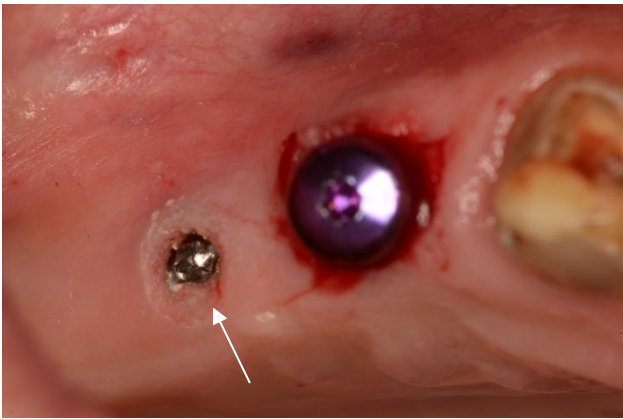


Fig. 5: During implant exposure with X-Runner

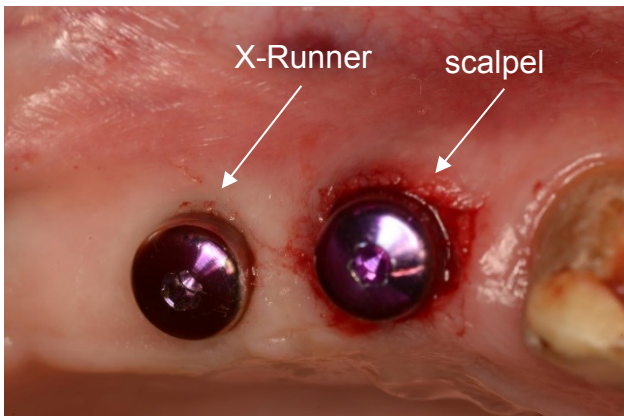


Fig. 6: After placing temporary healing abutment

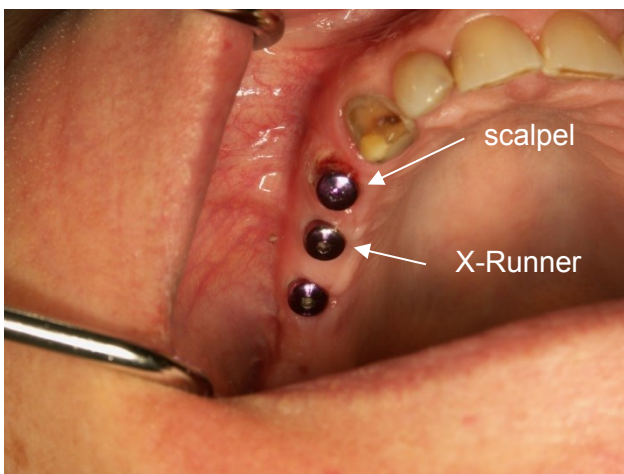


Fig. 7: 3 days after surgery

### c) Hyperpigmentation

A female, 32-year-old patient was examined intraorally. Slightly hyperpigmented gingiva on the upper maxillary arch was found (Figure 8). The patient expressed her wish to treat the colored part of the gingiva. An Er:YAG laser (LightWalker AT, Fotona, Slovenia) with a non-contact X-Runner digitally controlled handpiece was used. The laser settings were: pulse energy 120 mJ, pulse mode QSP, frequency 20 Hz. A circular shape of 3 mm in

diameter with the X-Runner handpiece was selected. The handpiece was held at a distance 15 mm from the gingiva and a light water spray was used. After the treatment site was outlined by the pilot beam, the laser was activated. The treatment was paused after each pass to examine the depth of the ablation and the necessity to remove a deeper layer. It was decided to stop the treatment at a chosen depth and wait for the results (Figure 9). The gingiva healed in 5 days (Figure 10).

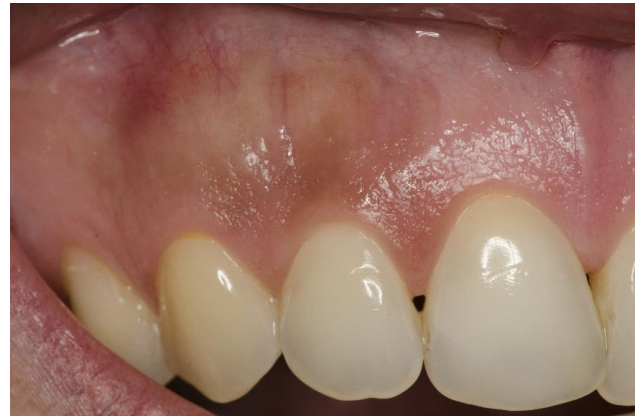

Fig. 8: Hyperpigmentation – before

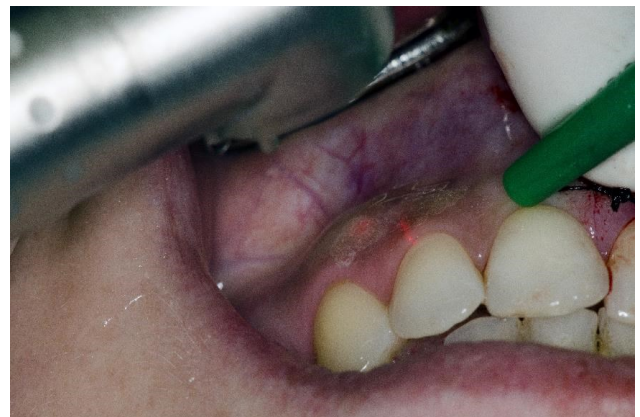

Fig. 9: Hyperpigmentation – during the treatment with X-Runner

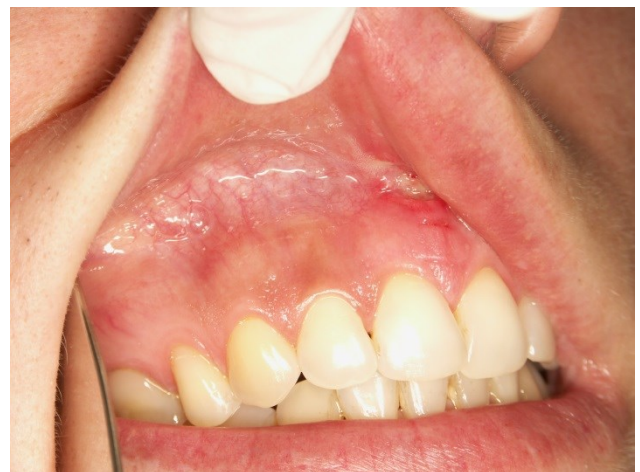

Fig. 10.: 5 Days after the treatment

### III. DISCUSSION

The Er:YAG laser with variable pulse (VSP) technology and tipless handpiece has been recognized as an effective, pleasant, and highly successful treatment modality in oral surgery. The ability of the operator to select the energy, pulse duration and spray settings defines the required interaction of the laser beam with different biologic tissues. When bloodless surgery is preferred, LP or VLP modes with longer pulse durations to add a thermal effect have been reported [7]. In the presented cases, a QSP mode was used, where the energy is delivered in a train of extremely short pulses of high frequency [8]. In this way the ablation is very precise and heals even faster than with LP mode due to the minimally invasive delivery of short, low energy pulses of high frequency.

There have not been any reports of using the X-Runner handpiece on oral soft tissue so far. Its ability to treat relatively large areas of different shapes very precisely and uniformly appeared to be very useful in our cases. The ablation depth can be roughly predicted for certain parameter settings and a known structure of soft tissue can be ablated, thus the required number of passes can be set in advance. Automatic guidance of the laser beam allows higher repetitions to be used, and consequently procedures are completed faster.

### IV. CONCLUSIONS

It was found out that removing lesions or soft tissue with the non-contact, digitally controlled X-Runner handpiece is very safe and pleasant for the patient and very effective and comfortable for the operator. The operational field is very clear, especially because there was no bleeding during the operation with the QSP mode. The interventions were performed very quickly because of the automatic coverage of the area with the X-Runner handpiece.

### REFERENCES

1. Holmstrup P, Vedtofte P, Reibel J, Stoltze K. Long-term treatment outcome of oral premalignant lesions. *Oral Oncology* 2006;42:461-474.
2. Moritz A. *Oral Laser Applications*. Quintessenz Verlags-GmbH 2006:450-453.
3. Motisingh Rathod D, Mulay S. Comparative evaluation of Er:YAG and Nd:YAG Laser for gingival depigmentation. *J Dent Las* 2013;7:38-42.
4. Farnoosh AA. Treatment of gingival pigmentation and discoloration for esthetic purposes. *Int J Periodontics Restorative Dent* 1990;10:312-319.
5. Buser N, von Arx T. Surgical procedures in partially edentulous patients with ITI implants. *Clin Oral Impl Res* 2000;11(Suppl):83-100.
6. Olivi G, Signore A, Olivi M, Genovese MD. Lingual frenectomy: functional evaluation and new therapeutical approach. *Eur J Paediatr Dent* 2012;13:101-106.
7. Maden I, Kazak Z, Erbil Maden Ö. Lasers in aesthetic dentistry. *Cosm Dent* 2013;7:30-32.
8. Lukac M, Malej Primc N, Pirnat S. Quantum Square Pulse Er:YAG Lasers for fast and precise hard dental tissue preparation. *J LAHA*. 2012;1:14-21.

The intent of this Laser and Health Academy publication is to facilitate an exchange of information on the views, research results, and clinical experiences within the medical laser community. The contents of this publication are the sole responsibility of the authors and may not in any circumstances be regarded as official product information by medical equipment manufacturers. When in doubt, please check with the manufacturers about whether a specific product or application has been approved or cleared to be marketed and sold in your country.